

Article

Rapid systematic review of neonatal COVID-19 including a case of presumed vertical transmission

Gordon, Morris, Kagalwala, Taher, Rezk, Karim, Rawlingson, Chris, Ahmed, M Idris and Guleri, Achyut

Available at <http://clock.uclan.ac.uk/33444/>

Gordon, Morris ORCID: 0000-0002-1216-5158, Kagalwala, Taher, Rezk, Karim, Rawlingson, Chris, Ahmed, M Idris and Guleri, Achyut (2020) Rapid systematic review of neonatal COVID-19 including a case of presumed vertical transmission. BMJ Paediatrics Open, 4 (1). e000718.

It is advisable to refer to the publisher's version if you intend to cite from the work.
<http://dx.doi.org/10.1136/bmjpo-2020-000718>

For more information about UCLan's research in this area go to <http://www.uclan.ac.uk/researchgroups/> and search for <name of research Group>.

For information about Research generally at UCLan please go to <http://www.uclan.ac.uk/research/>

All outputs in CLoK are protected by Intellectual Property Rights law, including Copyright law. Copyright, IPR and Moral Rights for the works on this site are retained by the individual authors and/or other copyright owners. Terms and conditions for use of this material are defined in the <http://clock.uclan.ac.uk/policies/>

Rapid systematic review of neonatal COVID-19 including a case of presumed vertical transmission

Morris Gordon ^{1,2} Taher Kagalwala ², Karim Rezk,² Chris Rawlingson,² M Idris Ahmed,² Achyut Guleri³

To cite: Gordon M, Kagalwala T, Rezk K, *et al*. Rapid systematic review of neonatal COVID-19 including a case of presumed vertical transmission. *BMJ Paediatrics Open* 2020;**4**:e000718. doi:10.1136/bmjpo-2020-000718

Received 28 April 2020
Revised 13 May 2020
Accepted 16 May 2020

ABSTRACT

Objective To carry out a systematic review of the available studies on COVID-19 (coronavirus disease 2019) in neonates seen globally since the onset of the COVID-19 global pandemic in 2020. The paper also describes a premature baby with reverse transcription (RT)-PCR-positive COVID-19 seen at the Blackpool Teaching Hospitals NHS Foundation Trust, UK.

Design We conducted a multifaceted search of the Cumulative Index to Nursing and Allied Health Literature, Embase, Medline and PubMed from 1 December 2019 to 12 May 2020 to harvest articles from medical journals and publications reporting cases of COVID-19 in neonates from anywhere in the world. Additional searches were also done so as not to miss any important publications. Write-up was in line with the Preferred Reporting Items for Systematic Reviews and Meta-Analyses, the protocol for the review was registered with International Prospective Register of Systematic Reviews (PROSPERO), and risk of bias was analysed with the Newcastle-Ottawa tool. Additionally, the preterm neonate with COVID-19 from our hospital is also reported.

Results The systematic review has revealed eight studies where neonates have been described to have confirmed COVID-19, with low risk of bias. Of the 10 reported cases elsewhere, only three are likely to be vertically transmitted, while seven occurred in the postperinatal period and are likely to have been postnatally acquired. All neonates had a mild course, recovered fully and were negative on retesting. Our case of COVID-19 in a 32-week premature baby from the UK was delivered by emergency caesarean section, with the mother wearing a face mask and the family having no contact with the neonate, suggesting vertical transmission. On day 33, the neonate was asymptomatic but was still RT-PCR-positive on nasopharyngeal airway swab.

Conclusions Neonatal infection is uncommon, with only two previously reported cases likely to be of vertical transmission. The case we report is still RT-PCR-positive on day 28 and is asymptomatic. Ongoing research is needed to ascertain the epidemiology of COVID-19 in neonates.

INTRODUCTION

The novel coronavirus disease (COVID-19) is a highly contagious disease that was first reported in Wuhan, Hubei Province, China in December 2019. Within weeks of

What is known about the subject?

- ▶ COVID-19 has been described globally in children and adults of all age groups.
- ▶ Few cases have been reported in neonates and preterm babies.

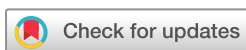What this study adds?

- ▶ This review found only 10 published cases of COVID-19 in neonates, as well as reporting a further case.
- ▶ The course appears mild and vertical transmission even rarer, occurring in only three cases.

the emergence of the disease, it has spread to several countries, and the WHO declared the outbreak as a public health emergency of international concern in January 2020 and as a pandemic in March 2020.¹ According to the WHO's Situation Report 113 published on 12 May 2020, coronavirus now affects 210 countries and 2 international conveyances, and has affected more than 4 100 000 persons, with more than 283 000 individuals dead.²

COVID-19 is caused by severe acute respiratory syndrome coronavirus 2 (SARS-CoV-2), previously known as the 2019 novel coronavirus or 2019-nCoV. SARS-CoV-2 is a novel member of coronaviruses, which are a large class of highly diverse, enveloped, positive-sense, single-stranded RNA viruses.³ Most reported cases of the disease are in adults, but the disease has also been reported in children, including neonates.⁴

While COVID-19 typically presents as acute respiratory disease and pneumonia, it has been reported to also impact other systems including the gastrointestinal tract.⁵ The first reported paediatric case of COVID-19 was probably of a 10-year-old boy from Shenzhen, China diagnosed with the condition in



© Author(s) (or their employer(s)) 2020. Re-use permitted under CC BY-NC. No commercial re-use. See rights and permissions. Published by BMJ.

¹Biomedical evidence synthesis and translation to practice unit, University of Central Lancashire, Preston, UK

²Families division, Blackpool Victoria Hospital, Blackpool, UK

³microbiology department, Blackpool Victoria Hospital, Blackpool, UK

Correspondence to

Dr Morris Gordon; Mgordeon@uclan.ac.uk

January 2020.⁶ Since then, there have been a few other reports of confirmed COVID-19 in neonates.

We did a rapid systematic review to summarise the published data on neonatal presentations of COVID-19. We also report a case of a 32-week premature baby with COVID-19 born to a COVID-19-affected mother.

METHODS

Search strategy and study selection

This study is reported in accordance with the Preferred Reporting Items for Systematic Reviews and Meta-Analyses.⁷ The protocol was registered with the International Prospective Register of Systematic Reviews (PROSPERO).⁸ Considering the date of the earliest confirmed reports of COVID-19, we have searched PubMed, Medline, Embase and Cumulative Index to Nursing and Allied Health Literature for studies published since 1 December 2019. The WHO database of publications on novel coronavirus was additionally searched for potentially relevant publications.⁹ We also searched the references listed within the retrieved articles to try and identify additional citations that may have been missed during the electronic search.

Eligible studies (including case reports, case series, cohort studies and retrospective studies) published in English-language peer-reviewed journals that have described original demographic and clinical characteristics of children diagnosed with COVID-19 were included for analysis. Review articles and opinion articles not reporting original data were excluded.

For the purpose of the electronic search, studies were identified with the following search terms: (coronavirus OR covid19 OR COVID-19 OR SARS-Cov-2 OR 2019-nCoV) AND (neonat* OR infant OR preterm OR premature OR Prem) AND (case report OR case series OR symptom OR symptoms OR characteristics OR characteristic*). We included both medical subject headings and free-text terms.

Two independent reviewers (MG and TK) evaluated the titles and abstracts of papers to identify relevant studies. Articles identified were then independently

assessed by the two reviewers using predefined eligibility criteria. Any disagreements between authors regarding study inclusion were resolved through discussion among the reviewers.

Risk of bias

For cohort and case-control studies, we used the Newcastle-Ottawa tool¹⁰ to assess the risk of bias. For case reports and case series, we used the tool suggested by Murad *et al.*¹¹ This had previously been used in published systematic reviews,¹² and was adapted from the Newcastle-Ottawa tool by the removal of items that relate to comparability and adjustment (which are not relevant to non-comparative studies) and retained items that focused on selection, representativeness of cases, and ascertainment of outcomes and exposure. This resulted in five criteria in the form of questions with a binary response (yes/no), whether the item was suggestive of bias or not. We considered the quality of the report as good (low risk of bias) when all five criteria were fulfilled, moderate when four were fulfilled, and poor (high risk of bias) when three or fewer were fulfilled. In the end, all the eight selected studies had a low risk of bias and were deemed good (table 1).

Data extraction

Data were extracted independently by the two reviewers on to a Microsoft Excel spreadsheet using a predefined checklist. Extracted data included but were not limited to the following: study design, year of publication, country, author name(s), number of patients, patient demographics, gastrointestinal symptoms and/or signs, other clinical symptoms and timing of gastrointestinal symptoms in relation to respiratory symptoms. The extracted data were compared and differences were discussed and resolved by consensus.

Statistical analysis

Statistical analyses were mainly descriptive (numerical and graphical). Frequencies and proportions were used to summarise qualitative variables, whereas means, medians, SD and quartiles or ranges were used to summarise quantitative variables. Where possible, meta-analyses

Table 1 Risk of bias assessment of the included studies (case reports and case series)

Study	Cases (n)	Question 1	Question 2	Question 3	Question 4	Question 5	Risk of bias
Alzamora <i>et al</i> ²⁹	1	Yes	Yes	Yes	Yes	Yes	Low
Kamali Aghdam <i>et al</i> ³⁰	1	Yes	Yes	Yes	Yes	Yes	Low
Chacón-Aguilar <i>et al</i> ³¹	1	Yes	Yes	Yes	Yes	Yes	Low
Piersigilli <i>et al</i> ³²	1	Yes	Yes	Yes	Yes	Yes	Low
Wang <i>et al</i> ³³	1	Yes	Yes	Yes	Yes	Yes	Low
Wang <i>et al</i> ³⁴	1	Yes	Yes	Yes	Yes	Yes	Low
Yu <i>et al</i> ³⁵	1	Yes	Yes	Yes	Yes	Yes	Low
Zeng <i>et al</i> ³⁶	3	Yes	Yes	Yes	Yes	Yes	Low

Tool details

Low risk items: Green shading, Unclear risk: Yellow shading, High risk: red shading

using the random-effects model were performed to assess associations between demographic features and gastrointestinal symptoms. All statistical analyses were performed using StatsDirect statistical software.

Case report

The research and development department approved the writing of this paper.

Patient and public involvement

Patients and/or the public were not involved in the design, or conduct, or reporting, or dissemination plans of this research.

RESULTS

Our search was performed on 12 May 2020, and initial screening yielded 27 publications for full-text searching when screened against the inclusion and exclusion criteria. One of these publications was unrelated to neonates and was excluded.¹³ Ten other publications were excluded as the neonate(s) in all these were not confirmed to be infected.^{14–24} It is worth noting that one of the cases²⁴ reported a COVID-19-positive mother who was very unwell and delivered by caesarean section at the bedside; the 35-week neonate unfortunately died within

2 hours. No further details regarding the neonate are described and confirmation of diagnosis is not reported; hence, this case was excluded.

Four other publications were excluded as these were review articles (figure 1).^{25–28}

This left eight articles that described neonates with COVID-19 confirmed on reverse transcription (RT)-PCR swabs. The characteristics of the included studies are shown in table 2. They included descriptions of one neonate each from Peru,²⁹ Iran,³⁰ Spain³¹ and Belgium³² and six from China.^{33–36}

The clinical characteristics of the 10 babies described in the eight publications are listed in table 2.

The report from Peru²⁹ describes the occurrence of COVID-19 in a presumed 34-week baby who tested positive as early as 16 hours of life. The baby was intubated on day 0 and needed respiratory support for 6 days, but made an uneventful recovery therefrom. Imaging was negative. The baby had been separated from the mother at birth and had no postnatal contact with the family or anyone who was coronavirus-positive. This may be a case of vertical transmission.

The Iranian case report³⁰ describes the occurrence of COVID-19 in a 15-day-old neonate. Details regarding the neonate's delivery records are sketchy. This is unlikely

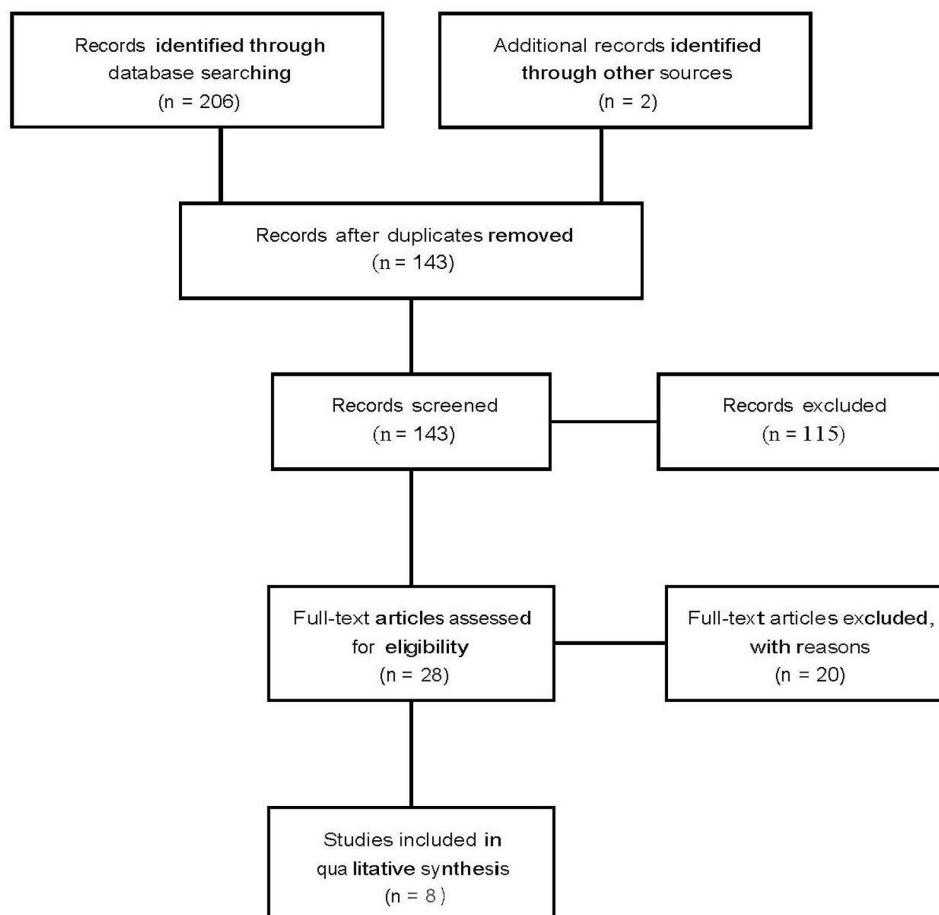


Figure 1 Flow diagram for study selection.

Table 2 Characteristics of included studies reporting COVID-19 cases in neonates

Study, country, setting	Sample size	Age of symptom onset	Gestations of neonate at delivery	Diagnosis present in the mother and method	Delivery details/ method/ Apgar/ resuscitation	PPE procedures undertaken at delivery	Method of COVID-19 diagnosis and timing	Symptoms and complications	Therapy	Length of follow-up/final outcome
Alzamora <i>et al.</i> ²⁹ Peru, secondary hospital	1	Day 0	Unclear, presumed 34 weeks.	Nasopharyngeal swab RT-PCR assay positive.	The neonate weighed 2970 g, with Apgar scores of 6 and 8 at 1 and 5 min, respectively.	He was immediately separated from his mother and was not exposed to family members.	Nasopharyngeal swab of neonate for SARS-CoV-2 RT-PCR, obtained 16 hours after delivery.	Neonate was electively intubated at birth.	Baby required 12 hours, then continuous positive airway pressure and was weaned successfully.	On the sixth day of life, the newborn had mild respiratory difficulty and sporadic cough requiring supplemental oxygen with nasal cannula.
Kamali Aghdam <i>et al.</i> ³⁰ Iran, children's hospital	1	15 days	Term.	CS, no diagnostic tests in mother.	Not stated in detail.	Not reported.	Pharyngeal swab RT-PCR assay positive.	Fever, no cough, mild subcostal recession.	Oxygen and fluids, vancomycin and amikacin given.	Discharged well on day 6 after admission.
Chacón-Aguilar <i>et al.</i> ³¹ Spain, secondary hospital	1	26 days	Not reported.	Symptomatic family members, no further details.	Unremarkable history, nil else noted.	Not reported.	A nasopharyngeal swab sample was tested for SARS-CoV-2 on admission.	Swinging fever, cranial ultrasound and EEG were normal.	Empirical antibiotics.	Day 6 discharge, neurologically normal and follow-up appointment booked.
Piersigilli <i>et al.</i> ³² Belgium	1	From birth	26 weeks+4 days' gestation.	Diagnosed on day 6 with chest symptoms and by RT-PCR from nasopharyngeal swab.	CS section due to maternal HELLP syndrome, Apgars 5/8/8 at 1 min/5 min/10 min.	None reported.	Day 7 when mother's results returned by RT-CPR.	Normal preterm course, chest radiograph showed no parenchymal infiltrates.	Initial non-invasive positive pressure ventilation and surfactant, pneumothorax at 12 hours.	Swab negative at 14 days, still in neonatal unit receiving care.
Wang <i>et al.</i> ³³ China, secondary hospital	1	17 days	38 weeks 6 days.	Mother and father positive for nucleic acid testing.	Normal delivery, no resuscitation.	Not reported.	Day 20 negative nasopharyngeal swab for RT-PCR, positive on day 23.	Day 17 vomiting and loose stools, day 18 fever, day 20 cough.	No active management described.	Day 29 RT-PCR swabs negative and child discharged on day, discharged 14 days after admission, well.
Wang <i>et al.</i> ³⁴ Wuhan, China, secondary hospital	1	N/A, as asymptomatic	Term.	Pharyngeal swab positive.	Emergency CS, Apgar 8 at 1 minute, 9 at 5 minute.	The mother had been wearing an N95 mask throughout the operation, and the baby had no contact with the mother after birth.	The result of pharyngeal swab for SARS-CoV-2 was positive at 36 hours after birth. All products of delivery negative.	Asymptomatic.	No treatment needed.	Day 17 swabs negative, discharged on day 18.
Yu <i>et al.</i> ³⁵ China, tertiary hospital	1 (6 negative infants reported)	Day 1	39 weeks 6 days.	Pharyngeal swab RT-PCR positive on admission.	Elective CS due to maternal diagnosis.	Maternal swab RT-PCR.	Swab positive for RT-PCR.	No fever/cough, with mild shortness of breath symptoms. Chest X-ray revealed mild pulmonary infection.	Standard neonatal care.	Discharged after 2 weeks, well.

Continued

Table 2 Continued

Study, country, setting	Sample size	Age of symptom onset	Gestations of neonate at delivery	Diagnosis present in the mother and method	Delivery details/ method/ Apgar/ resuscitation	PPE procedures undertaken at delivery	Method of COVID-19 diagnosis and timing	Symptoms and complications	Therapy	Length of follow-up/final outcome
Zeng <i>et al.</i> ³⁶ China, tertiary hospital	33 babies analysed, 3 positive	1. Day 2 2. Day 1 3. Day 1	1. 40 weeks. 2. 40+4 weeks. 3. 31+2 weeks.	All mothers had confirmed COVID-19 pneumonia by nasopharyngeal swabs (RT-PCR).	All three were elective CS due to maternal COVID-19 pneumonia.	Not described in the communication.	Nasopharyngeal and anal swabs sent for SARS-CoV-2 RT-PCR in all three babies; all were positive on day 2 and day 4, and negative by days 6–7.	1. Lethargy + fever with pneumonia on X-ray; resolved by 6 days. 2. Same as one above. 3. Neonatal RDS and <i>Enterobacter</i> bacteraemia; resolved with antibiotics.	Standard neonatal care and antibiotics; for the preterm baby, treatment as indicated for RDS.	Final devolution not described in the article, but stated as favourable outcomes in all three babies.

CS, caesarean section; EEG, electroencephalogram; HELL P, hemolysis, elevated liver enzymes, and a low platelet count syndrome; N/A, not applicable; PPE, personal protective equipment; RDS, respiratory distress syndrome; RT-PCR, reverse transcription PCR; SARS-CoV-2, severe acute respiratory syndrome coronavirus 2.

to be a vertical transmission. Also, the mother did not undergo any diagnostic tests.

The report from Spain³¹ describes a 26-day-old neonate presenting to the hospital with two episodes of presumed seizures. The baby was treated empirically with antibiotics, but tested positive for SARS-CoV-2 on nasopharyngeal swab. The baby was discharged after 6 days, with recommendations for home isolation for a further period of time. He was clinically well at discharge.

The report from Belgium³² is of a baby delivered at 26+4 weeks of gestation and discovered to have a positive nasopharyngeal swab for SARS-CoV-2 RT-PCR done on her after her mother tested positive on account of ill health on day 7 after preterm delivery by caesarean section. The baby's results turned negative 14 days after the initial positive result. She was still on the neonatal unit on account of her extreme prematurity.

The four case reports from China are from secondary (2) and tertiary (2) hospitals. In the study by Wang *et al.*³³ both parents were COVID-19-positive. The baby presented with vomiting and diarrhoea on day 17 of life and was initially negative up to the 20th day of life, but turned positive on day 23, and later negative on day 29. The baby was discharged 14 days after admission and remained well, with no respiratory symptoms and needing no treatment.

The case described by Wang *et al.*³⁴ is a presumed vertical transmission in a term neonate that tested positive at 36 hours after birth. Placental and birth products tested negative, and the baby and the mother had no contact intranatally or postnatally. The baby remained asymptomatic and was discharged on day 18 after the 17th-day swabs tested negative.

The report by Yu *et al.*³⁵ describes a COVID-19-positive asymptomatic term neonate born to a positive mother by caesarean section. The baby was discharged after 2 weeks' stay in Wuhan Children's Hospital in Wuhan, China. This study reported the outcome in six other positive mothers whose babies tested negative.

Finally, Zeng *et al.*³⁶ describe 3 out of 33 neonates in their series from the Wuhan Children's Hospital who tested positive on nasopharyngeal swabs for SARS-CoV-2 by RT-PCR. All the neonates were born by caesarean section. In each case, the mother had COVID-19 pneumonia. While two babies were born at term, one was born preterm. All babies were symptomatic and had positive swabs on days 2 and 4 of life, but tested negative on days 6 (in two babies) and 7 (in the preterm baby).

Case report

A 36-year-old, gravida 3 mother presented at 32 weeks of gestational age with cough, high fever, lymphopaenia and a positive RT-PCR swab for SARS-CoV-2. She underwent an emergency caesarean section after being given two doses of antenatal steroids 12 hours apart. The mother wore a fluid-resistant mask, and the entire operative team was dressed in full personal protective equipment. The baby was a live, female newborn weighing 2150 g. She



was directly handed over to the neonatal team without any contact with the mother. Postnatally, she has had no contact with the mother or the father or any family member.

She needed respiratory support, increasing from high-flow nasal oxygen and then requiring surfactant via less invasive surfactant administration, progressing to intubation. The baby was extubated the next day and then moved to biphasic positive airway pressure support, weaning over the next few days to air.

The radiograph showed findings consistent with surfactant deficiency lung disease. The initial RT-PCR swab on day 1 of life was negative, but the child had a positive swab on day 4, day 14 and also on day 21, while being asymptomatic.

While the baby gradually recovered and is being isolated in the neonatal unit and being fed and nursed, the mother deteriorated rapidly after the delivery and was kept on a ventilator in the intensive care unit of the hospital for a week. She underwent tracheostomy. Over the past week, she continued to improve, and she has now been moved out of the intensive care unit and the tracheostomy has been closed. She remains on oxygen at the time of writing this paper.

The baby remained RT-PCR-positive on day 28 of life, but was clinically well, and was discharged with the mother on day 33 of life.

DISCUSSION

This systematic review of published literature has shown only 10 case reports of neonatal COVID-19 infection. While seven of these ten babies were full-term, three were preterm, the lowest being at 26+4 weeks of gestation. Three are suspected to be vertically transmitted, in addition to our own case, the summary of which has been described. Ours is the first case of a premature baby with COVID-19 in the UK and the fourth preterm baby globally. Also, our baby continued to remain positive at 28 days of life. It remains to be seen when the baby will become RT-PCR-negative, although it is clear that the baby is otherwise asymptomatic from the coronavirus infection.

Global knowledge about this new infectious pandemic is evolving. The current knowledge is that the virus is less virulent in children, although there have been case reports of older children dying as a result of contracting the infection. There is no available proven treatment, although many trials on different known and new drugs are ongoing both in the UK and elsewhere in the world.

Our rapid review concentrates on neonatal COVID-19. The methodology was performed rapidly; however, this did not impact the high-quality systematic approach that such a review requires. We present only 10 positive neonatal cases from the global literature within the last 5 months since the pandemic started to emerge, and only three were potentially of vertical transmission. Within our excluded studies, it is worth noting that a further 65

neonates were reported as born to COVID-19-positive mothers who themselves tested negative on RT-PCR.^{14 16–22} As the goal of the review was not to report well neonates born to infected mothers, this is likely a small representation of a much larger sample of reported cases of well neonates. Therefore, it does currently seem reasonable to suggest that vertical transmission to neonates and neonatal infection from infected family members are both rare occurrences. Additionally, when they do occur, the course appears mild. A previous review which was performed up to March 2020 considered children and neonates and found a similar mild course within these cohorts.³⁷

The main limitation of this review is the relative novelty of COVID-19. It is possible that many more cases are either not reported to scholarly texts or in the process of peer review, and the reader must bear this in mind. Therefore, it is likely this review will be rapidly out of date and a repeat review will be required. Similarly, the scope of the review was very precise, and therefore it is inappropriate to suggest any firm conclusions regarding the incidence of COVID-19-negative neonatal cases born to infected mothers or the details of maternal outcomes, which would both have to be specific outcomes and are better covered in works focused on these issues, some of which were uncovered in this review.^{23 25}

We believe that many other reports of this kind will emerge. It is key that future research considers the possibility of transmission from asymptomatic mothers. This will likely become of greater interest as population testing increases. It is also of particular interest that the case we report has remained RT-PCR-positive on day 28 and on discharge, despite being asymptomatic. Questions as to the time needed for seroconversion in infected children, the ability to spread while being asymptomatic and ongoing immunity after infection all require future investigation.

CONCLUSIONS

Neonatal infection has only been reported in 10 cases, with this study adding a case report of an eleventh case. Three occurred in the late neonatal period and three were presumed cases of vertical transmission, with the addition of the case we report likely to be of vertical transmission. All 10 previously reported cases had a mild course, and respiratory symptoms were generally consistent with their gestational age. Ongoing research is needed to ascertain the epidemiology of COVID-19 in neonates.

Twitter Morris Gordon @drmorrisgordon and Taher Kagalwala @drtaher

Acknowledgements The authors would like to thank the father of the baby for giving us the permission to publish the case report anonymously. Thanks are also due to the virology department of the hospital for reporting on the swabs of the baby.

Contributors MG and TK led the systematic review and manuscript drafting. KR, CR, MIA and AG cared for the neonate reported, contributed to the manuscript and approved the submission.

Funding The authors have not declared a specific grant for this research from any funding agency in the public, commercial or not-for-profit sectors.

Competing interests None declared.

Patient consent for publication Next of kin consent obtained.

Provenance and peer review Not commissioned; externally peer reviewed.

Data availability statement All data relevant to the study are included in the article or uploaded as supplementary information.

Open access This is an open access article distributed in accordance with the Creative Commons Attribution Non Commercial (CC BY-NC 4.0) license, which permits others to distribute, remix, adapt, build upon this work non-commercially, and license their derivative works on different terms, provided the original work is properly cited, appropriate credit is given, any changes made indicated, and the use is non-commercial. See: <http://creativecommons.org/licenses/by-nc/4.0/>.

ORCID iDs

Morris Gordon <http://orcid.org/0000-0002-1216-5158>

Taher Kagalwala <http://orcid.org/0000-0002-9846-9696>

REFERENCES

- Bedford J, Enria D, Giesecke J, *et al*. WHO Strategic and Technical Advisory Group for Infectious Hazards. COVID-19: towards controlling of a pandemic. *Lancet* 2020;S0140-6736:30673-5.
- World Health Organization. Available: https://www.who.int/docs/default-source/coronaviruse/situation-reports/20200512-covid-19-sitrep-113.pdf?sfvrsn=feac3b6d_2
- He F, Deng Y, Li W. Coronavirus disease 2019 (COVID-19): what we know? *J Med Virol* 2020.
- Lai C-C, Liu YH, Wang C-Y, *et al*. Asymptomatic carrier state, acute respiratory disease, and pneumonia due to severe acute respiratory syndrome coronavirus 2 (SARS-CoV-2): facts and myths. *J Microbiol Immunol Infect* 2020:S1684-1182(20)30040-2.
- Gu J, Han B, Wang J. COVID-19: gastrointestinal manifestations and potential Fecal-Oral transmission. *Gastroenterology* 2020;158:1518-9.
- Chan JF-W, Yuan S, Kok K-H, *et al*. A familial cluster of pneumonia associated with the 2019 novel coronavirus indicating person-to-person transmission: a study of a family cluster. *Lancet* 2020;395:514-23.
- Moher D, Liberati A, Tetzlaff J, *et al*. Preferred reporting items for systematic reviews and meta-analyses: the PRISMA statement. *J Clin Epidemiol* 2009;62:1006-12.
- University of Leicester. PROSPERO: International prospective register of systematic reviews. Available: <https://www2.le.ac.uk/library/find/databases/p/Prospero>
- World Health Organization. WHO database of publications on coronavirus disease (COVID-2019), 2020. Available: www.who.int/emergencies/diseases/novel-coronavirus-2019/global-research-on-novel-coronavirus-2019-ncov
- Newcastle - Ottawa quality assessment scale cohort studies. Available: http://www.evidencebasedpublichealth.de/download/Newcastle_Ottawa_Scale_tool.pdf
- Murad MH, Sultan S, Haffar S, *et al*. Methodological quality and synthesis of case series and case reports. *BMJ Evid Based Med* 2018;23:60-3.
- Bazerbachi F, Leise MD, Watt KD, *et al*. Systematic review of mixed cryoglobulinemia associated with hepatitis E virus infection: association or causation? *Gastroenterol Rep* 2017;5:178-84.
- Wei M, Yuan J, Liu Y, *et al*. Novel coronavirus infection in hospitalized infants under 1 year of age in China. *JAMA* 2020;323:1313-4.
- pp Chen H, Guo J, Wang C, *et al*. Clinical characteristics and intrauterine vertical transmission potential of COVID-19 infection in nine pregnant women: a retrospective review of medical records. *Lancet* 2020;395:809-15.
- Goldstein M. Chinese study suggests COVID-19 is not transmitted from pregnant mothers to newborns. *Neonatal Today* 2020;60-2.
- Lowe B, Bopp B. COVID-19 vaginal delivery - a case report. *Aust N Z J Obstet Gynaecol* 2020. doi:10.1111/ajo.13173. [Epub ahead of print: 15 Apr 2020].
- Liu W, Wang J, Li W, *et al*. Clinical characteristics of 19 neonates born to mothers with COVID-19. *Front Med* 2020;14:193-8.
- Peng Z, Wang J, Mo Y, *et al*. Unlikely SARS-CoV-2 vertical transmission from mother to child: a case report. *J Infect Public Health* 2020;13:818-20.
- Chen Y, Peng H, Wang L, *et al*. Infants born to mothers with a new coronavirus (COVID-19). *Front Pediatr* 2020;8.
- Zhu H, Wang L, Fang C, *et al*. Clinical analysis of 10 neonates born to mothers with 2019-nCoV pneumonia. *Transl Pediatr* 2020;9:51-60.
- Li N, Han L, Peng M, *et al*. Maternal and neonatal outcomes of pregnant women with COVID-19 pneumonia: a case-control study. *Clin Infect Dis* 2020. doi:10.1093/cid/ciaa352. [Epub ahead of print: 30 Mar 2020].
- Yang P, Wang X, Liu P, *et al*. Clinical characteristics and risk assessment of newborns born to mothers with COVID-19. *J Clin Virol* 2020;127:104356.
- Liu D, Li L, Wu X, *et al*. Pregnancy and perinatal outcomes of women with coronavirus disease (COVID-19) pneumonia: a preliminary analysis. *AJR Am J Roentgenol* 2020:1-6.
- Li J, Wang Y, Zeng Y, *et al*. Critically ill pregnant patient with COVID-19 and neonatal death within two hours of birth. *Int J Gynecol Obstet* 2020.
- Kleinwechter H, Laubner K. *Coronavirus disease 2019 (COVID-19) and pregnancy: overview and report of the first German case with COVID-19 and gestational diabetes Diabetologie*, 2020.
- Panahi L, Amiri M, Pouy S, *et al*. Risks of novel coronavirus disease (COVID-19) in pregnancy; a narrative review. *Arch Acad Emerg Med* 2020;8:e34.
- Zaigham M, Andersson O. Maternal and perinatal outcomes with COVID-19: a systematic review of 108 pregnancies. *Acta Obstet Gynecol Scand* 2020. doi:10.1111/aogs.13867. [Epub ahead of print: 07 Apr 2020].
- Parazzini F, Bertolus R, Mauri PA, *et al*. Delivery in pregnant women infected with SARS-CoV-2: a fast review. *Int J Gynaecol Obstet* 2020. doi:10.1002/ijgo.13166. [Epub ahead of print: 09 Apr 2020].
- Alzamora MC, Paredes T, Caceres D, *et al*. Severe COVID-19 during pregnancy and possible vertical transmission. *Am J Perinatol* 2020. doi:10.1055/s-0040-1710050. [Epub ahead of print: 18 Apr 2020].
- Kamali Aghdam M, Jafari N, Eftekhari K. Novel coronavirus in a 15-day-old neonate with clinical signs of sepsis, a case report. *Infect Dis* 2020;52:427-9.
- Chacón-Aguilar R, Osorio-Cámara JM, Sanjurjo-Jimenez I, *et al*. COVID-19: fever syndrome and neurological symptoms in a neonate. *An Pediatr* 2020. doi:10.1016/j.anpede.2020.04.001. [Epub ahead of print: 27 Apr 2020].
- Piersigilli F, Carkeek K, Hocq C, *et al*. COVID-19 in a 26-week preterm neonate. *Lancet Child Adolesc Health* 2020. doi:10.1016/S2352-4642(20)30140-1. [Epub ahead of print: 07 May 2020].
- Wang J, Wang D, Chen G-C, *et al*. SARS-CoV-2 infection with gastrointestinal symptoms as the first manifestation in a neonate. *Chi J of Contemp Ped* 2020;22:211-4.
- Wang S, Guo L, Zhang J, *et al*. A case report of neonatal COVID-19 infection in China. *Clin Infect Dis* 2020:ciaa225.
- Yu N, Li W, Kang Q, *et al*. Clinical features and obstetric and neonatal outcomes of pregnant patients with COVID-19 in Wuhan, China: a retrospective, single-centre, descriptive study. *Lancet Infect Dis* 2020;20:559-64.
- Zeng L, Xia S, Yuan W, *et al*. Neonatal early-onset infection with SARS-CoV-2 in 33 neonates born to mothers with COVID-19 in Wuhan, China. *JAMA Pediatr* 2020. doi:10.1001/jamapediatrics.2020.0878. [Epub ahead of print: 26 Mar 2020].
- Panahi L, Amiri M, Pouy S. Clinical characteristics of COVID-19 infection in newborns and pediatrics: a systematic review. *Arch Acad Emerg Med* 2020;8:e50.