

# Median nerve thenar motor branch anatomical variations

E. Mizia<sup>1</sup>, K.A. Tomaszewski<sup>1</sup>, G. Goncerz<sup>1</sup>, W. Kurzydło<sup>2</sup>, J. Walocha<sup>1</sup>

<sup>1</sup>Department of Anatomy, Jagiellonian University Medical College, Krakow, Poland

<sup>2</sup>Institute of Physiotherapy, Jagiellonian University Medical College, Krakow, Poland

[Received 29 March 2012; Accepted 19 June 2012]

**Background:** The aim of this study was to determine the prevalence of the different types of median nerve thenar motor branch and to compare them with literature data.

**Material and methods:** This study was conducted using median nerves dissected from cadavers stored in a 10% solution of formaldehyde at the Department of Anatomy of Jagiellonian University Medical College (JUMC) and cadavers from the Department of Forensic Medicine JUMC. The research protocol was approved by the Jagiellonian University Ethics Committee (registry KBET/209/B/2002).

**Results:** The studied group comprised 8 (26.7%) women and 22 men (age between 23 and 92 years), yielding a total of 60 thenar motor branches (30 right vs. 30 left). Forty-seven (78.3%) nerves were classified as extraligamentous, 12 (20%) were subligamentous, and 1 (1.7%) was transligamentous. As for the side of origin of the thenar motor branch, in 45 (75%) cases it was the radial side and in 2 (3.33%) cases it was the ulnar side.

**Conclusions:** The obtained results confirm that the extraligamentous type of thenar motor branch is the most common and that the ulnar origin of the thenar motor branch is the rarest. (*Folia Morphol* 2012; 71, 3: 183–186)

**Key words:** anatomical variations, median nerve, thenar motor branch, carpal tunnel

## INTRODUCTION

The carpal tunnel, located on the palmar surface of the wrist, contains the median nerve, four tendons of the flexor digitorum superficialis, four tendons of the flexor digitorum profundus, and the tendon of the flexor pollicis longus [14]. The median nerve is a mixed motor and sensory nerve [6]. It descends beneath the flexor digitorum superficialis, lying on the flexor digitorum profundus in the forearm, within 5 cm of the transverse carpal ligament, and then it becomes more superficial, situated between the tendons of the flexor digitorum superficialis and the flexor carpi radialis [6]. It lies behind and radial to the side of the palmaris longus ten-

don just before entering the carpal tunnel [6]. The median nerve is located between the flexor retinaculum and the tendons of the middle finger flexor digitorum superficialis muscle in wrist extension [6].

The median nerve normally divides into six branches at the distal terminus of the flexor retinaculum [6]. These include the recurrent motor branch innervating the opponens pollicis, the abductor pollicis brevis, and the flexor pollicis brevis.

There exist a number of reports describing the congenital anatomical variations of the median nerve thenar motor branch [1, 7, 9, 10]. These studies use the Poisel classification system [13] for describing median nerve variations and the relationships of the

branches to the transverse carpal ligament (TCL). This system divides the variations into three types — the extraligamentous (type I), the subligamentous (type II), and the transligamentous (type III). In the extraligamentous type, the thenar motor branch arises distal to the TCL and then runs a retrograde course to reach the thenar muscles [2, 13]. In the subligamentous type, the branch arises within the carpal tunnel and remains deep to the TCL until it reaches the thenar muscles [2, 13]. In the transligamentous type, the branch arises within the carpal tunnel and then pierces the TCL to reach the thenar muscles [2, 13].

The aim of this study was to determine the prevalence of the different types of median nerve thenar motor branch and to compare them with literature data.

## MATERIAL AND METHODS

This study was conducted using median nerve motor branches dissected from cadavers stored at the Department of Anatomy of the Jagiellonian University Medical College as well as cadavers from the Department of Forensic Medicine of Jagiellonian University Medical College. The cadavers were examined bilaterally.

There were no restrictions as to gender or age concerning inclusion into the study. Exclusion criteria included extensive damage to the median nerve preventing proper sample acquisition.

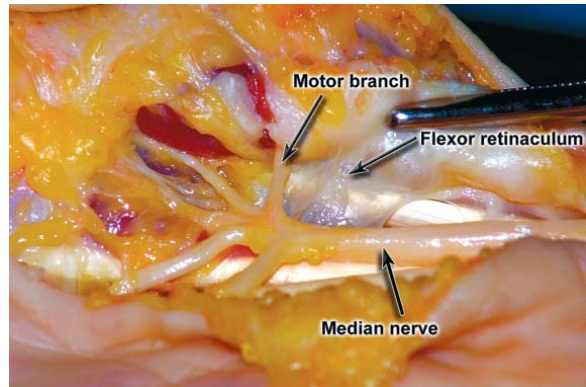
The research protocol was approved by the Jagiellonian University Ethics Committee (registry KBET/209/B/2002).

### Dissection technique

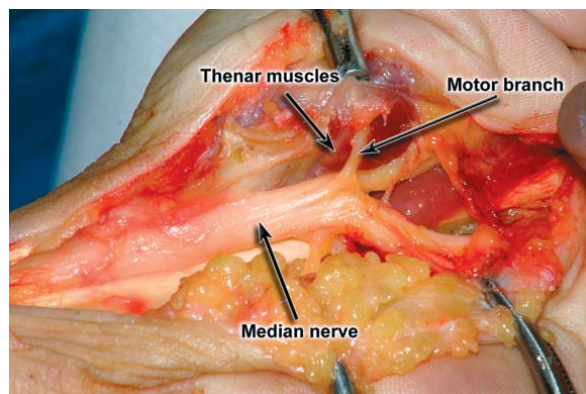
The incision was made starting at the distal 1/3 of the forearm, continuing between the tendon of the flexor carpi radialis and the tendon of the palmaris longus muscle, along the thumb flexion line to the proximal intraphalangeal joint. After dissecting the skin and the subcutaneous tissue, the median nerve was exposed and the flexor retinaculum was cut on the ulnar side, by longitudinal incision. Next the median nerve was dissected (in or above the carpal tunnel) together with the motor branches innervating the muscles of the thumb. The existing incision was closed using a running intradermal suture.

### Statistical analysis

Statistical analysis was conducted using computer software Statistica 10.0 PL by StatSoft Poland. To



**Figure 1.** The extraligamentous course of the thenar motor branch. The motor branch originates from the radial side of the median nerve.



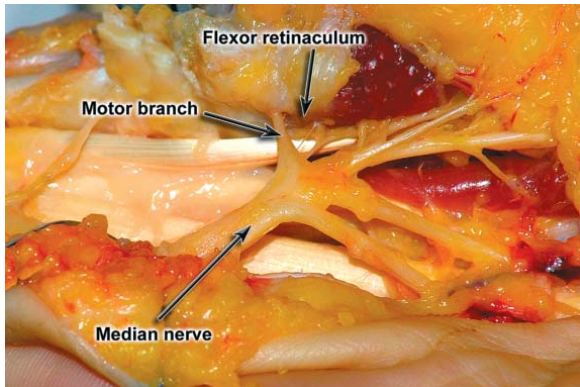
**Figure 2.** The subligamentous course of the thenar motor branch. The motor branch originates from the stem of the median nerve within the carpal tunnel.

analyse the data, elements of descriptive statistics were used (percentage distribution, minimum value, maximum value). To assess differences between proportions, the  $\chi^2$  test (with Yates' correction for continuity) was used. The significance level was set at  $p < 0.05$ .

## RESULTS

The studied group comprised 8 (26.7%) women and 22 men (age between 23 and 92 years), yielding a total of 60 median nerve motor branches (30 right vs. 30 left).

Examination showed that 47 (78.3%) nerves were type I according to Poisel (extraligamentous) (Fig. 1), 12 (20%) were type II (subligamentous) (Fig. 2), and 1 (1.7%) was type III (transligamentous). Figure 3 and Table 1 present a comparison of the obtained results with literature data.



**Figure 3.** The transligamentous course of the thenar motor branch. The motor branch originates from the stem of the median nerve within the carpal tunnel and pierces the flexor retinaculum.

The most common side of origin of the median nerve motor branch was the radial side (45 cases; 75%) (Fig. 1). Branching from the ulnar side of the median nerve was found in 2 (3.33%) cases, from the palmar (anterior) aspect in 6 (10%) cases, and between the radial and palmar side in 7 (11.67%) cases. Table 2 presents percentage distribution of the side of origin of the thenar motor branch as compared with literature data.

### DISCUSSION

This study presents data obtained from the analysis of median nerve thenar motor branch anatomical variations.

**Table 1.** Median nerve variations according to Poisel — comparison with literature data

Author	N	Source	Type I (extraligamentous)	Type II (subligamentous)	Type III (transligamentous)
Poisel (1974) [13]	100	Cadavers	46.00%*	31.00%	23.00%*
Tountas et al. (1987) [15]	821	Intraoperative	81.50%	9.78%	1.30%
Tountas et al. (1987) [15]	92	Cadavers	96.00%*	2.07%*	8.70%
Hurwitz (1996) [7]	80	Intraoperative	55.00%*	29.00%	16.00%*
Kozin (1998) [9]	202	Cadavers	93.00%*	0.00%*	7.00%
Ahn et al. (2000) [1]	354	Intraoperative	96.10%*	2.80%*	1.10%
Lindley (2003) [11]	526	Intraoperative	99.20%*	0.20%*	0.20%
Barbe (2005) [3]	75	Cadavers	64.00%	33.00%	33.00%*
Beris et al. (2008) [5]	110	Intraoperative	No data	27.30%	No data
Al-Qattan (2010) [2]	100	Intraoperative	56.00%*	34.00%	9.00%
Current study	60	Cadavers	78.34%	20.00%	1.66%

\*Marks statistically significant differences ( $p < 0.05$ ) between literature data and the results of the current study

**Table 2.** Side of origin of the thenar motor branch — comparison with literature data

Author	N	Source	Radial side	Palmar (anterior) side	Ulnar side
Tountas et al. (1987) [15]	821	Intraoperative	95.00%*	3.90%	1.10%
Tountas et al. (1987) [15]	92	Cadavers	100.00%*	0.00%*	0.00%
Mackinnon and Dellon (1988) [12]	50	No data	60.00%	22.00% (18% between radial and palmar sides)	0.00%
Hurwitz (1996) [7]	80	Intraoperative	86.25%	12.50%	1.25%
Ahn et al. (2000) [1]	354	Intraoperative	81.70%	17.20%	1.10%
Current study	60	Cadavers	75.00%	10.00% (11.67% between radial and palmar sides)	3.33%

\*Marks statistically significant differences ( $p < 0.05$ ) between literature data and the results of the current study

The incidences of anatomical variations of the median nerve thenar motor branch differ greatly between studies (Table 1). In the current study the most common type (according to Poisel) was the extraligamentous variation. That was also the case in previous studies [1, 2, 7, 9, 11, 13, 16]. In our study only one branch (1.66%) was of the transligamentous type. The percentage of the transligamentous branch varies significantly, from as low as 0.2% [11] to as high as 80% [8]. This could probably be explained easily if the difference existed only between intraoperative and cadaveric studies. But differences also exist between studies acquiring nerves from the same type of source. This invalidates the argument that differences between results of clinical and cadaveric studies may result from broader access to the examined region during autopsy. This also makes obsolete the argument that clinical studies may be biased because the transligamentous course is frequently associated with thenar atrophy [4] and thus a higher incidence of this type could be expected in surgically treated carpal tunnels.

At first the authors thought that a major drawback of this study would be the small number of examined cadavers. But after performing statistical analysis we found that our results do not differ statistically from the results obtained by Tountas et al. [15] on a group of 821 patients (intraoperative study).

When assessing the side of origin of the thenar motor branch, the ulnar aspect seems to be rare in all studies and races (Table 2) [16]. Once again, our result did not differ statistically from the results obtained on larger groups by Ahn et al. [1] (intraoperative study of 354 patients) or Hurwitz [7] (intraoperative study of 80 patients) and only differed slightly from the results obtained by Tountas et al. [15] (intraoperative study of 821 patients).

## CONCLUSIONS

In conclusion, the obtained results confirm that the extraligamentous type of the thenar motor branch is the most common and that the ulnar origin of the median nerve motor branch is the least common. This confirms the necessity of approaching the median nerve from the ulnar side when opening the carpal tunnel.

## REFERENCES

1. Ahn DS, Yoon ES, Koo SH, Park SH (2000) A prospective study of the anatomic variations of the median nerve in the carpal tunnel in Asians. *Ann Plast Surg*, 44: 282–287.
2. Al-Qattan MM (2010) Variations in the course of the thenar motor branch of the median nerve and their relationship to the hypertrophic muscle overlying the transverse carpal ligament. *J Hand Surg Am*, 35: 1820–1824.
3. Barbe M, Bradfield J, Donathan M, Elmaleh J (2005) Coexistence of multiple anomalies in the carpal tunnel. *Clin Anat*, 18: 251–259.
4. Bennett JB, Crouch CC (1982) Comparison syndrome of the recurrent motor branch of the median nerve. *J Hand Surg*, 7: 407–409.
5. Beris AE, Lykissas MG, Kontogeorgakos VA, Vekris MD, Korompilias AV (2008) Anatomic variations of the median nerve in the carpal tunnel release. *Clin Anat*, 21: 514–518.
6. Demircay E, Civelek E, Cansever T, Kabatas S, Yilmaz C (2011) Anatomic variations of the median nerve in the carpal tunnel: a brief review of the literature. *Turk Neurosurg*, 21: 388–396.
7. Hurwitz PJ (1996) Variation in the course of the thenar motor branch of the median nerve. *J Hand Surg*, 21: 344–346.
8. Johnson RK, Shrewsbury MM (1970) Anatomical course of the thenar branch of the median nerve — usually in a separate tunnel through the transverse carpal ligament. *J Bone Joint Surg*, 52: 269–273.
9. Kozin SH (1998) The anatomy of the recurrent branch of the median nerve. *J Hand Surg*, 23: 852–858.
10. Lanz U (1977) Anatomical variations of the median nerve in the carpal tunnel. *J Hand Surg*, 2: 44–53.
11. Lindley SG, Kleinert JM (2003) Prevalence of anatomic variations encountered in elective carpal tunnel release. *J Hand Surg*, 28: 849–855.
12. Mackinnon SE, Dellon AL (1988) Anatomic investigations of nerves at the wrist: I. Orientation of the motor fascicle of the median nerve in the carpal tunnel. *Ann Plast Surg*, 21: 32–35.
13. Poisel S (1974) Ursprung und verlauf des ramus muscularis des nervus digitalis palmaris communis I (N. medianus). *Chir Praxis*, 18: 471–474.
14. Rotman MB, Donovan JP (2002) Practical anatomy of the carpal tunnel. *Hand Clin*, 18: 219–230.
15. Tountas CP, Bhrle DM, MacDonald CJ, Bergman RA (1987) Variations of the median nerve in the carpal. *J Hand Surg*, 12: 708–712.
16. Wolf AW, Packard S, Chow JC (1993) Transligamentous motor branch of the median nerve discovered during endoscopically assisted carpal tunnel release. *Arthroscopy*, 9: 222–223.