

## Journal Pre-proof

Enhancing rotational placement of reconstruction prostheses of the distal femur after sarcoma resection.



Arne De Smet M.D. Resident Orthopaedic Surgery ,  
Dries Verrewaere M.D. Resident Orthopaedic Surgery ,  
Gwen Sys M.D., PhD Orthopaedic Surgeon

PII: S1350-4533(20)30065-5  
DOI: <https://doi.org/10.1016/j.medengphy.2020.05.001>  
Reference: JJBE 3489

To appear in: *Medical Engineering and Physics*

Received date: 29 November 2019  
Revised date: 15 April 2020  
Accepted date: 5 May 2020

Please cite this article as: Arne De Smet M.D. Resident Orthopaedic Surgery , Dries Verrewaere M.D. Resident Orthopaedic Surgery , Gwen Sys M.D., PhD Orthopaedic Surgeon , Enhancing rotational placement of reconstruction prostheses of the distal femur after sarcoma resection., *Medical Engineering and Physics* (2020), doi: <https://doi.org/10.1016/j.medengphy.2020.05.001>

This is a PDF file of an article that has undergone enhancements after acceptance, such as the addition of a cover page and metadata, and formatting for readability, but it is not yet the definitive version of record. This version will undergo additional copyediting, typesetting and review before it is published in its final form, but we are providing this version to give early visibility of the article. Please note that, during the production process, errors may be discovered which could affect the content, and all legal disclaimers that apply to the journal pertain.

© 2020 Published by Elsevier Ltd on behalf of IPEM.

#### HIGHLIGHTS

- Currently there are no accepted international guidelines for the correct placement of reconstruction prostheses in the axial plane.
- The linea aspera is not a reliable landmark for the axial rotation of femoral implants.
- The position of the linea aspera is highly dependent on the osteotomy height and differs between individual patients.
- Preoperative assessment of the linea aspera is advocated in order to reduce the chance of malrotation.

Journal Pre-proof

Enhancing rotational placement of reconstruction prostheses of the distal femur after sarcoma resection.

Arne De Smet<sup>1</sup>, Dries Verrewaere<sup>1</sup>, Gwen Sys

- Arne De Smet<sup>a,b</sup>, M.D., Resident Orthopaedic Surgery
  - Arne.de.smet@vub.be
- Dries Verrewaere<sup>a,c</sup>, M.D., Resident Orthopaedic Surgery
  - Dries.verrewaere@ugent.be
- Gwen Sys<sup>a,c</sup>, M.D., PhD, Orthopaedic Surgeon
  - Gwen.Sys@ugent.be

<sup>a</sup> Department of Orthopaedic Surgery and Traumatology, Ghent University Hospital, Belgium.

<sup>b</sup> Faculty of Medicine and Pharmacy, Vrije Universiteit Brussel, Belgium.

<sup>c</sup> Faculty of Medicine and Health Sciences, Ghent University, Belgium.

Correspondence: Gwen Sys, Department of Orthopaedic Surgery and Traumatology, Ghent University Hospital, De Pintelaan 185, B-9000 Gent.

E-mail: [Gwen.Sys@ugent.be](mailto:Gwen.Sys@ugent.be)

## ABSTRACT

*Introduction:* Currently there are no accepted international guidelines for the correct placement of reconstruction prostheses in the axial plane of the femur after *en bloc* resection. The most accepted method is based on the linea aspera as an intraoperative landmark, indicating posterior. This study was conducted to address the reliability of the linea aspera as a landmark for rotational alignment.

*Material and methods:* 50 CT angiographies of the right limb were used for this purpose. These 2D images were reconstructed into 3D models using the Mimics software (Materialise NV, Leuven, Belgium). The posterior condylar line was used as a reference axis. The orientation of the linea aspera was described as the angle between the perpendicular line to the PCL, through the center of the diaphysis, and the lateral ( $\alpha$ ) and medial labium ( $\beta$ ).

*Results:* The linear mixed model shows that the  $\alpha$ - and  $\beta$ -angles are significantly associated with the distance from the joint line ( $p < 0.001$ ) and vary significantly between subjects ( $p < 0.001$ ). The  $\alpha$ -angle has the lowest variance and approximates more closely true posterior, while the median  $\beta$ -angle never overlaps true posterior.

*Discussion:* When a surgeon would blindly rely on the linea aspera as a posterior landmark roughly 78% of the femoral implants would exceed the accepted  $\pm 3^\circ$  deviation around the surgical transepicondylar axis (sTEA) as defined in total knee replacement. The linea aspera is not a reliable landmark for axial rotation of femoral implants. The position is highly dependent on the osteotomy height and in addition differs between individual patients. Preoperative assessment of the linea aspera is advocated in order to reduce the risk of malrotation. As the height of the osteotomy cannot always be determined correctly preoperatively, a table was designed as a guideline for how much a deviation from the planned resection height will affect the rotation of the implant.

**Keywords:** Linea aspera; femur; axial alignment; axial rotation; reconstruction prostheses; tumor prostheses.

Enhancing rotational placement of reconstruction prostheses of the distal femur after sarcoma resection.

Arne De Smet<sup>1</sup>, Dries Verrewaere<sup>1</sup>, Gwen Sys

## INTRODUCTION

Bone sarcomas are rare tumors compared to other types of tumors. The most frequent types are osteosarcoma, chondrosarcoma and Ewing sarcoma. Localization of the tumor depends on tumor type, but in general the femur is the most frequently involved bone [1, 2]. Advances in orthopedic surgery, diagnostic techniques, chemotherapy and radiotherapy have led to substantial improvements in survival. Limb salvage techniques using a reconstruction prosthesis after wide resection are now widely accepted. The longer survival of the patients has led to a new concern, i.e. the survival and function of the prosthesis. Mechanical failure, including aseptic loosening (type 2 complication), is one of the main complications of reconstruction prostheses. Recent developments have focused on ameliorating prosthetic fixation to the host bone (e.g. Compress Compliant Pre-stress technology and hydroxyapatite collars), while the introduction of a rotating platform (Fig. 1) has resulted in a substantial reduction of stress at the bone-implant interface [3-7]. However, implant survival is still inferior to conventional total knee prostheses and more research is needed to identify risk factors of mechanical failure to improve implant survival [8-11]. Nevertheless, correct axial placement of the implant is advocated even with the use of rotating platforms. Malrotation of the implant can possibly lead to patellofemoral complications and abnormal biomechanical stress on the hinge mechanism, causing early failure [12-17]. This could also offer an explanation for the increased serum metal ion levels (cobalt and chromium) that are observed in this specific patient population [18, 19]. At our institution, we occasionally encounter patients with rotational malalignment of the implant (Fig. 2).

Currently there are no accepted international guidelines for the correct placement of reconstruction prostheses in the axial plane. The most accepted method is based on the position of the linea aspera as an intraoperative landmark to identify the true posterior aspect of the femur [20]. True posterior can be defined as the perpendicular line, in the horizontal plane, to the femoral cylindrical axis, the axis that connects the centers of the best matching spheres of the femoral condyles. This axis represents the flexion-extension axis of the knee [12, 13, 21-24]. However, recent literature has been questioning the reliability of the linea aspera [25-27].

The linea aspera is the longitudinal crest on the posterior side of the femoral diaphysis and consists of a lateral and a medial labium. Distally, the linea aspera transforms into the lateral and medial supracondylar ridge. Proximally, the lateral labium continues as the gluteal tuberosity, while the medial lip is further divided into the spiral and pectineal line (Fig. 3) [25, 28-30].

In this study, our objective was to investigate the reliability of the linea aspera as a landmark for rotational alignment of reconstruction prostheses at different resection heights, whether it can be blindly trusted as a true posterior landmark of the femur. To address this problem, the position of the linea aspera relative to the posterior side of the femur was determined along the femoral diaphysis.

## MATERIAL AND METHODS (Fig. 4)

This study was performed on 50 CT angiographies of the right limb of 50 persons (31 men and 19 women). All patients were adults and genua vara or valga were not considered as exclusion criteria. All the CT angiographies (Somatom Definition Flash, Siemens, Erlangen, Germany) were performed at the Ghent University Hospital. The CT protocol involved the following settings: 120Kv, 0.6mm slice thickness and slice resolution of 0.69 x 0.69 mm.

From these two-dimensional images, a 3D reconstruction was created using the commercially available Mimics Software (Materialise NV, Leuven, Belgium) [31, 32]. The posterior condylar line (the tangent line to the most posterior part of the femoral condyles with the femur viewed along its mechanical axis) was used as reference axis. True posterior, in this study, was defined as the perpendicular line to the posterior condylar line (PCL), through the center of the diaphysis. The orientation of the linea aspera was described

as the angle between the parallel line to the PCL through the center of the diaphysis, and the lateral ( $\alpha$ ) and medial labium ( $\beta$ ) (Fig. 5). Subsequently the difference to true posterior ( $90^\circ$ ) was calculated.

These angles were determined at 1 cm intervals, starting 10 cm from the most distal point of the femur at the level of the knee joint, up to the height corresponding with 75% of the total length of the femur (distance between most inferior point of the medial condyle and the most superior point on the femoral head). The femora were divided by gender in 2 groups, the anthropometric data as described by Trotter et al. were used to further divide the femoral length into 3 subgroups: short, medium and long. The mean length of a male and female femur is respectively 46.9 and 42.7 cm [33]. An interval of  $\pm 1$  cm was made around these means, representing the medium group. The short and long group had respectively lower and higher values than this interval.

The angles were independently measured once by the two main authors to evaluate the inter-rater agreement.

### Statistics

SPSS statistics 25 [34] is used for statistical analysis. The  $\alpha$ - and  $\beta$ -angles are depicted with box and whisker plots in order to describe the course of the linea aspera relative to the distance to the most inferior point, both the absolute distance and the relative distance. The relative distance is calculated from the absolute distance as a percentage of the total length of the femur. This accommodates for differences in femoral size between patients.

To evaluate the reliability of the linea aspera as a rotational landmark, linear mixed modelling is used. The model consists of two levels: the first level examines the  $\alpha$ - and  $\beta$ -angles within one subject. The second level examines the  $\alpha$ - and the  $\beta$ -angles between subjects. The  $\alpha$ - and  $\beta$ -angles are dependent variables, the absolute distance from the distal point is an independent variable. The size of the femur and the gender of the subjects are predictors.

The reproducibility of the methodology in this study is assessed by terms of inter-rater agreement. This is preferred to reliability as agreement addresses the measurement error, a characteristic to the measurement method itself. Contrary, the reliability reflects the variability in a certain population sample and is not a criterion of the measurement error [35].

### RESULTS

Fig. 6 represents the box and whiskers plots of the  $\alpha$ - and  $\beta$ -angles to display the variance between the subjects relative to the distance from the most inferior point. The X-axis demonstrates the relative distance in intervals of 2.5%. Within the subjects, the orientation is strongly dependent on the relative distance from the inferior point as demonstrated by the progression along the X-axis. The median is nowhere perfectly posterior. The  $\alpha$ -angle has the lowest variance and more closely approximates true posterior, but the median  $\alpha$ -angle never reaches perfect posterior. The size of the box and whiskers plots demonstrates the high variance between the subjects. At the level of the middle of the total femoral length, the variance between subjects is the lowest, while the linea aspera very closely approximates true posterior.

The linear mixed model shows that the  $\alpha$ - and  $\beta$ -angles were significantly associated with the distance from the most inferior point ( $p < 0.001$ ) and varied significantly between subjects ( $p < 0.001$ ). The length of the femur has a significant influence on the  $\alpha$ - and  $\beta$ -angle. The proportional variance shows to what extent each level determines the variance. For the orientation of the lateral labium, 78.3% of the total variance is determined by the variance within the femora and 21.7% by the variance between femora. The variance determined by the absolute distance is 70.3% of the total variance within a femur. For the medial labium, these values are respectively 69.8%, 30.2% and 41.6%.

According to this model, a parabolic equation can be generated for the lateral and medial labium, where the x-factor represents the absolute height. The predictors gender and size of the femora can be added to this equation resulting in six different equations. Graphic representation of these equations is demonstrated in fig. 7. In table 1, the different factors (a, b, c) of the parabolic equation can be found.

$$\alpha \text{ or } \beta - \text{angle} = aX^2 + bX + c$$

Based on the equations above, tables can be generated for the course of the lateral and medial labium of the linea aspera according to the height. Based on these tables, the angulation error can be predicted if the height of the osteotomy is performed one centimeter above or underneath the target height (in Table 2 only the lateral labium is displayed). When these tables are plotted, all curves have a parabolic course, demonstrating the minimal error at the mid-diaphyseal level of the femur. Short femora achieve this point at a lower absolute height. At the proximal end of the femur, the deviation from true posterior is more pronounced, especially for the lateral labium. We could not find a significant difference for gender.

Of all (1192) measured  $\alpha$ -angles, only 25.2% (300/1192) were located around a  $\pm 3^\circ$  interval of 'true posterior, as defined in this study, and only 21.6% (258/1192) around a  $\pm 3^\circ$  interval of the surgical transepicondylar axis (sTEA) (derived as  $3^\circ$  more externally rotated relative to the PCL [12]). Around the middiaphysis these values are 38% (171/450) and 37.7% (168/450).

The reproducibility of the methodology in this study was assessed by means of inter-rater agreement. Table 3 shows the agreement between the two observers. The mean difference is  $-0.634^\circ$  (SD  $2.24^\circ$ ) for the lateral labium and  $-0.5^\circ$  (SD  $3.3^\circ$ ) for the medial labium. The difference between the two observers is less than  $3^\circ$  in 79.5% of all measured  $\alpha$ -angles and less than  $5^\circ$  in 99.2% of all measured  $\alpha$ -angles. For the  $\beta$ -angle the percentages are respectively 70.1% and 94.1%. In the middle of the diaphysis the inter-rater agreement is higher compared to proximal or distal on the femur.

## DISCUSSION:

While performing reconstruction surgery of the distal femur after excision of a sarcoma, the surgeon has only the linea aspera as bony landmark to guide the axial rotation of the femoral implant. However, this research demonstrates that in fact, the linea aspera is not a reliable landmark as its orientation is highly dependent on the height of the osteotomy as well as on the patient. When a surgeon would blindly rely on the linea aspera as a posterior landmark, the rotational placement of roughly 78% of the femoral implants would exceed the accepted  $\pm 3^\circ$  around the sTEA as defined in total knee replacement [22, 36, 37].

The implant would be placed in exorotation if the linea aspera runs medially to true posterior and in endorotation if the linea aspera runs laterally to true posterior.

This finding is in accordance to other studies concerning the linea aspera. Tuy et al. concluded that the linea aspera does not run true posterior. They found that the linea aspera deviates on average  $6.9^\circ$  laterally at the distal femur,  $2.2^\circ$  medially at the midshaft and  $6.9^\circ$  laterally at the proximal third [27]. Also, Reple et al. and Abdelaal et al. concluded that preoperatively the orientation of the linea aspera should be assessed in order to avoid a malrotation of the femoral component [25, 26]. Although they all used the PCL as a reference, they used a different methodology in measuring the orientation and deviation of the linea aspera.

This research was the first to evaluate the medial and lateral labium as separate entities, whereas previous research evaluated the linea aspera as one entity. Furthermore, we studied the linea aspera over its entire course, whilst Tuy et al. and Abdelaal et al. only investigated resp. 3 and 4 different levels. This is an important distinction from previous studies considering the course of the linea aspera is highly dependent on the height of the osteotomy, as was proved by this study. Furthermore, this gives a more detailed assessment of the course of the linea aspera, which helps preoperative planning.

A surgeon should at least evaluate the orientation of the linea aspera at the intended resection height during the preoperative planning and anticipate how some deviation from the intended resection height will affect the rotation. The lateral labium is the preferred bony landmark as it is easier detectable on CT and during surgery. In addition, the lateral labium is less variable and is located closer to true posterior than the medial labium.

The strength of current study is its clinical applicability, as due to impaired visibility caused by the volume of the tumor, the performed osteotomy height may deviate from the intended osteotomy height, usually within the boundaries of 1cm below or above the intended osteotomy height. As the orientation of the linea aspera is strongly affected by resection height, this deviation from the preoperative plan would also affect the rotational positioning of the implant. As defining the position of the linea aspera by the surgeon

at all probable resection heights during the preoperative planning is impractical, we have constructed a table (table 2) as a guideline for how much this deviation in height will affect the rotation of the implant. Around the midshaft of the femur, the angulation error will be the smallest. Practically, if a surgeon needs to perform an osteotomy to excise a tumor, he needs to measure the  $\alpha$ -angle at the desired osteotomy level, during preoperative planning, and adapt his rotation depending on the difference with true posterior. After the osteotomy has been performed the surgeon verifies the resection specimen for measurements errors. If a measurement error has been made, table 2 can be used to correct axial alignment. The first column indicates the intended osteotomy height and the second column the actual performed osteotomy height. The surgeon can then find, according to sex and length of the patient's femur, the angulation error. If this value is positive, extra exorotation needs to be built in and endorotation for a negative value.

We could not find any reports on the incidence and clinical consequence of femoral malrotation when using tumor reconstruction prostheses. It may be stated that the use of rotating tibial platforms may offer higher tolerance for rotational errors of the femoral component. However, at our institute we occasionally encounter patients with rotational deviations during flexion and patellar problems possibly caused by malrotation of the femoral component, as reported in total knee arthroplasty [12-16].

This study has several limitations. First, the PCL was employed as a reference axis, while there is growing consensus that the sTEA is the preferred axis for rotational alignment, because it's the best intra-operatively representation of the flexion-extension axis of the knee [12, 21, 36, 38]. However, the sTEA is more subject to interobserver variability [12, 36]. In addition, the epicondyles and the medial sulcus are frequently deformed or destroyed by the neoplastic process and will therefore not be available as a landmark in tumor surgery. Secondly, the methodology used in this study has, to our knowledge, never been used before and is therefore not yet validated. However, the inter-rater agreement was high: 79.5% of all measured  $\alpha$ -angles differed less than 3° between observers, making this method suitable for preoperative planning.

## CONCLUSION

The linea aspera is not a reliable landmark for defining the axial rotation of femoral implants in reconstruction prostheses after tumor resection. The angulation compared to the true posterior position is highly dependent on the osteotomy height and in addition differs between patients. Preoperative planning is advocated in order to reduce the chance of any malrotation of the implant. A deviation of the intended osteotomy height from the planned height, due to impaired visibility due to tumor volume, will cause an angulation error, which can be corrected using our table after measuring the height of the resection piece.

Further research is needed to understand the consequences of femoral malrotation in tumor reconstruction prostheses and to find alternatives to improve the axial placement of these implants, such as patient specific instruments.

**Competing interests:** None declared

**Funding:** None

**Ethical approval:** Not required

**Acknowledgements:** Assistance provided by Stefanie De Buyser for the statistical analysis was greatly appreciated.



## REFERENCES

- [1. *Kanker.be. (2018). Botkanker | Stichting tegen Kanker. [online] Available at: <https://www.kanker.be/alles-over-kanker/alle-types-kanker/botkanker> [Accessed 17 Apr. 2018].*
2. Valery, P.C., M. Laversanne, and F. Bray, *Bone cancer incidence by morphological subtype: a global assessment*. *Cancer Causes Control*, 2015. **26**(8): p. 1127-39.
3. Bhangu, A.A., et al., *Early distal femoral endoprosthesis survival: cemented stems versus the Compress implant*. *Int Orthop*, 2006. **30**(6): p. 465-72.
4. Kramer, M.J., et al., *Compressive osseointegration promotes viable bone at the endoprosthesis interface: retrieval study of Compress implants*. *Int Orthop*, 2008. **32**(5): p. 567-71.
5. Bini, S.A., J.O. Johnston, and D.L. Martin, *Compliant prestress fixation in tumor prostheses: interface retrieval data*. *Orthopedics*, 2000. **23**(7): p. 707-11; discussion 711-2.
6. Myers, G.J., et al., *Endoprosthesis replacement of the distal femur for bone tumours: long-term results*. *J Bone Joint Surg Br*, 2007. **89**(4): p. 521-6.
7. Pedtke, A.C., et al., *Aseptic failure: how does the Compress((R)) implant compare to cemented stems? Clinical orthopaedics and related research*, 2012. **470**(3): p. 735-42.
8. Schwartz, A.J., et al., *Cemented distal femoral endoprosthesis for musculoskeletal tumor: improved survival of modular versus custom implants*. *Clin Orthop Relat Res*, 2010. **468**(8): p. 2198-210.
9. Biau, D., et al., *Survival of total knee replacement with a megaprosthesis after bone tumor resection*. *J Bone Joint Surg Am*, 2006. **88**(6): p. 1285-93.
10. Sharma, S., et al., *Cemented rotating hinge endoprosthesis for limb salvage of distal femur tumors*. *Clin Orthop Relat Res*, 2006. **450**: p. 28-32.
11. Pesenti, S., et al., *Knee function after limb salvage surgery for malignant bone tumor: comparison of megaprosthesis and distal femur allograft with epiphysis sparing*. *Int Orthop*, 2018. **42**(2): p. 427-436.
12. Victor, J., *Rotational alignment of the distal femur: a literature review*. *Orthop Traumatol Surg Res*, 2009. **95**(5): p. 365-72.
13. Maderbacher, G., et al., *Impact of Axial Component Alignment in Total Knee Arthroplasty on Lower Limb Rotational Alignment: An In Vitro Study*. *J Knee Surg*, 2017. **30**(4): p. 372-377.
14. Kawahara, S., et al., *Internal rotation of femoral component affects functional activities after TKA--survey with the 2011 Knee Society Score*. *J Arthroplasty*, 2014. **29**(12): p. 2319-23.
15. Thompson, J.A., et al., *Biomechanical effects of total knee arthroplasty component malrotation: a computational simulation*. *J Orthop Res*, 2011. **29**(7): p. 969-75.
16. Victor, J., et al., *A common reference frame for describing rotation of the distal femur: a ct-based kinematic study using cadavers*. *J Bone Joint Surg Br*, 2009. **91**(5): p. 683-90.
17. Kelly, M.A., *Patellofemoral complications following total knee arthroplasty*. *Instructional course lectures*, 2001. **50**: p. 403-7.
18. Friesenbichler, J., et al., *Serum metal ion concentrations in paediatric patients following total knee arthroplasty using megaprotheses*. *Biomed Res Int*, 2014. **2014**: p. 817257.

19. Friesenbichler, J., et al., *Serum metal ion levels after rotating-hinge knee arthroplasty: comparison between a standard device and a megaprosthesis*. *Int Orthop*, 2012. **36**(3): p. 539-44.
20. Malawer, M.M., *Distal femoral resection with endoprosthetic reconstruction*, in *Musculoskeletal cancer surgery: Treatment of sarcomas and allied diseases*, P.H.S. Martin M Malawer, Editor. 2001, Kluwer Academic Publishers: The Netherlands.
21. Hamada, D., et al., *The Posterior Condylar Cartilage Affects Rotational Alignment of the Femoral Component in Varus Knee Osteoarthritis*. *J Med Invest*, 2017. **64**(1.2): p. 24-29.
22. Lee, J.K., et al., *Rotational alignment of femoral component with different methods in total knee arthroplasty: a randomized, controlled trial*. *BMC Musculoskelet Disord*, 2017. **18**(1): p. 217.
23. Churchill, D.L., et al., *The transepicondylar axis approximates the optimal flexion axis of the knee*. *Clinical orthopaedics and related research*, 1998(356): p. 111-8.
24. Yin, L., et al., *Identifying the Functional Flexion-extension Axis of the Knee: An In-Vivo Kinematics Study*. *PLoS one*, 2015. **10**(6): p. e0128877.
25. Abdelaal, A.H., et al., *The linea aspera as a guide for femoral rotation after tumor resection: is it directly posterior? A technical note*. *J Orthop Traumatol*, 2016. **17**(3): p. 255-9.
26. Reple, G., et al., *The linea aspera as a rotational landmark: an anatomical MRI-based study*. *Surg Radiol Anat*, 2016. **38**(9): p. 1069-1074.
27. Tuy, B.E., et al., *Linea Aspera as Rotational Landmark for Tumor Endoprostheses: A Computed Tomography Study*. *Am J Orthop (Belle Mead NJ)*, 2016. **45**(4): p. E198-203.
28. Pitt, M.J., *Radiology of the femoral linea aspera-pilaster complex: the track sign*. *Radiology*, 1982. **142**(1): p. 66.
29. Polguy, M., et al., *Morphological study of linea aspera variations - proposal of classification and sexual dimorphism*. *Folia morphologica*, 2013. **72**(1): p. 72-7.
30. Gheorghiu, D. and A. Leinenkugel, *The linea aspera-pilaster complex as a possible cause of confusion with the 'flame sign': a case report*. *Acta orthopaedica et traumatologica turcica*, 2010. **44**(3): p. 254-6.
31. *Information on Mimics Materialise [Internet] 2016 [cited on the 15th of february 2016]*. <http://biomedical.materialise.com/mimics>.
32. *Information on 3Matic Materialise [Internet] 2016 [cited on the 15th of february 2016]*. <http://biomedical.materialise.com/3-matic-0>.
33. Trotter, M. and G.C. Gleser, *Estimation of stature from long bones of American Whites and Negroes*. *American journal of physical anthropology*, 1952. **10**(4): p. 463-514.
34. *IBM Corp. Released 2017. IBM SPSS Statistics for Windows, Version 25.0. Armonk, NY: IBM Corp.*
35. de Vet, H.C.W., et al., *When to use agreement versus reliability measures*. *Journal of Clinical Epidemiology*, 2006. **59**(10): p. 1033-1039.
36. Victor, J., et al., *How precise can bony landmarks be determined on a CT scan of the knee?* *Knee*, 2009. **16**(5): p. 358-65.
37. Manjunath, K.S., K.G. Gopalakrishna, and G. Vineeth, *Evaluation of alignment in total knee arthroplasty: a prospective study*. *European journal of orthopaedic surgery & traumatology : orthopedie traumatologie*, 2015. **25**(5): p. 895-903.

38. Aunan, E., et al., *A simple method for accurate rotational positioning of the femoral component in total knee arthroplasty*. Acta Orthop, 2017. **88**(6): p. 657-663.

Journal Pre-proof

**Table 1**

The linear mixed model. Factors of the parabolic equation ( $Y = ax^2+bx+c$ ) for the medial and lateral labium after adding the predictors length and gender of the femur.

	Lateral Labium						Medial Labium					
	Short femora		Medium femora		Long femora		Short femora		Medium femora		Long femora	
	♂	♀	♂	♀	♂	♀	♂	♀	♂	♀	♂	♀
a	-0.14	-0.16	-0.13	-0.15	-0.11	-0.18	-0.22	-0.21	-0.16	-0.21	-0.14	-0.18
b	0.55	-0.23	0.80	0.23	0.9	0.53	-0.48	-1.81	-0.17	-1.17	0.01	-0.03
c	90.29	92.32	91.38	94.46	93.6	95.55	73.27	69.93	73.2	69.92	66.96	71.05

Journal Pre-proof

**Table 2.**

This table can be used as a guide for how much a measurement error in height determination (cm) will affect the angulation error ( $^{\circ}$ ), when using the lateral labium as reference.


Intended osteotomy level	Performed osteotomy level	Men			Women		
		Short	Medium	Long	Short	Medium	Long
11	10	3,7	3,8	3,5	3,5	3,9	4,8
	12	-3,4	-3,5	-3,2	-3,2	-3,5	-4,4
12	11	3,4	3,5	3,2	3,2	3,5	4,4
	13	-3,1	-3,3	-3,0	-2,9	-3,2	-4,0
13	12	3,1	3,3	3,0	2,9	3,2	4,0
	14	-2,9	-3,0	-2,8	-2,5	-2,9	-3,7
14	13	2,9	3,0	2,8	2,5	2,9	3,7
	15	-2,6	-2,8	-2,6	-2,2	-2,6	-3,3
15	14	2,6	2,8	2,6	2,2	2,6	3,3
	16	-2,3	-2,5	-2,3	-1,9	-2,3	-2,9
16	15	2,3	2,5	2,3	1,9	2,3	2,9
	17	-2,1	-2,2	-2,1	-1,6	-2,0	-2,6
17	16	2,1	2,2	2,1	1,6	2,0	2,6
	18	-1,8	-2,0	-1,9	-1,2	-1,6	-2,2
18	17	1,8	2,0	1,9	1,2	1,6	2,2
	19	-1,5	-1,7	-1,7	-0,9	-1,3	-1,8
19	18	1,5	1,7	1,7	0,9	1,3	1,8
	20	-1,2	-1,5	-1,5	-0,6	-1,0	-1,5
20	19	1,2	1,5	1,5	0,6	1,0	1,5
	21	-1,0	-1,2	-1,2	-0,3	-0,7	-1,1
21	20	1,0	1,2	1,2	0,3	0,7	1,1
	22	-0,7	-0,9	-1,0	0,1	-0,4	-0,7
22	21	0,7	0,9	1,0	-0,1	0,4	0,7
	23	-0,4	-0,7	-0,8	0,4	-0,1	-0,3
23	22	0,4	0,7	0,8	-0,4	0,1	0,3
	24	-0,1	-0,4	-0,6	0,7	0,2	0,0
24	23	0,1	0,4	0,6	-0,7	-0,2	0,0
	25	0,1	-0,1	-0,3	1,0	0,6	0,4
25	24	-0,1	0,1	0,3	-1,0	-0,6	-0,4
	26	0,4	0,1	-0,1	1,4	0,9	0,8
26	25	-0,4	-0,1	0,1	-1,4	-0,9	-0,8
	27	0,7	0,4	0,1	1,7	1,2	1,1
27	26	-0,7	-0,4	-0,1	-1,7	-1,2	-1,1
	28	1,0	0,6	0,3	2,0	1,5	1,5
28	27	-1,0	-0,6	-0,3	-2,0	-1,5	-1,5
	29	1,2	0,9	0,5	2,3	1,8	1,9
29	28	-1,2	-0,9	-0,5	-2,3	-1,8	-1,9
	30	1,5	1,2	0,8	2,7	2,1	2,2
30	29	-1,5	-1,2	-0,8	-2,7	-2,1	-2,2
	31	1,8	1,4	1,0	3,0	2,5	2,6
31	30	-1,8	-1,4	-1,0	-3,0	-2,5	-2,6
	32	2,0	1,7	1,2	3,3	2,8	3,0
32	31	-2,0	-1,7	-1,2	-3,3	-2,8	-3,0
	33	2,3	1,9	1,4	3,6	3,1	3,3
33	32	-2,3	-1,9	-1,4	-3,6	-3,1	-3,3
	34	2,6	2,2	1,7	4,0	3,4	3,7
34	33	-2,6	-2,2	-1,7	-4,0	-3,4	-3,7
	35	2,9	2,5	1,9	4,3	3,7	4,1
35	34	-2,9	-2,5	-1,9	-4,3	-3,7	-4,1
	36	3,1	2,7	2,1	4,6	4,0	4,5

**Table 3**

Reproducibility of the methodology.

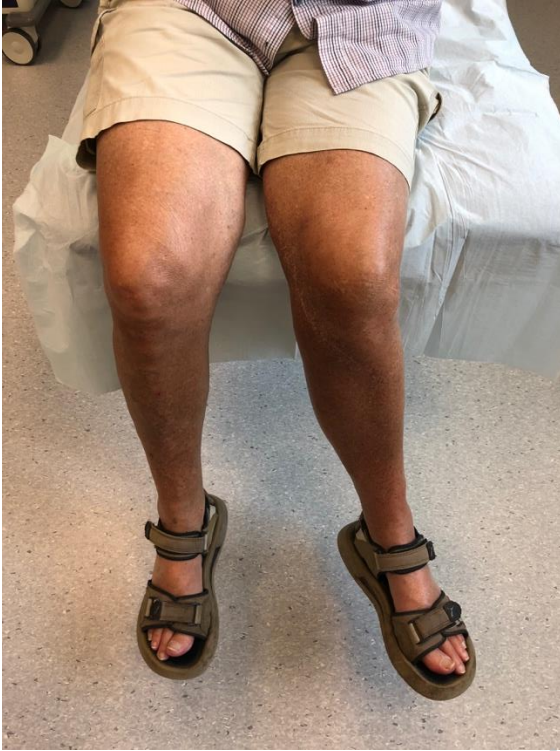	PCL' – lateral labium	PCL' – medial labium
Observer 1: mean (SD) (°)	85,9 (9,1)	63,4 (10,9)
Observer 2: mean (SD) (°)	85,3 (9,3)	62,9 (10,8)
Mean difference between O1 and O2 (SD)	-0,634 (2,24)	-0,5 (3,3)
O1 vs. O2: % in 1°	32	29
- Distal	29,6	26,4
- Middiaphysis	34,9	31,8
- Proximal	31,5	28,8
O1 vs. O2: % in 3°	79,5	70,1
- Distal	79,1	64,4
- Middiaphysis	83,1	76,7
- Proximal	74,7	68,5
O1 vs. O2: % in 5°	99,2	94,1
- Distal	99,6	87,8
- Middiaphysis	99,6	99,3
- Proximal	97,9	95,9
ICC <sub>agreement</sub> (%)	98,4	97,6
ICC <sub>consistency</sub> (%)	98,5	97,6

O1 = observer 1, O2 = observer 2. ICC = intraclass correlation coefficient.

**Fig. 1.** Rotating hinged knee.

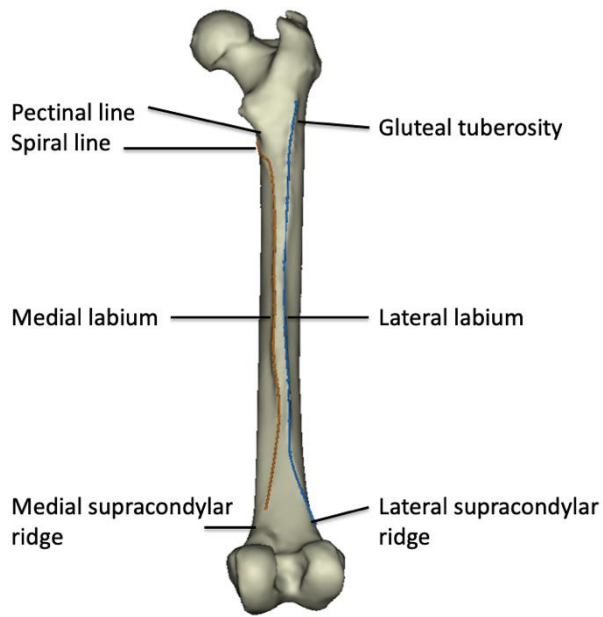
The prosthesis functions via an axle and yoke construct. The axle connects the femoral component to the yoke, which can rotate in the tibial bearing. An anti-rotation stop in the tibial bearing provides a range of motion of +/- 20 degrees of internal and external rotation. Polyethylene bushings prevent direct metal-on-metal contact. (Reprinted with permission from Zimmer Biomet, Inc.).

**Fig. 2.** Clinical example. A patient presenting with rotational malalignment of the left knee despite the presence of a rotating platform. Femoral component of the reconstruction prosthesis was placed too much in endorotation.



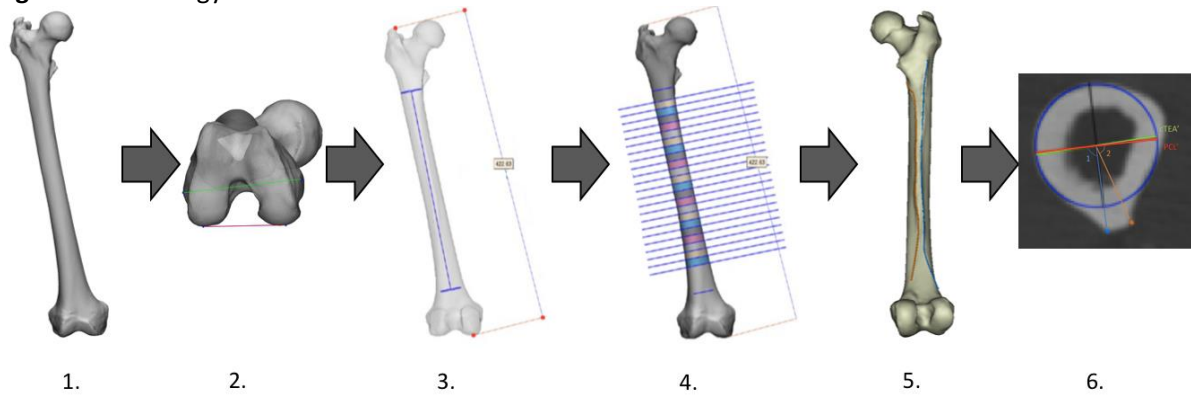
Journal Pre-proof



**Fig.3.** Linea aspera

Posterior view on the femur. The orange line represents the medial labium of the linea aspera. The blue line represents the lateral labium.

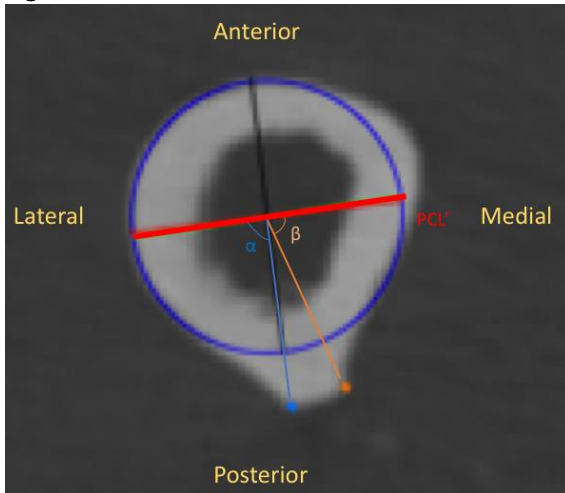
Journal Pre-proof

**Fig. 4.** methodology**Methodology:**

- 1: 50 CT angiographies were used to reconstruct 50 femora.
- 2: the posterior condylar line was marked as the reference line
- 3: the axis and the length of the femur were defined.
- 4: Starting 10 cm proximal of the most distal point of the femur, a plane was defined every centimeter until 75% of the length of the femur was reached.
- 5: the lateral labium and medial labium were marked on every femur.
- 6: Orientation of the lateral ( $\alpha$ ) and medial labium ( $\beta$ ) of the linea aspera regarding the PCL' were defined.

Journal Pre-proof

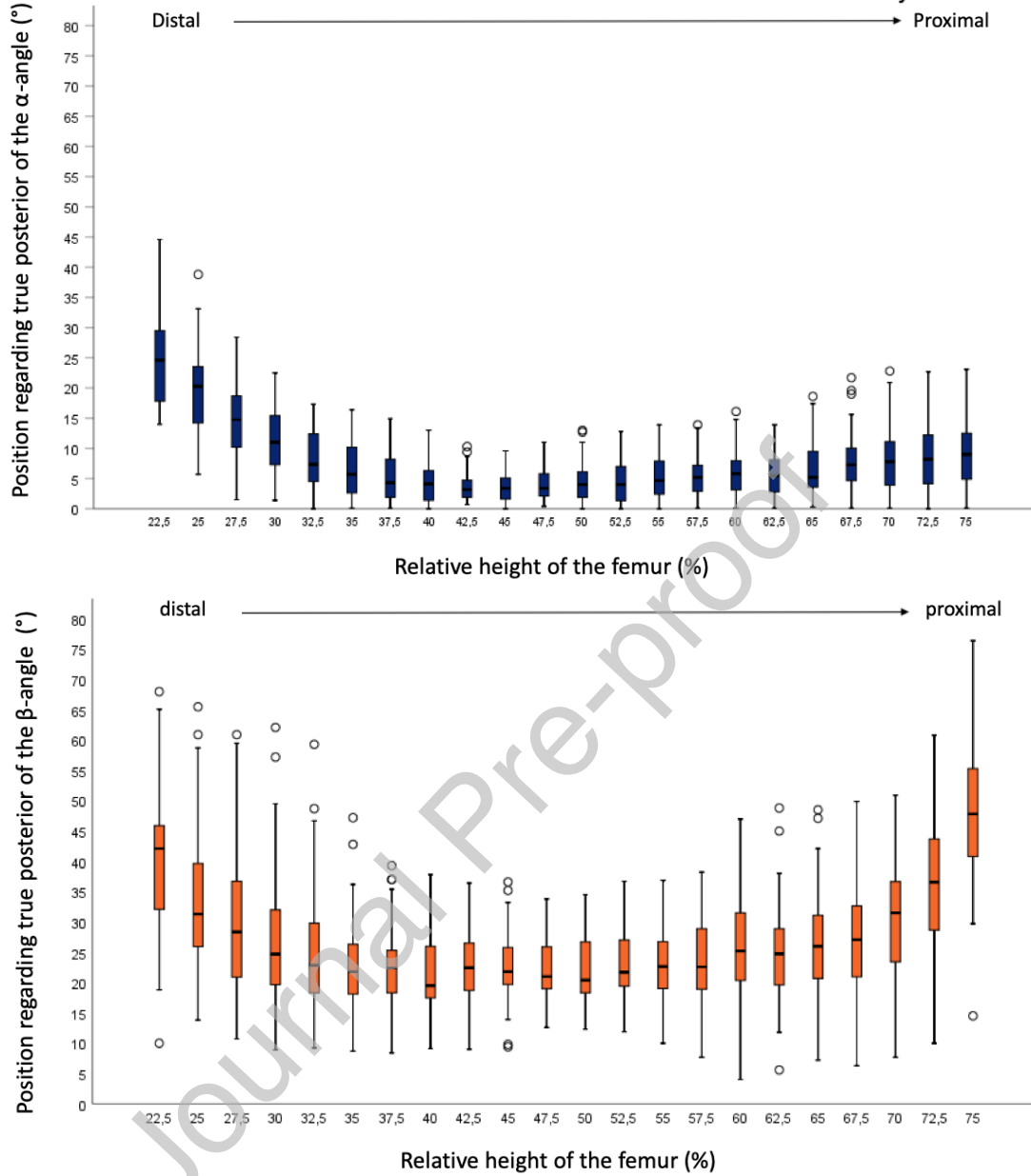
Fig. 5.



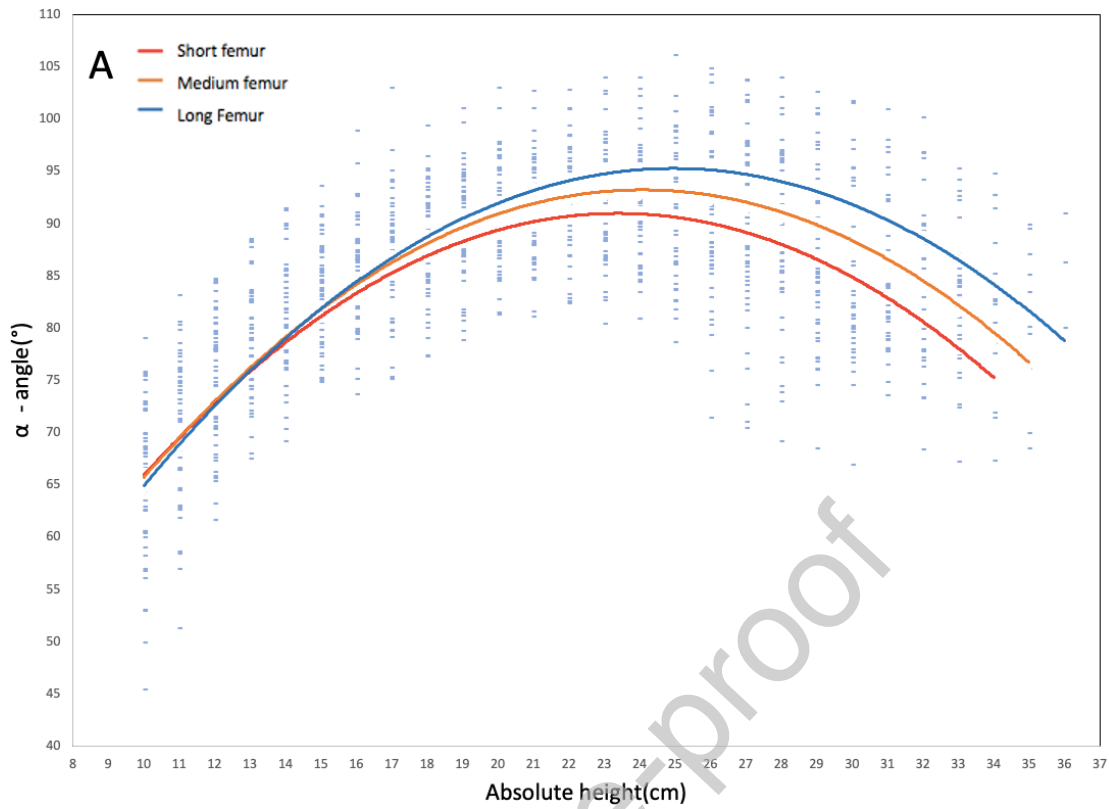
Orientation of the lateral ( $\alpha$ ) and medial labium ( $\beta$ ) of the linea aspera regarding the PCL'. Blue circle: best fitting circle in the diaphysis of the femur. Red line = PCL', a parallel line to the PCL, through the center of the diaphysis. Black line = line perpendicular relative to PCL', indicating the anteroposterior line of the femur. Blue line =  $\alpha$ -angle, the angle between the lateral labium and the PCL'. Orange line =  $\beta$ -angle, the angle between the medial labium and the PCL'.

Journal Pre-proof

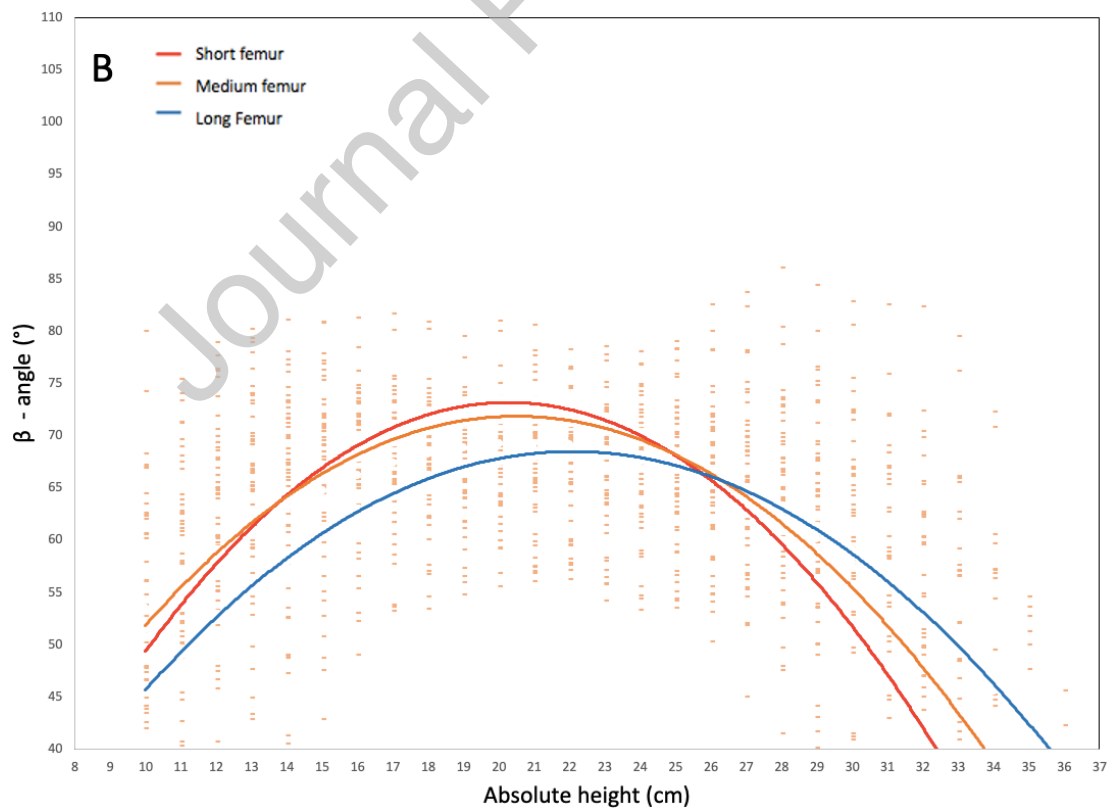
**Fig. 6.** box and whiskers plots of the  $\alpha$ - (blue) and  $\beta$ -angle (orange). The x-axis represents the relative height of the femur, starting from the most inferior point of the medial condyle. This length is divided in intervals of 2.5%. The y-axis represents the deviation ( $^{\circ}$ ) from true posterior,  $0^{\circ}$  indicates true posterior.



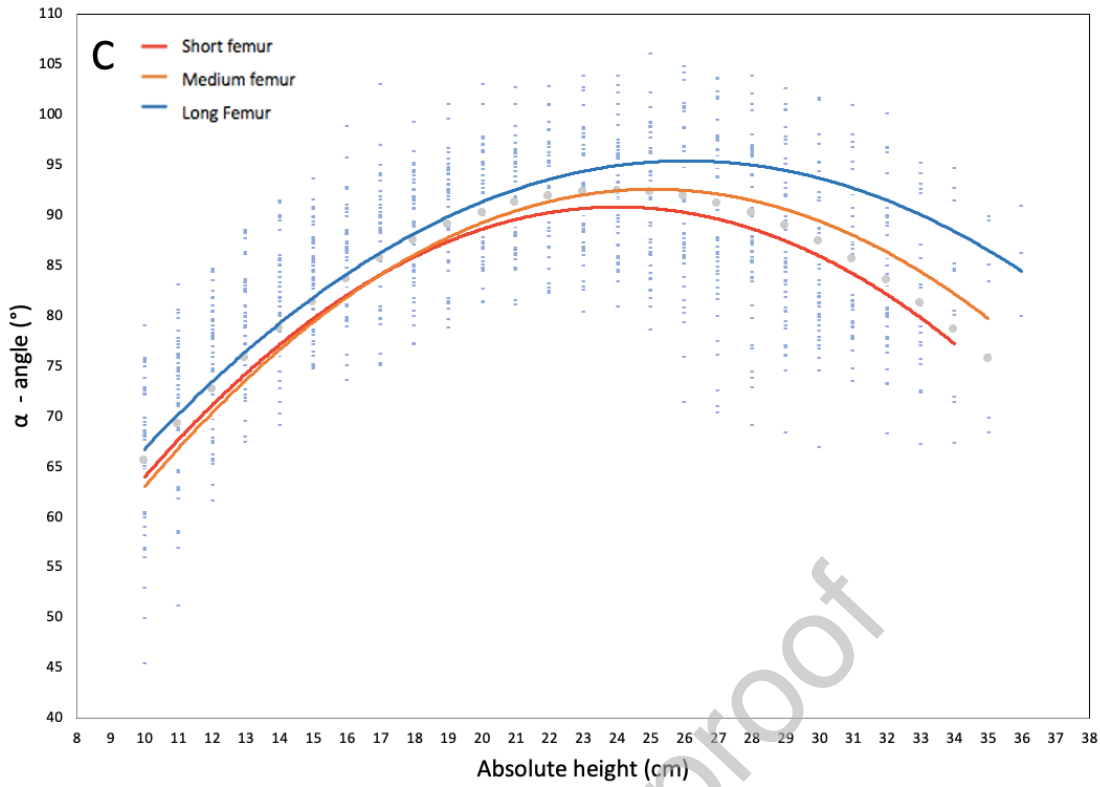
**Fig. 7.** The linear mixed model presented as graphics.



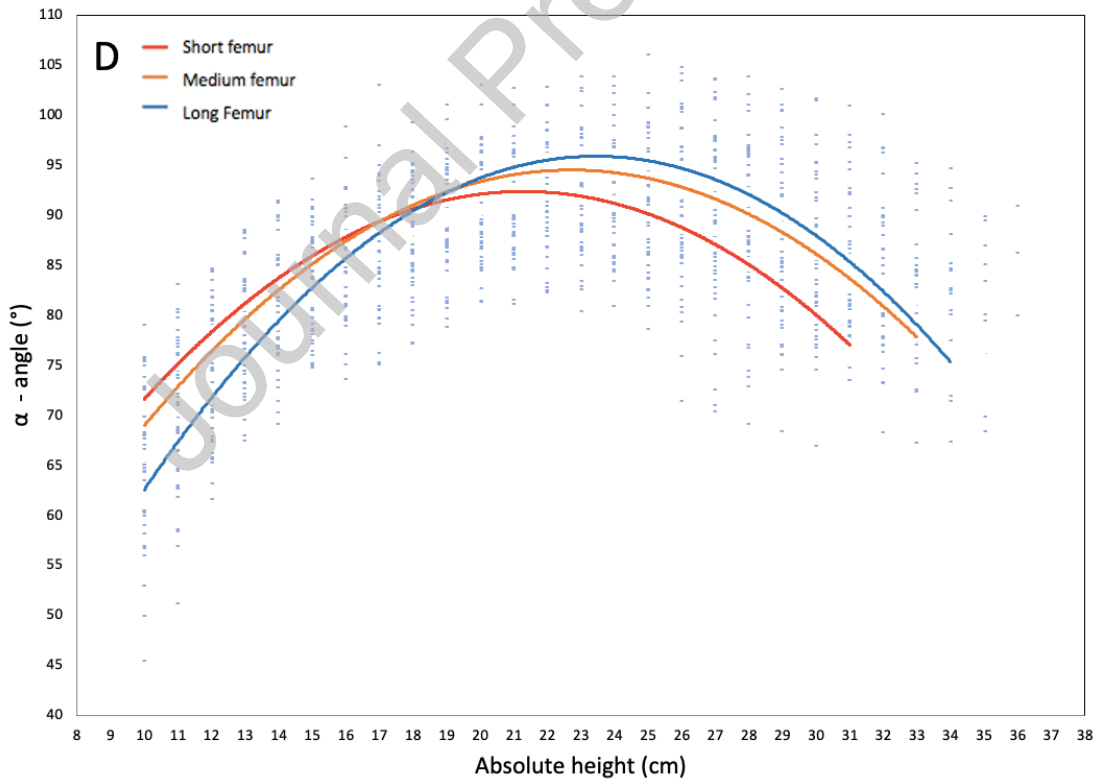
*A: the course of the lateral labium after adding the predictor 'length of the femur'.*



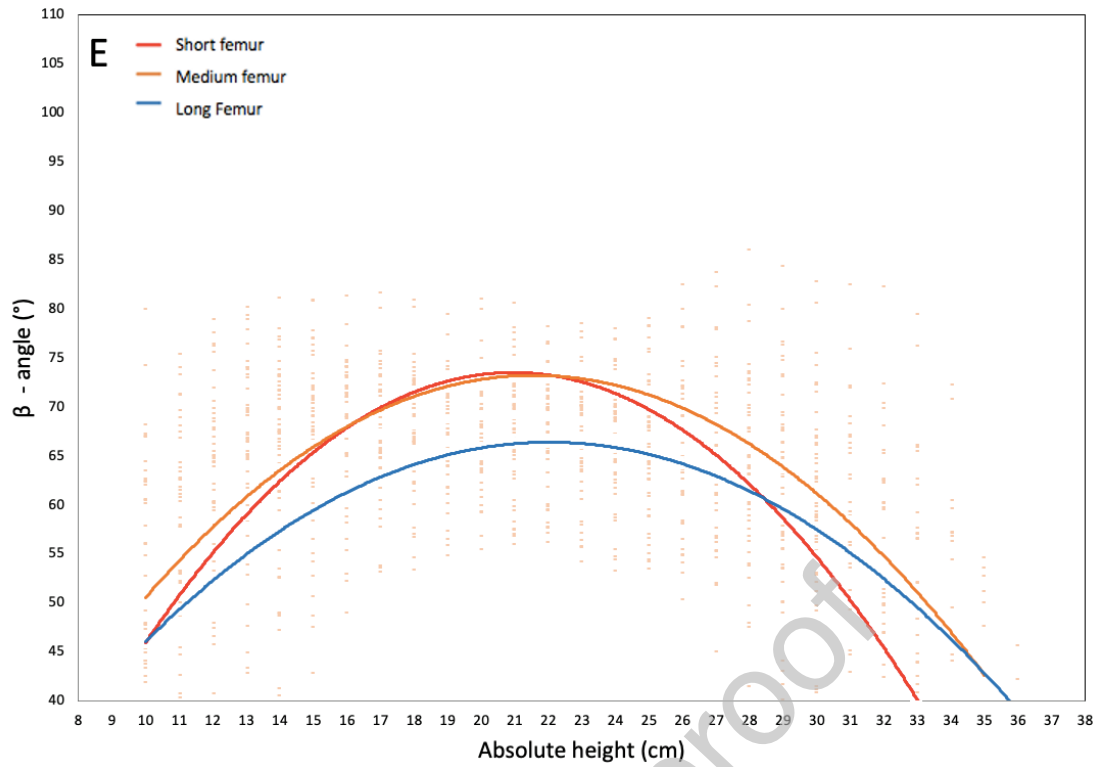
*B: the course of the medial labium after adding the predictor 'length of the femur'.*



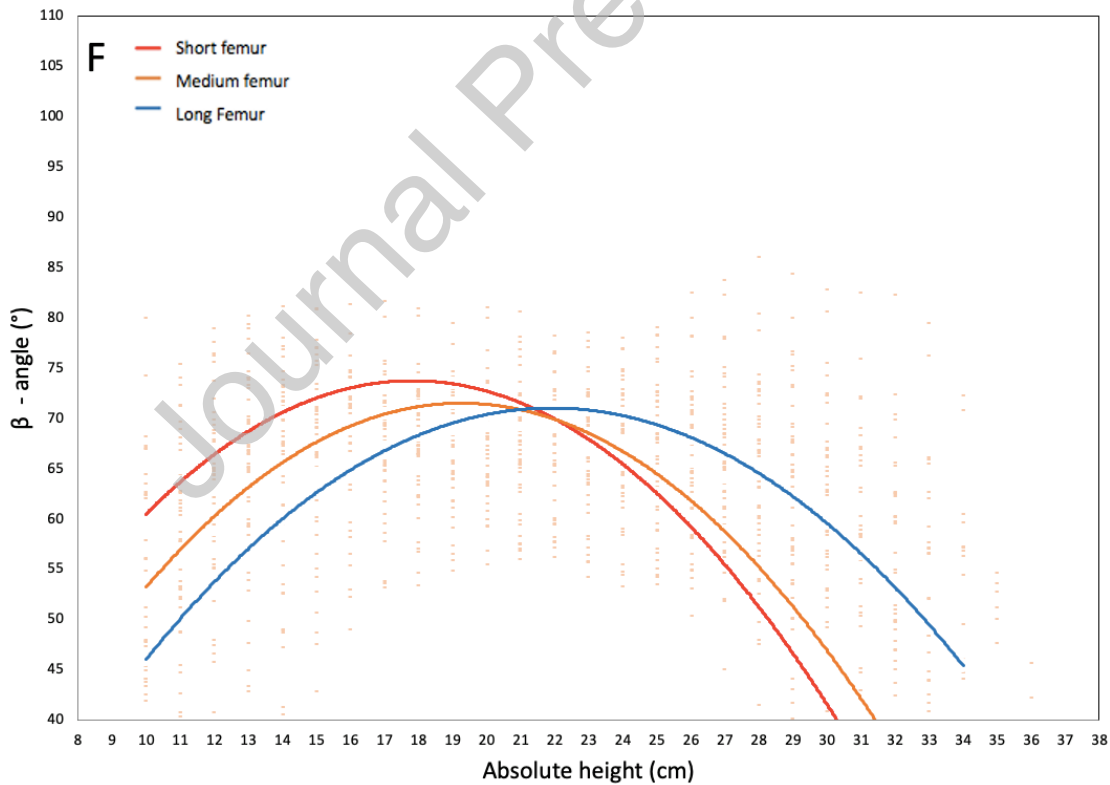
C: the course of the lateral labium after adding the predictors 'length of the femur' and 'gender (men)'.



D: the course of the lateral labium after adding the predictors 'length of the femur' and 'gender (women)'.



E: the course of the medial labium after adding the predictors 'length of the femur' and 'gender (men)'.



F: the course of the medial labium after adding the predictors 'length of the femur' and 'gender (women)'.