

University of Massachusetts Medical School

eScholarship@UMMS

Open Access Articles

Open Access Publications by UMMS Authors

2020-04-16

Medialized Total Ossicular Replacement Prosthesis

Marc D. Polanik

University of Massachusetts Medical School

Et al.

Let us know how access to this document benefits you.

Follow this and additional works at: <https://escholarship.umassmed.edu/oapubs>



Part of the [Equipment and Supplies Commons](#), [Otolaryngology Commons](#), and the [Otorhinolaryngologic Diseases Commons](#)

Repository Citation

Polanik MD, Remenschneider AK. (2020). Medialized Total Ossicular Replacement Prosthesis. Open Access Articles. <https://doi.org/10.1177/2473974X20916432>. Retrieved from <https://escholarship.umassmed.edu/oapubs/4225>

Creative Commons License




This work is licensed under a [Creative Commons Attribution-NonCommercial 4.0 License](#)

This material is brought to you by eScholarship@UMMS. It has been accepted for inclusion in Open Access Articles by an authorized administrator of eScholarship@UMMS. For more information, please contact Lisa.Palmer@umassmed.edu.

Medialized Total Ossicular Replacement Prosthesis

Marc D. Polanik^{1,2,3}, and Aaron K. Remenschneider, MD, MPH^{1,2,3,4}

OTO Open
 2020, Vol. 4(2) 1–3
 © The Authors 2020
 Article reuse guidelines:
sagepub.com/journals-permissions
 DOI: 10.1177/2473974X20916432
<http://oto-open.org>


Keywords

stapedotomy, ossiculoplasty, total ossicular replacement prosthesis, hearing loss, conductive hearing loss, temporal bone imaging, treatment outcome

Received February 9, 2020; accepted March 10, 2020.

Introduction

Vestibular complaints secondary to a deeply medialized ossicular prosthesis have been documented following stapedotomy¹ but infrequently reported following total ossicular replacement prosthesis (TORP) placement. Lateral TORP displacement through the tympanic membrane (TM) occurs in 5% to 9% of cases²; however, medial displacement, with violation of the footplate, is rare and has only been reported following canal wall down mastoidectomy.³ For the below case, institutional review board approval was obtained from the University of Massachusetts Medical School Human Subjects Committee.

Case Report

A 58-year-old woman with chronic right-sided middle ear infections and conductive hearing loss was referred for persistent sensations of right-sided aural fullness, pressure, and otalgia following multiple middle ear reconstructive procedures dating to 15 years prior. Surgical history included intact canal wall mastoidectomy, ossiculoplasty using a 7.0-mm-length calvarial bone strut TORP from the malleus to stapes footplate, and cartilage-backed tympanoplasty. The majority of the patient's current symptoms appeared following the aforementioned ossiculoplasty, which also rendered her significantly vertiginous for a 2- to 3-week period before self-resolving. At the time of presentation, the patient endorsed disequilibrium but denied otorrhea or fluctuations in hearing. Antibiotics and steroids had provided minimal symptomatic relief. The patient benefited from ipsilateral amplification for right-sided conductive hearing loss. There was no history of recent otitis media, serous effusion, positional vertigo, or neurological disorders.

On exam, the right external auditory canal was normal and the TM was thickened at the location of the cartilage

graft. There was no evidence of effusion. Examination of the left ear was normal. Tuning fork exam lateralized to the right with bone greater than air conduction on that side. The remainder of her exam was normal. Initial audiogram (**Figure 1A**) demonstrated asymmetric right-sided conductive hearing loss with preserved discrimination. Tympanometry was type A on the right and type C on the left. Computed tomography (CT) imaging of the temporal bones without contrast (**Figure 2**) demonstrated a right-sided ossicular prosthesis sitting adjacent to the umbo of the malleus with a medial segment extending through the oval window, deep into the vestibule, with the prosthesis tip contacting the medial vestibule wall.

Given the severity and chronicity of her symptoms in combination with a suggestive etiology on imaging, the patient underwent a revision exploratory tympanotomy under general anesthesia. Intraoperative visualization of the middle ear revealed a calvarial bone strut extending from the remnant manubrium through the stapes footplate, deep into the vestibule. The malleus head, body of the incus, and bone strut were removed. A 5.0-mm-length nitinol-Teflon stapes piston prosthesis was placed with the wire crimped into position around the manubrium of the malleus and the medial tip extending shallowly through the footplate fenestration. A lobular fat graft was used to seal the fenestration of the oval window.

Postoperatively, the patient experienced immediate symptomatic improvement. One month following surgery, her initial complaints of right-sided aural fullness, pressure, and otalgia were completely resolved. Postoperative audiogram (**Figure 1B**) demonstrates a narrowed air-bone gap with

¹Department of Otolaryngology, Massachusetts Eye and Ear Infirmary, Boston, Massachusetts, USA

²Department of Otolaryngology, UMass Memorial Medical Center, Worcester, Massachusetts, USA

³University of Massachusetts Medical School, Worcester, Massachusetts, USA

⁴Department of Otolaryngology, Harvard Medical School, Boston, Massachusetts, USA

Corresponding Author:

Aaron K. Remenschneider, MD, MPH, Department of Otolaryngology, Massachusetts Eye and Ear Infirmary, Eaton-Peabody Laboratories, Suite 469, 243 Charles Street, Boston, MA 02114, USA.
 Email: aaron_remenschneider@meei.harvard.edu



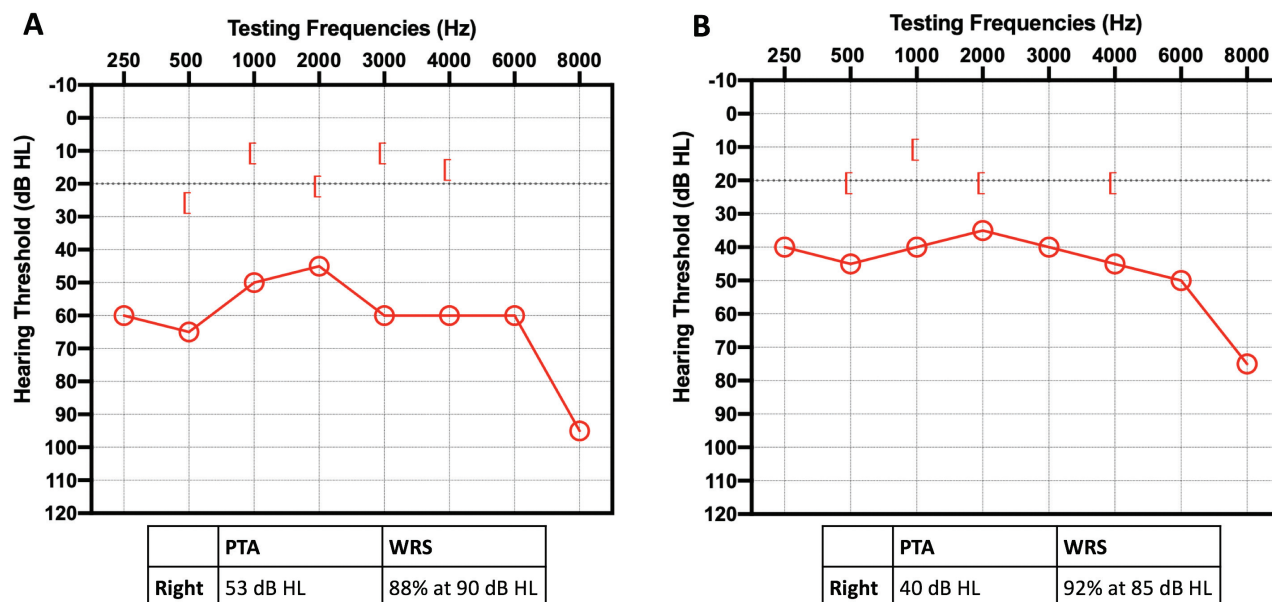


Figure 1. (A) Initial audiogram demonstrates right-sided conductive hearing loss. (B) Postoperative audiogram and speech audiometry reveal improved air conduction and unchanged bone conduction thresholds. Air-bone gap is narrowed and word recognition score (WRS) is improved. PTA, pure-tone average.

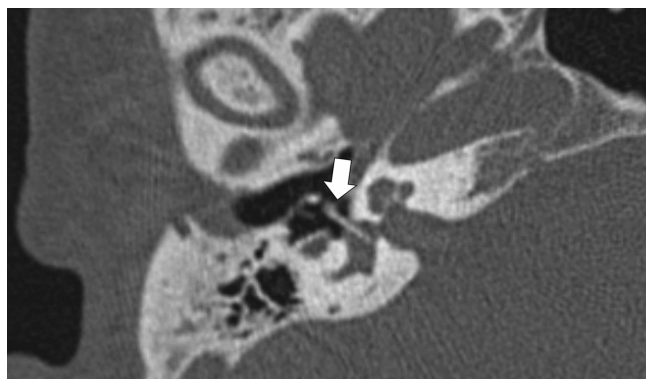

Figure 2. Preoperative noncontrast axial computed tomography of temporal bones. A 7.0-mm, right-sided calvarial bone strut total ossicular replacement prosthesis (arrow) sitting adjacent to the umbo with a medial segment extending through the oval window, deep into the vestibule.

unchanged bone conduction and improved discrimination scores.

Discussion

Medial TORP displacement is likely a rare occurrence in the setting of an intact stapes footplate since it is common practice to (1) use cartilage or titanium shoes to disperse pressure across the footplate⁴ and (2) minimize pressure on the footplate by measuring for appropriate prosthesis length prior to placement. Considering the typical horizontal reach from the footplate to the malleus is between 4 and 5 mm,⁵ the use of a 7-mm calvarial bone strut was likely in part responsible for the footplate penetration seen in this case.

Footplate manipulation resulting in microfractures may also predispose to TORP medialization, a complication previously observed in radical tympanomastoidectomy.³ Our case highlights that this event may occur even with an intact canal wall and preserved tympanic space.

A number of patient complaints may suggest medialization of an ossicular prosthesis into the vestibule, including persistent dizziness or vertigo after surgery, head trauma, or barotrauma. Dizziness with belching, eustachian tube dilation, and/or swallowing are also classic indications of a medialized prosthesis.⁶ Present in this case are complaints of otalgia, aural pressure, and fullness. Although these symptoms are not typically associated with a medialized prosthesis, the immediate resolution following surgery offers evidence that these symptoms may be improved by replacement of a deeply placed prosthesis.

Management of a patient with a medialized prosthesis largely depends on the symptom nature and severity. Given the higher risk of deafness associated with revision stapedectomy,⁶ hearing aids may be an acceptable alternative if conductive hearing loss is the only complaint. If aural fullness or vestibular symptoms are severe, revision exploratory tympanotomy is reasonable.

Acknowledgments

The authors acknowledge the mentorship and advice of Dr Michael McKenna on this challenging case.

Author Contributions

Marc D. Polanik, writing and editing manuscript, literature review; **Aaron K. Remenschneider**, conception/design, clinical contributions, editing manuscript.

Disclosures

Competing interests: None.

Sponsorships: None.

Funding source: None.

References

1. Whetstone J, Nguyen A, Nguyen-Huynh A, Hamilton BE. Surgical and clinical confirmation of temporal bone CT findings in patients with otosclerosis with failed stapes surgery. *AJNR Am J Neuroradiol*. 2014;35(6):1195-1201.
2. Sheehy JL. TORPs and PORPs: causes of failure—a report on 446 operations. *Otolaryngol Head Neck Surg*. 1984;92(5):583-587.
3. Sanei-Moghaddam A, Kumar S, Donnelly N, Axon P. Medialization of total ossicular replacement prosthesis in mastoid obliteration. *Int Adv Otol*. 2013;9(1):110-114.
4. Luers JC, Schwarz D, Anagnostos A, Gostian AO, Beutner D, Huttenbrink KB. Long-term follow-up study of the sandwich cartilage shoe technique in cases of insecure stapes footplate. *Otol Neurotol*. 2016;37(7):e197-e202.
5. Dornhoffer J. Ossiculoplasty with synthetic PORPS and TORPS. In: Dornhoffer J, Gluth M, eds. *The Chronic Ear*. New York, NY: Thieme; 2016. https://medone-otolaryngology.thieme.com/ebooks/1566052?fromSearch=true#/ebook_1566052_SL64812114. Accessed July 3, 2019.
6. Sarac S, McKenna MJ, Mikulec AA, Rauch SD, Nadol JB Jr, Merchant SN. Results after revision stapedectomy with malleus grip prosthesis. *Ann Otol Rhinol Laryngol*. 2006;115(4):317-322.