



## Protocol for a randomised clinical trial of transoral ultrasound versus standard of care in the diagnosis of peritonsillar abscess

Todsén, Tobias; Stage, Mads Georg; Michaelsen, Sanne Høxbroe; Tolsgaard, Martin G; Melchior, Jacob; Madsen, Anders Rørbæk; Hahn, Christoffer Holst; Godballe, Christian

*Published in:*  
Danish Medical Journal

*Publication date:*  
2019

*Document version*  
Publisher's PDF, also known as Version of record

*Document license:*  
[CC BY-NC](#)

*Citation for published version (APA):*  
Todsén, T., Stage, M. G., Michaelsen, S. H., Tolsgaard, M. G., Melchior, J., Madsen, A. R., ... Godballe, C. (2019). Protocol for a randomised clinical trial of transoral ultrasound versus standard of care in the diagnosis of peritonsillar abscess. *Danish Medical Journal*, 66(11), [A5573].

# Protocol for a randomised clinical trial of transoral ultrasound versus standard of care in the diagnosis of peritonsillar abscess

Tobias Todsen<sup>1,2</sup>, Mads Georg Stage<sup>1</sup>, Sanne Høxbroe Michaelsen<sup>3</sup>, Martin G. Tolsgaard<sup>2</sup>, Jacob Melchior<sup>1,2</sup>, Anders Rørbæk Madsen<sup>3</sup>, Christoffer Holst Hahn<sup>1</sup> & Christian Godballe<sup>3</sup>

## ABSTRACT

**INTRODUCTION:** Peritonsillar infection is a common complication to acute tonsillitis in younger adults. If peritonsillar cellulitis progresses to a peritonsillar abscess (PTA), the primary treatment is surgical drainage. But distinguishing cellulitis from PTA on a standard clinical examination is difficult. This trial aims to explore whether point-of-care transoral ultrasound can improve diagnostic accuracy and guide successful needle aspiration in patients referred with PTA.

**METHODS:** A randomised, controlled multicentre trial will be conducted at the departments of otorhinolaryngology, head and neck surgery at Rigshospitalet and Odense University Hospital. Patients referred with PTA will be randomised to either standard clinical examination (control) or standard clinical examination with supplemental transoral ultrasound (intervention). The diagnostic accuracy, the total number of performed needle aspirations and the proportion of successful needle aspirations will be compared between the two groups. The difference will be evaluated using binary logistic regression and a generalised estimating equation to adjust for clustering of data within each physician and each hospital. A total of 88 patients are necessary to measure the clinical effect of adding transoral ultrasound.

**CONCLUSIONS:** This study will explore the clinical benefits of adding transoral ultrasound to the diagnostic work-up of patients with peritonsillar infections.

**FUNDING:** The Rigshospitalet and Odense University Hospital Foundation.

**TRIAL REGISTRATION:** Clinicaltrials NCT03824288.

The progression of peritonsillar cellulitis (PTC) to a peritonsillar abscess (PTA) – defined as a collection of pus in the loose connective tissue between the palatine tonsil and the pharyngeal muscles – is the most common head and neck infection requiring hospitalisation [1]. Patients have typically suffered from a prolonged case of acute tonsillitis and complain of unilateral sore throat, ipsilateral ear pain and decreased oral intake [2]. Objective findings consistent with a PTA include a muffled voice, trismus, a swollen tonsil and deviation of the uvula to the opposite side of the PTA [3]. Early

surgical drainage is imperative to avoid a potentially dangerous spreading of the PTA into the surrounding tissue [4]. The abscess can be drained under local anaesthesia by needle aspiration or knife incision [5]. Most commonly, the point of maximal protrusion and fluctuance will guide the insertion of the needle or scalpel. If no pus is aspirated, the instrument is inserted once or twice more, guided by specific landmarks (the landmark technique) [2, 6]. Distinguishing a PTA from PTC based on a standard clinical examination is difficult (sensitivity 78%, specificity 50%) [7]. A PTA may therefore be missed, or unnecessary PTC drainage attempts will therefore often be performed [8]. Furthermore, unsuccessful needle aspirations may also be seen in patients with a small or more posteriorly located abscess cavity. A computed tomography with contrast can ensure a correct diagnosis, but is expensive and exposes the, often young, patients to ionising radiation. Instead, point-of-care ultrasound can provide a fast, radiation-free and low-cost imaging [9]. Previously published case series and retrospective cohort studies have described that transoral ultrasound with an endocavity or “hockey stick” transducer can increase the diagnostic accuracy [10-14]. Only one small single-centre randomised controlled trial has been conducted, but their technique only allowed for static ultrasound imaging and not for real-time guidance of the needle aspiration [15]. For this reason, we have developed a new technique which utilises a small neurosurgical ultrasound transducer suitable for transoral ultrasound-guided aspiration of PTAs [16]. The hypothesis is that we can improve the diagnostic accuracy and treatment of patients referred with a PTA by adding a novel point-of-care transoral ultrasound technique to the standard clinical examination. The research question is: In a group of patients referred to an otolaryngology department with objective signs of a peritonsillar abscess, what is the effect of using transoral ultrasound to diagnose PTA and guide needle aspiration when measured by the diagnostic accuracy, the proportion of successful needle aspirations and the total number of performed needle aspirations. This effect is compared with the effect in

## PROTOCOL ARTICLE

- 1) Department of Otorhinolaryngology, Head and Neck Surgery & Audiology, Rigshospitalet
- 2) Copenhagen Academy for Medical Education and Simulation, Copenhagen, Capital Region
- 3) Department of Otorhinolaryngology – Head & Neck Surgery and Audiology, Odense University Hospital, Denmark

Dan Med J  
2019;66(11):A5573

**TABLE 1 /** Eligibility criteria for enrollment of study participants..

| Criteria           | Description  |
|--------------------|--|
| Inclusion criteria | Patients referred to the department of otorhinolaryngology on the suspicion of having a peritonsillar abscess, who also present ≥ 1 of the following on clinical examination<br>Unilateral tonsillar protrusion<br>Peritonsillar swelling<br>Trismus |
| Exclusion criteria | Age < 18 yrs<br>Compromised airways or suspected retro-/parapharyngeal abscess<br>Needle aspiration already performed or participated in the study 1 × earlier<br>Unable to understand the verbal or written information                             |

patients diagnosed using a standard clinical examination and treated using the traditional landmark-based needle aspiration technique.

**METHODS**

The study is a prospective, randomised, controlled multicentre trial conducted at two university hospitals in Denmark (the Department of Otorhinolaryngology – Head & Neck Surgery and Audiology, Odense University Hospital (OUH), and the Department of Otorhinolaryngology, Head and Neck Surgery & Audiology, Rigshospitalet (RH)). The protocol is registered with clinicaltrials.gov (Trial number: NCT03824288) and adheres to the recommendations for interventional trials described in the SPIRIT 2013 Checklist.

**Eligibility criteria**

In Denmark, patients suspected of having a PTA are typically first examined by a general practitioner or a physician from an emergency department. Once suspicion of PTA has been raised, they are referred to an office-based otolaryngologist or a hospital-based department of otolaryngology. Patients referred to the two participating departments of otolaryngology, head and neck surgery on suspicion of having a PTA will be invited to participate in the study only if the resident on call has been trained in the procedure of ultrasound-guided PTA drainage. Patients who meet both the eligibility and the inclusion criteria (see **Table 1**) and agree to participate in the study will be allocated to the intervention or control group using a 1:1 randomisation.

**Randomisation**

Before the study begins, a randomisation list will be created using a random permuted blocks technique available online. Based on the randomisation list, sealed envelopes containing the equipment needed for either the intervention or the control group will be prepared and provided with a consecutive patient inclusion number. Once patient consent has been obtained,

included patients will be allocated to either the control or the intervention group in accordance with the contents of the sealed envelope.

**Interventions**

All included patients will receive the same physical otorhinolaryngology examination, including a flexible transnasal laryngoscopy and an objective measure of the degree of trismus based on a TheraBite range of motion scale. All patients will receive a minimum of one spray of topical anaesthetic (lidocaine 10 mg/dose) to the posterior pharynx. If needle aspiration is deemed necessary, 0.5 ml of 2% lidocaine with 5 µg epinephrine will subsequently be injected into the mucous membrane. If the PTA aspiration produces pus, this will be collected in a test tube with a transport medium suitable for aerobic and anaerobic bacteria and sent for microbiological examination. A mosquito forceps will then be introduced to open the abscess cavity further to aid additional drainage. If no needle aspiration is performed, or if a needle aspiration produces no pus, a swap of the affected tonsil is made and sent for microbiological examination. All patients will either be seen in the outpatient clinic 24-36 hours after their first consultation or be admitted to the hospital according to their general condition. The patients who refuse to participate in the study will receive the standard treatment, which is identical to that of the control group.

About a month after the discharge from the outpatient clinic/hospital, patients will receive a phone call from one of the co-authors inquiring about their total number of sick days (defined as days until they returned to work/school or believe that they would have returned if they were sick during vacation/holidays).

**Control group**

A standard examination of the oral cavity is performed, and if the clinical findings are consistent with a PTA, a needle aspiration is attempted. The needle is inserted into the point of maximal protrusion and fluctuance, which most commonly corresponds to the superior pole of the tonsil [2]. If the initial aspiration is unsuccessful, up to two additional attempts – typically in the middle and lower pole of the tonsil – may be made. If all attempts are unsuccessful, the patient will either be discharged with penicillin V and a planned follow-up visit in the outpatient clinic or be admitted to the otorhinolaryngology department for treatment with intravenous antibiotics or quincy tonsillectomy – depending on the severity of the symptoms and clinical findings.

**Intervention group**

The otorhinolaryngologist on call will perform a standard oral examination, apply topical anaesthetics to the posterior pharynx and subsequently conduct a trans-

oral ultrasound examination using a bk5000 machine and a Burr-Hole N11C5s transducer from BK Medical. The transducer is placed in a surgical glove filled with ultrasound gel. The tip of the transducer is then placed on the palatoglossal arch and swept from the cranial to the caudal end of the affected tonsil. An abscess is expected to appear as a hypoechoic area with ill-defined margins. If an abscess is not clearly visualised, the slightly larger high-frequency Hockey Stick X18L5 transducer may be applied to obtain a higher resolution image. If an abscess cavity is suspected, local anaesthesia is injected into the mucosa, and an ultrasound-guided needle aspiration is attempted. The aspiration technique chosen will depend on the degree of trismus and the severity of the gag reflex. The needle aspiration will therefore either be performed with an in-plane needle guide attached to a Burr-Hole N11C5s transducer, (b) an ultrasound-guided free-hand technique or (c) a “blind” aspiration guided by the previously visualised abscess on the static ultrasound image, see **Figure 1**. If the initial aspiration is unsuccessful, up to two additional attempts may be made. If no abscess cavity is visualised, no needle aspiration is attempted. Instead, the patient is handled like the patients in the control group after three unsuccessful needle aspiration attempts.

**Training in transoral ultrasound**

Surgeon-performed ultrasound is an integrated part of the diagnostic work-up at otolaryngologists in Denmark and the residents therefore receive head and neck ultrasound training early in their residency. Before they can include patients in the study, they must participate in an additional 45-minute intensive simulation training of ultrasound-guided PTA aspiration. First, they will attend a short didactic lecture by author TT, and then they will receive hands-on training on a custom-made artificial PTA model, taught by either TT or SHM, see **Figure 2**. The artificial PTA consists of a cup filled with hardened gelatin (the “pharyngeal muscles”) into which two small water balloons (two “abscesses”) have been placed [17]. All residents must perform two ultrasound-guided aspiration attempts: one with a needle-guide attached to the ultrasound transducer and the other with a free-hand technique.

**Clinical outcome measures**

These baseline characteristics between the intervention and the control group will be compared: sex, smoking habits, level of pain on presentation, number of cases of acute tonsillitis during the past year, previous number of PTAs.

Primary outcome will be reported as:

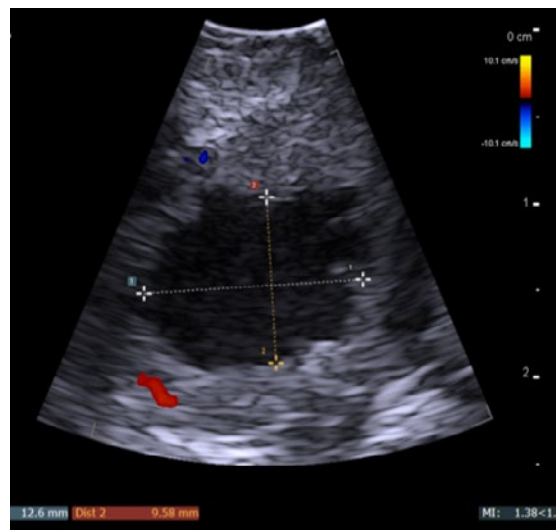
- Diagnostic accuracy

- Part of successful (with pus) needle aspirations
- Total number of performed needle aspirations in each group.

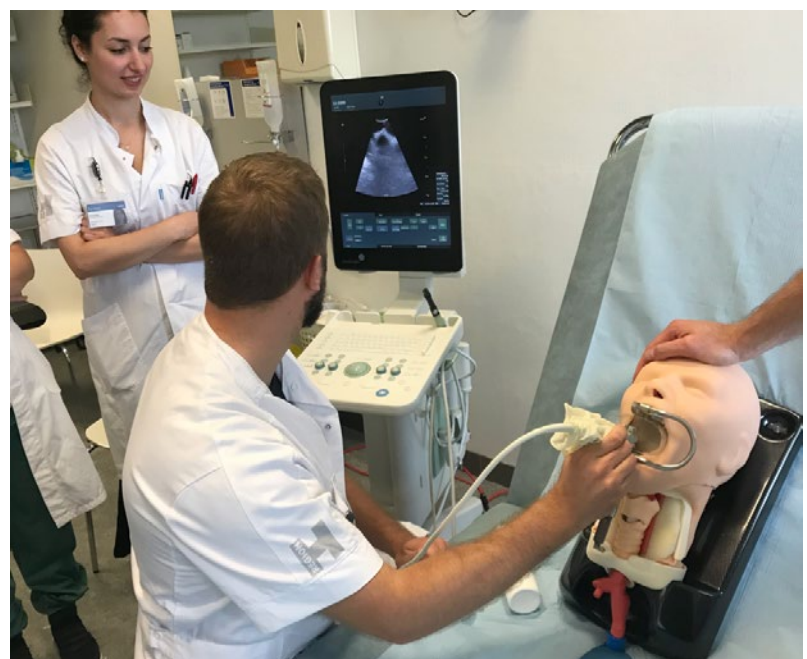Secondary outcomes will be:

- Number of sick days
- Number of days of hospitalisation

**FIGURE 1 /** Transoral ultrasound image from a patient with a peritonsillar abscess (white and yellow measuring lines on the image).



**FIGURE 2 /** Simulation training of ultrasound-guided peritonsillar abscess aspiration on a custom-made peritonsillar abscess gelatine phantom placed in the oral cavity of a mannequin for airway management.



**TABLE 2 /** Power calculations to determine minimum sample size needed to compare two binomial proportions using a two-sided test with significance level 0.05 and power 90%.

| Parameter      | Calculation  |
|----------------|--|
| n              | $\left\{ Z_{1-\frac{\alpha}{2}} \times \sqrt{p_x \times q_x \times \left(1 + \frac{1}{k}\right)} + Z_{1-\beta} \times \sqrt{p_1 \times q_1 + \left(\frac{p_2 \times q_2}{k}\right)} \right\}^2 / \Delta^2$ |
| q <sub>1</sub> | 1 - p <sub>1</sub>   |
| q <sub>2</sub> | 1 - p <sub>2</sub>   |
| p <sub>x</sub> | $\frac{p_1 + kp_2}{1 + k}$   |
| q <sub>x</sub> | 1 - p <sub>x</sub>   |

α = probability of type I error (= 0.05); β = probability of type II error (= 0.2); Δ = |p<sub>2</sub> - p<sub>1</sub>| = absolute difference between 2 proportions; k = ratio of sample size for intervention group no. 2 to control group no. 1;

$$n = \text{sample size for 1 group, } n = \left\{ 1.96 \times \sqrt{0.78 \times 0.22 \times \left(1 + \frac{1}{1}\right)} + 1.28 \times \sqrt{0.92 \times 0.08 + \left(\frac{0.64 \times 0.36}{1}\right)} \right\}^2 / 0.28^2 = 44;$$

p<sub>1</sub> = diagnostic accuracy of transoral ultrasound (intervention group); p<sub>2</sub> = diagnostic accuracy of clinical examination (control group); z = critical Z-value for a given α or β.

- Number of quincy tonsillectomies (tonsillectomy “a chaud”)
- Number of visits in the outpatient clinic
- Patient-reported outcome measures (using an 11-point numeric rating scale).

**Statistics**

*Power calculation*

The power calculation was based on the expected change in diagnostic accuracy when adding transoral ultrasound as point-of-care imaging.

The sample size needed to compare two independent binomial proportions with a significance level of 0.05 and 90% power was calculated based on a prior study that found a difference in diagnostic accuracy of 28% when comparing transoral ultrasound with clinical examination [7].

Based on the power calculation presented in **Table 2**, it was estimated that 44 patients would be needed in each group [18]. We therefore aim to include a total of 88 patients in the study.

**Statistical analysis**

All enrolled patients are included in the analysis on an intention-to-treat basis. For each patient, the diagnostic accuracy (correct/false tentative diagnosis) and proportion of successful needle aspirations (aspiration of ± pus) are analysed as binary data. The mean differences between the intervention and the control group will be compared using binary logistic regression and a generalised estimating equation to adjust for clustering of data within each physician and each hospital. Negative binomial distribution will be used to explore the differences in sick days and the number of performed needle aspirations between the intervention and the control group.

The statistical analyses will be performed using the statistical software package (PASW, version 25.0; SPSS

Inc, Chicago, Illinois, U.S.A.), and two-sided significance levels of 0.05 will be used for all analyses.

**Inclusion period**

The annual incidence of PTAs is 36 per 100,000 persons [1]. We will include adult patients from two different otorhinolaryngology departments at RH and at OUH, covering a population of 916,000 (RH) and 466,284 (OUH) totalling 1.38 million people. We therefore expect 498 patients to be diagnosed with a PTA annually within the coverage areas of the two hospitals. Some of these patients will be treated by an office-based otorhinolaryngologist and some patients will decline to participate in the study. We therefore expect to include 25% of the 498 potential patients = 125 patients. We will thus need about nine months to include 88 patients in the study.

**Ethics and data management**

Ethical approval was granted in the form of an exemption letter from the Committee on Biomedical Research Ethics of the Capital Region of Denmark (registration number: H-18037012). Verbal and written informed consent will be obtained from every patient involved. All data will be stored on a Research electronic data capture (RedCap) Database and documentation requirements and data permission were approved by The Capital Region of Denmark (registration number: VD-2018-361). Data entry will be performed by co-authors MGS and SHM, and the statistical analyses will be performed by first author TT who will be blinded to the randomisation of the study subjects until the analyses of the primary outcome have been completed. The anonymised data will be made publicly available through the open-access database Zenodo open data repository (CERN).

*Trial registration:* Clinicaltrials NCT03824288.

## DISCUSSION

Transoral ultrasound has the potential to improve the accuracy of diagnosing peritonsillar abscesses, but previous studies have methodological deficiencies, and the procedure has yet to be included as part of the standard diagnostic work-up. A single-centre RCT using transoral ultrasound as static imaging reported promising findings, but the study was limited by a small sample size. Furthermore, it lacked a description of the training received by the physicians performing the procedure, which is a relevant parameter since ultrasound is very operator dependent [19]. This study will be the first multi-centre RCT to explore the clinical effect of adding a novel transoral ultrasound technique to the diagnostic work-up of patients with peritonsillar infection. Our results will have the potential to improve both the diagnosis and treatment thereby avoiding unnecessary interventions and hospitalizations in the future.

**CORRESPONDENCE:** Tobias Todsén. E-mail: tobiastodsén@gmail.com

**ACCEPTED:** 3 September 2019

**CONFLICTS OF INTEREST:** none. Disclosure forms provided by the authors are available with the full text of this article at [ugeskriftet.dk/dmj](http://ugeskriftet.dk/dmj)

## LITERATURE

1. Klug TE. Peritonsillar abscess: clinical aspects of microbiology, risk factors, and the association with parapharyngeal abscess. *Dan Med J* 2017;64(3):B5333.
2. Passy V. Pathogenesis of peritonsillar abscess. *Laryngoscope* 1994;104:185-90.
3. Powell J, Wilson JA. An evidence-based review of peritonsillar abscess. *Clin Otolaryngol* 2012;37:136-45
4. Page C, Biet A, Zaatar R et al. Parapharyngeal abscess: diagnosis and treatment. *Eur Arch Otorhinolaryngol* 2008;265:681-6.
5. Herzon, FS. Peritonsillar abscess: incidence, current management practices, and a proposal for treatment guidelines. *Laryngoscope* 1995;105:1-17
6. Shaul C, Koslowsky B, Rodriguez M et al. Is needle aspiration for peritonsillar abscess still as good as we think? A long-term follow-up. *Ann Otol Rhinol Laryngol* 2015;124:299-304
7. Scott PM, Loftus WK, Kew J et al. Diagnosis of peritonsillar infections: a prospective study of ultrasound, computerized tomography and clinical diagnosis. *J Laryngol Otol* 1999;113:229-32.
8. Froehlich MH, Huang Z, Reilly BK. Utilization of ultrasound for diagnostic evaluation and management of peritonsillar abscesses. *Curr Opin Otolaryngol Head Neck Surg* 2017;25:163-8.
9. Todsén T. Surgeon-performed ultrasonography. *Dan Med J* 2017;64(11):B5421.
10. Salihoglu M, Eroglu M, Yildirim AO et al. Transoral ultrasonography in the diagnosis and treatment of peritonsillar abscess. *Clin Imaging* 2013;37:465-7.
11. Lyon M, Blaivas M. Intraoral ultrasound in the diagnosis and treatment of suspected peritonsillar abscess in the emergency department. *Acad Emerg Med* 2005;12:85-8.
12. Blaivas M, Theodoro D, Duggal S. Ultrasound-guided drainage of peritonsillar abscess by the emergency physician. *Am J Emerg Med* 2003;21:155-8.
13. Nogan S, Jandali D, Cipolla M et al. The use of ultrasound imaging in evaluation of peritonsillar infections. *Laryngoscope* 2015;125:2604-7.
14. Filho BCA, Sakae FA, Sennes LU et al. Intraoral and transcutaneous cervical ultrasound in the differential diagnosis of peritonsillar cellulitis and abscesses. *Braz J Otorhinolaryngol* 2006;72:377-81.
15. Costantino TG, Satz WA, Dehnkamp W et al. Randomized trial comparing intraoral ultrasound to landmark-based needle aspiration in patients with suspected peritonsillar abscess. *Acad Emerg Med* 2012;19:626-31.
16. Todsén T, Stage MG, Hahn CH. A novel technique for intraoral ultrasound-guided aspiration of peritonsillar abscess. *Diagnostics (Basel)* 2018;8:50.
17. Ng V, Plitt J, Biffar D. Development of a novel ultrasound-guided peritonsillar abscess model for simulation training. *West J Emerg Med* 2018;19:172-6.
18. Rosner, B. *Fundamentals of biostatistics*. Copenhagen: Cengage Learning, 2010.
19. Todsén T, Melchior J, Charabi B et al. Competency-based assessment in surgeon-performed head and neck ultrasonography: a validity study. *Laryngoscope* 2018;128:1346-52.