

**UCC Library and UCC researchers have made this item openly available. Please [let us know](#) how this has helped you. Thanks!**

<b>Title</b>	Work-related stress induced Takotsubo cardiomyopathy
<b>Author(s)</b>	O'Sullivan, Grainne; O'Sullivan, K.; Gallagher, John
<b>Publication date</b>	2020-02
<b>Original citation</b>	O'Sullivan, G., O'Sullivan, K. and Gallagher, J. (2020) 'Work-related stress induced Takotsubo cardiomyopathy', Irish Medical Journal, 113(2), P27 (3pp). Available at: <a href="http://www.imj.ie/wp-content/uploads/2020/02/Work-Related-Stress-Induced-Takotsubo-Cardiomyopathy.pdf">http://www.imj.ie/wp-content/uploads/2020/02/Work-Related-Stress-Induced-Takotsubo-Cardiomyopathy.pdf</a> (Accessed: 18 May 2020)
<b>Type of publication</b>	Article (peer-reviewed)
<b>Link to publisher's version</b>	<a href="http://imj.ie/irish-medical-journal-february-2020-vol-113-no-2/">http://imj.ie/irish-medical-journal-february-2020-vol-113-no-2/</a> Access to the full text of the published version may require a subscription.
<b>Rights</b>	© 2020, Irish Medical Journal. All rights reserved.
<b>Item downloaded from</b>	<a href="http://hdl.handle.net/10468/9962">http://hdl.handle.net/10468/9962</a>

Downloaded on 2020-05-27T00:07:46Z



**UCC**

University College Cork, Ireland  
 Coláiste na hOllscoile Corcaigh

# Work-Related Stress Induced Takotsubo Cardiomyopathy

G. O'Sullivan, K. O'Sullivan, J. Gallagher

Occupational Health Department, Cork University Hospital, Wilton, Cork

## Abstract

### **Aim**

To report a case of Takotsubo cardiomyopathy secondary to a verbal altercation in an employee who presented with chest pain.

### **Methods**

The clinical history was obtained from the patient's occupational health record and correspondence from her treating cardiologist.

### **Results**

The patient was diagnosed with Takotsubo cardiomyopathy following investigations for chest pain. Her echocardiogram was diagnostic. She was treated with beta blockers and advised to have complete rest; she remained out of work for six months.

### **Conclusion**

There are few published cases of work related Takotsubo cardiomyopathy; it poses a challenge to physicians to be cognisant of this condition in a case of chest pain following emotional turmoil.

## Introduction

Takotsubo Cardiomyopathy or 'broken heart syndrome' is a temporary, stress induced cardiomyopathy <sup>1</sup>. It is diagnosed due to its characteristic appearance of the left ventricle; a ballooning of the apex with a hypercontractile basal portion (figure 1a and figure 1b) <sup>1</sup>. It is a condition seen almost exclusively in postmenopausal women <sup>1</sup>. It can mimic a myocardial infarction as it presents with chest pain and dyspnoea. Investigations reveal ST elevation and a raised troponin level <sup>1</sup>.

The condition may be caused by emotional or physical stressors or an underlying medical illness. Emotional stressors such as death or injury of a loved one, an assault, a severe argument or a natural disaster have all been implicated in causation <sup>2</sup>. Physical stressors include surgery. Medical conditions such as sepsis, an asthmatic attack and acute pancreatitis have all been found to cause Takotsubo cardiomyopathy <sup>2</sup>.

## Case Report

A forty-nine year-old lady attended the Occupational Health Department at our hospital. She was referred by her line manager querying a possible work-related health problem. This lady reported she suffered verbal abuse over the phone by a client's relative and suffered similar verbal abuse in person from the same person four days later. She developed retrosternal chest pain four days after this second incident.

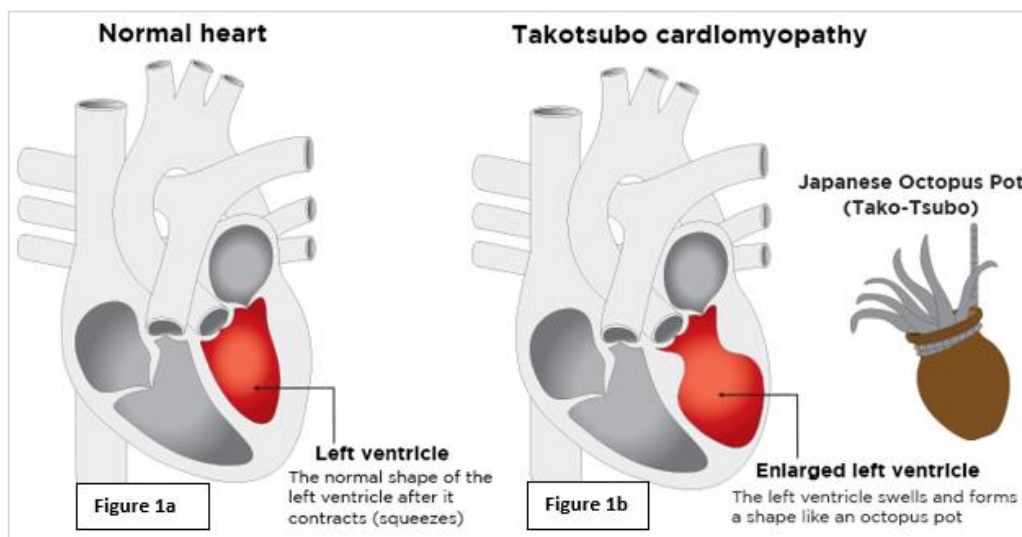
She attended a local Emergency Department and was admitted with an elevated serum troponin and abnormal electrocardiogram. A coronary angiogram was performed which revealed no evidence of coronary artery disease. An echocardiogram revealed akinesia of the apex of her heart. A repeat echocardiogram two weeks later was normal, confirming the diagnosis of Takotsubo cardiomyopathy.

Her cardiologist commenced her on beta blockers (bisoprolol five mg once daily), advised she needed complete rest and to avoid any triggers or stresses that may lead to a recurrence in her condition.

She remained out of work on her cardiologist's recommendations over a six month period. Following further review in the occupational health clinic and in conjunction with her cardiologist, a graduated return to work was suggested. Her employer has been advised that she should not have any contact with the person with whom she had the traumatic interaction.

## Discussion

Takotsubo Cardiomyopathy (TC) was first described in Japan in 1990<sup>3</sup>. It has been likened to a Japanese octopus trap due to its characteristic apical ballooning appearance on an echocardiogram (figure 1a and figure 1b)<sup>3</sup>. Although initially thought to be a rare event, it is now recognised that one to two percent (1-2%) of all presentations of acute coronary syndrome are due to TC<sup>3</sup>.



There is limited literature on work related TC. A case report published in 2018 identified chronic work place bullying as a cause of TC<sup>4</sup>.

The pathophysiology of stress induced TC is not well understood. Risk factors for TC include female sex, post menopause, mental health illnesses (depression, anxiety and schizophrenia), asthma, chronic obstructive pulmonary disease and diabetes<sup>3</sup>.

TC caused by work related stress poses a challenge for occupational health physicians. The recurrence rate of TC has been reported at two to four percent (2-4%) per year<sup>3</sup>. There is no evidence or guidelines on the long-term management in terms of limiting risk of recurrence<sup>3</sup>.

Our case highlights the association between verbal conflict and emotional upset in the workplace and subsequent development of TC. It thus challenges employers, managers and employees to risk assess and manage workplace stress in order to limit risks of potential medical complications.

Further research to identify why some individuals are susceptible to Takotsubo cardiomyopathy is necessary. In the interim, case by case management is required.

**Acknowledgements:**

Diagram kindly reproduced with permission from the National Heart Foundation of New Zealand.

**Declaration of Conflicts of Interest:**

The authors have no conflicts of interest to declare.

**Corresponding Author:**

Dr. Grainne O'Sullivan  
Occupational Health Department,  
Cork University Hospital,  
Wilton, Cork  
Email: grainne\_o\_sullivan@yahoo.co.uk

**References:**

1. Banning A., Cuculi F., Lim C.C.S. Takotsubo cardiomyopathy. *BMJ* 2010; 340: c1272.
2. Andrade A.A. ,Stainback R.F. Takotsubo Cardiomyopathy. *Texas Heart Institute Journal*. 2014 Jun; 41(3): 299–303.
3. Medina de Chazal H., Giuseppe Del Buono M., Keyser-Marcus L., Ma L., Moeller F.G., Berrocal D., Abbate A. Stress Cardiomyopathy Diagnosis and Treatment. *Journal of the American College of Cardiology*. Oct 2018; 72 (16): 1955-1971
4. Malik H., Kangaharan N. and Agahari I. Takotsubo Cardiomyopathy Associated with Work-Place Bullying. *Occupational Medicine*. Feb 2018; 68(1):67-69.