

**LENGTHENING IN CONGENITAL LIMB LENGTH DISCREPANCY  
USING CALLOTASIS:  
CLINICAL, RADIOLOGICAL AND PHYSIOLOGICAL STUDIES**

Thesis presented for the degree  
of Master of surgery by  
**NICOLA MAFFULLI**

Department of Surgery  
Institute of Child Health  
University of London


ProQuest Number: U063615

All rights reserved

INFORMATION TO ALL USERS

The quality of this reproduction is dependent upon the quality of the copy submitted.

In the unlikely event that the author did not send a complete manuscript and there are missing pages, these will be noted. Also, if material had to be removed, a note will indicate the deletion.



ProQuest U063615

Published by ProQuest LLC(2016). Copyright of the Dissertation is held by the Author.

All rights reserved.

This work is protected against unauthorized copying under Title 17, United States Code.  
Microform Edition © ProQuest LLC.

ProQuest LLC  
789 East Eisenhower Parkway  
P.O. Box 1346  
Ann Arbor, MI 48106-1346

To my teachers:

from them, I am learning how to fly with my own wings

## ABSTRACT

Limb lengthening is widely practised for short stature and limb length discrepancy. Gradual callus distraction following corticotomy, while breaching the cortex, leaves intact the medullary canal, and produces elongation of bone and soft tissues.

Published work has generally reported the results of dwarfism and post-traumatic conditions. Data regarding the correction of congenital limb length discrepancy are not at present available.

This thesis reports the work, carried out in a longitudinal fashion, performed on a selected group of 24 children undergoing lengthening to correct lower and upper limb congenital length discrepancy.

The procedure, while being described by other authors as practically risk free, proved to have a significant number of problems, with all children suffering from pin site infection. The children had to be protected in a cast when the external fixation apparatus was removed to prevent fracture of the regenerate bone, which occurred in some of the early patients. Also, joint contractures had to be prevented and treated by intense physiotherapy. One child suffered from toxic shock following septicaemia stemming from pin site infection.

Ultrasound scanning gives valuable information on the morphology of the regenerate bone. However, it is probably not sensitive enough to replace serial conventional radiographs in assessing the maturity of

the newly formed bone.

Children with a congenital short femur take two years to return to the pre-lengthening isometric strength of their knee extensor muscles.

## CONTENTS

	Page number
Abstract .....	3
List of contents .....	4
Acknowledgements .....	6
List of figures .....	8
List of tables .....	9
List of papers bound in .....	10
Chapter 1: GENERAL INTRODUCTION .....	11
Chapter 2: CLINICAL STUDIES .....	46
Chapter 3: RADIOLOGICAL STUDIES .....	86
Chapter 5: PHYSIOLOGICAL STUDIES .....	117
Chapter 6: CONCLUSIONS .....	132
References .....	134
Papers bound in .....	159

## ACKNOWLEDGEMENTS

I am deeply indebted to all the children and their parents who participated in this study, which was supported by a grant of the Growth Foundation. Ms. Christine Monk deverses many thanks for the skill with which the funds were administered.

Although the thesis bears my name, and the ideas and opinions expressed therein are my own, without the help of many people its presentation in the present form would not have been possible.

For the advice throughout the ordeal of performing research, maintaining my clinical knowledge up to date, and increasing it, analysing the data, and writing up, I thank my advisor Mr. John A. Fixsen, Consultant in Orthopaedic Surgery at the Hospital for Sick Children, and Senior Lecturer in Orthopaedic Surgery at the Institute of Child Health, and my supervisor Prof. Louis Spitz, Professor of Paediatric Surgery at the Institute of Child Health. The discussions during the study period greatly helped my scientific development.

Mr. J.A. Fixsen, while giving me firm directions, made me feel at home in his Department, taught me how to deal with orthopaedic problems in youngsters, gave me the opportunity to carry out clinical research in Paediatric Orthopaedics, and made me fall in love with the subject: for all this I owe him my gratitude.

Thanks to my colleagues and co-authors in the studies that form part of this thesis: John Fixsen,

Veronica Green, Tudor Hughes, Ian Minty, Rodney Pattinson, Donald Shaw: without them, this thesis would not have been undertaken.

Many thanks are given to the Departments of Medical Illustration of the Institute of Child Health and of the University of Aberdeen Medical School for the help given in the preparation of the illustrations accompanying this thesis.

Although the research was carried out in London, the 'writing-up' phase took place in Aberdeen. The encouragement and understanding of my colleagues and bosses has been instrumental to the peace of mind needed to pursue such a task: thank you.

If the main aim of a thesis is the education of its author, then the present one has surely succeeded in teaching me that team work in Paediatric Orthopaedics is the only way to produce good results, that one has to experience difficulties first hand to be able to tackle them successfully, and that reading is not a substitute for dedicated continuous teaching.

Last, but not least, thanks to Papa', Mamma and Francesco. Papa' and Francesco were close to me as part the family, and, as doctors themselves, forced me to make an effort to get my message through to non-specialist colleagues.



LIST OF FIGURES

	Page Number
2.1. CT and plain scanogram to quantify leg length discrepancy ...	52
2.2. Sequence of application of fixator and corticotomy (A to J) ...	57
2.3. Tibial lengthening .....	70
2.4. Ulnar lengthening .....	72
2.5. Tibia and fibula of a patient with Ollier's disease ...	75
2.6. Femoral lengthening: loosening ...	80
2.7. Fracture through tibial lengthening .....	81
3.1. Radiographic sequence of a tibial lengthening .....	91
3.2. Detail of pin loosening .....	94
3.3. Ragged radiolucent region in newly formed bone .....	97
3.4. Ultrasound scanning of a child ....	102
3.5. Ultrasound scan after corticotomy ..	104
3.6. Ultrasound scan at 10 days .....	105
3.7. Ultrasound scan at four weeks ....	106
3.8. Ultrasound scan at eight weeks ...	107
3.9. Sonolucent area in bone .....	109
3.10. Angulation at lengthened site .....	110
4.1. The chair used to measure the isometric strength of the knee extensor muscles .....	124
4.2. Evolution of maximal isometric strength in the the lower limb ....	128

LIST OF TABLES

		Page Number
2.1.	Characteristics of the patients	..... 48
2.2.	Difficulties encountered	..... 74
2.3.	Overall evaluation of the lengthening process	..... 74
3.1.	New bone formation	..... 92
3.2.	Periosteal reaction	..... 93
3.3.	Pin loosening	..... 95
4.1.	Physical characteristics of the subjects	..... 121
4.2.	Evolution of maximal isometric voluntary contraction strength	..... 127

## PAPERS BOUND IN

This thesis is based on research performed during my period of employment at the Institute of Child Health and at the Hospitals for Sick Children, London, between July 1987 and December 1990. Further research was performed during the following period of employment in London as an Orthopaedic Registrar, from January 1991 to November 1992. The following papers, enclosed in the appendix, are the result of this work:

I. N. Maffulli, T. Hughes, J.A. Fixsen.

Ultrasonographic monitoring of limb lengthening.

Journal of Bone and Joint Surgery (Br)

74-B: 130-132, 1992

II. N. Maffulli, R.C. Pattinson, J.A. Fixsen.

Lengthening of congenital limb length discrepancy using callotasis: early experience of the Hospital for Sick Children.

Annals of the Royal College of Surgeons of England

75: 105-110, 1993

III. V. Green, N. Maffulli, T.H. Hughes. Ultrasound in bone lengthening imaging.

Radiography Today

59: 14-15, 1993

Furthermore, the thesis includes unpublished material.

**CHAPTER 1**

**GENERAL INTRODUCTION**

	Page number
1.1. PURPOSES OF THE THESIS .....	12
1.2. GENERAL INTRODUCTION .....	13
1.2.1. Callotasis .....	13
1.3. REVIEW OF THE LITERATURE .....	15
1.4. CALLOTASIS FOR CORRECTION OF CONGENITAL LIMB LENGTH DISCREPANCY ..	29
1.4.1. Upper limb .....	31
1.4.2. Lower limb .....	35

### 1.1. PURPOSES AND ORGANIZATION OF THE THESIS

From 1987 to 1992, 24 patients completed 25 bone segment lengthening procedures. Twentyone of these lengthenings (twelve femora, nine tibiae) were performed in children for correction of leg length discrepancies. Four children had the ulna lengthened.

This thesis reports the results of a four year longitudinal study of this selected group of patients suffering from congenital limb length discrepancy (LLD). All were treated by callotasis lengthening of their shorter limb according to the technique described by De Bastiani et al. (1987) using the Orthofix monolateral dynamic axial fixator.

The thesis focuses on clinical and radiographic features of the lengthening process, giving details of the problems encountered. Furthermore, a morphological study of the newly generated bone using ultrasonographic scanning (US) is presented. Finally, the isometric strength of the knee extensor muscles of children undergoing femoral lengthening for congenital femoral shortening is examined.

## 1.2. GENERAL INTRODUCTION

### 1.2.1. Callotasis

The callotasis technique is a method of gradual callus distraction based on the principle that bone forms when the tissue between the bone ends undergoes prolonged progressive gradual tension stresses at a slow rate, so as not to disrupt its vascular supply (Ilizarov et al., 1969).

During the distraction period, this tissue is transformed into a network of connective fibres running parallel to the direction of distraction (Tajana et al., 1989). Fibroblasts in this tri-dimensional network of collagen fibres become osteoblasts, and produce bone which is subsequently mineralised (Lascombes et al., 1991).

At the end of the distraction period, with the radiographic appearance of a uniform callus, the fixator is neutralised, i.e. it is locked in a stable position, and full weight bearing is encouraged. The newly formed bony trabeculae increase and become more compact under dynamic loading.

Corticalisation starts at this stage (Aldegheiri, Pouliquen and Agostini, 1992), and dynamisation of the fixator (i.e. loosening of the body of the fixator while it is still in situ) allows progressive corticalisation of the newly formed bone.

The fixator is removed when at least three cortices are seen on radiographs (Maffulli, Pattinson and Fixsen, 1993), although other techniques are being

used to identify this moment more objectively (Eyres, Bell and Kanis, 1993). The screws can be left in place for several days after removal of the fixator until the surgeon is sure that healing is complete (Aldegheri, Pouliquen and Agostini, 1992).

### 1.3. REVIEW OF THE LITERATURE

The literature of callus distraction, or callotasis will be reviewed. Other methods of gradual bone lengthening, such as trans-epiphyseal distraction, or chondrodiatasis (De Bastiani et al., 1986; Monticelli and Spinelli, 1981; Ring, 1958), or 'modern' modifications of older methods [such as Wagner's method (Lee et al., 1993)], although of acknowledged interest, will not be discussed. Non-gradual lengthening involving one or more stages of distraction and subsequent grafting (Ensley, Green and Barnes, 1993) will equally not be discussed. Some of the studies on limb lengthening produced by skeletal traction will be reviewed, as they were instrumental in the development of the present techniques. Indeed, diaphyseal osteotomy and skeletal traction is still considered by some surgeon a simple and inexpensive technique to produce lengthenings of 6 to 16 cm (Yadav, 1993).

Comprehensive reviews on the general subject of limb lengthening have recently been published (Moseley, 1989 and 1991; Paley, 1988; Scott and Saleh, 1992; Sproul and Price, 1992a).

LLD is an obvious deformity, and it is therefore likely that lengthening procedures were devised and practised well before being reported in scientific journals (Moseley, 1991).

To lengthen a limb, surgeons have used several conceptually different approaches. Firstly, growth of



the short bone can be stimulated by various means. Periosteal stripping was first recorded by Ollier (1867), and still practised in the Eighties (Wilde and Baker, 1987). Other techniques include creation of artero-venous fistulae (Janes and Jennings, 1961; Vanderhoeft et al., 1963), sub-epiphyseal implantation of foreign material (Bohlman, 1929; Chapchal and Zeldenrust, 1948; Pease, 1952), sequential surgical insults (Sofield, 1939), lumbar sympathectomy (Harris, 1930; Harris and MacDonald, 1936). All the above methods have had some success, but the lengthening obtained has been, at best, unpredictable.

A second approach has been to lengthen the bone proximal to the short segment. Millis and Hall (1979) described a modified innominate osteotomy for the treatment of postural imbalance. They lengthened the hemipelvis of 20 patients with acetabular dysplasia with ipsilateral femoral shortening, simple LLD, intrapelvic asymmetry, and decompensated scoliosis. Lengthening of 3 cm with the possibility of a variable amount of acetabular redirection was achieved (Millis and Hall, 1979). A similar study in 23 patients reported an average gain in leg length of 2.8 cm (Barry, McManus and O'Brien, 1992). However, a non-resolving residual femoral nerve palsy was reported. Triple innominate osteotomy in 62 patients with leg length discrepancy due to poliomyelitis produced an average lengthening of 1.7 cm, but resulted in a total of three femoral and two sciatic nerve palsies, one

degenerative arthritis of the hip, and one soft tissue infection (Lee et al., 1993). All nerve palsies recovered within 15 months (Lee et al., 1993).

No reports have been published on the strategy of lengthening the bone distal to the shortened one. Such work is ongoing in our Department.

The other approach has been direct mechanical lengthening of the structural bone of the shortened limb. The first report in the English literature using this strategy was published in 1905 by Codivilla. The method was used to correct post-traumatic femoral shortenings, and the stages necessary to achieve mechanical distraction were clearly outlined, consisting of:

1. surgical division of the bone to be lengthened;
2. stabilisation of the divided bone;
3. distraction to achieve the desired length;
4. healing of the distracted area.

Codivilla (1905) performed an open transverse mid-diaphyseal osteotomy of the femur. Distraction was applied through a pin inserted in the calcaneum, and the osteotomy stabilised through a plaster-of-Paris spica cast incorporating the calcaneal pin. After a few days, the cast was divided at the level of the osteotomy, and a further acute distraction performed. The patient was re-plastered, and the process repeated until the desired length had been achieved. The healing stage was accomplished in the plaster-of-Paris spica. The rationale used was of gradual skeletal

lengthening respecting the soft tissues. The original paper does not mention whether the patients were hospitalised for the duration of the process, but, given the Italian practice of the time, it is likely that they were.

Codivilla's main problem was the poor control of the osteotomy site. In 1913, Ombredanne reported a child that he had lengthened using an external fixation device following an 8 cm long oblique femoral osteotomy. The external fixation device was connected to the bone ends by a single screw proximal and a single screw distal to the osteotomy site. The bone was to be lengthened by 0.5 cm per day for eight days, but the procedure had to be stopped on the sixth day due to an area of vascular impairment of the skin. A wound infection complicated the procedure, and the final length gain was 1.5 cm.

Another Italian, Putti (1921), introduced an external fixation device, the osteoton, to apply during the lengthening phase. The osteoton consisted of a large half pin through each of the bone fragments connected to a telescoping tube containing a spring compressed by a screw (Putti, 1921). The device was left in situ for 30 days, and a plaster-of-Paris cast applied. The process probably took place in hospital, and resulted in considerable tilting of the fragments.

In 1927, Abbott used a step-cut osteotomy of the tibia exerting traction through a pin distally, and counter-traction through a proximal ring. Distraction

was produced using a compressed spring contained in a bilateral external frame. The patients were distracted to a maximum of 4 cm over 8 to 10 weeks, and subsequently immobilised in a plaster cast. He recommended that lengthening should be used only as a last resort (Abbott, 1927). Later, Abbott (1932) recommended that two pins above and two pins below the osteotomy site should be used to avoid malalignment of the bony fragments. The apparatus was used with some success also by Haboush and Finkelstein (1932).

Allan (1948) used two Kirschner wires above and two below the osteotomy, a plaster cast cut at the level of the osteotomy, and a screw distraction device that directly lengthened the leg, a process that he called *positive elongation* (Allan, 1948). Lengthening took place at a rate of around 1.6 mm per day, considerably slower than that suggested in earlier techniques.

A similar screw distraction device was used by Anderson (1952), who performed routine lengthening of the Achilles tendon and tibio-fibular synostosis before starting the lengthening process. The rate of distraction was 2.8 mm per day.

A study comparing the healing of oblique, Z and transverse osteotomies showed that there were no significant differences between them (Bost and Larson, 1956). They used a transverse osteotomy, introduced the 'periosteal sleeve' concept, and used a spring loaded lengthener on each side. These authors carried

out the lengthening over an intra-medullary rod, an interesting adjunct used by Westin (1967), and, more recently, by Paley et al. (1992) and by Taschke et al. (1992). The lengthening was continued for up to 30 weeks for a maximum gain of 10.8 cm. Secondary bone grafting was frequently necessary, and late fractures were reported (Bost and Larson, 1956).

More recently, the healing patterns of transverse and 60° oblique osteotomies in canine tibiae under external fixation were compared (Aro, Wahren and Chao, 1991). The oblique osteotomies exhibited a significant lesser degree of axial stiffness, and intra-cortical bone formation was significantly higher in transverse osteotomies. Pin loosening was more prevalent and more severe in the oblique osteotomies (Aro, Wahren and Chao, 1991).

The use of external fixation routinely allowing early weight bearing and discharge from hospital was introduced in the seventies by Wagner (1980), although, in 1968, Kawamura et al. described a device light enough to allow the patients out of bed. Lengthening was accomplished by three to five acute sessions under general anaesthesia (Kawamura et al., 1968).

Wagner (1978 and 1980) used a unilateral external device fixed to the lengthened bone by strong Schanz screws. The technique consisted of a mid-diaphyseal transverse osteotomy without any periosteal-sparing measures, and an elongation rate of 1.5 mm per day

after an acute lengthening of 1 cm (Wagner, 1978 and 1980).

At present, the preferred site of osteotomy is at the metaphyseal-diaphyseal junction, distal to the insertion of the ileopsoas muscle in the femur, and distal to the insertion of the patellar tendon in the tibia (Aldegheri et al., 1992; De Bastiani et al., 1987; Ilizarov, 1989). The preferred level of osteotomy for lengthening of the radius is the distal radial metaphysis (Tetsworth et al., 1991; Villa et al., 1990). In the ulna, the preferred level lies just distal to the coronoid process (Tetsworth et al., 1991; Villa et al., 1990), and in the humerus just distal to the insertion of the deltoid (Tetsworth et al., 1991), at the insertion of the *pectoralis major* muscle (Cattaneo, 1992). In the humerus, if a bifocal lengthening is planned, the distal osteotomy should be performed proximal to the *brachioradialis* muscle origin, taking care not to injure the radial nerve (Cattaneo, 1992).

A recent paper, comparing diaphyseal and metaphyseal osteotomy for femoral lengthening in 23 patients, confirmed that the former does not produce good callus formation, and results in a higher incidence of post-lengthening fracture (Bowen, Levy and Donohue, 1993).

The osteotomy originally described by Codivilla (1905) and Putti (1921) was a simple transverse osteotomy. Subsequently, more complex osteotomies were

described, such as the Z-osteotomy (Dickson and Diveley, 1932) and the long oblique osteotomy (Abbott, 1927). Neither used periosteal-sparing measures. However, in 1940 Harmond and Krigstein limited periosteal stripping to the area of the osteotomy. The technique was perfected by Anderson (1952) and Kawamura et al. (1968). They recommended percutaneous drilling and closed osteoclasis.

Matev (1979a and 1979b) was the first author to describe, in the anglosaxon literature, a transverse sub-periosteal osteotomy through a small skin incision, probably based on Ilizarov's original work, published in Russian (for reference, see Ilizarov 1989), and on Kawamura et al's (1968) method. According to his method, elongation started a few days after the operation, at a rate of 1 to 1.5 mm per day (Matev, 1979a and 1979b). Using his method to correct traumatic length discrepancy in thumb metacarpals, he more than doubled the length of the remaining bony stump (Matev, 1979a and 1979b).

Ilizarov (1989) and De Bastiani et al. (1987) described careful blunt dissection of the periosteum and a subperiosteal corticotomy (also called by Ilizarov a compactotomy). According to De Bastiani et al.'s (1987) technique, a stop was fitted, so that no more than 1.0 cm of drill projected beyond the end of the guide, limiting penetration to the cortex and preventing medullary damage. The holes thus produced around two thirds of the bone circumference were

joined by an osteotome, which was also used to complete the corticotomy separating the remaining parts of the medial and lateral cortex. The strip of periosteum opposite to the original incision always remained intact (De Bastiani et al., 1987). Ilizarov (1989) has described other techniques to produce a corticotomy, using a Gigli saw or a small sharp osteotome. The cortex is cut with a 5 mm wide osteotome taking great care not penetrate the medullary canal to spare the nutrient artery and the medullary circulation. Only two thirds to three fourths of the bone circumference can be cut in this fashion. The remaining cortex must be fractured either by turning the osteotome through 90° to distract the bone ends or by rotating the fixator back and forwards (Ilizarov, 1989; Schwartsman and Schwartsman, 1992). The final clinical result of the De Bastiani et al. (1987) and Ilizarov (1989) techniques appears to be the same (Paley, 1990a; Paley and Tetsworth, 1991).

The maintenance of the medullary canal is not as important as originally thought (Kojimoto et al., 1988). Normal medullary circulation returns within a few days (Kojimoto et al., 1988) following the osteotomy. As most new bone formation results from periosteal membranous ossification, a periosteal-sparing osteotomy is important (Kojimoto et al., 1988). The fact that a corticotomy is no longer considered to be necessary is stressed by the fact that, in the latest version of the Orthofix manual for



limb lengthening, only the word osteotomy is mentioned (Aldegheri, Pouliquen and Agostini, 1992). Ruter and Brutscher (1988) radiologically quantified the difference in bone production between corticotomy and osteotomy. While there were some statistically non-significant differences between 16 and 20 weeks, no differences were found at the end of the distraction period, 30 weeks (Ruter and Brutscher, 1988).

An alternative technique to corticotomy, consisting of percutaneous subperiosteal dissection, passage of a Gigli saw and bone division has recently been described (Paktiss and Gross, 1993). In contrast to 'classical' corticotomy (Paley and Tetsworth, 1991), the endosteum is divided, but the surrounding soft tissues suffer less disruption (Paktiss and Gross, 1993). However, only limited experience is available using this alternative corticotomy technique.

Distraction osteogenesis does not proceed in a strictly sequential manner, and heterogeneous areas are seen in the same specimen (Tajana et al., 1989). The most striking characteristic is that neo-osteogenesis is membranous rather than cartilaginous (Lascombes et al., 1991). Four stages of the osteogenic process can be described, namely colloidal, fibrillar, lamellar and inorganic (Tajana et al., 1989). Bone trabeculae are formed towards the third week of distraction. They are arranged in a mesh-like fashion, and develop an anastomotic network which

rapidly mineralises if the distraction rate is appropriate (Lascombes et al., 1991). Osteoblastic and osteoclastic activity, evident from the beginning (Tachibana et al., 1991), is still intense even one year after the lengthening has been completed (Lascombes et al., 1991).

Acute lengthening (Cauchoix and Morel, 1978; Herron, Asmutz and Sakai, 1978; Magnuson, 1913), used especially to correct post-traumatic LLD, is associated with significant vascular and neurological morbidity (Herron et al., 1978), although recent reports would suggest that it is applicable to selected patients to correct up to 7 cm of shortening (Murray, Kambouroglou and Kenwright, 1993).

Codivilla (1905) acknowledged that soft tissues were the limiting factor in length gain, and Putti (1921) practised the continuous gradual distraction which remains part of the present day method, albeit at a greater rate than that recommended at present.

Bier (1923) observed that, if the osteotomised bone ends were left in contact for 3 to 5 days after the osteotomy and when distraction rate was optimal, the gap was filled by newly generated bone. Despite noticing the phenomenon, neither Putti (1921) nor Bier (1923) appreciated its biological importance, and did not quantify the rate of distraction necessary to reliably induce it. For example, Putti used a distraction rate of 2-3 mm per day to achieve a total of 7-9 cm of lengthening. Given physiological inter-

individual variability, it is likely that some of his patients were able to produce acceptable bone formation even at those high distraction rates.

The present evidence suggests that distraction at a rate of 1 mm per day produces consistently good bone formation (De Bastiani et al., 1987; Ilizarov, 1989). A delay of 5 to 14 days is needed to allow maturation of the distraction zone, protecting endo- and periosteal blood supply (Calhoun, 1992; De Bastiani et al., 1987; Ilizarov, 1989; Monticelli and Spinelli, 1983; White and Kenwright, 1990; White and Kenwright, 1991). Continuous distraction devices have been used to produce daily 1 mm increments over a 24 hour period (Ilizarov, 1989). Early clinical work has showed that a quasi-continuous distraction rate decreased consolidation time (Ilizarov, 1989), and resulted in newly formed bone of very good quality (Korzinek et al., 1990). Continuous distraction would allow an increase in the total daily distraction rate without the ischaemic problems encountered at these higher rates (Ilizarov, 1989). Also, decreasing the rate and increasing the rhythm of distraction decreases the measured tension across the distraction gap (Leung et al., 1979). In clinical practice, the distraction rate used is 0.25 mm four times a day (De Bastiani et al., 1987).

It is necessary to closely monitor the radiographic appearance of the regenerate bone produced and to alter the distraction rate according to its quantity

and quality (Maffulli, Hughes and Fixsen, 1992). In some situations, such as in adults, it is necessary to slow the distraction rate, in others, such as in children with Ollier's disease, it is necessary to accelerate it.

Once the desired length has been achieved, the distraction area must be allowed to heal. Codivilla (1905) used a plaster-of-Paris spica cast, which made the whole process lengthy, and rehabilitation difficult. Anderson (1936) and Abbott and Saunders (1939) controlled the alignment of the lengthened limb in their frame until sufficient callus was formed, and left the limb free thereafter. Wagner (1980) removed the external fixator, and grafted and plated the distraction gap. This approach increases the morbidity of the whole procedure, as it requires a further operation to remove the plate (Wagner, 1980). The stress shielding of the distraction site may produce late fractures (Blachier et al., 1986; Chandler et al., 1988; Guarniero and Barros, 1990; Luke et al., 1992), and the plate may undergo fatigue fracture (Guarniero and Barros, 1990).

More recently, the external fixator has been left in situ until there is evidence of sufficient ossification of the distraction segment (Monticelli and Spinelli, 1981). The dynamic axial fixator of De Bastiani et al. (1987) allows dynamization of the newly formed bone gradually introducing in a controlled manner increasing mechanical loads.

Circular frames should allow axial compression forces to be exerted on the distraction area throughout the whole process, although biomechanical tests depend on the actual configuration of the individual frame being tested (Moseley, 1991). In this respect, a circular frame may provide a biomechanically better environment for consolidation (Aronson and Harp, 1992; Calhoun et al., 1992; Fleming et al., 1989; Kummer, 1992).

To decrease the time of treatment in limb lengthening, Wasserstein (1990) performs a mid-diaphyseal subperiosteal osteotomy. This is externally fixed using a circular fixator, and distracted at the rate of 1 to 2 mm per day over an unreamed flexible intramedullary nail. When the desired length is reached, the distraction gap is allografted with a slotted tubular bone segment. The rationale behind this approach is that the allograft lies in a very vascularised area of the bone, with a high osteogenic potential. This would lead to rapid consolidation and incorporation of the graft by the host (Wasserstein, 1990). The technique has been routinely used in patients up to 25 years of age, and with leg length discrepancy of more than 6 cm. The post-osteotomy treatment protocol does not contemplate weight-bearing during the lengthening phase. This technique has been applied only in one orthopaedic centre in Latvia (Wasserstein, 1990).

#### 1.4. CALLOTASIS FOR CORRECTION OF CONGENITAL LIMB LENGTH DISCREPANCY

The following review of the literature is limited to studies dealing with the results of callotasis in congenital limb length discrepancy, a subject on which relatively few reports have been published. The role of distraction osteogenesis in the management of cranio-facial abnormalities (Rachmiel et al., 1993), although acknowledged, is not going to be reviewed in this thesis.

The results of different studies are difficult to compare due to the different inclusion criteria for the patients, the different classifications for the complications encountered and the results obtained, and the different biomechanical characteristics of the external fixators used. The latter, at least theoretically, could exert a major influence on the biological environment where bone regeneration takes place (Aronson and Harp, 1992; Calhoun et al., 1992; Fleming et al., 1989; Kummer, 1992).

Conditions such as hypo- and a-chondroplasia, mesomelic dysplasia and other form of dwarfism and skeletal dysplasias, although forming the basis of many reports and numerically accounting for the vast majority of the lengthenings reported in the literature (Bell et al., 1992; Bridgman et al., 1993; Correll, 1991; De Bastiani et al., 1987) will not be considered. The results of tarsal and metatarsal lengthening (Boike, Gerber and Snyder, 1993; Magnan et

al., 1988; Nogarin et al., 1988; Steedman and Peterson, 1992; Wakisaka et al., 1988), and of phalangeal (Rosslein, 1993) and metacarpal lengthening (Matev, 1979a and 1979b) will not be reviewed, as they are mostly small series or case reports, and no generalisations can be inferred from them. Upper and lower limb studies will be considered separately, and in order of publication.

#### 1.4.1. Upper limb

Aldegheri and Tessari (1985) described 10 cases of forearm lengthening for radio-ulnar discrepancy. Only two patients were treated using callotasis. A boy of 14 was suffering from diaphyseal aclasis, and a girl of 10 had Ollier's disease. The ulna of the first patient was lengthened 3 cm (16.5% of the initial length), while the other patient had an ulnar lengthening of 1.5 cm (7.5% of the initial length).

In the study of Villa et al. (1990), 12 forearm lengthenings using Ilizarov's technique are reported. Of these, nine were for congenital problems (radio-humeral synostosis, radial aplasia, ulnar aplasia). The lengthenings achieved were from 10% to 143% of the original length of the lengthened bone, and several complications were reported, such as transient pin-related radial nerve palsy, delayed union of the newly formed bone, loss of motion, refractures, transient reflex sympathetic dystrophy). The treatment goal, correction of the LLD, was achieved in all cases.

Cheng (1991) used the callotasis technique and the Wagner apparatus to lengthen the ulna in three patients aged seven, 16 and 13 years, respectively, suffering from multiple exostoses. The distraction was started two weeks after the corticotomy, and the fixator was removed when good cortical union was seen. This ranged from 16 to 22 weeks. Range of movement improved or remained the same in all patients, and the only complication was a superficial pin tract



infection in the 13 year old patient. Recovery was uneventful.

A recent study on the Ilizarov technique reported 19 upper limb lengthenings on 18 patients (Tetsworth, Krome and Paley, 1992). Of these, one humeral and eight forearm (radius and/or ulna) lengthenings were for a congenital condition (Ollier's disease, osteochondromatosis, radial hypo- or a-plasia). The humerus was lengthened 10.4 cm (44% of the original length) using a bifocal technique. Forearm length was increased an average of 5.4 cm (58% of the original length). Function was unchanged or improved in all but two patients, both suffering from radial hypo- or a-plasia, in whom mild loss of finger and/or wrist extension was experienced. A high incidence of complications was reported, all in the forearm lengthenings. These consisted of angulation after removal of the frame, transient radial nerve palsy which resolved after wire removal, premature consolidation requiring a repeat corticotomy, and superficial pin tract infection. The authors conclude that the Ilizarov method allows reliable and safe correction of LLD in the upper limb.

Cattaneo (1992) studied retrospectively a series of patients with arm and forearm lengthening treated with the Ilizarov technique (1989). In 21 patients undergoing humeral lengthening for LLD, one was suffering from multiple exostoses, four from unspecified congenital shortening, one from Ollier's

disease. The results of the 21 humeral lengthenings for LLD are given combined with the results of 38 humeral lengthening for achondroplasia. Total lengthening averaged 8.3 cm, and seven patients experienced a fracture through the newly formed bone. Pin track infections were reported in 21 patients. Only one patient experienced a bad result. In the same study, 20 forearm lengthenings are reported. Of these, the patients with congenital conditions were suffering from lateral hemimelia (four cases), medial hemimelia (three cases), Madelung deformity (four cases), and chondromatosis (one case). The average lengthening achieved was 5.9 cm. Two patients suffered from a fracture through the newly formed bone. Both arm and forearm lengthening were complicated by transient nerve paresis and delay in bone consolidation.

Of a series of eight consecutive humeral lengthenings in seven patients using the Ilizarov technique, only one was for congenital shortening (Sidor et al., 1992). The mean LLD was 10.5 cm, and the mean humeral lengthening achieved was 9.8 cm. In the series, three stress fractures through the regenerate bone occurred, and were treated conservatively. Range of motion of the shoulder and the elbow was not affected by the procedure.

Catagni et al. (1993) published a retrospective study on five adult patients with radial hemimelia who had ulnar lengthening following a wrist centralization and arthrodesis. All patients had successful lengthen-

ing with a gain of 4 to 13 cm, ranging from 19% to 275% of the original ulnar length. The whole procedure lasted 7 to 25 months, and all patients experienced some complications, such as elbow contractures, ulnar nerve paraesthesiae, atrophic new bone, and ulnar nerve neuroma. Although the fingers became stiffer, the function of the arm as a whole was improved. The authors believe that the patients should be told of the length of the procedure, of the high prevalence of complications, and of the loss of motion in the fingers.

#### 1.4.2. Lower limb

Dal Monte and Donzelli (1987) used the Ilizarov system to correct LLD due to congenital causes in 13 limbs. Lengthening ranging from 4 to 11.5 cm, with an average of 36% of the original length, was achieved. Complications were relatively frequent. Superficial infection occurred in five of the 52 wires. They were all treated with antibiotics. The wires broke in three cases. There were six contractures of the knee and five equinus contractures of the ankle. Four contractures had to be released surgically. A transient sciatic nerve paralysis and a case of premature bony union were also reported. Good results are possible, but they require attentive and supportive para-medical staff (Dal Monte and Donzelli, 1987).

De Bastiani et al. (1987), in a study of 100 lengthening procedures in 73 patients, treated 26 segments for a congenital condition by callotasis. No details of the congenital conditions were given, and, from the data presented, it is not possible to differentiate between the results and complications in congenital, post-traumatic and post-infections LLD.

Canuti, Giorgi and Valenti (1988) treated LLD using the Ilizarov technique in 13 patients suffering from fibular hemimelia. Patients were classified in three types (Dal Monte and Donzelli, 1987): nine were suffering from type 1, three from type 2, and one from type 3 fibular hypoplasia. In type 1 patients, the

average lengthening achieved was 5.4 cm, in type 2 the average lengthening achieved was 8.5 cm, in the type 3 patient, a lengthening of 11 cm was achieved. An unspecified number of patients developed an equinus deformity of the ankle during treatment, requiring treatment with a plaster-of-Paris cast. One patient underwent surgical Achilles tendon lengthening.

In a further article from the Verona group (Aldegheri, Renzi-Brivio and Agostini, 1989) on 270 lower limbs, only 33 lengthening procedures were carried out for fibular hypoplasia. The Orthofix system was used in all cases. The results are presented in such a way that it is not possible to separate the congenital from the other categories of patients. Also, it is not clear whether some of these patients had been reported previously (see De Bastiani et al., 1987).

In the only article by the same group specifically dealing with congenital short femur, 18 cases were treated by callotasis (Renzi-Brivio et al., 1990). They had a mean lengthening of 4.8 cm (13.4% of the initial length). Three patients received a closed callotasis due to premature osteotomy consolidation, two patients fractured the regenerate bone, and were treated conservatively, and one suffered from subluxation of the hip. Again, it is not possible to ascertain whether part of these patients had been reported previously (De Bastiani et al., 1987)

Price and Cole (1990) used the Orthofix apparatus

to lengthen four femora (average discrepancy 5.7 cm) and two tibiae (average discrepancy 5.8 cm) in children with congenital LLD. The average length gained was 5.2 cm in the femur and 5.55 cm in the tibia. The authors recognise that the procedure can pose more problems in congenital LLD than in other cases.

Callotasis lengthening using the Ilizarov system was used by Franke et al. (1990) in 13 patients with congenital LLD problems. A further 14 patients with congenital LLD problems were treated by distraction epiphysiolyis (chondrodiatasis) using the same apparatus. Although it is not possible from the data reported to distinguish between the results obtained in congenital, post-traumatic and post-infective LLD, the authors achieved an average lengthening of 8.25 cm with chondrodiatasis and of 7.9 cm with callotasis, with a healing index slightly shorter and a slightly lesser incidence of complications in the chondrodiatasis group. However, they acknowledge that distraction epiphysiolyis should be reserved for a selected group of patients (Franke et al., 1990).

Catagni, Bolano and Cattaneo (1991) reported their philosophy for the correction of leg length discrepancy using the Ilizarov technique in 61 patients with fibular hemimelia. The patients were classified into three types according to Dal Monte and Onofrio (1987). 29 patients were type 1 (in all of whom treatment had been completed), 24 patients were

type 2 (in seven of whom treatment had been completed), and 18 patients were type 3 fibular hypoplasia (in four of whom treatment had been completed). In all patients with type 1 fibular hemimelia LLD had been corrected to within 2 cm. The authors stated that no significant complications had been experienced, and that joint function was satisfactory in all cases. In the seven patients with type 2 in whom treatment had been completed, six underwent independent fibular lengthening to correct ankle instability, and one had a distal tibial osteotomy to correct the position of the foot. One patient experienced a posterior subluxation of the knee during the lengthening process, two patients had residual knee flexion contracture, one suffered from a supracondylar femoral fracture. In the four patients with type 3 in whom treatment had been completed, the complications encountered included three significant residual flexion contractures, four foot deformity relapses, two fractures through the newly formed bone, and one residual oedema of the leg. The authors conclude that the treatment goals were reached in most cases, and that longer follow up is necessary to ascertain whether their approach is at least comparable to the more traditional way of managing the condition.

A French multicentre study on lower limb lengthening using the Ilizarov system reported on a total of 71 femoral and tibial lengthening procedures

in 70 patients (Dasmin et al., 1991). Of these, 20 lengthenings were due to 'malformative' causes, no further details being given of this subgroup. The average tibial lengthening achieved was 67.2 mm (27.3% of the original length), the average femoral lengthening achieved was 82.7 mm (28.6% of the original length). Although no further details are given, the authors recognise that congenital LLD is the most difficult variety to lengthen (Dasmin et al., 1991).

Guidera et al. (1991) reported their experience lengthening 24 patients using the Orthofix dynamic axial fixation system (De Bastiani et al., 1987). The LLD was due to congenital causes in 11 patients, suffering from congenital short femur, fibular hypoplasia, proximal femoral focal deficiency, clubfoot, constriction bands and osteochondromata. Average length gain in congenital patients was 22.4% in the femur, and 22.1% in the tibia. The whole group of 24 patients suffered from 60 complications, and the incidence of major complications per patient was 1.4 in the congenital group and 0.75 in the other patients.

Grill and Dungl (1991) used callotasis to treat 22 patients with unilateral short femur, using the Orthofix dynamic axial fixation system (De Bastiani et al., 1987) in 14, and the Ilizarov circular external fixation system (Ilizarov, 1989) in eight. The lengthening achieved ranged from 15.6% to 142%. The



average elongation achieved in absolute terms was 5.2 cm with the Wagner system, 8.9 cm with the Orthofix system, and 11.7 cm with the Ilizarov system. The authors prefer a distal femoral osteotomy to the classical proximal metaphyseal osteotomy (Aldegheri, Pouliquen and Agostini, 1992), as the former was accompanied by increasing atrophy and rarefaction of the elongated shaft. The patients treated with the Orthofix fixator and proximal osteotomy remained in the fixator 60% longer than the patients treated with the Ilizarov system and distal osteotomy.

Another French multicentre study reported on lower limb lengthening using the Orthofix apparatus (Pouliquen et al., 1991). 41 lengthening procedures out of a total of 97 were carried out for congenital LLD problems. The average lengthening in all patients was 49 mm. A total of 10 fractures through the regenerate bone were reported, but it is not possible to assess the congenital LLD separately.

At the Hospital for Sick Children, Toronto, 11 patients with congenital fibular deficiency underwent tibial lengthening of 12 involved limbs in the period April 1987 to January 1990 using the Ilizarov technique (Miller and Bell, 1992). The average lengthening was 8.3 cm, representing an average lengthening of 31%. All but two patients had bifocal lengthening, and all but one procedure had some form of complication, the most significant being regenerate bone deformation in one patient, a compartment

syndrome in one patient, and delayed consolidation in six others.

Korzinek et al. (1990), in a retrospective study of 118 lengthening procedures using several techniques, treated 17 children with congenital problems using the Ilizarov technique. Given the way the data are presented, it is only possible to infer the results in this subgroup, which appears to achieve reproducible good correction. Contractures were the most common complication.

Between 1984 and 1986, 75 tibial and femoral lengthening procedures were performed in 13 different French centres by 25 surgeons (Merloz, 1992). Although it is stated that 'the primary diagnosis ... were axial malformation and dystrophy' (Merloz, 1992, p. 173), it is not stated what the actual conditions were. In the whole group, consisting of a mixture of children and adults, the average LLD was 6 cm in the children and 5 cm in the adults. The average lengthening achieved was 5.6 cm in the children and 4.5 in the adults. The average duration of the lengthening phase was longer in the adults (103 vs 68 days), as was the average time for bone consolidation (180 vs 150 days). The average time for bone consolidation was on average 30% longer for the tibia than for the femur in both groups. Nerve palsy and axial deviations were the most common complications experienced during lengthening (20 cases in total), while post-lengthening joint stiffness was reported in

15 cases, and 3 patients suffered from a fracture through the regenerate bone.

Of 28 patients (52 lower limb segments) treated at the Royal Hospital for Sick Children in Glasgow and at the Robert Jones and Agnes Hunt Orthopaedic Hospital in Oswestry for leg length discrepancy, seven (six of whom were suffering from a congenital short femur) presented with a congenital condition (Bridgman et al., 1993). Of these seven patients, one was treated by chondrodiatasis. The congenital group is not discussed in detail, but, overall, the planned lengthening was reached in 43 of the 48 patients treated by callotasis. Overall, there were 40 minor complications that did not affect the final result (29 pin tract infections, four premature unions, two equinus deformities of the ankle, two urinary retentions, one delayed union, one hypertensive episode, and one underestimated growth at maturity necessitating a further lengthening), and eight major complications that did affect the end result (four angular deformities, two premature unions, one buckled callus, and one residual extensor hallucis longus weakness).

At the Alfred duPont Institute, Delaware, 83 lower limb lengthenings for congenital shortening (Ollier's disease, congenital short femur, fibular hemimelia, chondrodysplasia punctata) in 74 patients are reported (Karger et al. 1993). The series is non-homogeneous, in that the Ilizarov apparatus and

technique were used in 14 tibiae, and the Wagner apparatus, at times with a modified Wagner technique, were used in the remaining 51 femora and 18 tibiae. In three cases, tibial lengthening was performed using bifocal corticotomy, and three patients had soft tissues release during Ilizarov lengthenings. All patients were treated as in-patients. Although non-statistically significant, the number of operative procedures required to achieve the desired length was lower in the patients treated by Ilizarov's technique. A statistically significant greater complication rate was experienced by the patients in whom lengthening exceeded 25% of the original length (Karger et al., 1993).

Bonnard et al. (1993) performed 26 lower limb lengthenings (18 tibiae and eight femora) in 24 children using the Ilizarov method in the period 1984-1987. Eleven of the limb length discrepancies were of congenital origin, and the average discrepancy was 50 mm (range 12 to 220 mm). No details were given regarding specifically the congenital lengthenings. On the whole, in 18 of the 26 cases, the lower limbs were perfectly equalised, and in 23 of the 26 cases the limbs were equalised within 5 mm. The average lengthening was 47 mm for the femora and 41 mm for the tibiae. The average healing index was 35 days per centimetre. In thirteen cases some complications were experienced, ranging from intra-articular and intra-growth plate placement of the wire to premature fusion

of the newly formed bone. Stiffness of the knee or the ankle was common. It is noticeable that the original Ilizarov protocol was strictly adhered to, and distraction was commenced two days after the corticotomy. The authors acknowledge that callus distraction (De Bastiani et al., 1987) as opposed to haematoma distraction offer better reliability and possibly a lower complication rate (Bonnard et al., 1993).

In conclusion, many more lower than upper limb lengthening procedures using the principle of distraction osteogenesis have been reported. Despite the very low incidence of complications reported by the initiators of the technique (De Bastiani et al., 1987; Ilizarov, 1989; Monticelli and Spinelli, 1983), the patients undergoing limb lengthening for congenital problems are at significant risk of pin tract sepsis, joint contracture, nerve palsies, angular deformities, and fracture through the regenerate bone.

Only a minority of studies focus specifically on limb lengthening for congenital defects. Most series simply include some congenital patients, but it is difficult to retrieve the data, and to infer valid deductions from them.

According to the work of Karger, Guille and Bowen (1993) and Maffulli, Pattinson and Fixsen, 1993, the amount of lengthening with an acceptable complication rate should not exceed 25% of the initial bone length.

Even using circular frames with small pins, practically all patients may be expected to develop at least one complication each, ranging from pin tract infection to the necessity of carrying out additional unplanned operative procedures either during or after the treatment period (Velazquez et al., 1993). The prevalence of major complications seems to be correlated with the complexity and the duration of the treatment (Velazquez et al., 1993).

CHAPTER 2  
CLINICAL STUDIES

	Page number
2.1. INTRODUCTION .....	47
2.2. PATIENTS AND METHODS .....	47
2.2.1. Selection of patients .....	47
2.2.2. Limb length discrepancy measurement .....	51
2.2.3. Operative technique ....	54
2.2.4. Post-operative management ..	66
2.2.5. Evaluation of the lengthening process .....	67
2.2.6. Classification of difficulties encountered during lengthening .....	67
2.3. RESULTS .....	69
2.3.1. Clinical assessment .....	69
2.3.2. Difficulties encountered ...	73
2.4. DISCUSSION .....	82

## 2.1. INTRODUCTION

From 1987 to 1992, 24 patients completed 25 bone segment lengthening procedures using the Orthofix device (De Bastiani et al., 1987). Twenty one of these lengthening were performed in children for correction of leg length discrepancies. Four children had an ulna lengthened. Twelve femora (average discrepancy: 6.9 cm), nine tibiae (average discrepancy: 5.7 cm) and four ulnae (average discrepancy: 27 mm) were lengthened.

## 2.2. PATIENTS AND METHODS

### 2.2.1. Selection of patients

The children were not affected by any form of dwarfism, and all had some form of congenital LLD without associated major valgus, varus or rotational deformities (Table 1). They were originally referred to the Limb Length Discrepancy out-patient clinic of the Hospital for Sick Children by their own G.P. or by their local orthopaedic surgeon. The children had been followed up for several years at the Hospital for Sick Children before they and the families were offered a limb lengthening operation (average 6.5 years, range 3.1 to 11.8 years)

The causative factors and the main characteristics of the patients are summarised in Table 1. Age at operation ranged from 7.1 to 13.4 years (overall average: 10.2 years; 10.8 years in femoral lengthening; 12.1 years in tibial lengthening; 7.6 years in ulnar lengthening).



TABLE 2.1.

Characteristics of the patients.

Patient	Sex	Age at operation	Etiology	Length discrepancy	Length gained	Healing index (day/cm)	Percentage lengthening
<i>Femoral lengthening</i>							
1.	F	7 7/12	CFS	5.5 cm	5.5 cm	27	21
2.	M	9 7/12	CFS	7.5 cm	7.5 cm	28	29
3.	M	10 1/12	Ollier's disease	6 cm	6 cm	28	21
4.	M	9 3/12	CFS	7.5 cm	7.5 cm	29	28
5.	M	10 6/12	CFS	7.5 cm	5.5 cm	32	23
6.	M	9 3/12	CFS	8.2 cm	8.2 cm	29	23
7.	F	8 9/12	CFS	7 cm	7 cm	28	22
8.	M	9 5/12	CFS	6.8 cm	6.8 cm	30	21
9.	M	9 3/12	CFS	6.5 cm	6.5 cm	30	24
10.	M	9 4/12	CFS	7.1 cm	7.1 cm	31	22
11.	F	8 2/12	CFS	6.8 cm	6.8 cm	28	21
12.	F	9 3/12	CFS	6.7 cm	6.7 cm	29	24

CFS: congenital femoral shortening.

Average healing index: 29 days per cm

Average percent lengthening: 23.2%

TABLE 2.1. (ctd.)

Characteristics of the patients.

Patient	Sex	Age at operation	Etiology	Length discrepancy	Length gained	Healing index (day/cm)	Percentage lengthening
<i>Tibial lengthening</i>							
13.	F	5 1/12	Popliteal web syndrome	5 cm	5 cm	31	26
14.	F	13 4/12	Posterior bowing	5 cm	5 cm	51	18
15.	M	10 1/12	Ollier's disease	6 cm	6 cm	28	24
16.	F	11 1/12	CTS	6.7 cm	6.5 cm	32	21
17.	M	13 1/12	CTS	6 cm	6 cm	31	23
18.	F	9 8/12	CTS	6.2 cm	6.2 cm	30	22
19.	M	11 2/12	Popliteal web syndrome	5 cm	5 cm	48	20
20.	M	8 9/12	Ollier's disease	6.3 cm	6.3 cm	29	25
21.	M	9 5/12	CTS	5.7 cm	5.6 cm	31	23

CTS: congenital tibial shortening.

N.B. Patient 3. and 15. had a simultaneous ipsilateral femoral and tibial lengthening.

Average healing index: 34.5 days per cm

Average percent lengthening: 22.4%

TABLE 2.1. (ctd.)

Characteristics of the patients.

Patient	Sex	Age at operation	Etiology	Length discrepancy	Length gained	Healing index (day/cm)	Percentage lengthening
<i>Forearm lengthening</i>							
22.	F	7 3/12	DA	26 mm	26 mm	39	19
23.	M	8 6/12	DA	30 mm	30 mm	37	18
24.	M	7 1/12	DA	24 mm	24 mm	39	20
25.	M	7 4/12	CSU	28 mm	28 mm	38	20

DA: diaphyseal aclasis.

CSU: congenital short ulna.

Average healing index: 38 days per cm

Average percent lengthening: 19.2%

### 2.2.2. Limb length discrepancy measurement

Prior to surgery, all patients were evaluated clinically and with plain radiographs of both limbs and/or plain or CT scanograms (Figure 2.1.). Although associated with low inter-tester reliability, the anthropometric tape remains the instrument routinely used to evaluate LLD during an orthopaedic examination (Friberg et al., 1988).

Absolute leg length was measured with the patient lying supine from the anterior superior iliac spine. Two measurements were recorded: one to the medial malleolus, and the other to the heel. Care was taken to accurately identify the correct bony landmarks, and to consistently align the anthropometric tape on the defining landmarks (Hoyle et al., 1991). As leg length inequality measurement in the supine position may overlook a functional inequality that is evident only in the standing position, after anthropometric tape measurements were taken, wooden blocks of different thickness were inserted under the short leg while two surgeons monitored pelvic tilt from the front and the back of the patient (Gofton, 1985). The thickness of the inserted blocks required to level the pelvis both from the front and the back of the patient measured leg length discrepancy.

Forearm length was measured using the anthropometric tape with the child resting the forearm in midpronation on a flat surface. The bony landmarks used to measure length discrepancy were the tip of the

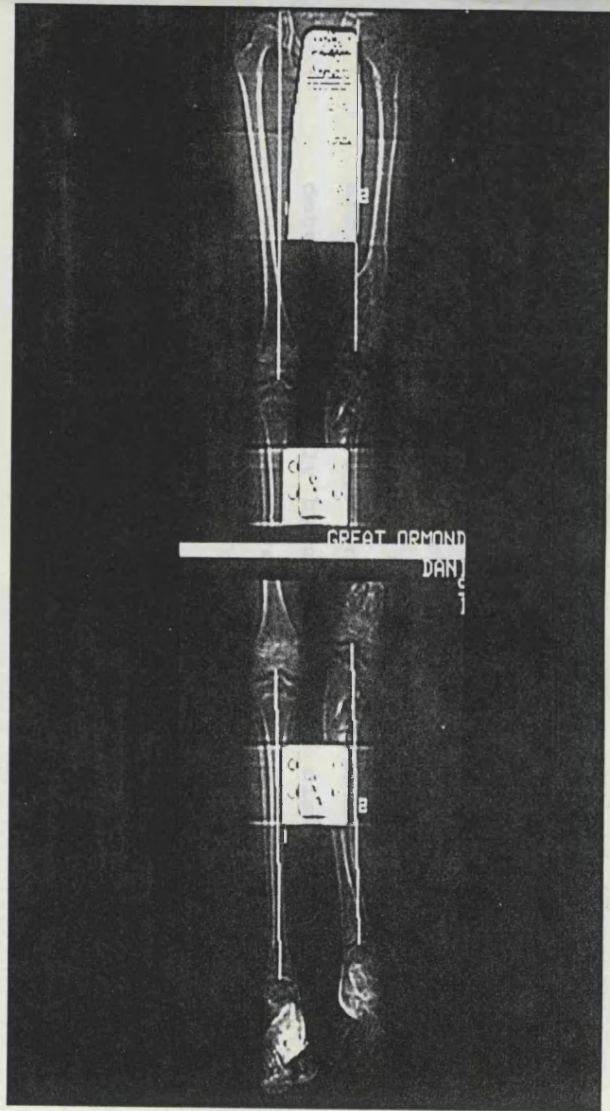
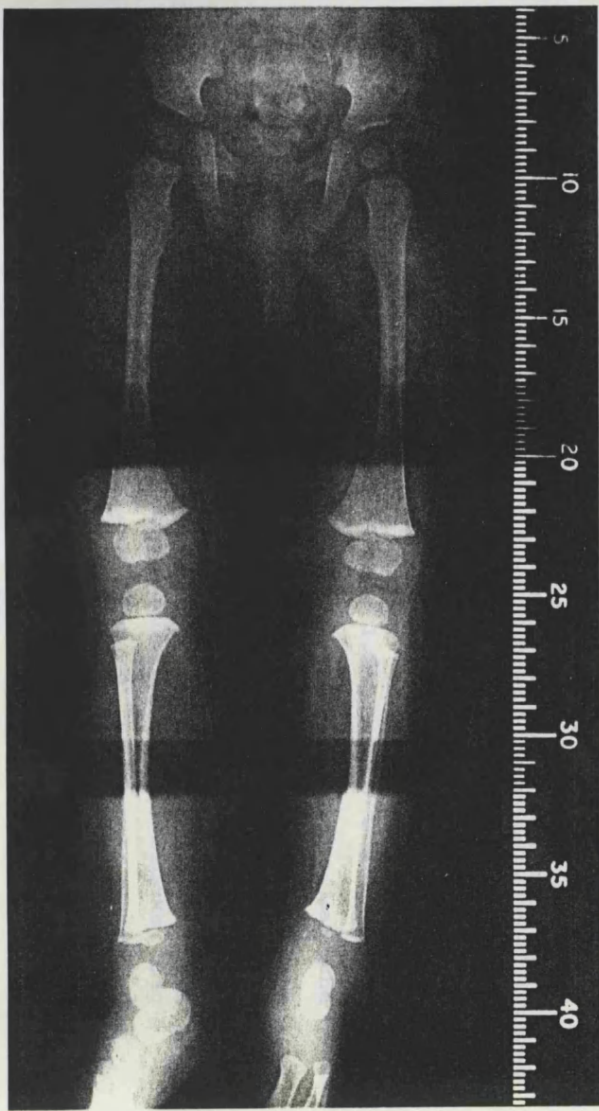


Figure 2.1. CT and plain scanograms used to quantify leg length discrepancy.

olecranon and the tip of the ulnar styloid (Cameron, 1984). The same landmarks were used when radiographic measurements of the forearm were performed.

All patients presenting with leg length discrepancy also had their leg length measured on plain antero-posterior radiographic scanograms (Fisk and Baigent, 1975). On these, femoral length was determined manually by measuring the distance between the centre of the femoral head and the centre of the femoral condyles. Tibial length was measured manually as the distance between the midpoint of the tibial spines and the midpoint of the medial surface of the lateral malleolus and the lateral surface of the medial malleolus on the inferior tibial articular surface.

In 14 patients, an antero-posterior lower limbs CT scanogram was also taken (Huurman et al., 1987), and femoral and tibial length were determined by a computer programme using the same criteria used to measure plain scanograms (Figure 2.1.).

The radiographic measurements were always of a lesser magnitude (on average 1.2%, range 0.8 to 1.5%) when compared to the anthropometric measures, as the former did not measure the soft tissues, which account for part of the measured shortening.

For operative planning, the LLD considered was the one measured anthropometrically and on blocks. Leg length discrepancy at the time of surgery ranged from 5 to 12 cm (6.9 cm in femoral lengthenings, 5.7 cm in

tibial lengthening), and the average forearm length discrepancy was 27 mm.

### 2.2.3. Operative technique

The operative technique used was that described by De Bastiani et al. (1987), Ilizarov et al. (1969), and Paley et al. (1990), and already reported by our group (Maffulli et al., 1992 and 1993). All procedures were performed under sterile conditions and using an image intensifier. In general, two proximal and two distal screws were used, unless the body of the fixator had to be placed more than three cm away from the skin, in which case an extra screw was applied both proximally and distally.

#### *Callotasis of the femur*

The leg was draped separately, so that it could easily be moved. In the femur, cortical screws (4.8 mm drill and 6.5 mm screws) were used.

The first screw was inserted under image intensifier guidance on the lateral aspect of the femur, just above the lesser trochanter, taking care not to penetrate the hip joint capsule. The pin was inserted through a 1 cm stab wound going through the skin and the fascia lata. The soft tissues were separated by blunt dissection, and the lateral cortex of the upper femur was thus reached. A pointed trocar was inserted through a screw guide and tapped over the lateral cortex of the femur in order to engage it. The trocar was removed, and a drill guide was inserted in the screw guide. A drill was inserted in the drill

guide, and both the lateral and the medial cortices of the femur were drilled, taking care that the direction of drilling was perpendicular to the longitudinal axis of the femur. The screws were inserted so that at least one thread was protruding from the medial cortex.

The above procedure was performed for all the remaining screws, using a template. When all the screws had been inserted, the fixator was attached to them. The fixator was distracted three mm, so as to preload it without stressing the compressor/distractor unit or the pin-bone interface.

The femoral corticotomy was then performed one to two cm distal to the most distal of the proximal set of screws. The femur was routinely exposed using an anterior or a lateral skin incision five to eight cm long. Using an anterior approach, the space between tensor fascia lata and sartorius was identified and developed. The space between rectus femoris and vastus lateralis was identified and developed, and the femur identified. Using a lateral approach (Figure 2.2.), the fascia lata was divided longitudinally, the vastus lateralis was divided along the direction of its fibres, and the femur identified. Both using an anterior and a lateral approach, the periosteum was divided longitudinally, and carefully lifted from the femoral shaft. A 3.2 mm drill with a drill guide was used to perform the corticotomy. The drill stop was set in a way that it engaged the whole diameter of the



bone. A series of transverse drill holes were made across the bone. The anterior, medial and lateral sides of the femur were then connected with an osteotome, which was then used to divide the postero-medial and postero-lateral corners. At this stage the bone ends gently became separate. Separation was confirmed manually inserting a flat blunt instrument and by plain radiography.

The periosteum was closed when possible, and the wound closed with a suction drain. The suction drain was generally kept closed unless bleeding was evident. The drain was opened every three hours to check for bleeding. The hip and the knee were flexed to 90°, and the fascia and the skin at the pin sites released if too tight. The pin incisions were carefully dressed, and the drain removed on the first or second post-operative day. A photographic sequence of a femoral legthening is given in Figure 2.2.

Figure 2.2. A. to J. The sequence of application of the fixator and corticotomy in a child with congenital femoral shortening.

Figure 2.2. A. Using a template, a hole is drilled in the femur.

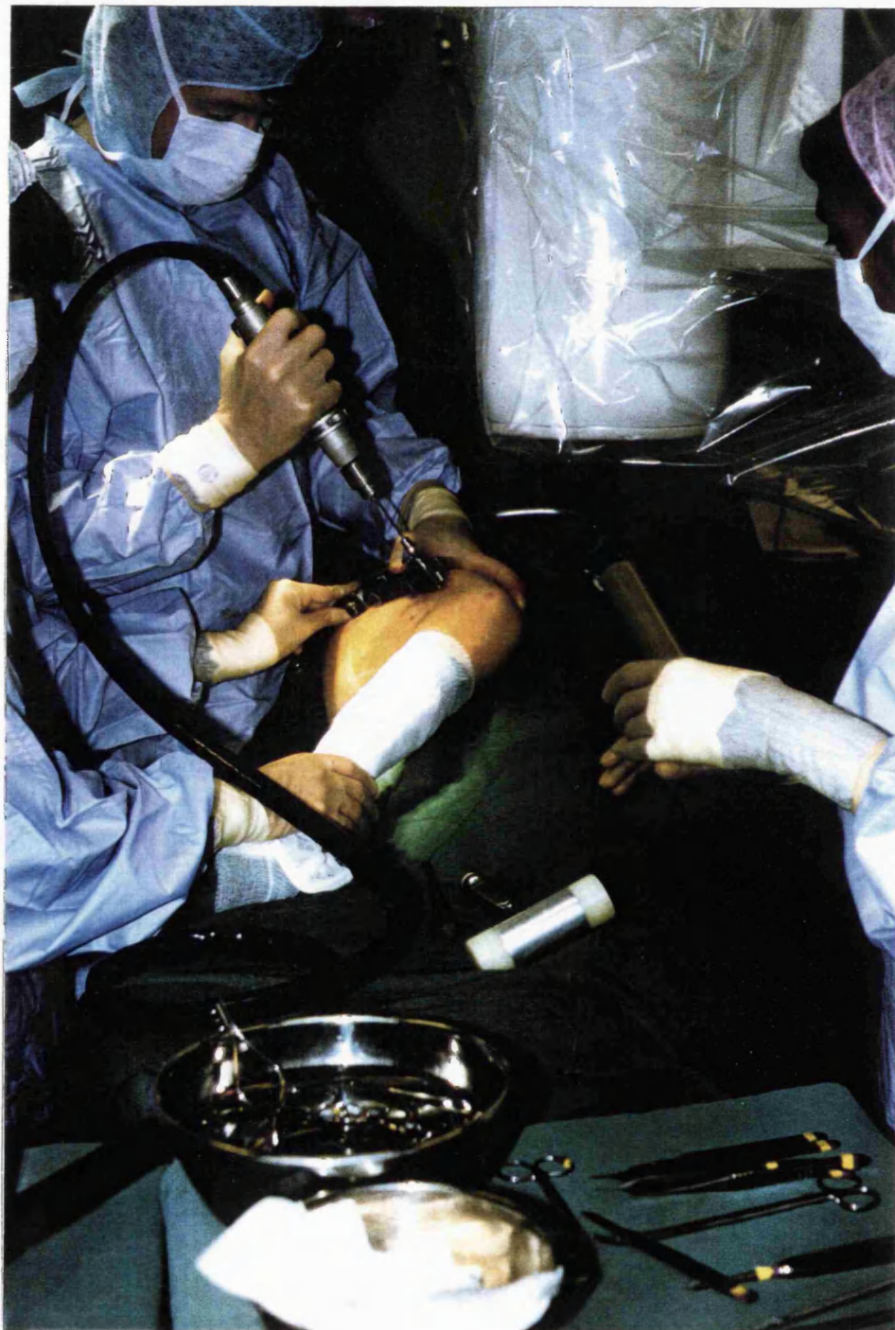

Figure 2.2. B. Screws are inserted by hand.

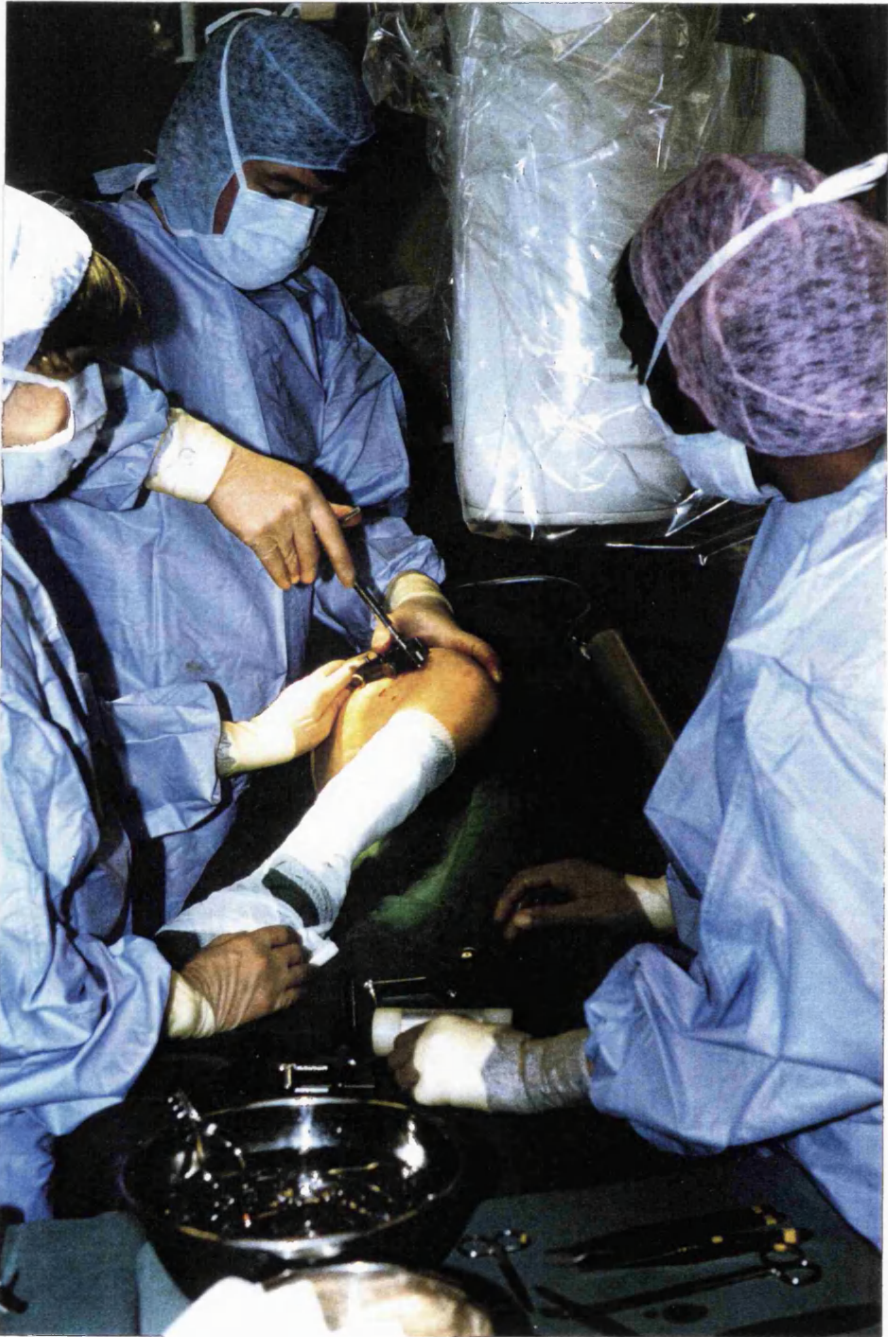

Figure 2.2. C. After the most distal screw, the most proximal is inserted, always using the template.

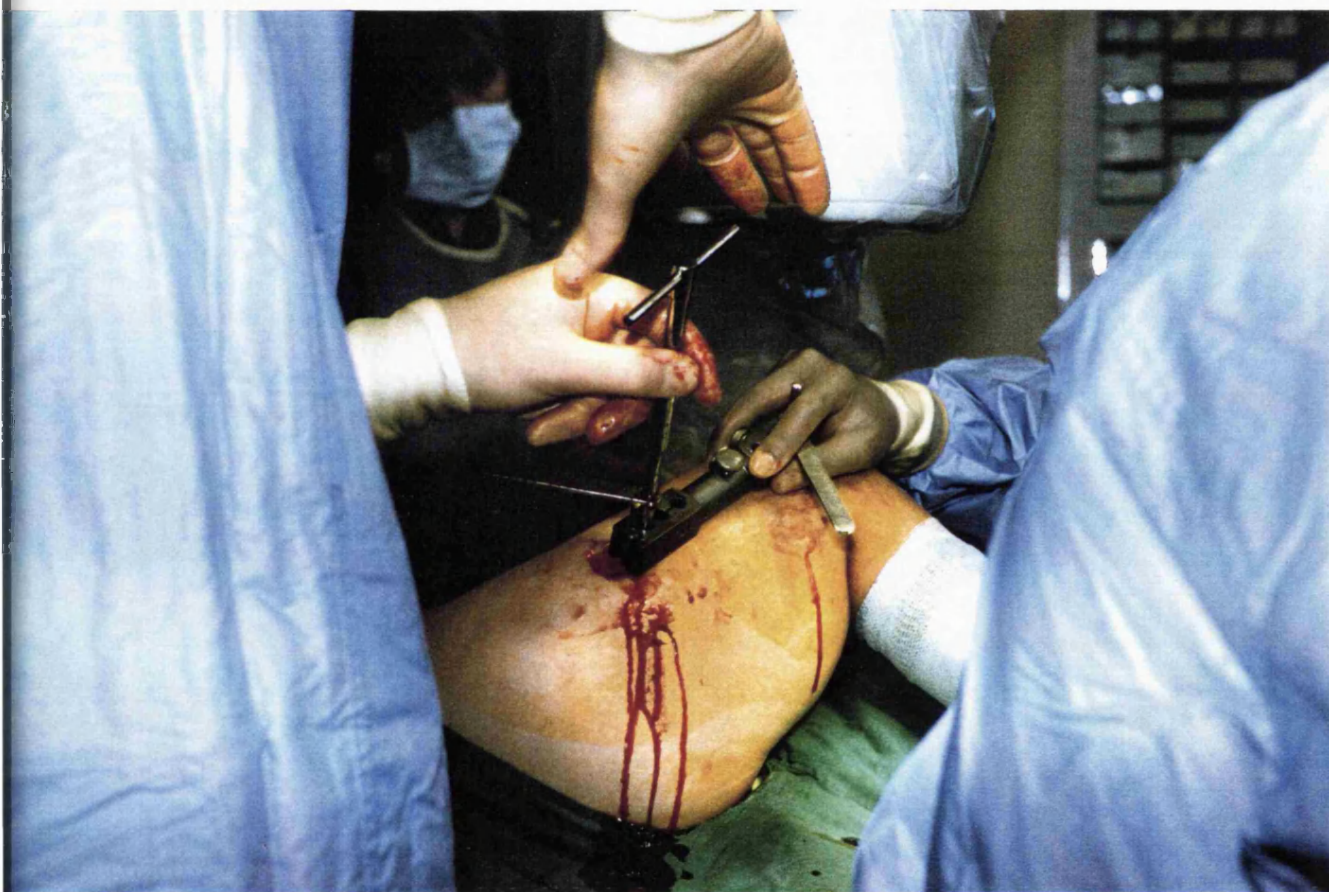


Figure 2.2. D. All screws are in place.

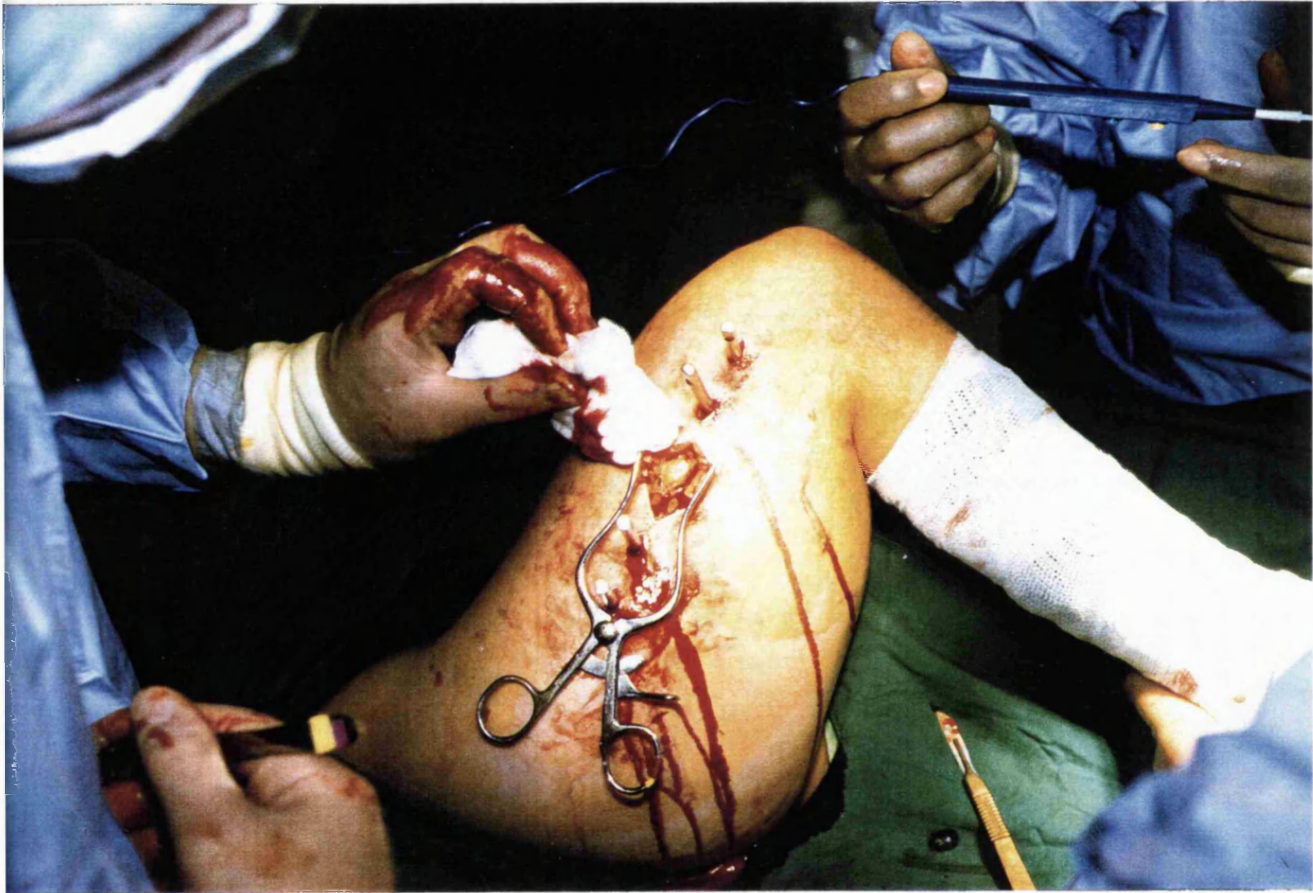


Figure 2.2. E. The femur is exposed through a small lateral incision.

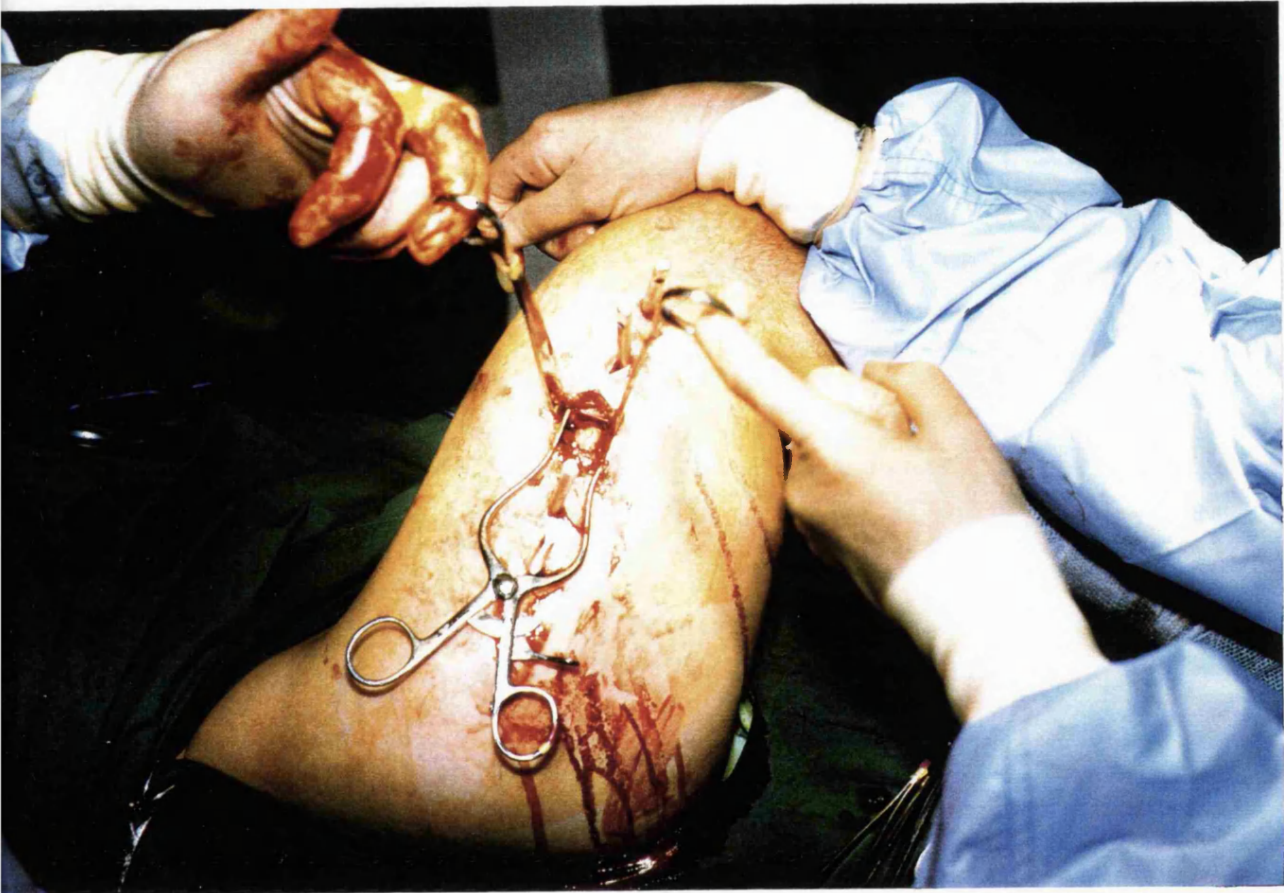

Figure 2.2. F. A series of transverse drill holes is made in the femur.

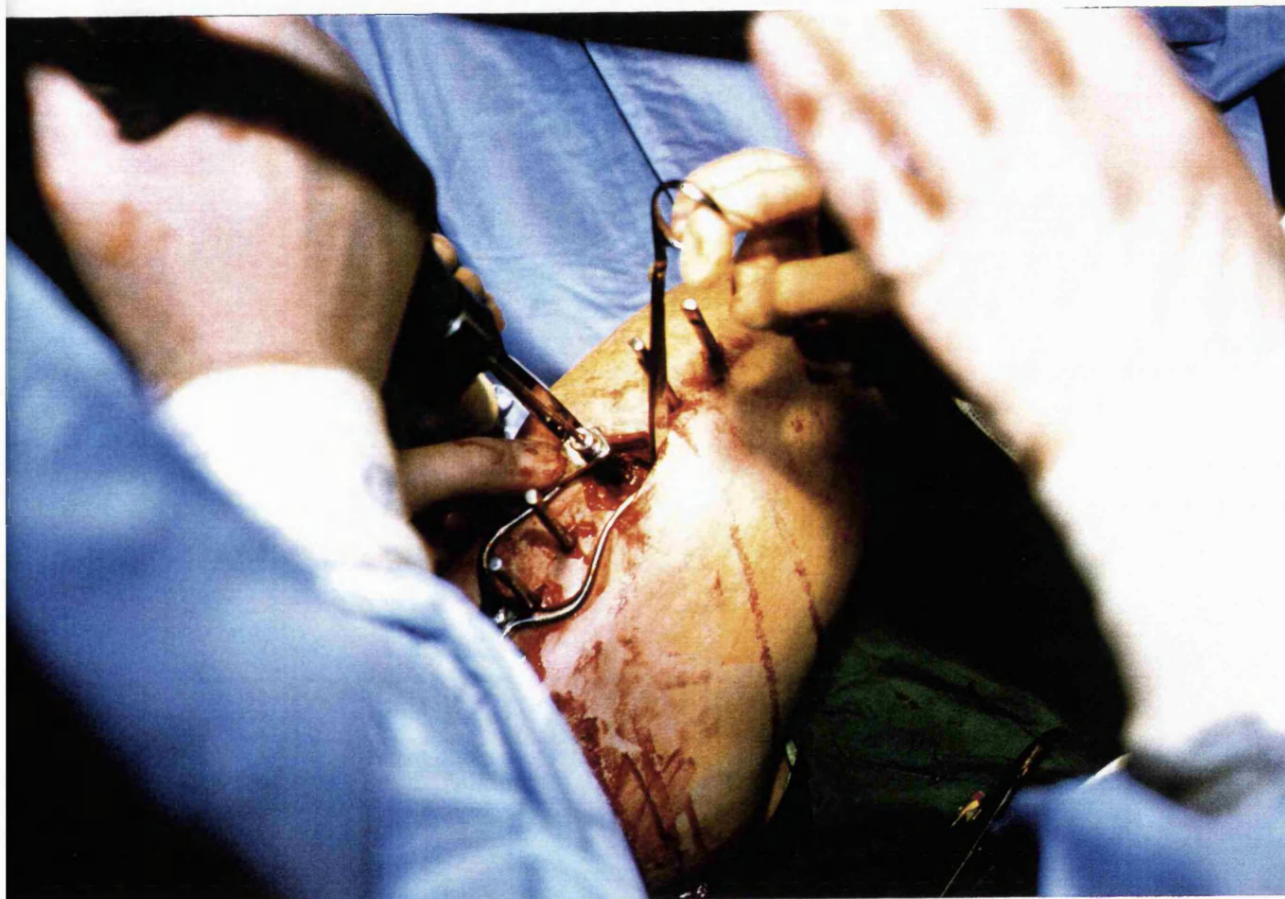


Figure 2.2. G. The holes are connected with an osteotome.

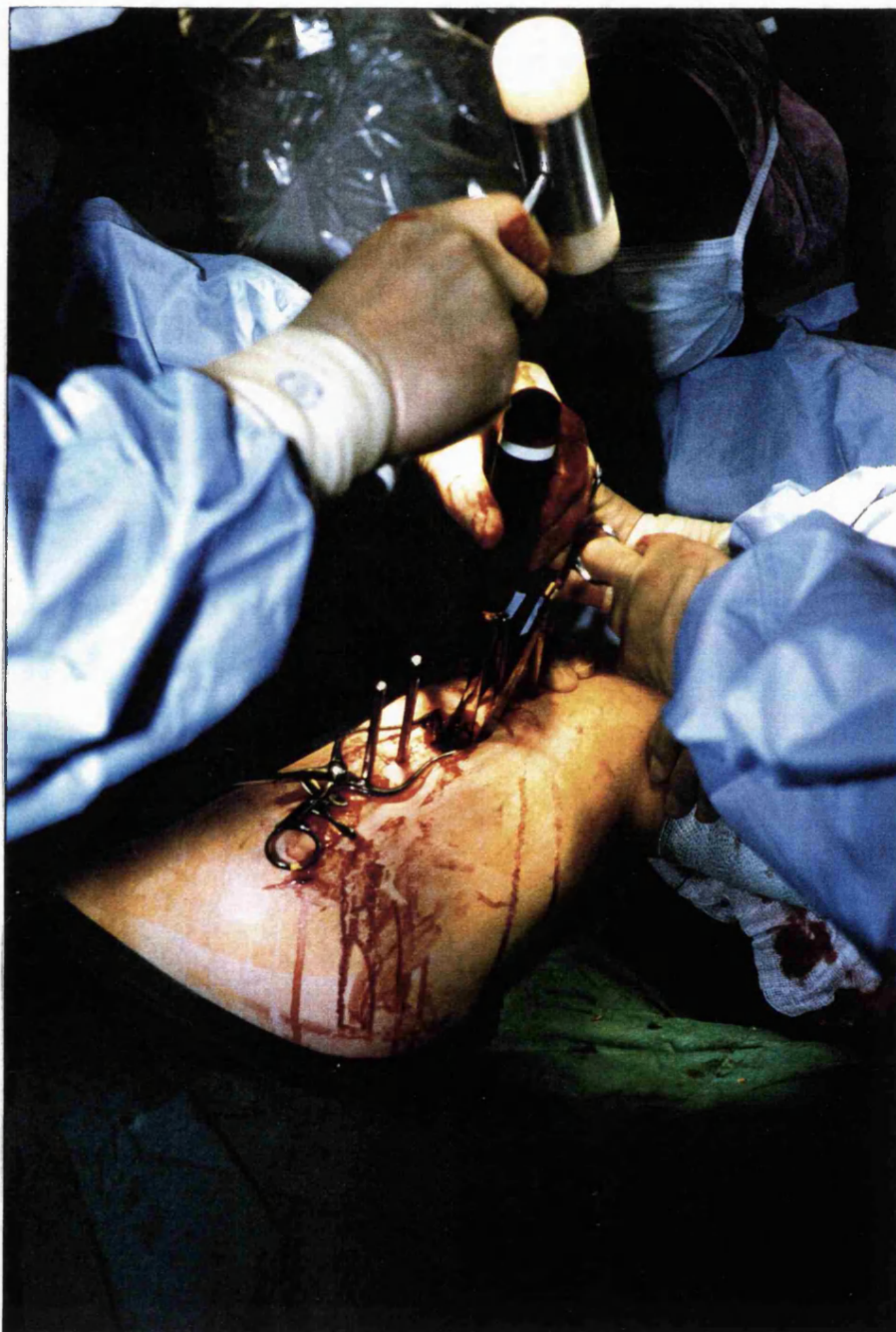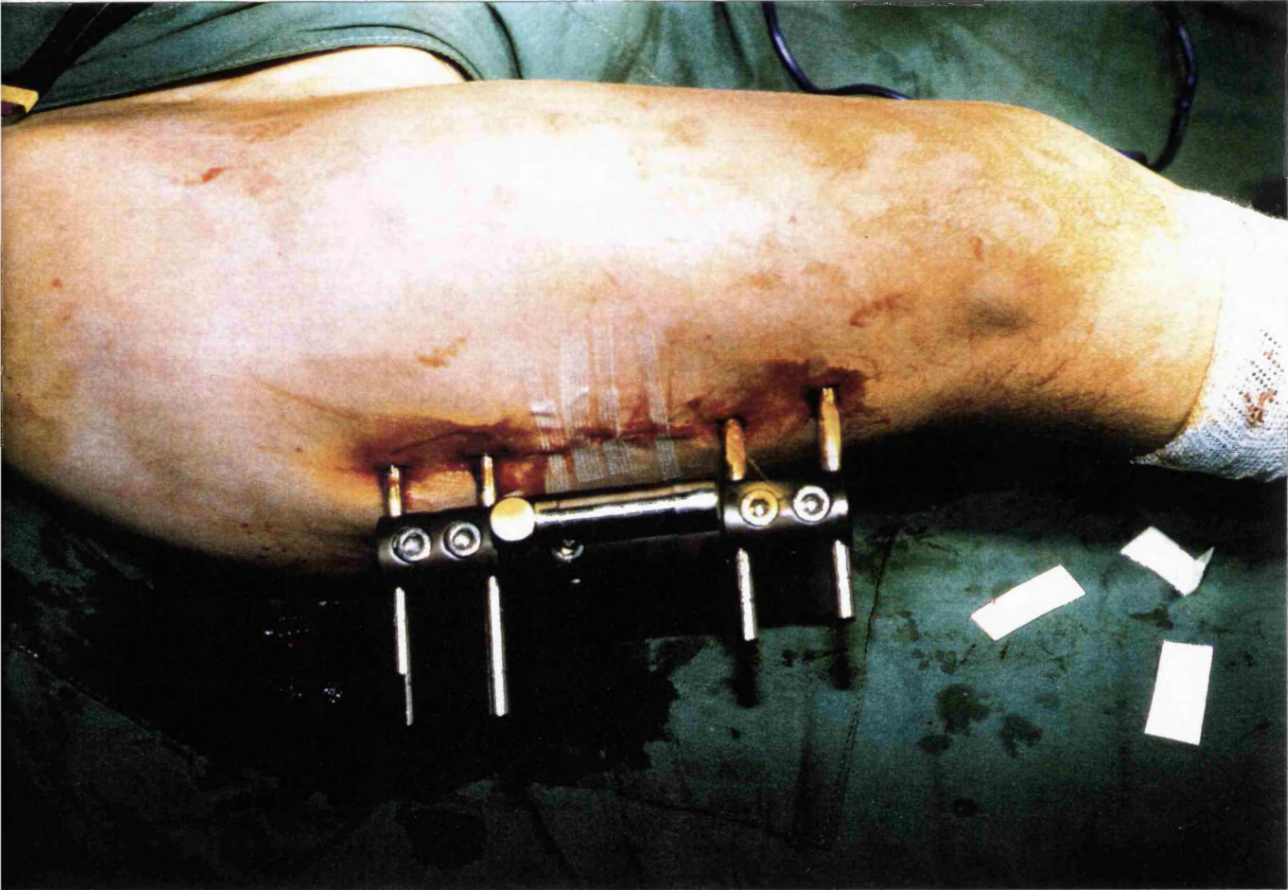




Figure 2.2. H. The femur undergoing osteoclasis.

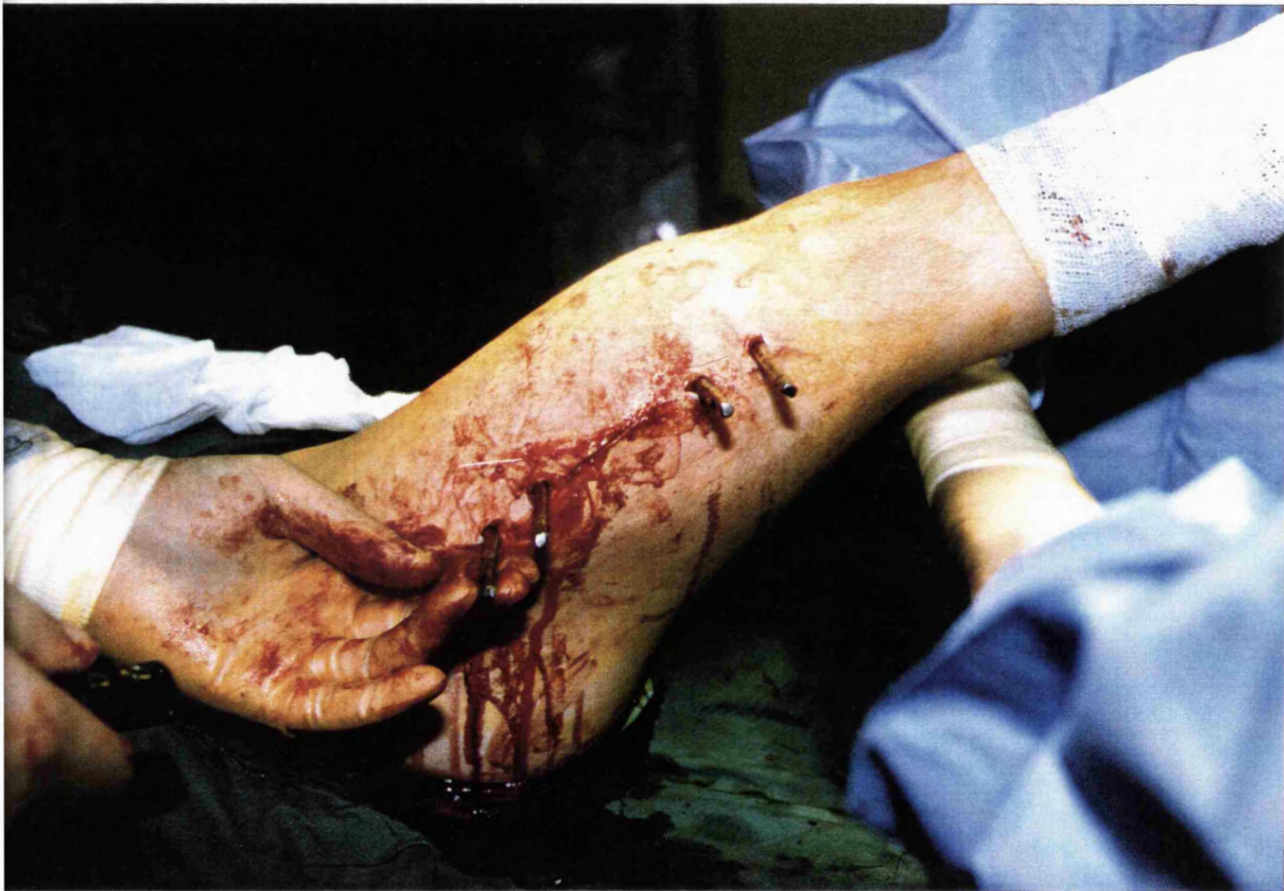

Figure 2.2. J. The fixator in situ.



### *Callotasis of the tibia*

The same general principles were applied when lengthening the tibia. The fixator was applied antero-medially, and the proximal screw was a cancellous screw. Two cm of the lower fibula were removed through a small lateral incision before applying the fixator.

### *Callotasis of the ulna*

In general, the procedure followed the same lines as in the femur and tibia. The ulna was approached through a small longitudinal dorsal incision, and the fixator applied dorsally.

#### 2.2.4. Post-operative management

The patients were allowed to mobilise partially weight bearing with the lengthener locked. The pin tracks were checked at least daily so as to keep them clean and draining freely. The patients and their families were taught how to do this, and how to massage the skin around the pins to prevent adherence of the pins to the skin.

Distraction was applied seven to 10 days after the initial corticotomy (White and Kenwright, 1990). The patients and their families were taught how to perform the lengthening, which routinely took place at the total rate of 1 mm per day, divided into four quarter turns.

All children required regular physiotherapy to mobilise and keep mobile the joints proximal and distal to the bone segment lengthened (Green, 1990). Children were discharged home when comfortable, and,

if they were undergoing a lower limb lengthening procedure, when they were able to use crutches confidently. The indications for re-admission or prolonged admission were unreliable children or parents, unremitting pain, pin site infection not responding to oral antibiotics, contracture of joint proximal or distal to the lengthened bony segment, and the necessity to change a fixator which had reached its maximum length.

#### 2.2.5. Evaluation of the lengthening process

Clinical and radiological evaluation of the patients and of the problems encountered was carried out at weekly to two-weekly intervals (Paley, 1990a). The process of lengthening was evaluated radiographically, using both radiography (Vade and Eissenstat, 1990; Young et al., 1990b) and ultrasound scanning (Young et al., 1990a; Maffulli, Hughes and Fixsen, 1992). Details of these studies are given in other parts of this thesis.

The healing index was calculated dividing the time in days from the initial corticotomy to the removal of the fixator (or of the plaster cast when this had been used) by the amount of lengthening obtained in centimetres.

#### 2.2.6. Classification of difficulties encountered during lengthening

According to Paley's (1990b) classification, a problem was defined as a potentially expected difficulty arising during the distraction or fixation

period that is fully resolved by the end of the treatment period non-operatively.

An obstacle was defined as a potentially expected difficulty arising during the distraction or fixation period that is fully resolved by the end of the treatment period operatively.

Complications were defined as a local or systemic intra- or peri-operative complication, or a difficulty during distraction or fixation that is not resolved by the end of the treatment period. True complications were further divided into those interfering with the original goals of treatment and those that did not.

## 2.3. RESULTS

### 2.3.1. Clinical assessment

Limb length discrepancy was successfully corrected in all but one patient, in whom, due to a persistent superficial infection, the fixator was removed and a residual discrepancy of two centimetres was accepted.

#### *Femoral lengthening*

The average femoral lengthening achieved was 6.75 cm (range 5.5-8.2 cm), with an average healing index of 29 days. The average percentage lengthening achieved was 23.2%. In one case, when the distractor was locked in the fully extended position, it bent forming an angle of about 170°. As the amount of lengthening required had been achieved, it was decided not to change the distractor, and accept the position with some varus angulation at the lengthening site.

#### *Tibial lengthening*

The average tibial lengthening was 5.6 cm (range 5-6.5 cm), with an average healing index of 34.5 days. The average percentage lengthening achieved was 22.4%. All but one patient were protected in a below knee walking plaster-of-Paris cast for one month after the fixator had been removed, although the radiographic appearance at the time of fixator removal showed full bridging. An examples of successful tibial lengthening is given in Figure 2.3.

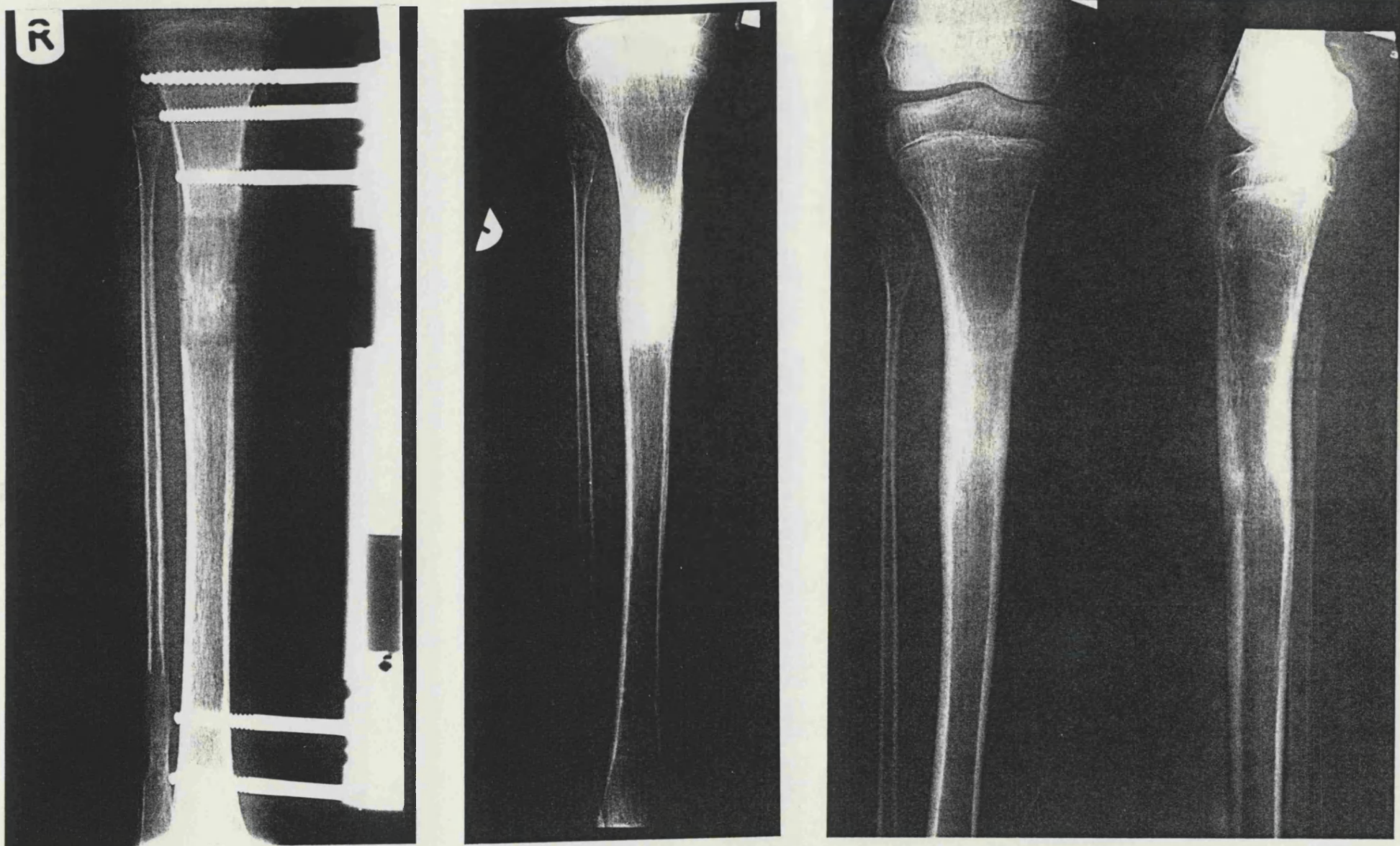


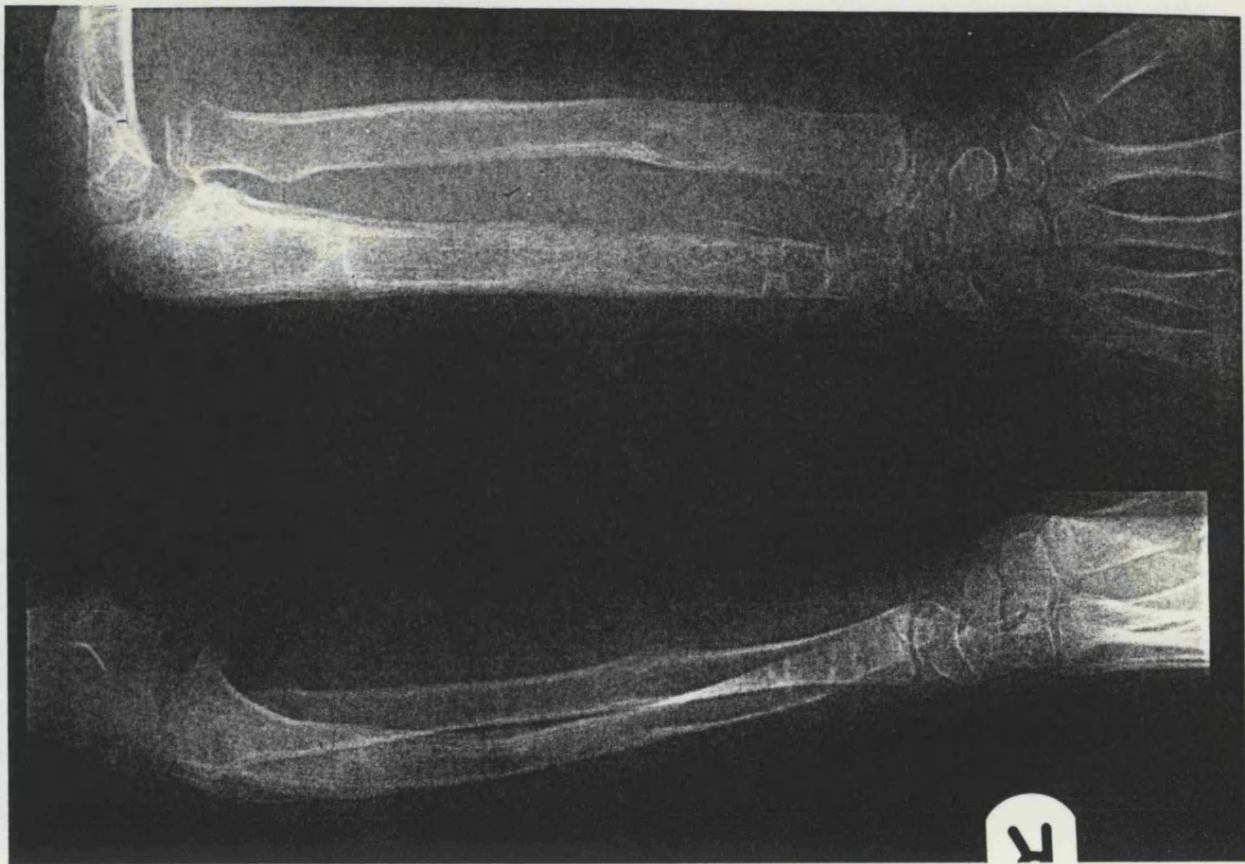
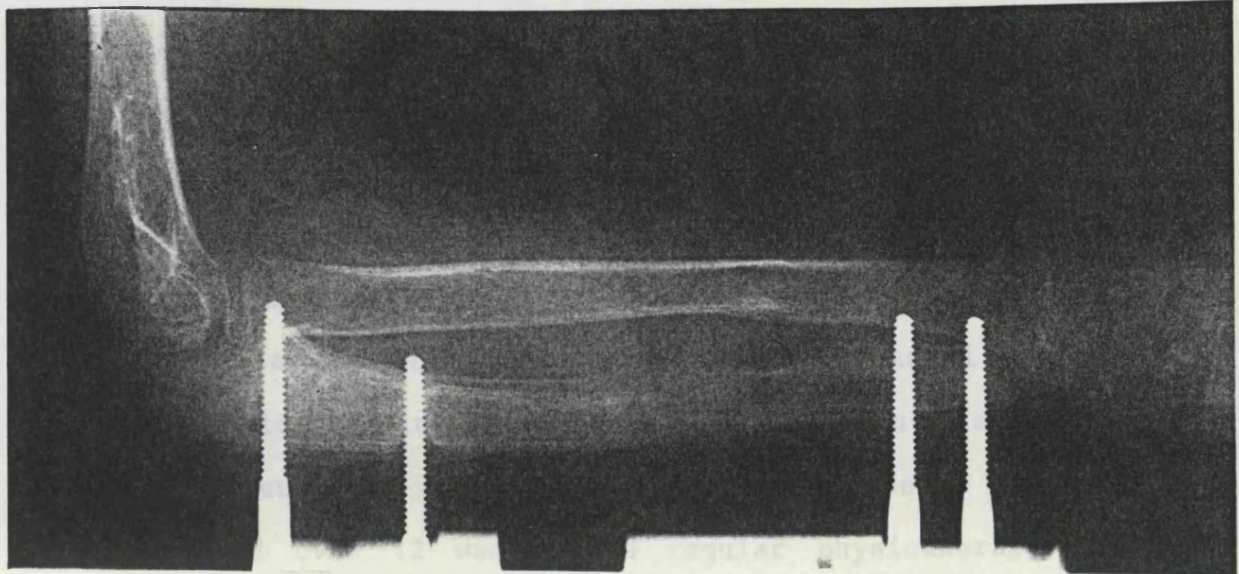
Figure 2.3. Successful tibial lengthening in a girl with congenital short tibia. A. During the consolidation phase. B. Three months after removal of the fixator. C. Eighteen months after removal of the fixator. The medullary canal is nearly fully formed.

### *Ulnar lengthening*

The average ulnar lengthening was 27 mm, and the healing index was 38 days per centimetre. The average percentage lengthening achieved was 19.2%. An example of ulnar lengthening is given in Figure 2.4.



Figure 2.4. Ulnar lengthening for congenital short ulna. A. At the end of the distraction period. B. Two months after removal of the fixator. At this stage, function was full, with some restriction of pronosupination movements.



### 2.3.2. Difficulties encountered (Table 2)

*Problems.* Despite regular daily local cleansing, all children developed superficial infection at the pin sites. These were treated by local cleansing, dressing and oral antibiotics. The radiographic signs of pin site problems is discussed in another section of this thesis.

*Obstacles.* In two cases (one femoral and one ulnar lengthening), the families were unreliable, and the children needed admission to supervise the initial lengthening period.

In a boy undergoing simultaneous femoral and tibial lengthening for Ollier's disease, a flexion contracture of  $30^{\circ}$  at the knee developed. This resolved over 12 weeks with regular physiotherapy. Lengthening was stopped for one week, but this did not interfere with the final result of the process (Figure 2.5.).

**TABLE 2.2.**

**Difficulties encountered**

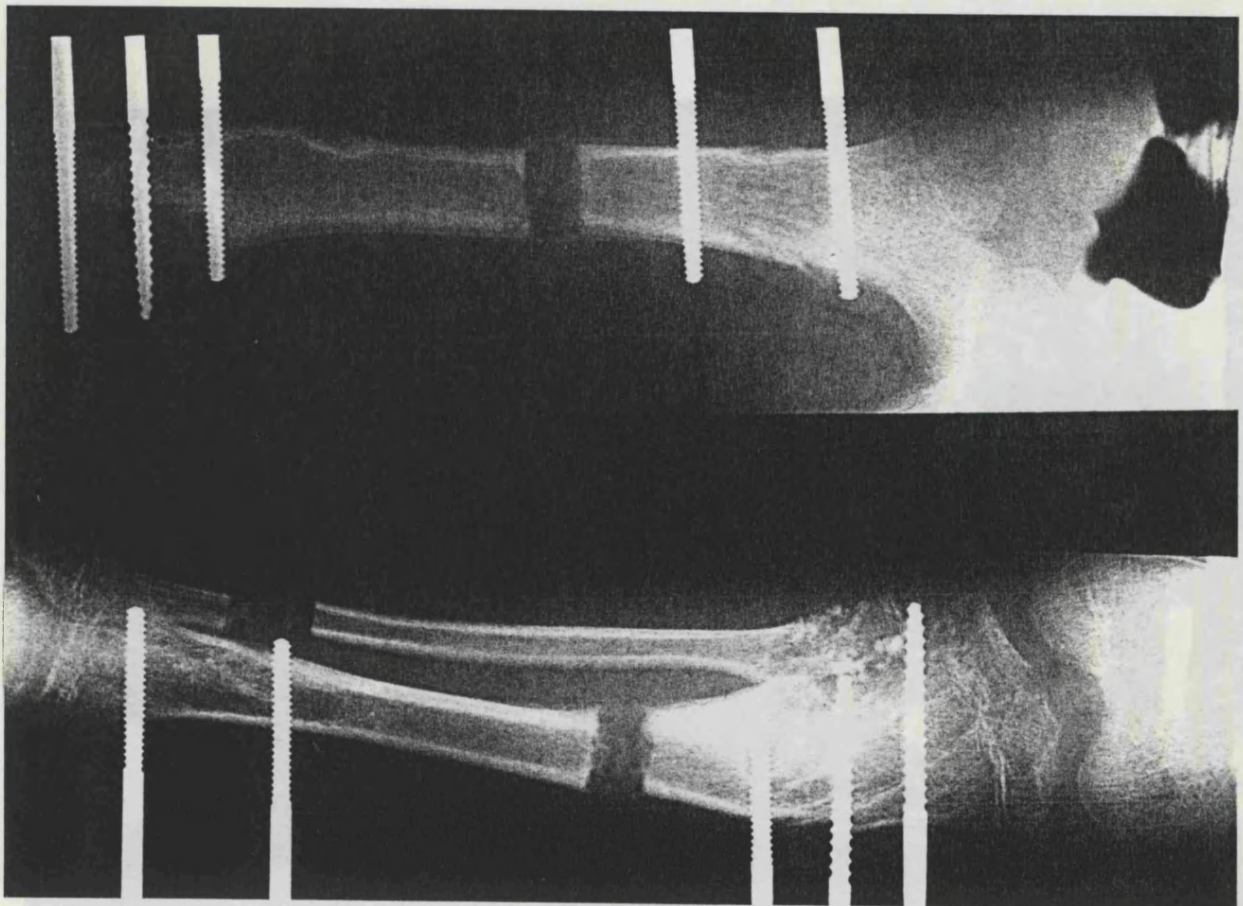
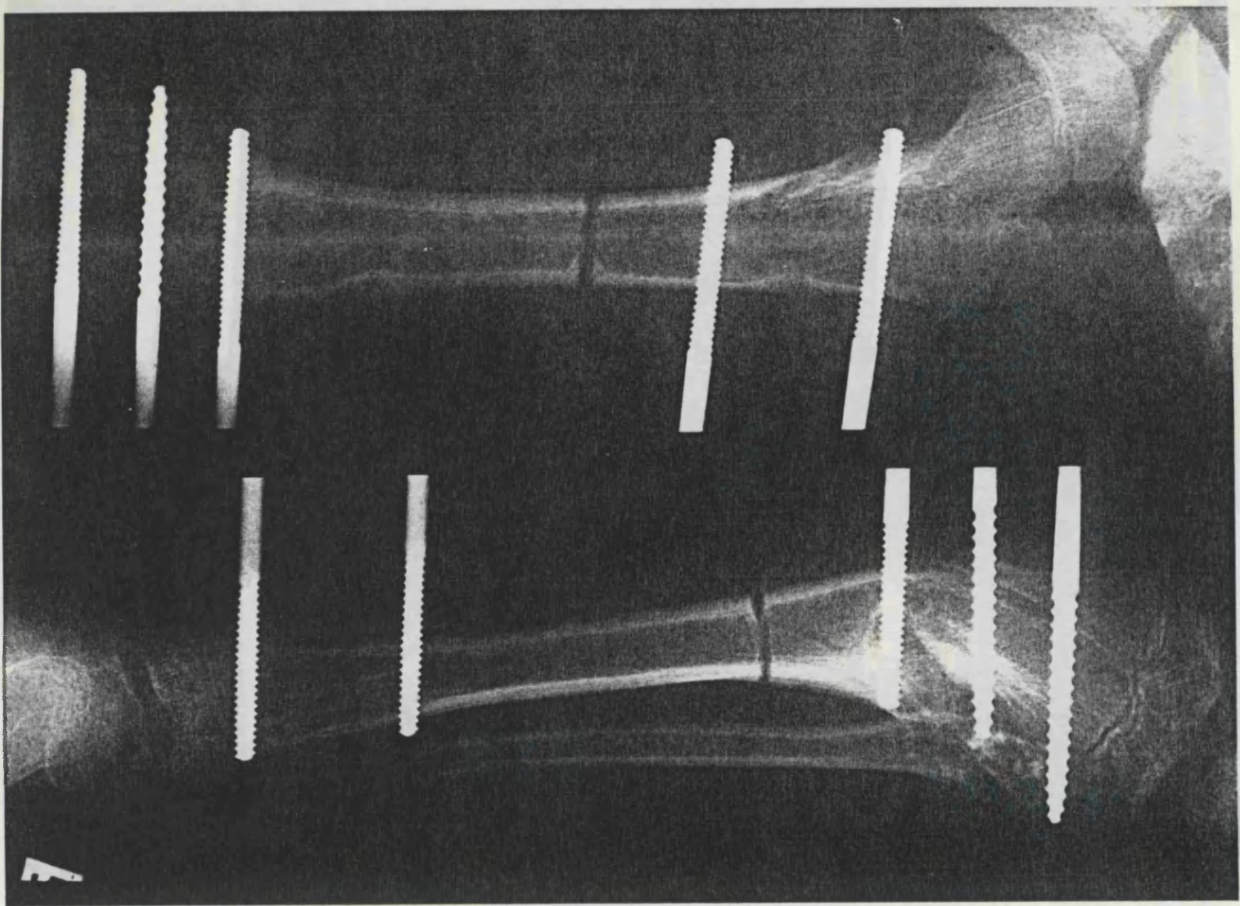
	Problems	Obstacles	Complications
Femur	12	1	3
Tibia	9	1	1
Ulna	4	1	-

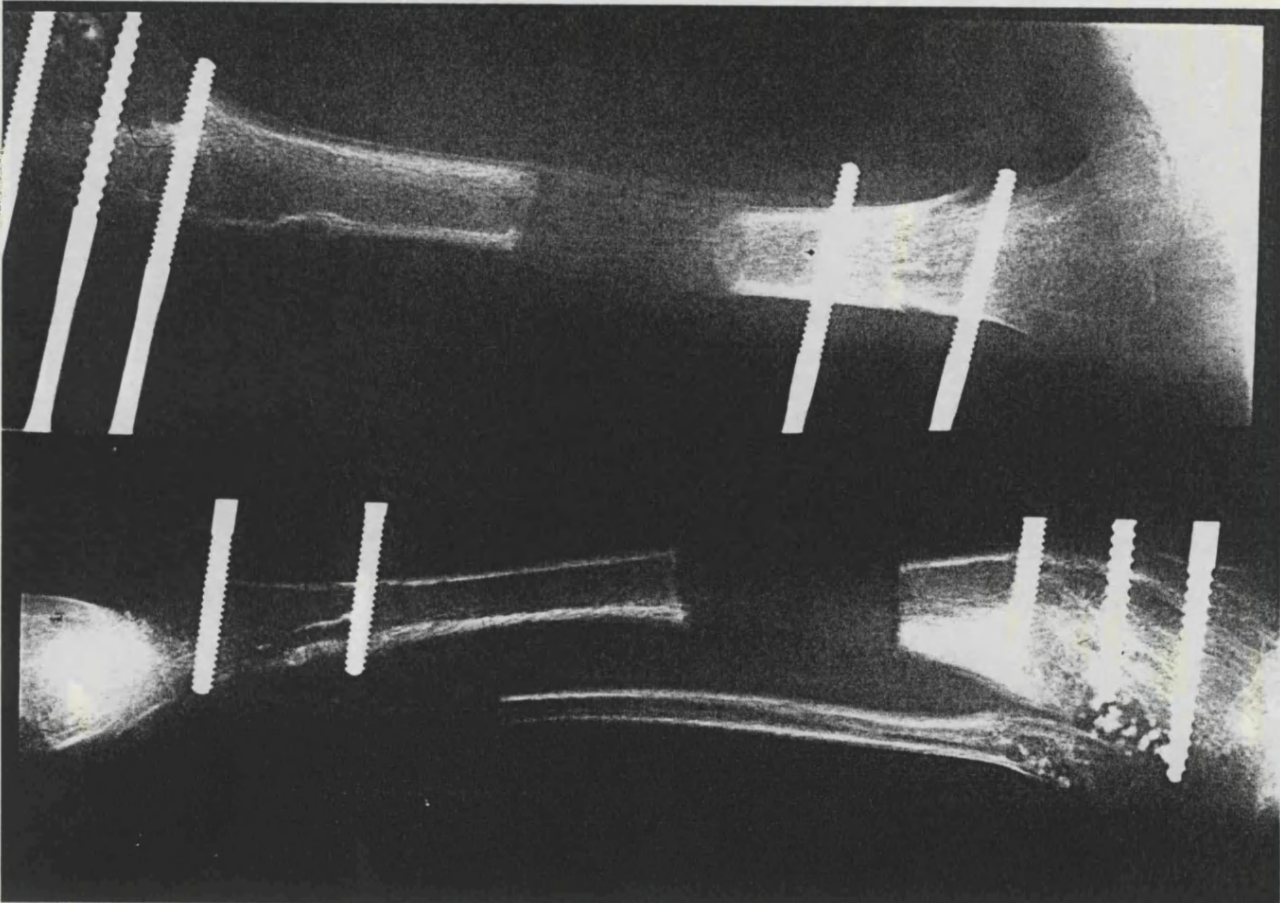
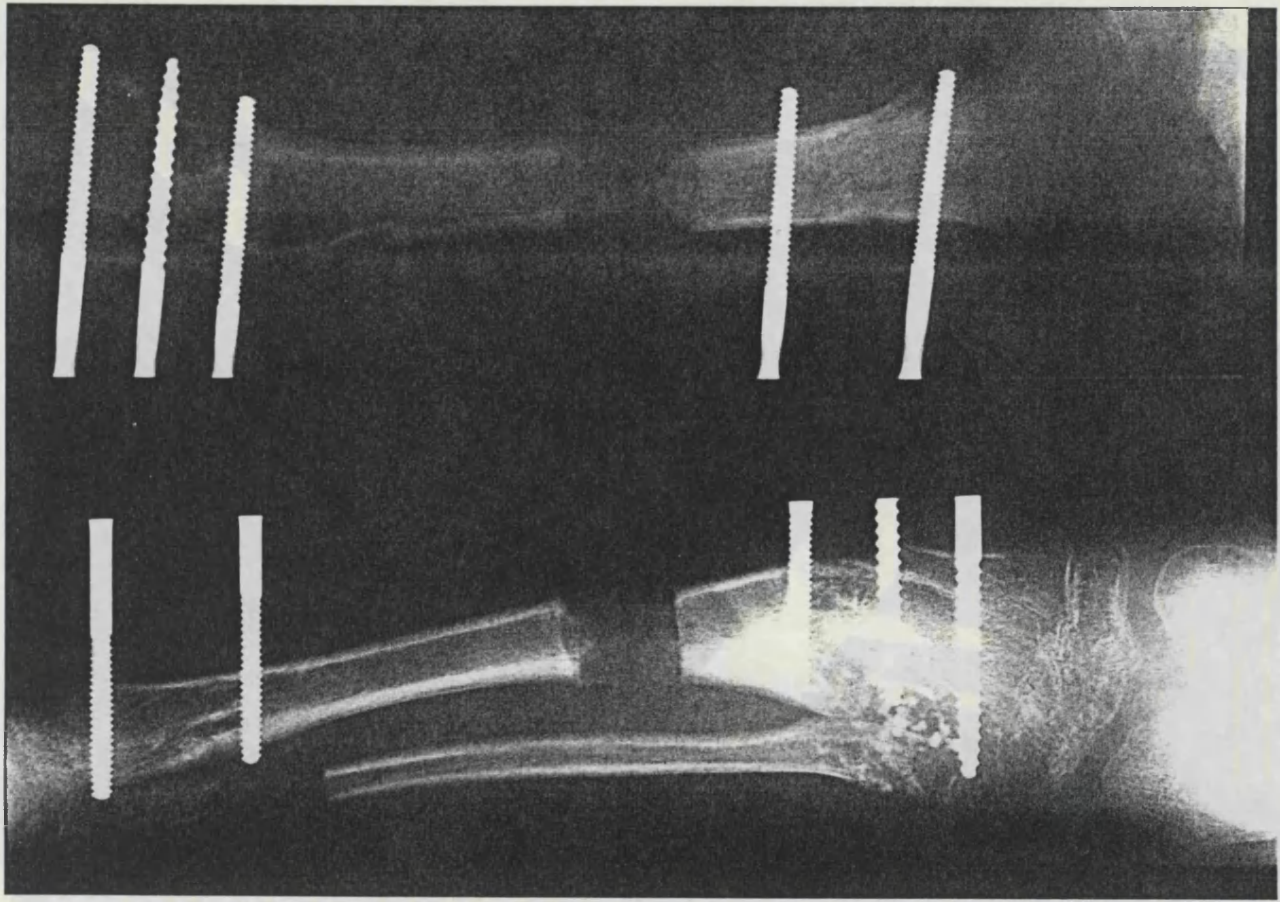
**TABLE 2.3.**


**Overall evaluation of the lengthening process.**

	<i>Average</i>	<i>Range</i>
Discrepancy (cm)	5.83	2.4 - 8.2
Gain (cm)	5.6	2.4 - 8.2
Healing index (days per centimetre)	32.52	27 - 51
Discrepancy (%)	23.2	18 - 29
Gain (%)	21.6	18 - 29
Surgical procedures per patient	1.2	1 - 3

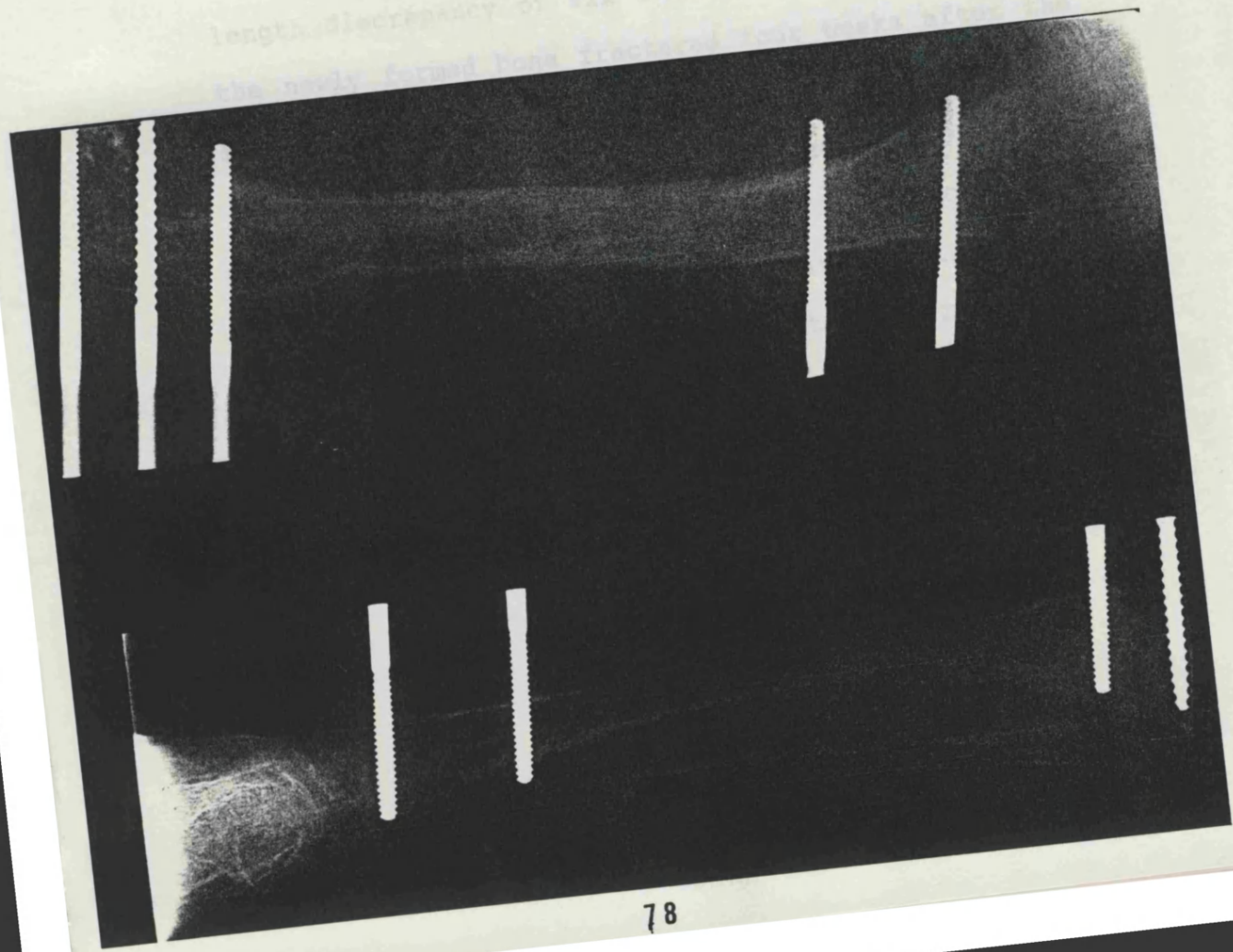
Figure 2.5. Boy undergoing femoral and tibial lengthening for Ollier's disease. Initially, no problems were encountered. Towards the end of the lengthening period, a flexion contracture of  $90^{\circ}$  at the knee developed. This resolved over 12 weeks with regular physiotherapy. Lengthening was stopped for one week, but this did not interfere with the final result of the process







lengthening for osseous short limb with a leg  
length discrepancy of six or more skeletal accuracy.  
The body formed here illustrates the



*Complications.* In one femoral lengthening, it was possible to detect an area of bone erosion around the more proximal of the two distal pins. This was associated with periosteal elevation medially (Figure 2.6.). The fixator was removed for a persisting infection, and the femur protected in a long leg plaster-of-Paris back slab for two weeks. Oral antibiotics were given and an intramedullary rod inserted when the pin sites were healed. A residual discrepancy of two centimetres was accepted.

In three children undergoing femoral lengthening, the fixator was exchanged under general anaesthesia because its maximum excursion had been reached. Lengthening proceeded uneventfully.

In the first patient undergoing tibial lengthening for congenital short tibia with a leg length discrepancy of six cm near skeletal maturity, the newly formed bone fractured four weeks after the removal of the device. He was treated conservatively in a plaster-of-Paris cast for ten weeks. Recovery was uneventful (Figure 2.7.). This experience prompted us to protect all tibial lengthening patients in a below knee walking cast for four weeks after the removal of the fixator.



Figure 2.6. Femoral lengthening. It is possible to detect an area of bone erosion around the more proximal of the two distal pins, associated with periosteal reaction medially. The fixator was removed for a persisting infection, and the femur protected in a long leg plaster-of-Paris back slab for two weeks. Oral antibiotics were given and an intramedullary rod inserted when the pin sites were healed. A residual discrepancy of two centimetres was accepted.

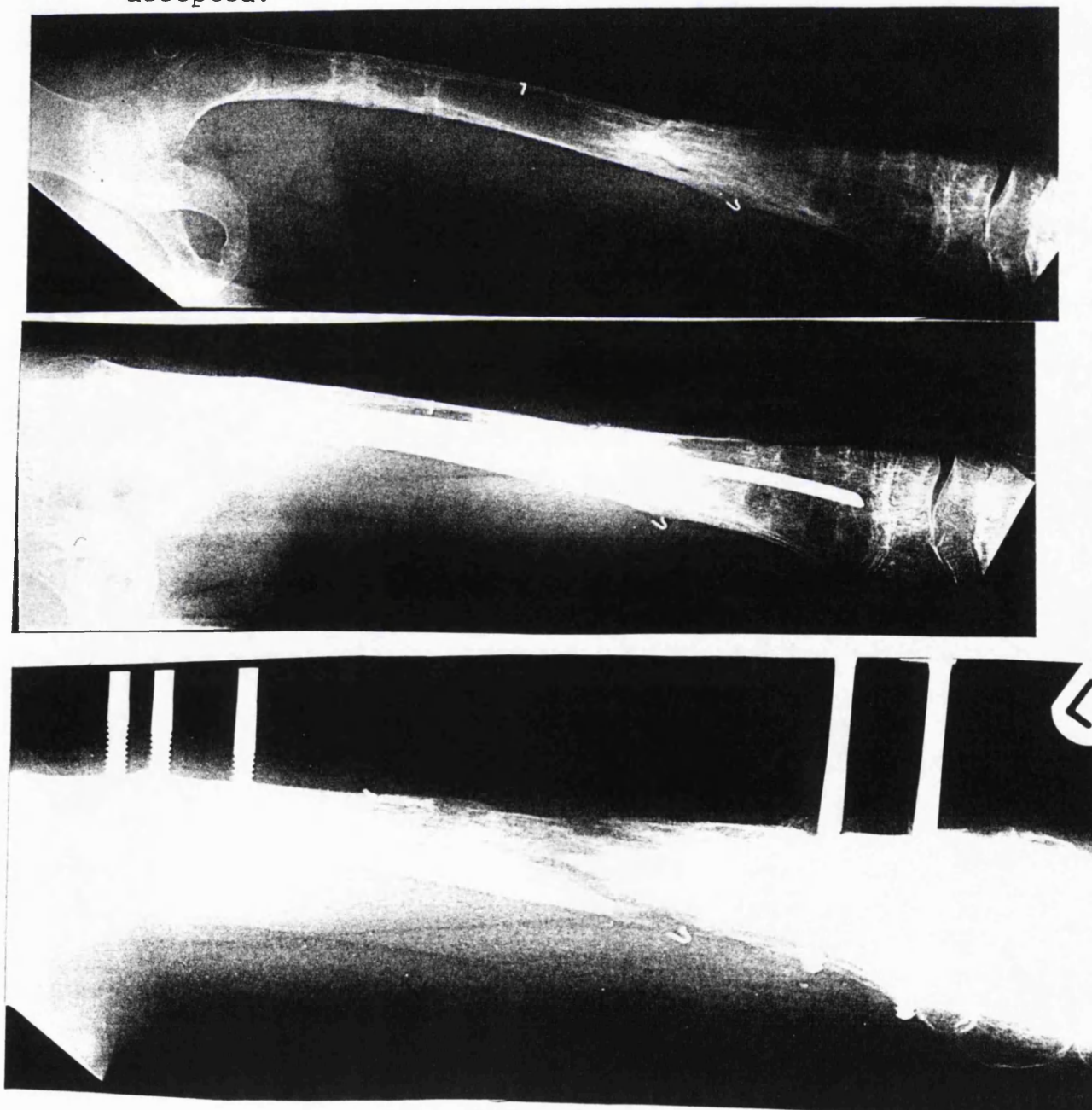

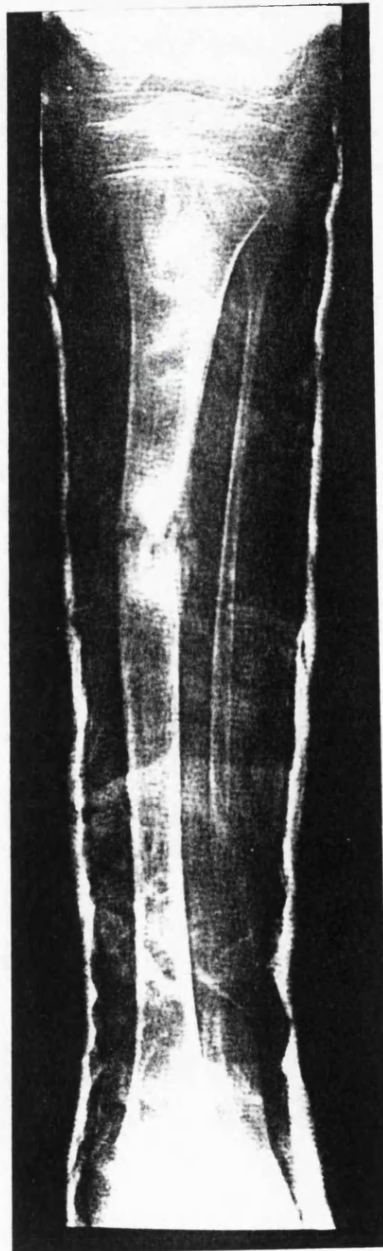

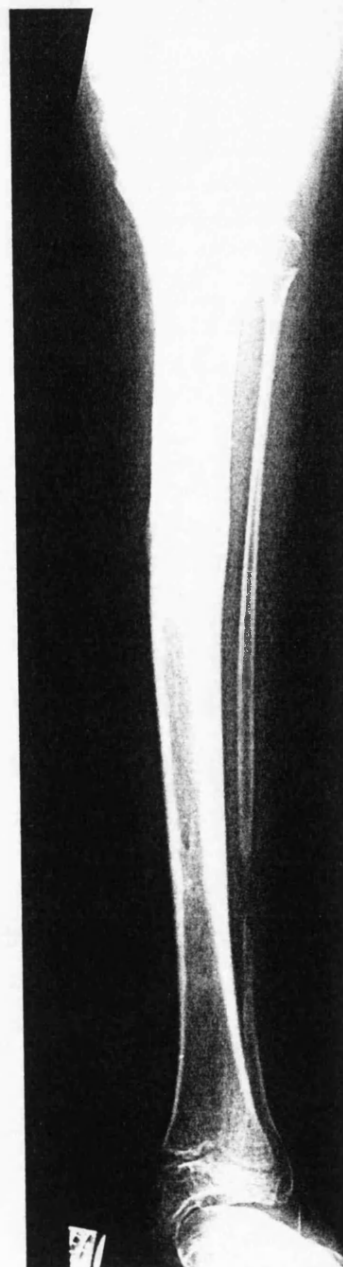
Figure 2.7. The first tibial lengthening for congenital short tibia. The newly formed bone fractured four weeks after the removal of the fixator. The injury was treated conservatively in a plaster-of-Paris cast for ten weeks. Recovery was uneventful.



a



b



c

## DISCUSSION

Reliable correction of congenital limb length discrepancy has recently been achieved using progressive distraction of the corticotomy site (De Bastiani et al., 1987; Ilizarov, 1989; Ilizarov et al., 1969).

The results reported in this thesis compare favourably with those reported by De Bastiani et al. (1987), and, more recently, Price and Cole (1990) using the same method. All but one of the patients in this series achieved the desired length, and all were capable of undertaking their normal activities during the lengthening process. All patients suffered from superficial infection of the pin sites, which can be considered a natural consequence of the stresses placed on the skin around the pin, and the continuous microtrauma that the skin undergoes in these cases (Paley, 1988). Aggressive antibiotic treatment is mandatory to avoid spreading of the infection.

Comparison of the current methods of limb lengthening by Ilizarov (1989), Ilizarov et al. (1969), De Bastiani et al. (1987), Monticelli and Spinelli (1983) and other techniques (Mitchell, 1963; Wagner, 1980) is difficult, given the inclusion criteria of patients in the various studies, and the biomechanical characteristics of the different distraction devices used (Gasser et al., 1990).

In the present study, the healing index was quite different in the three bony segments lengthened, with

the femur averaging 28.9 days/cm, the tibia 35.8 days/cm, and the ulna 38.3 days/cm. Although the number of patients in each group is too small to allow any statistical analysis, when sufficient data have been collected, these differences may well be statistically significant, as they imply a treatment period longer in the lengthening of the same absolute tibial versus femoral discrepancy. The reasons for this are not clear, but they could be connected with the deeper location, and hence greater vascularity and muscular protection, of the femur. Bifocal lengthening could be considered to shorten the duration of the whole procedure, both in the lower and in the upper limb (Paley, 1988).

Several factors must be considered when planning a lengthening procedure. Most important are the aetiology of the length discrepancy, and the timing of the correction. Congenitally short bones are more difficult to lengthen than post-traumatic or post-infective ones (Guidera et al., 1991). Some conditions, such as congenital insensitivity to pain and post-irradiation syndrome, should be considered absolute contra-indication to lengthening (Guidera et al., 1991).

Given the problem of dealing with congenital LLD, the relatively low complication rate and number of operations per patient reported in this series, especially when compared to the Wagner's method (Blachier et al., 1986), are probably due to the

intrinsic safety of the distraction method, to a well planned choice of patients, to the close liaison with the families, and to the careful supervision of the children.

Although no definite studies are available, and lengthening has been undertaken on patients well into their twenties (Vilarrubias et al., 1990), the best time to plan a lengthening procedure is probably around puberty (Dal Monte and Donzelli, 1987), as full healing potential is to be expected to achieve the best results.

Careful serial analysis of radiographs are required to assess the length of the corticotomy gap, possible malalignment of the corticotomy fragments, and to evaluate the quality of bone formation at the corticotomy site (Young et al., 1990b). Ultrasound scanning can probably play a role in the decision-making process (Young et al., 1990a; Maffulli, Hughes and Fixsen, 1992). Clinical evaluation for planning fixator removal is not clearly defined yet, and at present the surgeon should rely on imaging techniques. Possibly, measurements of bone stiffness, although still in an experimental phase and not yet implemented in limb lengthening, could help in the decision-making process (Richardson et al., 1992). Dual energy X-ray absorptiometry, although at its early stages, seems to provide an objective and quantitative assessment of new bone formation during leg lengthening (Eyres, Bell and Kanis, 1993).

For the time being, the timing of fixator removal depends largely on qualitative assessment of the newly formed bone. At least three cortices must be visible in the antero-posterior and lateral radiographs prior to removal. Care should be taken before removal of the fixator to allow full consolidation of the newly formed bone in order to avoid complications such as fractures through it.

## CHAPTER 3

### RADIOGRAPHIC STUDIES

	Page number
3.1. INTRODUCTION .....	87
3.2. RADIOGRAPHIC EVALUATION .....	89
3.3. RESULTS .....	90
3.3.1. Radiographic features of lengthening .....	90
3.4. DISCUSSION .....	98
3.5. ULTRASONOGRAPHIC FEATURES OF LIMB LENGTHENING .....	100
3.6. PATIENTS AND METHODS .....	101
3.6.1. Ultrasound scanning technique .....	101
3.7. RESULTS .....	103
3.8. DISCUSSION .....	111
3.9. WHICH IMAGING TECHNIQUE TO ASSESS BONE REGENERATION? .....	112
3.10. RADIOGRAPHIC METHODS .....	112
3.11. NON-RADIOGRAPHIC METHODS .....	114

### 3.1. INTRODUCTION

Imaging of the distracted segment is necessary to monitor the limb lengthening process and to document new bone formation (Blane et al., 1991; Hamanishi et al., 1992; Vade et al., 1990; Walker et al., 1991; Young et al., 1990a). Alignment is generally evaluated using sequential plain antero-posterior and lateral radiographs, possibly with additional views centred over the distraction site. Radiographs are taken initially at one-to two-weekly intervals (Young et al., 1990b). The distraction rate can thus be varied according to the radiographic appearance of the regenerate bone at and around the distraction site. Two months after the corticotomy, a monthly radiograph in the two planes usually suffices.

Although other techniques are being currently experimented with (Eyres, Bell and Kanis, 1993a and 1993b; Maffulli et al., 1992; Peretti et al., 1988; Young et al., 1990b), plain radiography is the most frequently used and readily available method (Blane et al., 1991; Hamanishi et al., 1992; Vade et al., 1990; Walker et al., 1991; Young et al., 1990a).

In this chapter, first the radiographic features of the process of limb lengthening in the patients described in the previous chapter will be reported. A simple system of radiographic grading newly generated bone is proposed. Furthermore, the ultrasonographic features of the lengthening process, studied in a sub-group of children, will be described. Finally, the



problem of which imaging modality to use to study the newly formed bone is discussed.

### 3.2. RADIOGRAPHIC EVALUATION

The radiographic features of limb lengthening were studied using antero-posterior and lateral radiographs taken for clinical purposes. Thus, no special radiographic techniques were used. All radiographs were studied by the author, and discussed with a Consultant Radiologist with a special interest in paediatric bone radiology.

The formation of newly formed bone was assessed and graded as follows:

- 1 - occasional speckle of bone
- 2 - unorganised callus
- 3 - organised layered bundles
- 4 - early formation of medullary canal
- 5 - radiographical evidence of medullary canal

The longitudinally aligned newly formed bone was considered the normal pattern of lengthening (Vade et al., 1990). When this was not the case, bone development was considered to be "amorphous". Ossification defects and complications were noted.

Radiographs were studied for radiographical evidence of periosteal reaction, pin loosening and angulation.

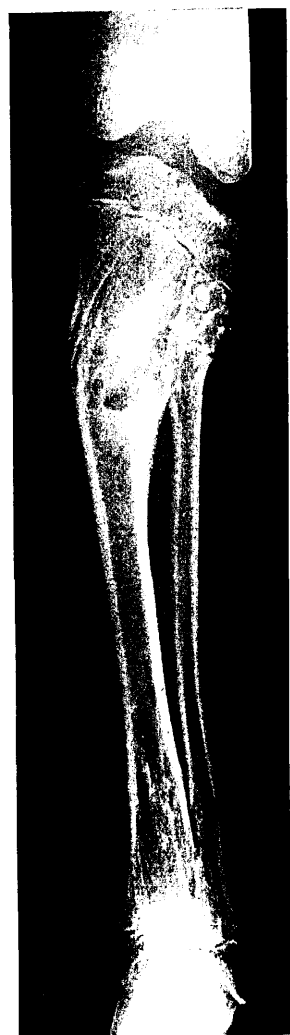
### 3.3. RESULTS

#### 3.3.1. Radiographic features of lengthening


The osteotomy created a defect clearly evident on radiographs. The process of bone formation following osteotomy and gradual distraction occurred in a well ordered fashion. After the first few weeks, the bone ends appeared mildly osteopenic, possibly due to the lytic action of the enzymes released by necrosed osteocytes.

Longitudinally oriented columns extended from each stump towards a central transverse radiolucent area. This is generally regular, but it may present a ragged appearance. The columns of new bone elongate maintaining a central radiolucent area. After distraction, the regenerate bone reaches a homogeneous appearance, and, during the fixation period, undergoes remodelling that reconstitutes a well defined cortex. Medullary canal formation was observed starting from the seventh to eighth week, and progressed until a fully formed canal was seen on plain radiographs. In no cases were ossification defects detected radiographically.


The rate of progression of new bone formation is shown in Table 3.1. and Figure 3.1. The average time to the formation of good medullary bridging was over six months. Four patients showed an amorphous pattern of bone growth. Of these, two were undergoing leg lengthening for Olliers disease. The other two were undergoing forearm lengthening for diaphyseal aclasia.



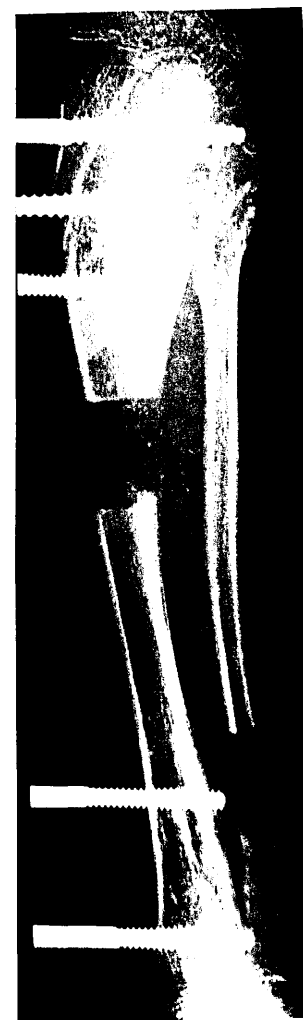
a




b




c



d



e



f

Figure 3.1. Radiographic sequence of a tibial lengthening in a patient with Ollier's disease. Note initial marked angulation.

Grade 1. Early callus formation.

Grade 3. Distraction site now showing a few organised layered bundles.

Grade 4. Further consolidation and early corticalization.

Grade 5. Full bridging.

TABLE 3.1.

	New Bone Formation				
Grading	1	2	3	4	5
Average days to reach grade	16	25	53	114	190

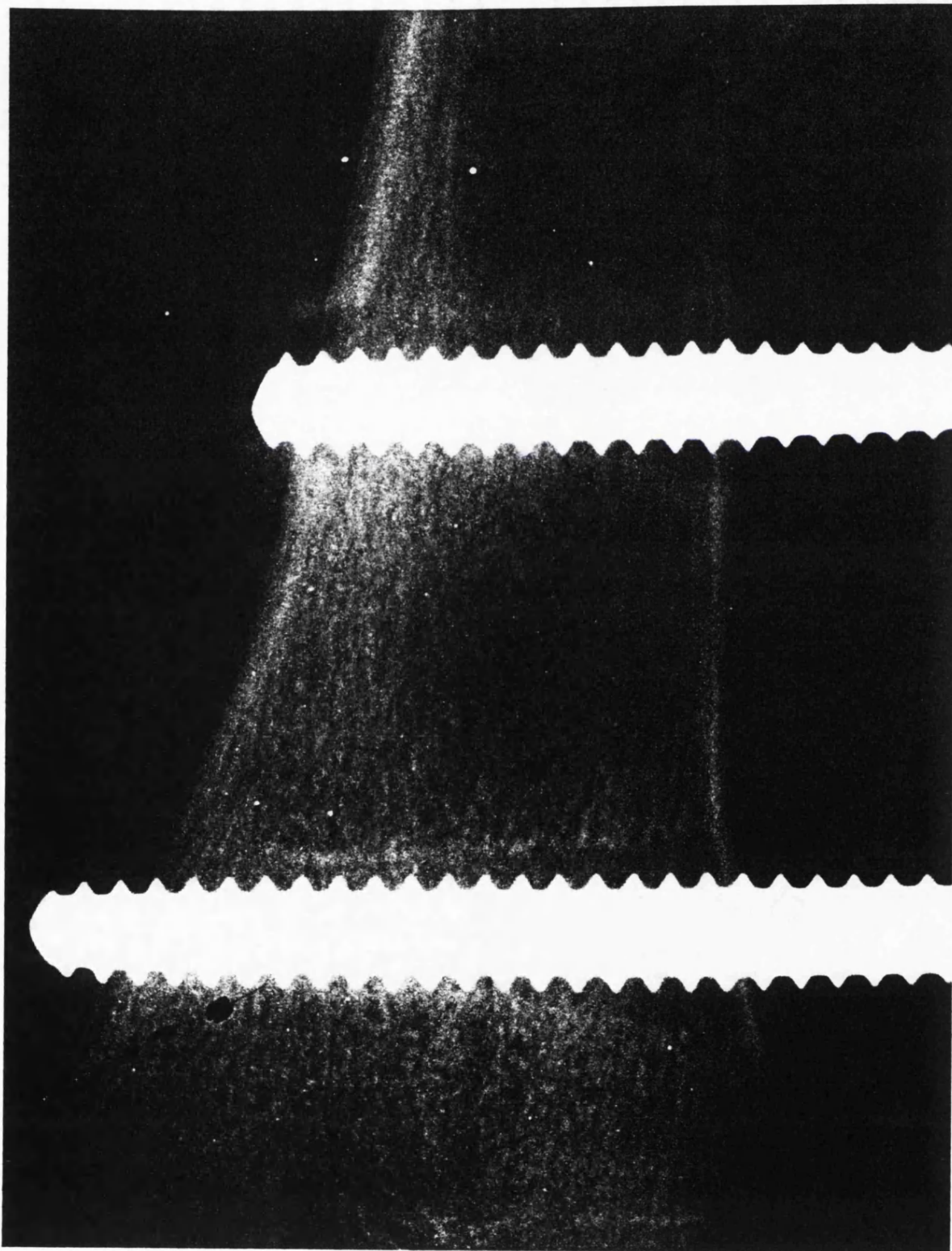
A periosteal reaction was the commonest abnormality seen (Table 3.2. and Figure 3.2.), noted in 81% of pin sites. The periosteal reaction occurred at one site only after an average of 40 days (range 2-209 days). With time, the reaction became increasingly common, and occurred at three pin sites by 100 days in 19% of patients.

TABLE 3.2.

	Periosteal Reaction					
No. pin sites	0	1	2	3	4	5
No. pts	4	13	11	4	3	1
Average days to periosteal reaction	-	28	79	102	99	51

N.B. Some patients started with a periosteal reaction limited to one or two pin sites, and subsequently progressed to develop the reaction at a greater number of sites.

Figure 3.2. Detail of pin loosening. The most proximal of the two screws shows an area of bone erosion around the screw itself, with a definite area of periosteal reaction medially.



Radiographic signs of bone resorption around the pin were found in 57% of patients (Table 3.3.). This was seen at one site only after an average of 82 days. The radiographic signs of bone resorption around the pin were always associated with a periosteal reaction. The latter pre-dated the bone resorption in 10 out of 25 patients (42%) by an average of 47 days. In two femora, it was possible to detect an area of bone erosion associated with periosteal elevation medially around the pins (Figure 3.2.). The fixator was removed for a persisting infection, and the femur protected in a long leg plaster-of-Paris back slab for two weeks before rodding (for a similar case, see Figure 2.6.).

**TABLE 3.3.**

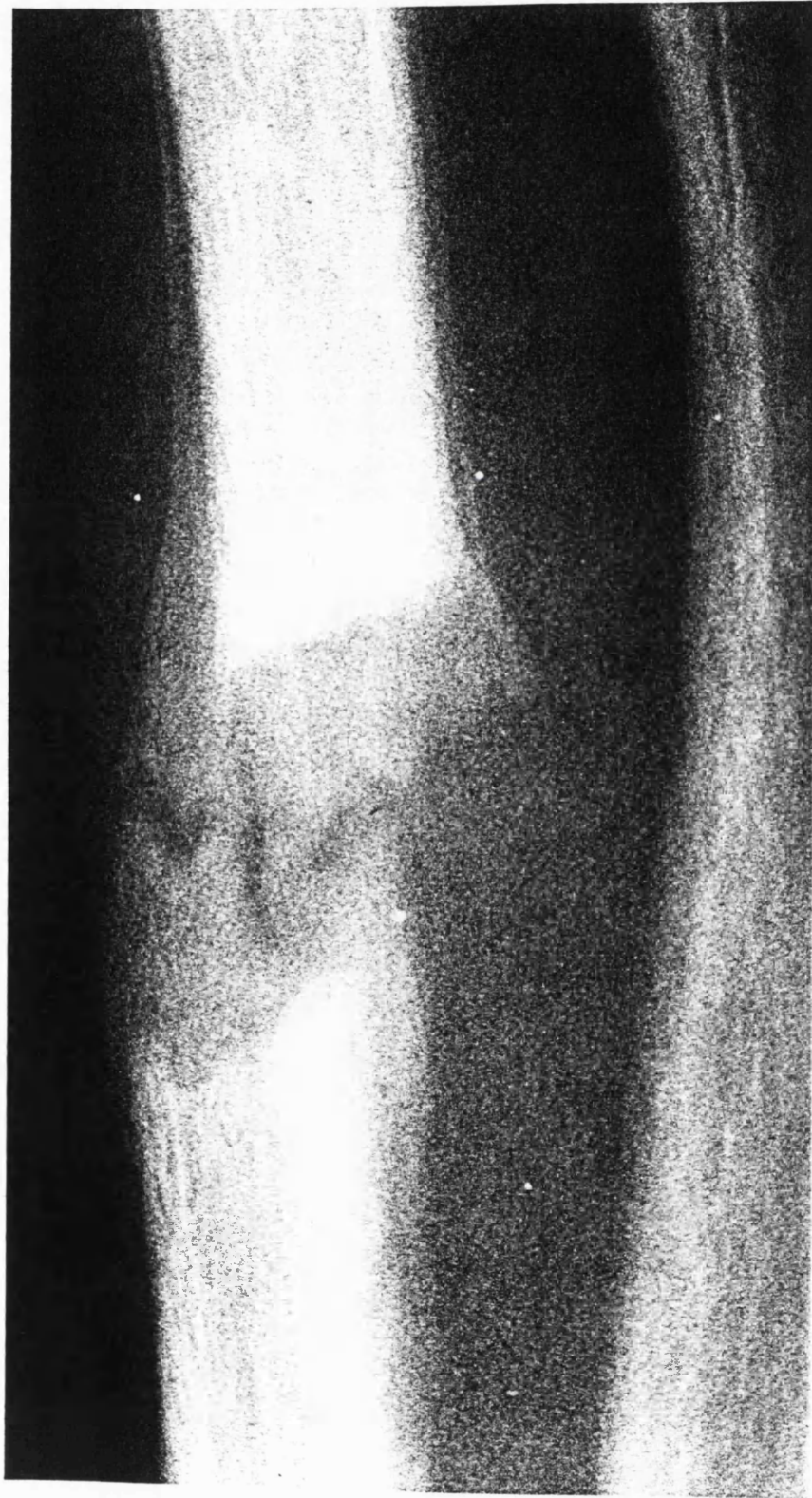	Pin Loosening				
	0	1	2	3	4
No. pin sites	0	1	2	3	4
No. pts.	9	9	5	1	1
Average days to loosening	-	82	117	40	225

N.B. Some patients started with loosening at one or two pin sites, and subsequently progressed to develop loosening at a greater number of sites.



Six patients developed a ragged radiolucent region through the newly forming bone at an average of 95 days from the osteotomy (range 51 to 225 days). This change was seen in three tibiae, two ulnae and one femur, with no definite pattern to the underlying cause. Subsequently uneventful healing occurred (Figure 3.3.).

Figure 3.3. Particular of the ragged radiolucent region through the newly forming amorphous bone. No underlying cause was identified, and uneventful healing occurred.



### 3.4. DISCUSSION

As pointed out in the clinical studies section, all patients suffered from superficial infection of the pin sites. This can be considered normal, given the stresses placed on the skin around the pin, and the continuous microtrauma that the skin undergoes during lengthening (Paley, 1988). Superficial pin site infection can progress to the radiological features of periosteal reaction and bone resorption around the pin, of which a periosteal reaction is an early indicator. Aggressive antibiotic treatment of superficial infection is essential to avoid further extension to deep tissues.

Careful serial analysis of radiographs is required to assess the length of the corticotomy gap, possible malalignment of the corticotomy fragments, and to evaluate the quality of bone formation at the corticotomy site (Blane et al., 1991; Hamanishi et al., 1992; Vade et al., 1990; Walker et al., 1991; Young et al., 1990a). Errors of alignment detected by plain radiography are usually correctable, at least partially.

The timing of fixator removal depends largely on qualitative assessment of the newly formed bone. At least three cortices must be visible in the antero-posterior and lateral radiographs before removal (Maffulli et al., 1993). Care should be taken to allow full consolidation of the newly formed bone to avoid serious complications such as fractures.

To avoid the problems connected with a purely qualitative estimate of bone maturation, recently Eyres et al. (1993b) have compared plain radiography, ultrasonography and dual energy bone densitometry (DEBD) to study the mineralisation of the newly formed bone. They suggest that DEBD is the most accurate tool to quantify this variable, and recommend that the fixator should be removed only when the regenerate bone is 75% as mineralised as the normal bone.

In six patients, a ragged radiolucent region through the newly forming bone was detected, while in the others the radiolucent region was more regular. As the newly formed columns are orientated to resist the forces being applied to the bone, the ragged appearance reflects macroscopically the stresses being transmitted to the lengthened bone through the mono-axial fixator. In practice, there would be concentration of tensile stresses on the side of the bone far away from the fixator, and these would tend to decrease towards the opposite side.

### 3.5. ULTRASONOGRAPHIC FEATURES OF LIMB LENGTHENING

The previous section reported the radiographic appearance of bone regeneration during the process of limb lengthening using callotasis.

Given the length of time needed to achieve the required length, and the subsequent consolidation time, the children undergoing callotasis require many radiographs, with repeated exposure to ionising radiation. Also, the assessment of the quality of the new bone is subjective.

There is therefore a need for a less invasive and more objective method of monitoring new bone formation (Eyres, Bell and Kanis, 1993a and 1993b). Both dual energy bone densitometry (DEBD) (Peretti et al., 1989), and ultrasonography (US) (Blane et al., 1991; Huppertz et al., 1990; Peretti et al., 1987; Ricciardi et al., 1986; Young et al., 1990a) have been used. It is recognised that no single method is totally accurate in assessing the maturity of the newly formed bone, hence the necessity of combining at least two of them (Eyres, Bell and Kanis, 1993b).

In this section, the ultrasonographic features of the process for limb lengthening will be described.

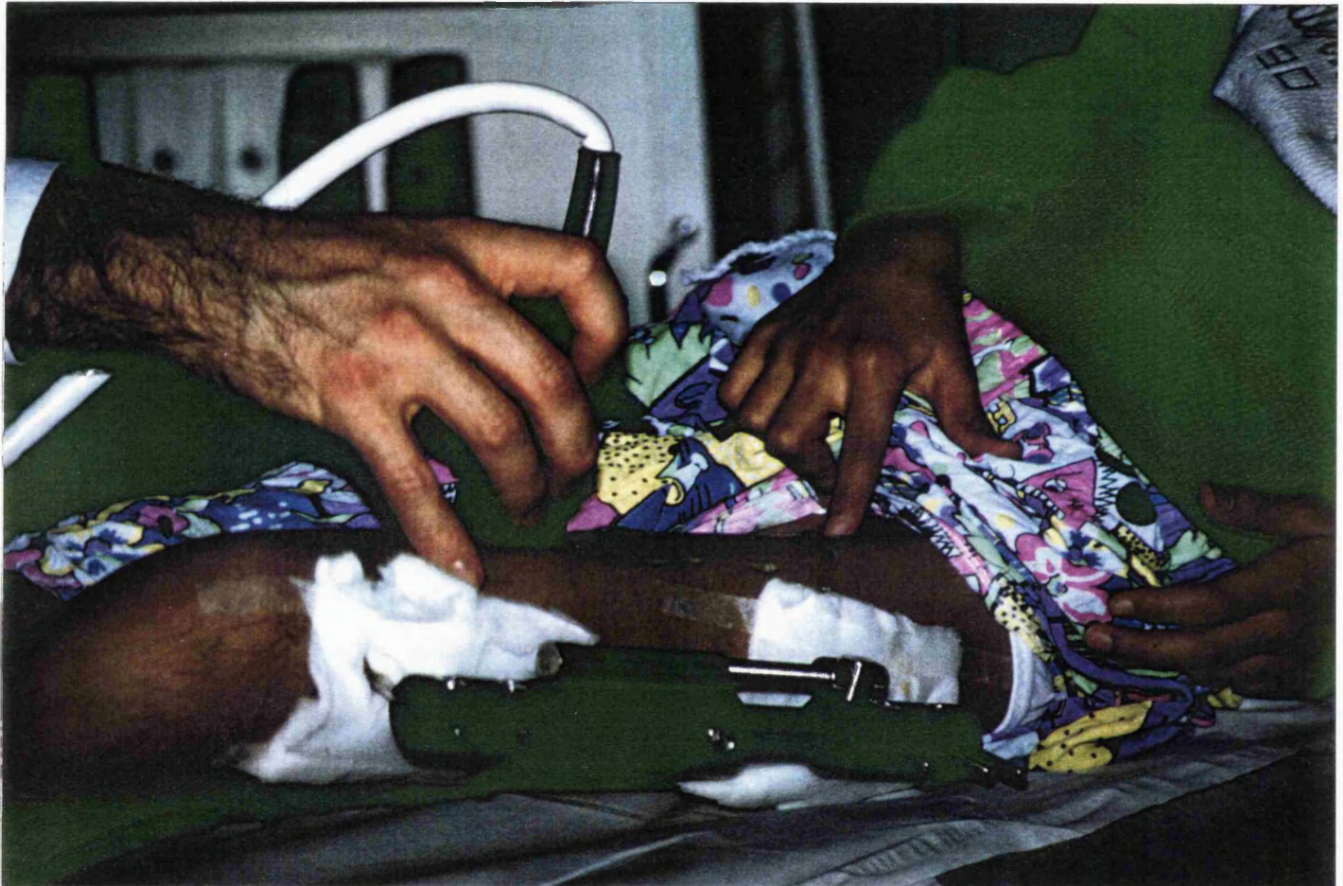### 3.6. PATIENTS AND METHODS

Nine patients, a subgroup of the 25 patients who have been described until now, participated in this part of the study. Their age at operation ranged from 8.5 to 10.2 years. Causative factors were femoral hypoplasia (four patients), tibial hypoplasia (four patients) and diaphyseal aklasia of the forearm (one patient). Leg length discrepancy at the time of surgery ranged from 4.5 to 8 cm, and average forearm length discrepancy was 26 mm.

#### 3.6.1. Ultrasound scanning technique

Sonograms were obtained in the longitudinal and coronal planes using a 5 MHz phase array or a linear array transducer on an Acuson 128 Unit. A commercially available gel was used to ensure optimal contact between the probe and the skin (Figure 3.4.). The US images were photographed, and all morphological evaluations were carried out on these. All the radiographs and US scans were evaluated with particular attention to: a. possible malalignment of the bony segments; b. distance between the osteotomy ends; c. appearance and d. maturity of the newly formed bone.

Figure 3.4. Ultrasound scanning of newly formed bone in a child undergoing lengthening for a congenital short femur.



### 3.7. RESULTS

From an intact cortex, typical high soft tissues-cortical bone interface sonographic echoes with a clear cut acoustic shadow area are obtained. The cortical defect resulted in greater permeability to the scanning beam, and thus the distraction zone appeared as a sonolucent area compared to normal bone (Figure 3.5.). Serial examination demonstrated increasing echogenicity at the distraction site. Studying the longitudinal scans, it was possible to detect initially some disorganised echogenic foci at the distraction site (Figure 3.6.). At around four weeks from the beginning of distraction, these echogenic areas tended to become more aligned (Figure 3.7.).

At approximately seven weeks of distraction, a clear impression of a new cortical margin was seen on the longitudinal scan. This was seen as a scalloped area close to the bone ends, and was evident on the transverse scans as ossified bundles of new bone, which showed progressive evidence of consolidation in the following weeks. The formation of a medullary canal was seen starting from the seventh to the eighth week of distraction (Figure 3.8.). This progressed until a fully formed canal was seen on radiographs. Care should be taken not to overestimate the presence of cortication (Eyres, Bell and Kanis, 1993).



Figure 3.5. Longitudinal ultrasound scan immediately following corticotomy. The corticotomy site appears as a sonolucent area compared to normal bone.

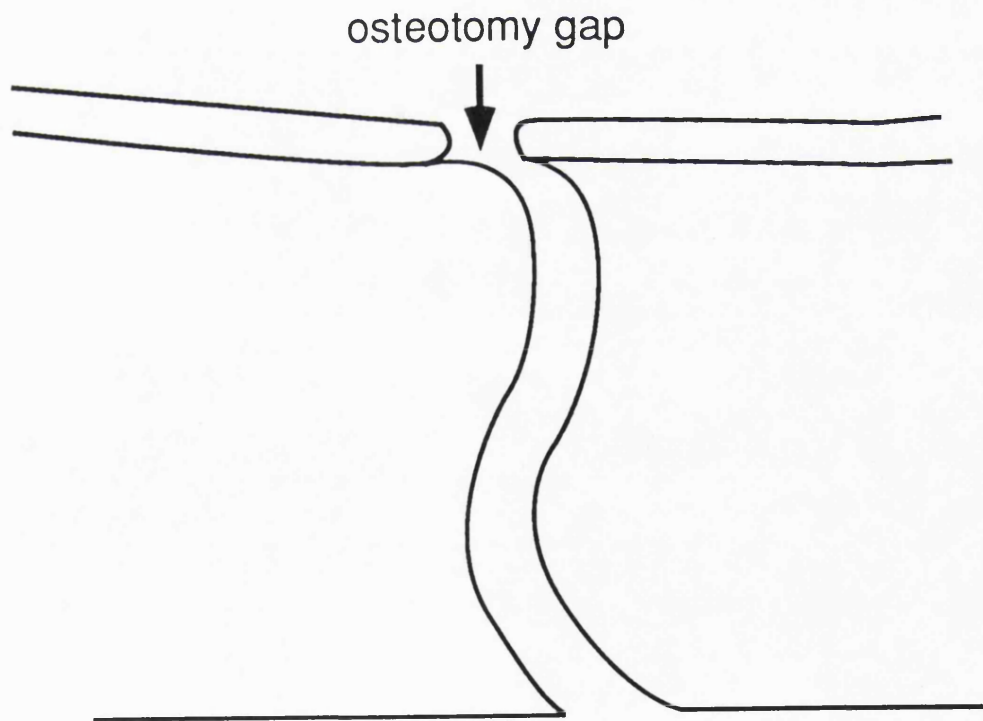
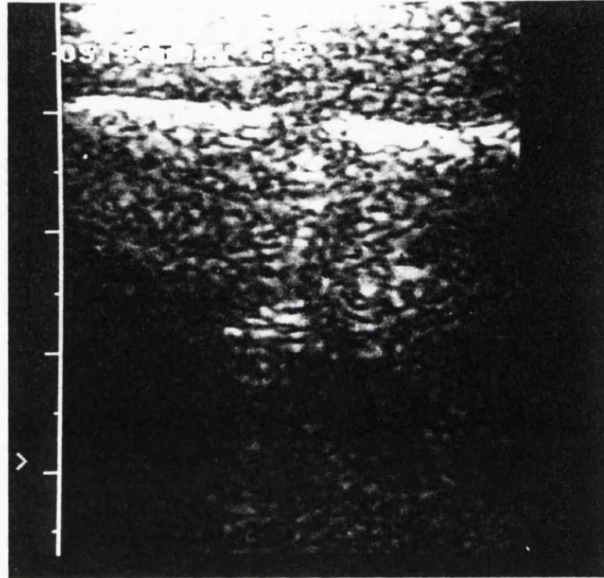


Figure 3.6. Longitudinal ultrasound scan at 10 days, showing disorganised echogenic foci at the distraction site.

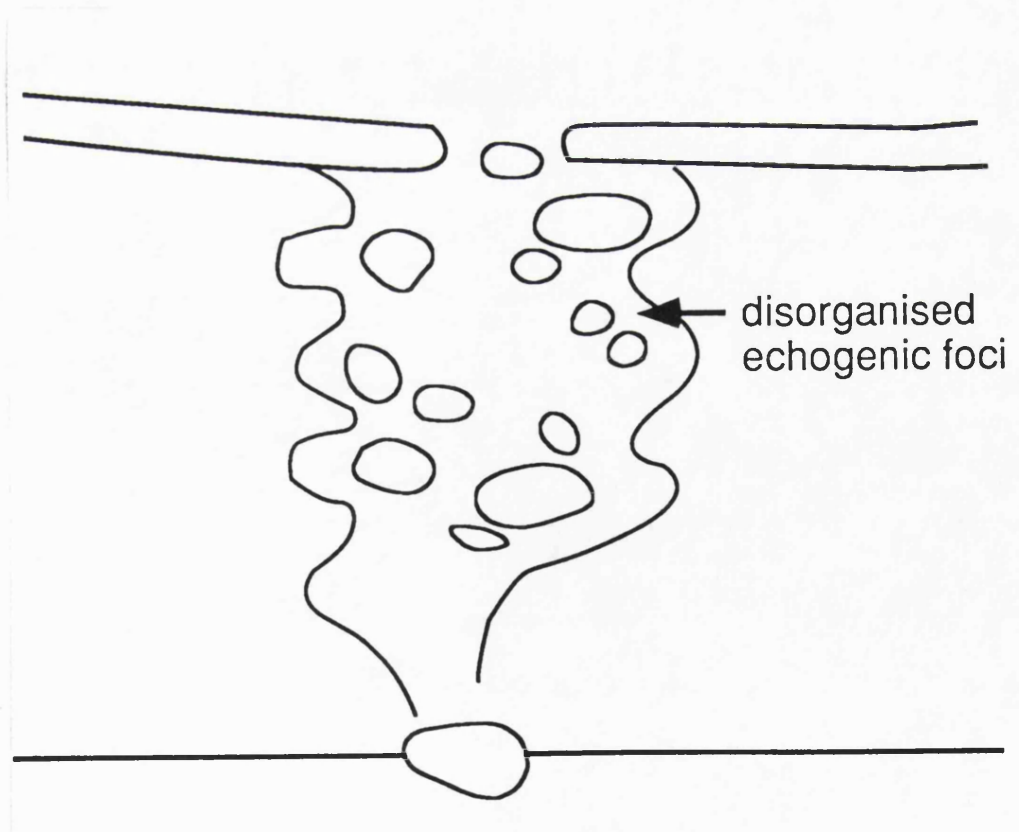
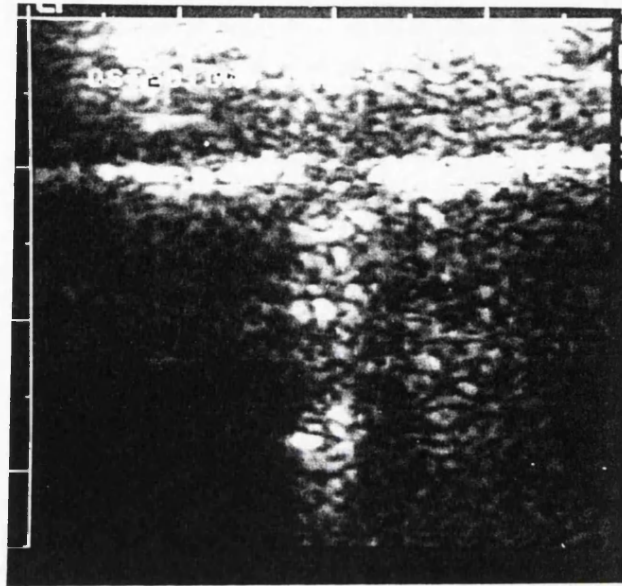


Figure 3.7. Longitudinal ultrasound scan at four weeks from the beginning of distraction. The previously disorganised echogenic areas tend to become more aligned.

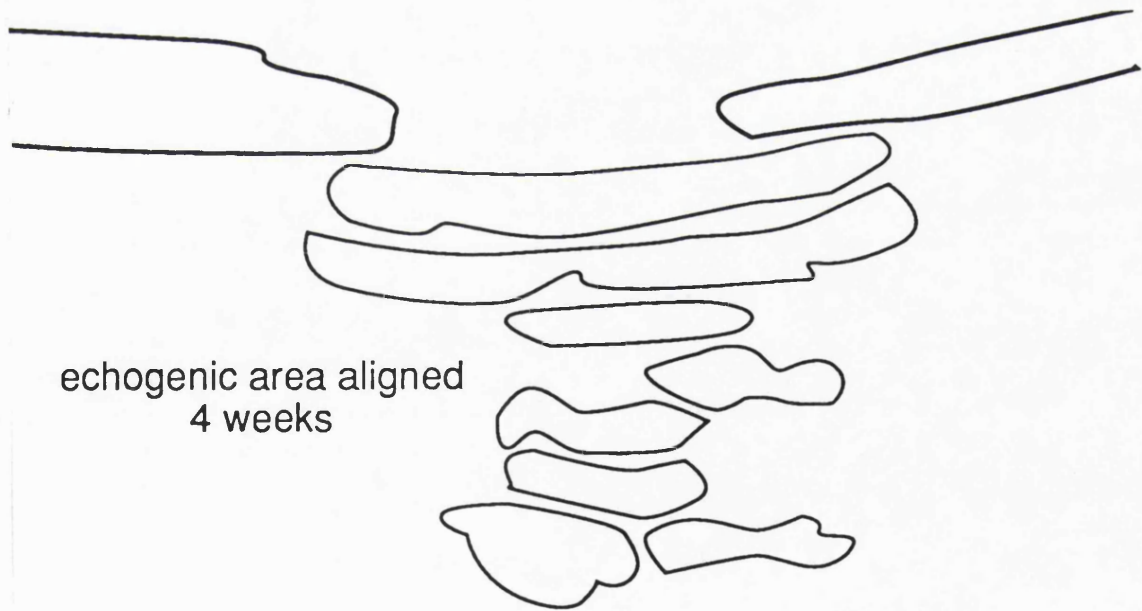
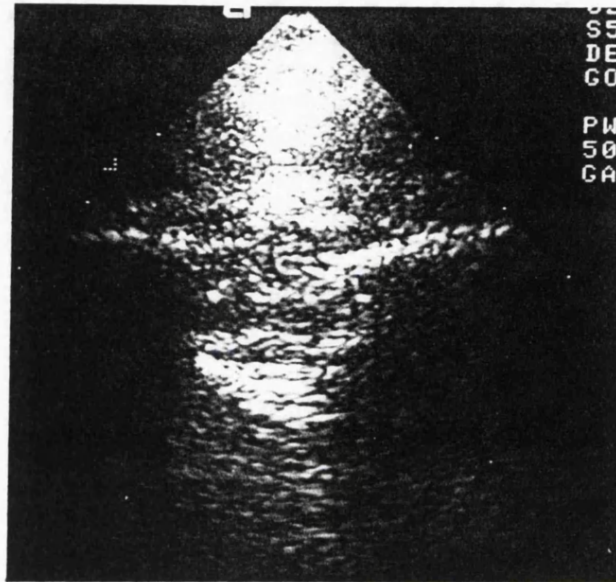
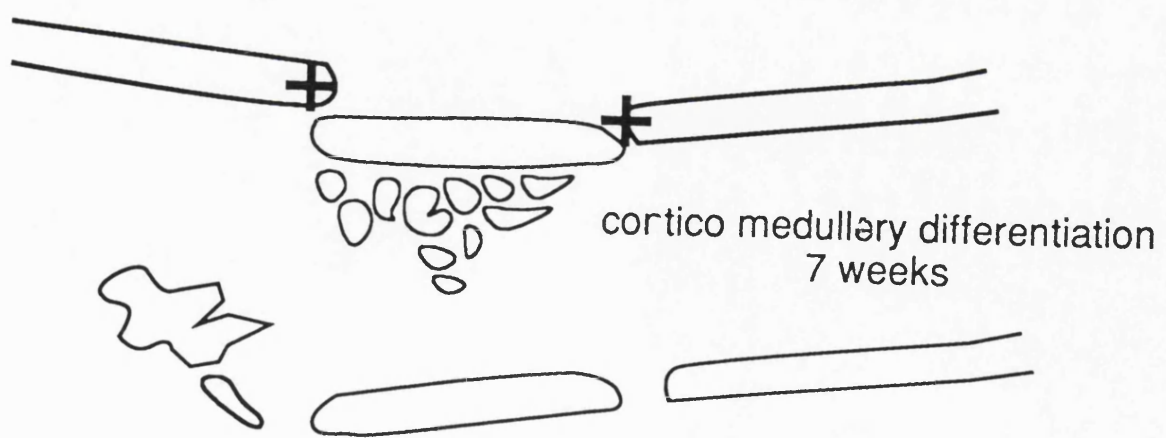
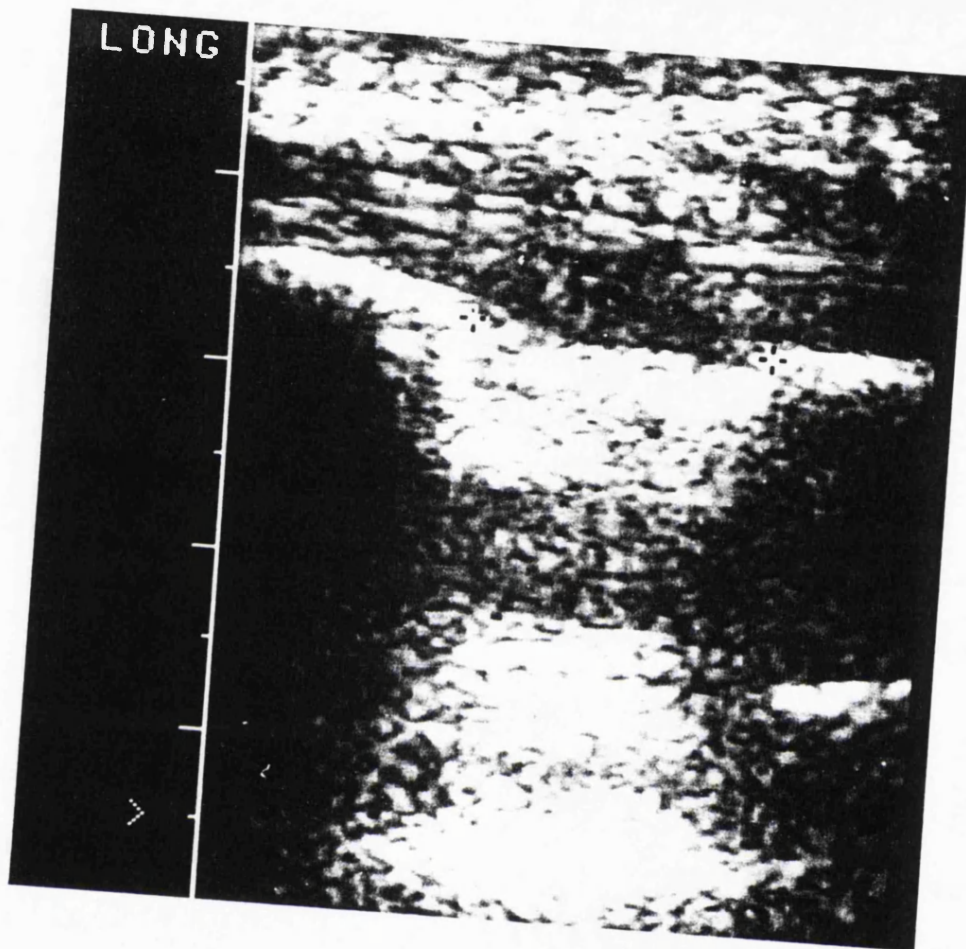


Figure 3.8. Longitudinal ultrasound scan at eight weeks from the beginning of distraction. Initial cortico medullary differentiation is seen.



In one case, it was possible to detect a small sonolucent area, of two by three mm, which probably represented a small defect in ossification with a cystic fluid collection (Figure 3.9.). Given its size, it was decided not to aspirate it. The lengthened area was compressed for five days. The sonolucent area was never evident on radiographs, and did not hinder the final result.

In a further case, once the desired length had been achieved, the fixator was locked. However, as the child was weight bearing, the whole construct bent. An US scan was able to ascertain the presence of the bending (Figure 3.10.)

Figure 3.9. A sonolucent area in the substance of the regenerated bone. It probably was a small defect in ossification with a cystic fluid collection. It was not aspirated. Never evident on radiographs, it did not hinder the final result.

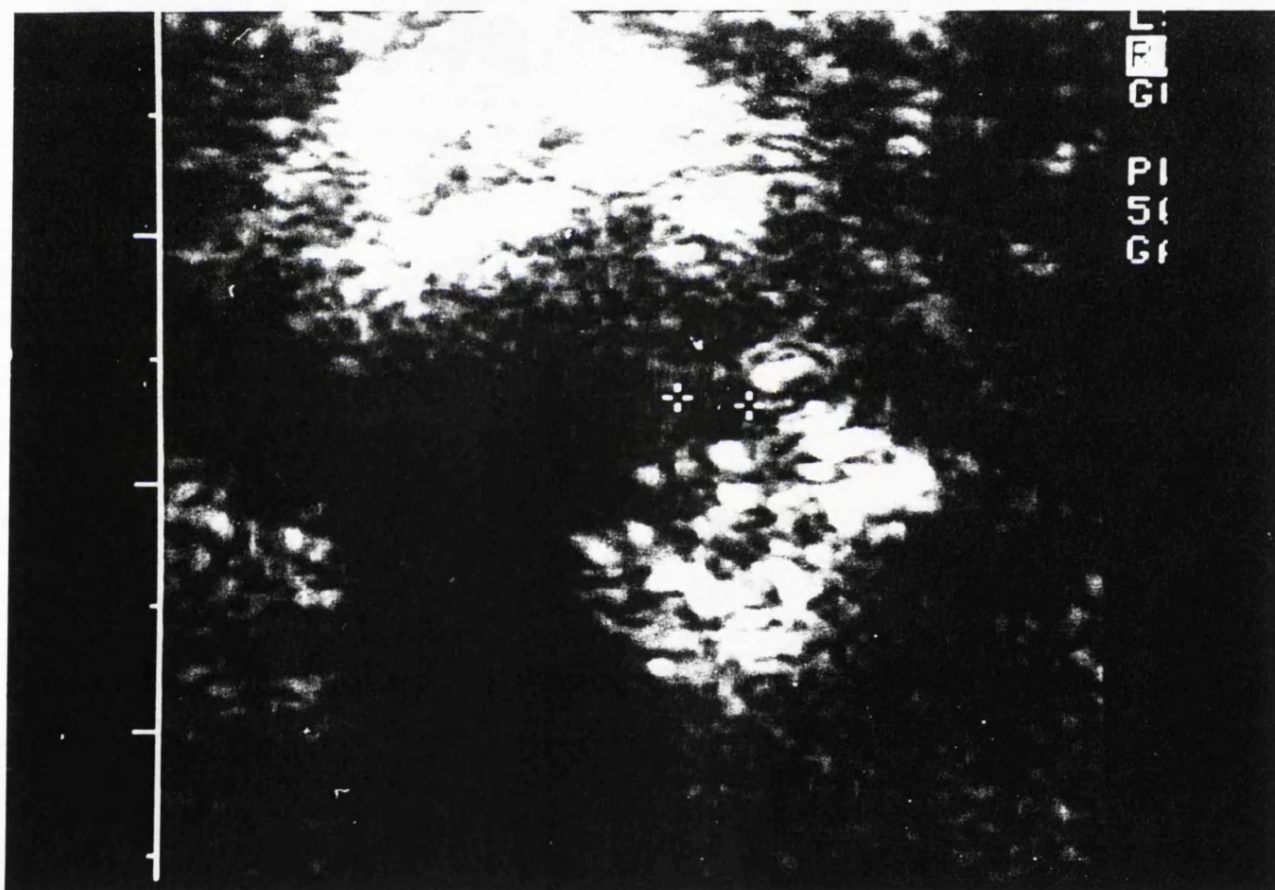
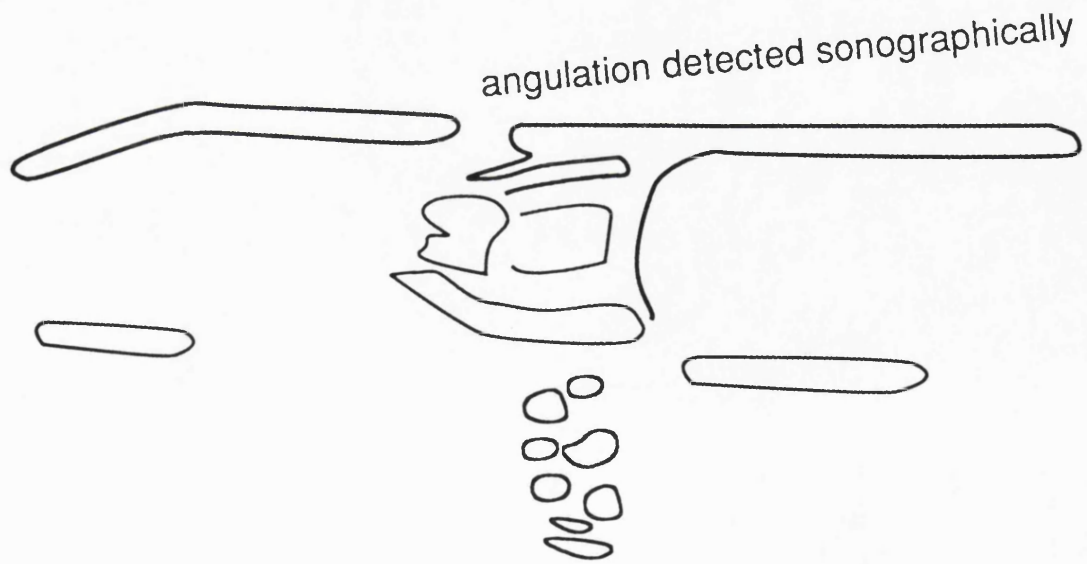
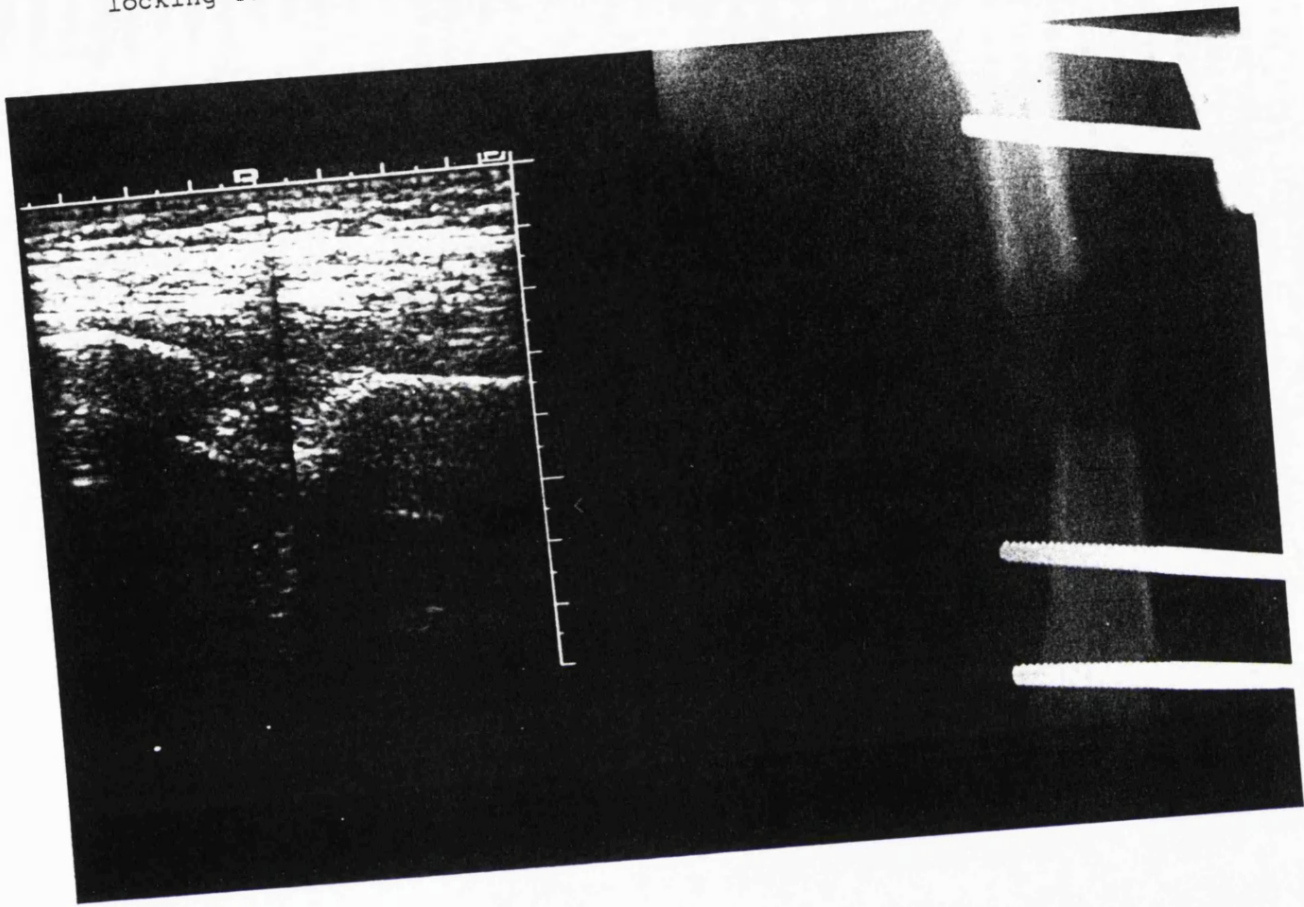


Figure 3.10. Angulation at the lengthening site, following locking of the fixator in the fully extended position.



### 3.8. DISCUSSION

Careful serial analysis of radiographs and US scans are required to assess the length of the osteotomy gap, malalignment of the fragments, and the quality of bone formation at the corticotomy site. Both radiographs and US scan show initially the corticotomy site. However, given radiographic magnification, accurate and valid measurement of the gap may be difficult. On US scans, by contrast, the measurement can be carried out in vivo, and in different planes. Also, US is much more sensitive in detecting early ossification foci and cystic areas. Given the validity and reliability of US scan measurements, the number of radiographs taken during the process of limb lengthening can be reduced.

Axial deviation is still better evaluated on radiographs, and, for the time being, these cannot be completely abandoned. A potential, but easily solvable, limitation of US could be the size of the linear probes. If a probe is too short, it cannot scan both ends of the osteotomy site at the same time in the later stages of the lengthening process.

Serial US scanning in limb lengthening can therefore reduce exposure to ionising radiation. It is a relatively fast and cheap method. Accurate measurements are possible, and the process of ossification is easily monitored. In our hands, axial deviations can be seen but not evaluated, and the stability of the regenerate bone has still to be assessed clinically.



### 3.9. WHICH IMAGING TECHNIQUE TO ASSESS BONE REGENERATION?

Computed tomography (CT), quantitative computed tomography (QCT), bone scanning, ultrasonography (US), and dual energy bone densitometry (DEBD) have been employed to follow the lengthening procedure (Aronson et al., 1990; Blane et al., 1991; Eyres, Bell and Kanis, 1993a and 1993b; Maffulli et al., 1992; Peretti et al., 1988; Van Roermund et al., 1987 and 1988; Williamson, 1991; Young et al., 1990a and 1990b). Application of others may, at least theoretically, be proposed (Fasciani et al., 1992; Richardson et al., 1992; Tiedeman et al., 1988).

### 3.10. RADIOGRAPHIC METHODS

Plain radiography is traditionally used in monitoring the whole process, and guiding the management of these patients, who may be checked upon up to twice a week (Blane et al., 1991; Young et al., 1990b).

QCT provides a quantitative evaluation of bone formation during lengthening. Experimental work in dogs (Aronson et al., 1990) and rabbits (Van Roermund et al., 1987 and 1988) has shown a definite polarity of mineralization within the osteogenic area, with mineralization occurring both longitudinally and transversally (Aronson et al., 1990). Calcium deposition within the distraction gap was visualised approximately one week before detection with plain radiography (Aronson et al., 1990). Using QCT, the bone density in the centre of the lengthened area was shown

to be lower than at the proximal and distal parts. The overall bone density in the distraction zone increases for a short period after the end of the procedure, to decrease thereafter before reaching a steady state (Van Roermund et al., 1987).

Plain CT scanning has, to my knowledge, been used only once in humans (Guida et al., in press). The process of bone regeneration in bone lengthening using the Ilizarov frame followed a centripetal direction. It was necessary to use a special frame where the rods were made of wood instead of metal, and the patients underwent a significant number of scans. Thus the technique, although interesting as a research tool, cannot be recommended for routine clinical use.

Photometric assessments of bone density, based on the intensity of light transmitted through standard radiographs, has been used experimentally to study fracture healing. The method has shown a high correlation with bone rigidity, making it potentially useful for the in vivo assessment of bone mineralization (Tiedeman et al., 1988).

Bone scanning using  $^{99}\text{Tc}$  methylene diphosphonate demonstrated increased uptake preceding the actual accretion of bone, followed by a decrease during the bone remodelling phase (Van Roermund et al., 1987). Uptake of the isotope partially reflects bone metabolism, and, being influenced by factors such as trauma, would not be a valid and reliable method to use in routine clinical practice.

Dual energy bone densitometry (DEBD) is of value especially in the later stages of lengthening (Eyres, Bell and Kanis, 1993; Peretti et al., 1988; Williamson, 1991). However, as it converts three dimensional bone formation into a two dimensional image and a one dimensional number, it could miss bone defects which can be detected with US. Also, DEBD cannot measure alignment, unless the deformity lies in the plane of the scan (Eyres, Bell and Kanis, 1993; Peretti et al., 1988; Williamson, 1991). Additionally, to accurately measure length, one assumes the bone to be parallel to the film, which is not always possible with DEBD. Finally, unlike US and plain radiography, DEBD is not available in most departments, and its costs are high.

CT scanograms are probably the most accurate way of measuring length discrepancies, assuming the limbs can lie near parallel in the scanner and perpendicular to the scan plane. This is a precise, valid and reliable method of initial assessment and operative planning, but is not justified on a cost and irradiation basis to serially measure distraction, especially in view of artifacts introduced by the metal work (Van Roermund et al., 1987).

### 3.10. NON-RADIOGRAPHIC METHODS

The need to reduce the ionising radiation dose incurred in the process, especially in view of its length and the patients' young age, has lead to recent research showing that US can play a significant

role in assessing progress (Blane et al., 1991; Maffulli et al., 1992).

In the early stages of lengthening, US conveys a vast amount of information, with: 1. extremely accurate measurements of the corticotomy gap; 2. early detection and assessment of the quality of newly formed bone by giving information on the alignment of the neo-calcified bundles. Waisting of these bundles is an indicator of too rapid distraction (the US 'chewing gum' sign); 3. detection of ossification defects in the neo-formed bone with the additional option of US guided aspiration. On the other hand, axial deviation can be seen, but, generally, cannot be accurately evaluated, although in one patient a  $10^{\circ}$  angulation was seen with US independently of the confirmatory radiographic findings (Maffulli et al., 1992).

During US examinations, the probe does not have to be kept perpendicular to the lengthened bone (Maffulli, Hughes and Fixsen, 1992). US, like CT and MRI, is a three-dimensional volume acquisition technique. Although standard scans are taken in the coronal, sagittal and axial planes, oblique views can be useful to obtain a clearer view of the bone ends at the distraction site. Serial US scanning in limb lengthening avoids exposure to ionising radiation, is relatively fast, easily available and cheap. Accurate measurements are possible, and ossification can be monitored.

Ultrasound velocimetry has been used to assess whether the callus produced in a fracture treated by dynamic external fixation was mature enough for the fixator to be removed (Fasciani et al., 1992). Preliminary studies are promising, although the technique has not been applied to bone regeneration.

Resistance to stresses is the main function of bone, and a variable which could be measured in regenerated bone is its stiffness. Once again, no work has been published in limb lengthening. In 91 tibial fractures treated by dynamic axial fixation, the frame was removed when the fracture stiffness had reached 15 Nm · deg<sup>-1</sup>. No refractures were seen in this group of patients (Richardson et al., 1992).

The ideal approach to imaging of the distraction site is multi-disciplinary (Eyres, Bell and Kanis, 1993b; Green, Maffulli and Hughes, 1993). A possible protocol to take into account the differing imaging modalities more commonly available could consist of: 1. pre-operative assessment with CT scanogram; 2. immediate post operative AP and lateral radiographs to ensure that the corticotomy has been carried out correctly and to check alignment; 3. weekly US for the first eight weeks; 4. monthly AP and lateral radiographs during the lengthening phase, and if there is any clinical suspicion of complication during the lengthening or the consolidation phase. If available, DEBD can be carried out fortnightly to monthly from eight weeks, until removal of fixator.

**CHAPTER 4**

**MUSCLE STRENGTH IN LIMB LENGTHENING**

	<b>Page number</b>
4.1. INTRODUCTION .....	118
4.2. PATIENTS AND METHODS .....	120
4.2.1. Patients .....	120
4.2.2. Anthropometry .....	120
4.2.3. Strength measurement .....	120
4.2.4. Statistics .....	122
4.3. RESULTS .....	125
4.3.1. Clinical assessment .....	126
4.3.2. Knee extensor muscles strength .....	126
4.4. DISCUSSION .....	129

#### 4.1. INTRODUCTION

The importance of the relationship of limb size and structure to its functional capacity is well established (Davies & Sargeant, 1975a and 1975b; Sargeant & Davies, 1977a and 1977b). Major determinants of skeletal muscle strength are the cross-sectional area (CSA) of the muscle (Ikai & Fukunaga, 1968; Jones & Rutherford, 1987) and its volume (Davies, 1990). Nearly linear relationships between muscular strength and limb size have been demonstrated (Davies, 1990; Davies & Sargeant, 1975b and 1975c).

In patients with congenital short femur, the affected thigh is shorter and often bulkier than the normal contralateral one (Ring, 1959). Although the pattern of linear growth of the short limb has been extensively studied (Shapiro, 1982), researchers have not focused on the possible differences in bone, skeletal muscle and soft tissues composition between the normal and shorter side.

Normal muscle function during and after lengthening has been assumed, although early research showed that at least partial muscular force impairment was to be expected, possibly due to the rapid stretch technique of the time (Compere, 1936; Phalen and Chaterton, 1942). More recently, electromyography and nerve conduction studies revealed that callotaxis produced partial muscle denervation in all limbs tested and reduced motor conduction velocity (Galardi

et al., 1990; Young et al., 1993). Sensory conduction velocity was unchanged in one study (Galardi et al., 1990), but significantly affected in another (Young et al., 1993).

Muscular weakness of a lengthened limb, at times resolving within two years (Coleman and Noonan, 1967; Sproul and Price, 1992), has been considered the most common and serious complication in the long term follow-up of patients undergoing limb lengthening (Sofield et al., 1958). The lengthening methods used in the above studies were, however, less physiological and gradual than the modern ones (De Bastiani et al., 1987; Ilizarov, 1989).

The pattern of strength production following limb lengthening was measured and commented upon by Shchurov et al. (1984, 1985). The muscles of the lengthened limb appear to become progressively more able to exert similar strength as the normal contralateral ones (Shchurov et al., 1984 and 1985). More recently, using isokinetic testing, quadriceps strength was shown to be significantly reduced at low angular speed following callotasis (Steen et al., 1992).

This chapter reports on the evolution of maximal isometric voluntary contraction strength (MVC) in a group of children who underwent callotasis lengthening of a congenital short femur.



## 4.2. PATIENTS AND METHODS

### 4.2.1. Patients

Seven children (five boys and two girls), a subgroup of the children taking part in the main study, (Table 1) suffering from simple congenital femoral hypoplasia with normal acetabulum (Ring 1959) and their parents gave their informed consent to participate in the study.

Age at operation ranged from 7.6 to 10.6 years (average: 9.2 years). Average leg length discrepancy at surgery was 7.1 cm (range: 5.5 to 8.2 cm). Leg length discrepancy was successfully corrected in all the children.

### 4.2.2. Anthropometry

Height, weight, thigh circumference (measured at the level between the lower third and the upper two thirds of the distance between the upper pole of the patella and the anterior inferior iliac spine), and anterior thigh skinfold thickness measured at the same level (Cameron, 1984) were determined every time the patients had their MVC measured. Muscle and bone CSA of the thigh were calculated from anthropometric measurements using Buckley et al.'s (1987) equations.

**TABLE 4.1.**

**PHYSICAL CHARACTERISTICS OF THE SUBJECTS (n = 7)**

	<u>Beginning</u>			<u>End</u>		
	Mean	SD	Range	Mean	SD	Range
Age (years)	9.2	2.1	7.6-10.2	12.0	2.2	11.7-13.4
Height (cm) <sup>a</sup>	138.2	5.8	130-150	152.1	7.5	138-164
Weight (kg) <sup>a</sup>	42.1	6.5	32-49	47.8	8.6	37-55
Leg length discrepancy (cm) <sup>a</sup>	7.1	1.2	5.5-8.2	0		
Muscle and bone area normal leg (cm <sup>2</sup> ) <sup>a*, b</sup>	69	8.2	59-84	83.4	11.3	72-113
Muscle and bone area affected leg (cm <sup>2</sup> ) <sup>a*, b</sup>	76.3	9.3	61-92.7	79.5	11.5	63-100

<sup>a</sup> = Significantly different at the beginning and end of the study.

<sup>b</sup> = Significantly different between normal and lengthened side at the beginning and end of the study.

In <sup>a</sup> and <sup>b</sup>, when not specified,  $p < 0.05$ .

\* =  $p < 0.01$ .

#### 4.2.3. Strength measurement

Maximum voluntary isometric contraction (MVC) was measured bilaterally using a custom-made chair (Davies et al., 1988; Maffulli et al., 1992a; Maughan et al., 1983; Tornvall, 1963) (Figure 4.1.). A strain gauge was incorporated into an inextensible link between a cuff placed just proximal to the medial malleolus of the ankle to be tested and a fixed point connected to a bar about which the link could swivel. The height of the bar was adjusted for each child so that the gauges were horizontally coplanar with the ankle joint. The apparatus was calibrated before and after each test by suspending known weights ranging from 7.5 to 119.6 kg. The strain gauge gave a linear response within these limits.

During the measurement, the children's arms were kept crossed in front of the chest. Elevation of the hips was prevented by lap and chest straps. MVC was measured by asking the child to extend the knee with as much force as possible, but without kicking.

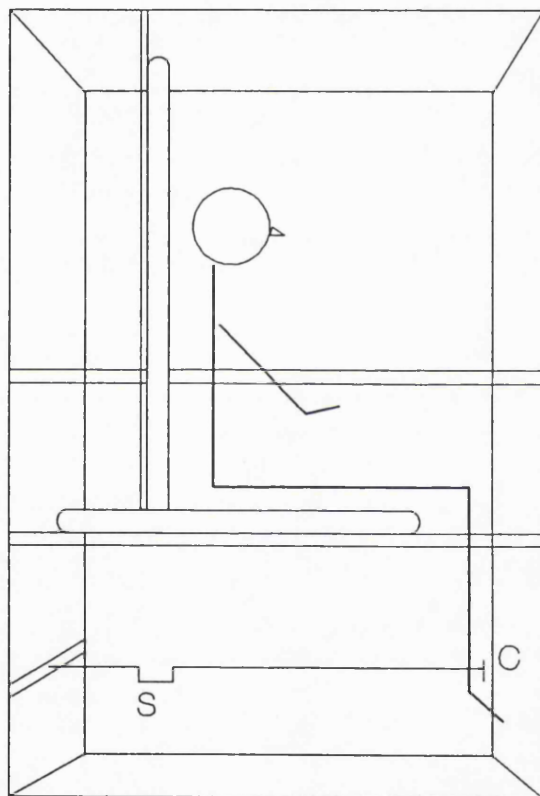
Each child was introduced to the procedure, and performed the test with the normal limb being tested first. Four attempts were recorded, and the highest was used in all subsequent analyses. Each MVC lasted an average  $1.5 \pm 0.3$  sec, and a period of rest of 20 to 30 seconds was allowed between each contraction.

This method of MVC recording has shown good reliability and reproducibility (Maffulli, 1992; Parker, 1989), and there are generally no problems in

fully recruiting the quadriceps or the elbow flexors (Rutherford et al., 1986). No fatigue effect was found in a large group of children tested using a protocol in which the order of testing was randomised in regards to the side tested first (Maffulli, 1992).

The baseline MVC measurement used in all analyses is the immediate pre-operative measurement. MVC was not measured during the lengthening process. MVC was measured two months after completion of the lengthening procedure, and at six month intervals thereafter for two years.

Figure 4.1. Schematic drawing of the chair used to measure the isometric strength of the knee extensor muscles. C = padded cuff around the ankle. S = strain gauge.



#### 4.2.4. Statistics

Results were analysed using Systat (Leland, 1988). Linear regression analysis was performed. Two-way ANOVA for repeated measures was used to evaluate any overall differences between the normal and the lengthened side of the body. A post hoc Student t-test for paired measures was applied to test any differences found. Significance was set at the 0.05 level.

### 4.3. RESULTS

#### 4.3.1. Clinical assessment

Leg length discrepancy was successfully corrected in all patients. The average femoral lengthening was 7.1 cm (range 5.5 -8.2 cm). The average percentage lengthening achieved was 23.5%.

#### 4.3.2. Knee extensor muscles strength

In the group of patients studied, the quadriceps strength of the normal side lies within normality (Maffulli, 1992; Parker et al., 1990), being 235.6 N (SD 28.4, range 205-286 N). The difference in strength between the two sides was 15.7% at the beginning and 13.1% at the end of the study (NS). By the end of the study, MVC, in absolute terms, had increased by 20.5% on the normal side, and by 24% on the lengthened side ( $p < 0.05$ ) (Table 2 and Figure 2).

Relationship between knee extensors strength and muscle and bone area of the mid thigh. The ratio of knee extensors strength to the muscle and bone area of the mid thigh was  $3.4 \text{ N} \cdot \text{cm}^{-2}$  for the normal and  $2.6 \text{ N} \cdot \text{cm}^{-2}$  for the lengthened side at the beginning of the study ( $p < 0.01$ ), and remained constant at  $3.4 \text{ N} \cdot \text{cm}^{-2}$  for the normal side (NS), while increasing to  $3.1 \text{ N} \cdot \text{cm}^{-2}$  ( $p < 0.05$ ) for the lengthened side at the end of the study. Linear regression analysis showed a high correlation between the MVC strength of the knee extensor muscles and the thigh muscle and bone CSA bilaterally (normal side:  $r = 0.76$ ,  $p < 0.05$ ; lengthened side:  $r = 0.73$ ,  $p < 0.05$ ).

TABLE 4.2.

EVOLUTION OF MAXIMAL ISOMETRIC VOLUNTARY CONTRACTION STRENGTH (n = 7)

	<u>Beginning</u>			<u>End</u>		
	Mean	SD	Range	Mean	SD	Range
Normal leg knee extensors MVC (N) <sup>a*</sup> , <sup>b</sup>	235.6	28.4	205-286	284	38.2	245-383
Leg with CFS knee extensors MVC (N) <sup>a*</sup> , <sup>b</sup>	198.8	16.9	167-234	246.5	28.3	222-293
Percent difference knee extensors strength <sup>a</sup>	15.7	4.2	7.3-10.9	13.2	3.6	8.8-16.1
Percent increase knee extensors strength, normal side <sup>d</sup>	20.5	12.3	10.1-20.2			
Percent increase knee extensors strength, lengthened side <sup>d</sup>	24	6.3	15.1-31.9			

<sup>a</sup> = Significantly different at the beginning and end of the study.

<sup>b</sup> = Significantly different at between normal and lengthened side at the beginning and end of the study.

<sup>c</sup> = Significantly different between normal and hypertrophic side only at the beginning of the study.

<sup>d</sup> = Significantly different only at the end of the study.

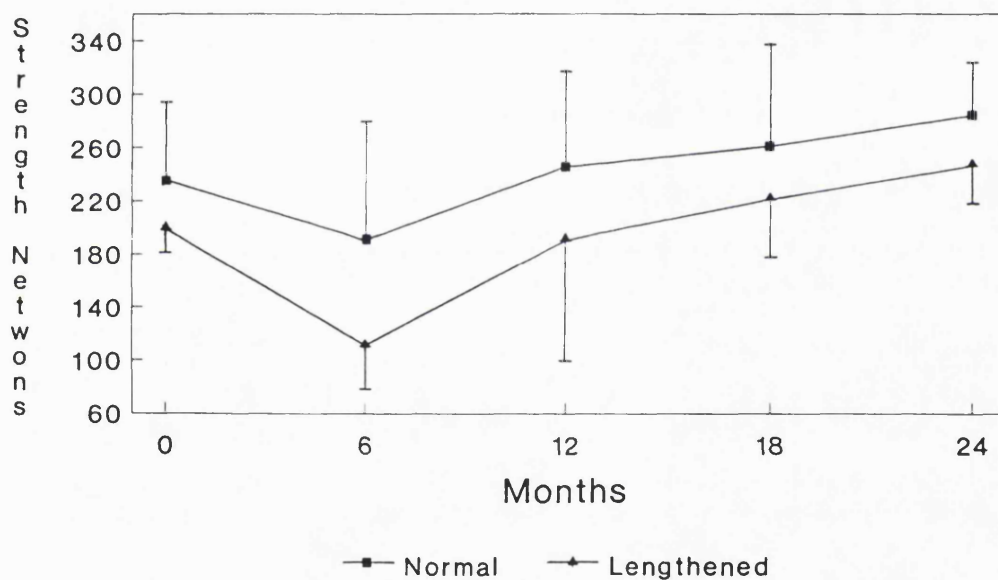
In a <sup>a</sup> and <sup>b</sup>, when not specified,  $p < 0.05$ .

\* =  $p < 0.01$ .



Figure 4.2. The evolution of maximal isometric strength in the lower limb.

## MAXIMAL ISOMETRIC STRENGTH KNEE EXTENSORS



#### 4.4. DISCUSSION

Limb lengthening produces a series of microscopic ruptures of the myofibrils, which subsequently regenerate (Calandriello, 1975; Simpson et al., 1991). The number of sarcomeres increases, exceeding the optimal overlap of actin and myosin filaments. This decreases muscle efficiency, and would explain why the muscular strength of the normal is different from that of the lengthened side (Shchurov et al., 1984; Steen et al., 1992), as is the ratio of isometric strength to CSA.

Atrophy and hypertrophy of muscle occur in response to, respectively, immobilization and training (Davies & Sargeant, 1975b). Systematic studies on the nature and course of skeletal muscle changes during normal growth are however lacking (Maffulli, 1992; Parker, 1989).

A major determinant of skeletal muscle strength is its CSA (Jones & Rutherford, 1987), but much variation within any group of subjects exists, and can be accounted for by several factors. These include difference in the lever system through which a muscle acts, the angle of pennation of the fibres, and possibly the fibre type composition of the muscle (Jones & Rutherford, 1987; Maughan et al., 1983). The stimuli for increase in strength are high levels of activity (Jones & Rutherford, 1987), and linear growth seems to play a role in pre-pubertal skeletal muscle growth (Parker et al., 1990).

In the children studied, a peculiar situation occurs, as the growth of the two sides of the body is quantitatively different. At first, the shorter femur lags behind the normal contralateral one. Following surgery, it greatly accelerates its growth rate, and, at the end of the procedure, the two sides show a similar growth rate (Paterson et al., 1989). It is still unclear whether the different pattern of linear growth may produce different soft tissue development. The knee extensor muscles of the normal side are capable of exerting greater absolute strength. Also, the capacity of exerting strength per unit of muscle and bone area in the lower limb is different.

It is not known whether the bone in the shorter, and subsequently lengthened, limb is in the same size relationship with the muscles as in the normal limb. For ethical reasons, we were unable to take CT scans to measure more directly the CSA of the muscle groups studied (Jones & Rutherford, 1987; Maughan et al., 1983), and so no conclusions can be made in this respect.

In congenital femoral hypoplasia, before lengthening the shorter leg is kept with the foot plantar flexed, while the longer leg is slightly flexed at the knee and the hip to produce some equalization. This may produce different stimuli to the lower limb muscles, with the ones of the shorter leg more stretched than the contralateral. Stretching induces muscle growth (Parker et al., 1990), and may

thus explain the similarity in the ratio between strength and cross-sectional area of the normal and lengthened limb.

Recently, it has been shown in rabbits that a free skeletal muscle graft undergoes a differential regenerative response according to the physical environment (Turk et al., 1991), with decreased tetanic tension and increased fatiguability, possibly due to a lag between muscle fibre regeneration and innervation. It is at present unknown whether these events do occur in humans.

In conclusion, the normal limb always exerted significantly greater isometric strength. The difference persisted when standardisation was made for an anthropometric estimate of thigh (muscle plus bone) CSA, and did not change significantly following limb lengthening.

CHAPTER 5

CONCLUSIONS

	Page number
5.1. CONCLUSIONS	..... 133

### 5.1. CONCLUSIONS

1. Callotasis produces reproducible lengthening even in the traditionally difficult congenitally short patients.

2. Twentyfive percent appears to be the safe limit of lengthening in these patients.

3. The process, albeit simple, needs attention to detail, and is marred by events such as pin site infections that need constant medical supervision.

4. Appropriate selection of patients is necessary, ensuring that both the child and his/her parents understand the complexity of the procedure, and are compliant with its regimen.

5. Radiography shows with reasonable accuracy the process of limb lengthening, but does not allow its reliable quantitative analysis.

6. Although most of the imaging required can be carried out by plain radiography, non-ionising methods are required to reduce the amount of radiation that these children receive.

7. Ultrasound scanning can reliably image the lengthened segment, especially in the earlier phases of lengthening. When ossification occurs, this ability is partially lost.

8. The children undergoing lengthening experience partial loss of the ability of the main muscle group of their lengthened limb to exert isometric strength. It can take up to two years to return to a normal strength production pattern.

## REFERENCES

- Abbott, L.C. The operative lengthening of the tibia and fibula. Journal of Bone and Joint Surgery 9: 128-152, 1927.
- Abbott, L.C. Lengthening of the lower extremities. California and Western Medicine 36: 6-13, 1932.
- Abbott, L.C., Saunders, J.B. The operative lengthening of the tibia and fibula. A preliminary report on the further development of the principles and technic. Annals of Surgery 110: 961-991, 1939.
- Aldegheri, R., Lavini, F. Callotasis: lengthening by callus distraction. Seminars in Orthopaedics 7: 152-157, 1992.
- Aldegheri, R., Pouliquen, J.C., Agostini, S. Limb lengthening and correction of deformities by callus distraction. Operative technique. Orthofix Srl. Bussolengo, Italy, 1-46, 1992.
- Aldegheri, R., Trivella, G., Renzi-Brivio, L., Tessari, G., Agostini, S., Lavini, F. Lengthening of the lower limbs in achondroplastic patients. Journal of Bone and Joint Surgery (British Volume) 70-B: 69-73, 1988.
- Allan, F.G. Bone lengthening. Journal of Bone and Joint Surgery (British Volume) 30-B: 490-495, 1948.
- Anderson, R. Femoral bone lengthening. American Journal of Surgery 31: 479-483, 1936.
- Anderson, W.V. Leg lengthening. Journal of Bone and Joint Surgery (British Volume) 34-B: 150, 1952.
- Aro, H.T., Wahner, H.T., Chao, E.Y.DS. Healing

patterns of transverse and oblique osteotomies in the canine tibia under external fixation. Journal of Orthopaedic Trauma 5: 351-364, 1991.

Aronson, J., Good, B., Stewart, C., Harrison, B., Harp, J. Preliminary studies of mineralization during distraction osteogenesis. Clinical Orthopaedics and Related Research 250: 43-49, 1990.

Aronson, J., Harp, J.H.Jr. Mechanical considerations in using tensioned wires in a transosseous external fixation system. Clinical Orthopaedics and Related Research 280: 23-29, 1992.

Barry, K., McManus, F., O'Brien, T. Leg lengthening by the transiliac method. Journal of Bone and Joint Surgery (British Volume) 74-B: 275-278, 1992.

Bell, D.F., Boyer, M.I., Armstrong, P.F. The use of the Ilizarov technique in the correction of limb deformities associated with skeletal dysplasia. Journal of Pediatric Orthopaedics 12: 286-290, 1992.

Bier, A. Uber Knochengeneration, uber Pseudarthrosen und uber Knochentransplantate. Archiv fur Klinikal Chirurgie 127: 1-136, 1923.

Blachier, D., Trevoux, L., Carlioz, H. Allongements progressifs du femur selon la technique de Wagner. A propos de 48 cases. Revue de Chirurgie Orthopedique et Traumatologique 72: 495-499, 1986.

Blane, C.E., Herzenberg, J.E., DiPietro, M.A. Radiographic imaging for Ilizarov limb lengthening in children. Pediatric Radiology 21: 117-120, 1991.

Bohlman, H.R. Experiments with foreign materials in



the region of epiphyseal cartilage plate of growing bones to increase their longitudinal growth. Journal of Bone and Joint Surgery 11: 365-384, 1929.

Boike, A.M., Gerber, M.R., Snyder, A.J. Brachymetatarsia. Axial lengthening by using the callus distraction technique Journal of the American Podiatric Medical Association 83: 973-378, 1993.

Bonnard, C., Favard, L., Sollogoub, I., Glorion, B. Limb lengthening in children using the Ilizarov method. Clinical Orthopaedics and Related Research 293: 83-88, 1993.

Bost, F.C., Larson, L.J. Experiences with lengthening of the femur over an intramedullary rod. Journal of Bone and Joint Surgery (American Volume) 38-A: 567-584, 1956.

Bowen, J.R., Lvy, E.J., Donohue, M. Comparison of knee motion and callus formation in femoral lengthening with the Wagner or monolateral-ring device. Journal of Pediatric Orthopaedics 13: 467-472, 1993.

Bridgman, S.A., Bennet, G.C., Evans, G.A., Stirling, J. Leg lengthening. Journal of the Royal College of Surgeons of Edinburgh 38: 101-104, 1993.

Buckley, D.C., Kudsk, K.A., Rose, B.S., Fatzinger, P., Koetting, C.A., Schlatter, M. Anthropometric and computerized tomographic measurements of lower extremity lean body mass. Journal of the American Dietetic Association 87, 196-199, 1987.

Calandriello, B. The behaviour of muscle fibres during surgical lengthening of a limb. Italian Journal of

- Orthopaedics and Traumatology 1, 231-247, 1975.
- Calhoun, J.H. Distraction osteogenesis with the Ilizarov technique. Seminars in Orthopaedics 7: 27-31, 1992.
- Calhoun, J.H., Li, F., Ledbetter, B.R., Gill, C.A. Biomechanics of the Ilizarov fixator for fracture fixation. Clinical Orthopaedics and Related Research 280: 15-22, 1992.
- Cameron, N. The measurement of human growth, pp. 1-180, Croom Helm, Beckenham, 1984.
- Canuti, M., Giorgi, B., Valenti, C. The Ilizarov apparatus in the treatment of congenital dysmetria of the leg. Italian Journal of Orthopaedics and Traumatology 14: 483-491, 1988.
- Catagni, M., Bolano, L., Cattaneo, R. Management of fibular hemimelia using the Ilizarov method. Orthopaedic Clinics of North America 22: 715-722, 1991.
- Catagni, M., Szabo, R.M., Cattaneo, R. Preliminary experience with Ilizarov method in late reconstruction of radial hemimelia. Journal of Hand Surgery (American Volume) 18: 316-321, 1993.
- Cattaneo, R. Lengthening of the upper limb. Seminars in Orthopaedics 7: 158-166, 1992.
- Cauchoux, J., Morel, G. One stage femoral lengthening. Clinical Orthopaedics and Related Research 136: 66-73, 1978.
- Chandler, D., King, J.D., Bernstein, S.M., Marrero, G., Koh, J., Hambrecht, H. Results of 21 Wagner limb

lengthenings in 20 patients. Clinical Orthopaedics and Related Research 230: 214-222, 1988.

Chapchal, G., Zeldenrust, J. Experimental research for promoting longitudinal growth of the lower extremities by irritation of the growth region of the femur and tibia. Acta Orthopaedica Scandinavica 17: 371-396, 1948.

Cheng, J.C.Y. Distraction lengthening of the forearm. Journal of Hand Surgery (British Volume) 1991; 16B: 441-445.

Codivilla, A. On the means of lengthening, in the lower limbs, the muscles and tissues which are shortened through deformity. American Journal of Orthopaedic Surgery 2: 353-369, 1905.

Coleman, S.S., Noonan, T.D. Anderson's method of tibial lengthening by percutaneous osteotomy and gradual distraction. Journal of Bone and Joint Surgery (American Volume) 49-A, 263-279, 1967.

Compere, E.L. Indications for and against the leg-lengthening operation. Journal of Bone Joint Surgery 28, 692-705, 1936.

Correll, J. Surgical correction of short stature in skeletal dysplasia. Acta Paediatrica Scandinavica Supplementum 377: 143-148, 1991.

Dal Monte, A., Donzelli, O. Tibial lengthening according to Ilizarov in congenital hypoplasia of the leg. Journal of Pediatric Orthopaedics 7: 135-138, 1987.

Dasmin, J.P., Panisset, J.C., Daunois, O.,

Gorodischer, S. Allongement des membres inferieurs: methode d'Ilizarov. SOFCOT Reunion Annuelle, Novembre 1990. Revue de Chirurgie Orthopedique et Traumatologique Supplementum 1: 46-48, 1991.

Davies, B.N. The relationship of lean limb volume to performance in the hand grip and standing long jump tests in boys and girls, aged 11.6-13.2 years. European Journal of Applied Physiology 60, 139-143, 1990.

Davies, C.T.M., Sargeant, A.J. Changes in physiological performance of the lower limb after fracture and subsequent rehabilitation. Clinical Science and Molecular Medicine 48, 107-114, 1975a.

Davies, C.T.M., Sargeant, A.J. Effects of exercise therapy on total and component tissue leg volumes of patients undergoing rehabilitation from lower limb injury. Annals of Human Biology 2, 327-337, 1975b.

Davies, C.T.M., Sargeant, A.J. Physiological responses to exercise in patients following fracture of the lower limb. Scandinavian Journal of Rehabilitation Medicine 7, 45-50, 1975c.

Davies, J., Parker, D.F., Rutherford, O.M., Jones, D.A. Changes in strength and cross sectional area of the elbow flexors as a result of isometric strength training. European Journal of Applied Physiology 57, 667-670, 1988.

De Bastiani, G., Aldegheri, R., Renzi-Brivio, L., Trivella, G. Limb lengthening by callus distraction (callotasis). Journal of Pediatric Orthopaedics 7:

129-134, 1987.

Dickson, F.D., Diveley, R.L. A new apparatus for the lengthening of legs. Journal of Bone and Joint Surgery 14: 194-196, 1932.

Ensley, N.J., Green, N.E., Barnes, W.P. Femoral lengthening using the Barnes device. Journal of Pediatric Orthopaedics 13:57-62, 1993.

Eyres, K.S., Bell, M.J., Kanis, J.A. New bone formation during leg lengthening. Evaluated by dual X-ray absorptiometry. Journal of Bone and Joint Surgery (British Volume) 75-B: 96-106, 1993a.

Eyres, K.S., Bell, M.J., Kanis, J.A. Methods of assessing new bone formation during limb lengthening. Ultrasonography, dual energy X-ray absorptiometry and radiography compared. Journal of Bone and Joint Surgery (British Volume) 75-B: 358-364, 1993b.

Fasciani, G.C., Pagnano, A., Ferraro, A.F. Measuring the degree of ossification: ultrasound velocity meter (UVM) densitometry. Analysis of reparative osteogenesis state in fractures treated with dynamic axial fixation. (Abstract) The Second Riva Congress: Current perspectives in external and intramedullary fixation. Riva del Garda, Italy, 27-31 May 1992, Abstract Book, page 92, 1992.

Fisk, J.W., Baigent, M.I. Clinical and radiological assessment of leg length. New Zealand Medical Journal 81: 477-480, 1975.

Fleming, B., Paley, D., Kristiansen, T., Pope, M. A biomechanical analysis of the Ilizarov external

- fixator. Clinical Orthopaedics and Related Research 241: 95-105, 1989.
- Franke, J., Hein, G., Simon, M., Hauch, St. Comparison of distraction epiphyseolysis and partial metaphyseal corticotomy in leg lengthening. International Orthopaedics 14: 405-413, 1990.
- Friberg, O., Nurminen, M., Korhonen, K., Soininen, E., Mattari, T. Accuracy and precision of clinical estimation of leg length inequality and lumbar scoliosis: comparison of clinical and radiological measurements. International Disability Studies 10: 49-53, 1988.
- Galardi, G. Comi, G., Lozza, L., Marchettini, P., Novarina, M., Facchini, R., Paronzini, A. Peripheral nerve damage during limb lengthening. Neurophysiology in five cases of bilateral tibial lengthening. Journal of Bone and Joint Surgery (British Volume) 72-B, 121-124, 1990.
- Gasser, B., Boman, B., Wyder, D., Schneider, E. Stiffness characteristics of the circular Ilizaov device as opposed to conventional external fixators. Journal of Biomechanic Engineering 112: 15-21, 1990.
- Giebel, G. Callus distraction. Clinical applications. Georg Thime Vrlag. Stuttgart: 1-88, 1992.
- Gofton, J.P. Persistent low back pain and leg length disparity. Journal of Rheumatology 12: 747-750, 1985.
- Green, S.A. Physiotherapy during Ilizarov fixation. Techniques in Orthopaedics 5: 61-65, 1990.
- Green, V., Maffulli, N., Hughes, T.H. Ultrasound in

bone lengthening imaging. Radiography Today 59: 14-15, 1993.

Grill, F., Dungl, P. Lengthening for congenital short femur. Results of different methods. Journal of Bone and Joint Surgery (British Volume) 73-B: 439-447, 1991.

Guarniero, R., Barros, T.E.P.Jr. Femoral lengthening by the Wagner method. Clinical Orthopaedics and Related Research 250: 154-159, 1992.

Guida, G., Gatto, S., Riccio, V. Computed tomographic studies on distraction osteogenesis. Clinical Orthopaedics and Related Research in press.

Guidera, K.J., Hess, W.F., Highhouse, K.P., Ogden, J.A. Extremity lengthening: results and complications with the Orthofix system. Journal of Pediatric Orthopaedics 11: 90-94, 1991.

Haboush, E.J., Finkelstein, H. Leg lengthening with new stabilizing apparatus. Journal of bone and Joint Surgery 14: 807-821, 1932.

Hamanishi, C., Y. Yasuwaki, H. Kikuchi, S. Tanaka, K. Tamura Classification of the callus in limb lengthening. Radiographic studies of 35 limbs. Acta Orthopaedica Scandinavica 63: 430-433, 1992.

Harmon, P.H., Krigstein, W.M. The surgical treatment of unequal leg length. Surgery, Gynecology and Obstetrics 71: 482-490, 1940.

Harris, R.I. The effect of lumbar sympathectomy on the growth of legs shortened from anterior poliomyelitis. A preliminary report. Journal of Bone and Joint

Surgery 12: 859-866, 1930.

Harris, R.I., MacDonald, J.L. The effect of lumbar sympathectomy upon the growth of legs paralyzed by anterior poliomyelitis. Journal of Bone and Joint Surgery 18: 35-45, 1936.

Herron, L.D., Amstutz, H.C., Sakai, D.N. One stage femoral lengthening in the adult. Clinical Orthopaedics and Related Research 136: 74-82, 1978.

Hoyle, D.A., Latour, M., Bohannon, R.W. Intraexaminer, interexaminer, and interdevice comparability of leg length discrepancy obtained with measuring tape and metrecom. Journal of Orthopaedic and Sports Physical Therapy 14: 263-268, 1991.

Hughes, T.H., Maffulli, N., Green, V., Fixsen, J.A. Imaging in bone lengthening. Clinical Orthopaedics and Related Research in press.

Huppertz, R., Pfeil, J., Kaps, H.P. Sonographische Verlaufskontrollen von Verlängerungsosteotomien. Zeitschrift für Orthopäde 128: 90-95, 1990.

Huurman, W.W., Jacobsen, F.S., Anderson, J.C., Chu, W.-K. Limb-length discrepancy measured with computerized axial tomographic equipment. Journal of Bone and Joint Surgery (American Volume) 69-A: 699-705, 1987.

Ikai, M., Fukunaga, T. Calculation of muscle strength per unit cross-sectional area of human muscle by means of ultrasonic measurement. International Zeitschrift für Angew Physiologie 18, 474-477, 1968.

Ilizarov, G.A. The tension-stress effect on the



genesis and growth of tissues. Part I. The influence of stability of fixation and soft-tissue preservation. Clinical Orthopaedics and Related Research 238: 249-281, 1989.

Ilizarov, G.A., Ledyayev, V.I., Shitin, V.P. The course of reparative regeneration of the compact bone in distraction osteosynthesis under different conditions of fixation of bone fragments (an experimental study). Eksperimental Khirurgia Anestesia 14: 3-21, 1969.

Janes, J.M., Jennings, W.K. Effect of induced arterio-venous fistulae on leg length: 10 year observations. Mayo Clinic Proceedings 36: 1-11, 1961.

Jones, D.A., Parker, D.F. Development of a portable strain gauge to measure human isometric muscle strength. Journal of Physiology 145, 11P, 1989.

Jones, D.A., Rutherford, O.M. Human muscle strength training: the effects of three different regimes and the nature of the resultant changes. Journal of Physiology 391, 1-11, 1987.

Karger, C., Guille, J.T., Bowen, J.R. Lengthening of congenital lower limb deficiencies. Clinical Orthopaedics and Related Research 291; 236-245, 1993.

Kawamura, H., Hosono, S., Takahashi, T., Yano, T., Kobayashi, Y. Limb lengthening by means of subcutaneous osteotomy. Journal of Bone and Joint Surgery (American Volume) 50: 851-878, 1968.

Kojimoto, H., H., Yasui, N., Goto, T., Marsudo, S., Shimomura, Y. Bone lengthening in rabbits by callus

distraction. Journal of Bone and Joint Surgery (British Volume) 70-B: 543-549, 1988.

Korzinek, K., Tepic, S., Perren, S.M. Limb lengthening and three-dimensional deformity corrections. A retrospective clinical study. Archives of Orthopaedic and Trauma Surgery 109: 334-340, 1990.

Kummer, F.J. Biomechanics of the Ilizarov external fixator. Clinical Orthopaedics and Related Research 280: 11-14, 1992.

Lascombers, P., Membre, H., Prevot, J., Barrat, E. The histomorphometry of regenerate bone in limb lengthening by the Ilizarov method. French Journal of Orthopaedic Surgery 5: 115-123, 1991.

Lee, D.Y., Choi, I.H., Chung, C.Y., Ahn, J.H., Steel, H.H. Triple innominate osteotomy for hip stabilisation and transiliac leg lengthening after poliomyelitis. Journal of Bone and Joint Surgery (British Volume) 75-B: 858-864, 1993.

Lee, D.Y., Choi, I.H., Chung, C.Y., Shim, J.S. A modified Wagner technique for femoral lengthening in skeletally mature patients with poliomyelitis. International Orthopaedics 17: 154-157, 1993.

Leland, W. Systat: the system for statistics. Systat Inc., Evanston, IL, pp. 1-959, 1988.

Leung, J.C.Y., Ma, R.Y.P., Clark, J.A., Cornish, L.S., Yau, A.C.M. Viscoelastic behaviour of tissue in leg lengthening by distraction. Clinical Orthopaedics and Related Research 139: 102-109, 1979.

Luke, D.L., Schoenecker, P.L., Blair, V.P., Capelli,

A.M. Fractures after Wagner limb lengthening. Journal of Pediatric Orthopaedics 12: 20-24, 1992.

Maffulli, N. The effects of intensive training on the musculo-skeletal system of elite young athletes. PhD Thesis, University of London, England, 1992.

Maffulli, N., Fixsen, J.A., Jackson, A.M. Muscular strength in idiopathic haemihypertrophy. Clinical Physiology 12, 135-143, 1992a.

Maffulli, N., Hughes, T., Fixsen, J.A. Ultrasonographic monitoring of limb lengthening. Journal of Bone and Joint Surgery (British Volume) 74-B: 130-32, 1992.

Maffulli, N., Pattinson, R.C., Fixsen, J.A. Lengthening of congenital limb length discrepancy using callosities: early experience of The Hospital for Sick Children. Annals of the Royal College of Surgeons of England 75: 105-110, 1993.

Magnan, B., Nogarin, L., Bragantini, A., Molinaroli, F. Interventi di allungamento delle ossa tarsali. Chirurgia del Piede 12: 261-266, 1988.

Magnuson, P.B. Lengthening of shortened bones of the leg by operation. Surgery, Gynecology and Obstetrics 17: 63-71, 1913.

Matev, I.B. Thumb reconstruction after amputation at the metacarpophalangeal joint by metacarpal lengthening. A preliminary report of three cases. Journal of Bone and Joint Surgery (American Volume) 52-A: 957-965, 1979a.

Matev, I.B. Thumb reconstruction in children through

metacarpal lengthening. Plastic and Reconstructive Surgery 64: 665-669, 1979b.

Maughan, R.J., Watson, J.S., Weir, J. Strength and cross-sectional area of human skeletal muscle. Journal of Physiology 338: 37-49, 1983.

Merloz, P. Lower limb lengthening using the Ilizarov method. Seminars in Orthopaedics 7: 167-178, 1992.

Miller, L.S., Bell., D.F. Management of congenital fibular deficiency by Ilizarov technique. Journal of Pediatric Orthopaedics 12: 651-657, 1992.

Millis, M.B., Hall, J.E. Transiliac lengthening of the lower extremity: a modified innominate osteotomy for the treatment of postural imbalance. Journal of Bone and Joint Surgery (American Volume) 61-A: 1182-1194, 1979.

Minty, I., Maffulli, N., Hughes, T., Shaw, D., Fixsen, J.A. Radiographic features of callotasis in children with limb shortening. Journal of Bone and Joint Surgery

Mitchell, G.P. L'elongation du tibia. Revue de Chirurgie Orthopedique et Traumatologique 49: 205-211, 1963.

Monticelli, G., Spinelli, R. Distraction epiphysiolysis as a method of limb lengthening. III. Clinical applications. Clinical Orthopaedics and Related Research 154: 274-282, 1981.

Monticelli, G., Spinelli, R. Leg lengthening by closed metaphyseal distraction. Italian Journal of Orthopaedics and Traumatology 9: 139-150, 1983.

Moseley, C.F. Leg lengthening. A review of 30 years. Clinical Orthopaedics and Related Research 247: 38-43, 1989.

Moseley, C.F. Leg lengthening: the historical perspective. Orthopaedic Clinics of North America 22: 555-561, 1992.

Murray, D.W., Kambouroglou, G., Kenwright, J. One-stage lengthening for femoral shortening with associated deformity. Journal of Bone and Joint Surgery (British Volume) 75-B: 566-571, 1993.

Nogarin, L., Magnan, B., Bragantini, A., Molinaroli, F. Ipometrie metatarsali congenite: tecniche di allungamento. Chirurgia del Piede 12: 397-402, 1988.

Ollier, L. Traite experimental et clinique de la regeneration des os et de la production artificielle du tissu osseux. Paris, Masson, 1867.

Ombredanne, L. Allongement d'un femur sur un membre trop coute. Bulletin et Memoirs de la Societe de Chirurgie (Paris) 39: 1177-1179, 1913.

Paktiss, A.S., Gross, R.H. Afghan percutaneous osteotomy. Journal of Pediatric Orthopaedics 13: 531-533.

Paley, D. Current techniques of limb lengthening. Journal of Pediatric Orthopaedics 8: 73-92, 1988.

Paley, D. The Ilizarov corticotomy. Techniques in Orthopaedics. 5: 41-52, 1990a.

Paley, D. Problems, obstacles, and complications of limb lengthening by the Ilizarov technique. Clinical Orthopaedics and Related Research 250: 81-104, 1990b.

Paley, D., Chaudray, M., Pirone, A.M., Lentz, P., Katz, D. Treatment of malunions and mal-nonunions of the femur and tibia by detailed preoperative planning and the Ilizarov techniques. Orthopaedic Clinics of North America 21: 667-691, 1990.

Paley, D., Herzenberg, J.E., Moar, D., Tetsworth, K. Femoral lengthening by simultaneous external fixation and rodding. Third Conference of the International Society for Fracture Repair (ISFR 92). September 24-26, Brussel, Belgium. Book of Abstracts: 172.

Paley, D., Tetsworth, K. Percutaneous osteotomies: osteotome and Gigli saw techniques. Orthopaedic Clinics of North America 22: 613-624, 1991.

Parker, D.F. Factors controlling the development and strength of human skeletal muscle. PhD Thesis, University of London, England, 1989.

Parker, D.F., Round, J.M., Sacco, P., Jones, D.A. A cross sectional survey of upper and lower limb strength in boys and girls during childhood and adolescence. Annals of Human Biology 17, 199-211, 1990.

Paterson, J.M.H., Waller, C.S., Catterall, A. Lower limb lengthening by a modified Wagner technique. Journal of Pediatric Orthopaedics 9, 129-133, 1989.

Pease, C.N. Local stimulation of growth of long bones. A preliminary report. Journal of Bone and Joint Surgery (American Volume) 34-A: 1-24, 1952.

Peretti, G., Memeo, A., Formentoni, A., Di Lelio, A., Marinoni, E.C. Gli allungamenti degli arti inferiori:

il valore dell'ecografia nella valutazione delle varie fasi del rigenerato osseo. Chirurgia degli Organi di Movimento 73: 53-58, 1987.

Peretti, G., Memeo, A., Paronzini, A., Marinoni, E.C. Methods for the study of bone regeneration in lengthening of the limbs. Italian Journal of Orthopaedics and Traumatology 15: 217-222, 1988.

Phalen, G.S., Chatterton, C.C. Equalizing the lower extremities. Clinical considerations of leg lengthening versus leg shortening. Surgery 12, 768-781, 1942.

Pouliquen, J.C., Ceolin, J.L., Gorodischer, S., Dasmin, J.P. Allongement des membres inferieurs par callotasis. SOFCOT Reunion Annuelle, Novembre 1990. Revue de Chirurgie Orthopedique et Traumatologique Supplementum 1: 48-50, 1991.

Price, C.T., Cole, J.D. Limb lengthening by callotasis for children and adolescents. Early experience. Clinical Orthopaedics and Related Research 250: 105-111, 1992.

Putti, V. The operative lengthening of the femur. Journal of the American Medical Association 77: 934-935, 1921.

Rachmiel, A., Potparic, Z., Jackson, I.T., Sugihara, T., Clayman, L., Topf, J.S., Forte', R.A. Midface advancement by gradual distraction. British Journal of Plastic Surgery 46: 201-207, 1993.

Raschke, M.J., Mann, J.W., Oedekoven, G., Claudi, B.F. Segmental transport after unreamed intramedullary reaming. Preliminary report of a 'monorail' system.

Clinical Orthopaedics and Related Research 282: 233-240, 1992.

Renzi-Brivio, L., Lavini, F., De Bastiani, G. Lengthening in the congenital short femur. Clinical Orthopaedics and Related Research 250: 112-116, 1990.

Ricciardi, L., Perissinotto, A., Visentin, E. Ultrasonography in the evaluation of osteogenesis in fractures treated with Hoffmann external fixation. Italian Journal of Orthopaedics and Traumatology 12: 197-205, 1986.

Richardson, J.B., Cunningham, J.L., Kenwright, J., O'Connor, B.T. Fracture stiffness as a measure of healing. (Abstract) The Second Riva Congress: Current perspectives in external and intramedullary fixation. Riva del Garda, Italy, 27-31 May 1992, Abstract Book, page 93, 1992.

Ring, P.A. Experimental bone lengthening by epiphysial distraction. British Journal of Surgery 46: 169-173.

Ring, P.A. Congenital short femur. Simple femoral hypoplasia. Journal of Bone and Joint Surgery (British Volume) 41-B, 73-79, 1959.

Rosslein, R. First experience with a distraction apparatus prototype (SM-Fix-Phalanx Distractor) for phalanges lengthening. European Journal of Pediatric Surgery 3: 231-235, 1993

Rutherford, O.M., Jones, D.A., Newham, D.J. Clinical and experimental application of the percutaneous twitch superimposition technique for the study of human muscle activation. Journal of Neurology,



Neurosurgery and Psychiatry 49, 1288-1291, 1986.

Ruter, A., Brutscher, R. Die Behandlung ausgedehnter Knochendefekte am Unterschenkel durch die Verschiebeosteotomie nach Ilizarov. Chirurg 59: 357-359, 1988.

Sargeant, A.J., Davies, C.T.M. Limb volume, composition, and maximum aerobic power output in relation to habitual 'preference' in young male subjects. Annals of Human Biology 4, 49-55, 1977a.

Sargeant, A.J., Davies, C.T.M. The effect of disuse muscular atrophy on the forces generated during dynamic exercise. Clinical Science and Molecular Medicine 53, 183-188, 1977b.

Schwartzman, V., Schwartzman, R. Corticotomy. Clinical Orthopaedics and Related Research 280: 37-47, 1992.

Shapiro, F. Developmental patterns of lower extremity discrepancies. Journal of Bone and Joint Surgery (American Volume) 64-A, 639-651, 1982.

Shchurov, V.A., Ivanova, T.I., Bogomyagkov, V.S. Dependence of blood supply of the leg on its longitudinal dimensions and biomechanical properties of the skeletal muscle. Fiziologiya Cheloveka 10, 281-286, 1984 (in Russian).

Shchurov, V.A., Kudrin, B.I., Shevtzov, V.I., Ivanova, T.I. Evaluation of level of restoration of muscle function of the elongated extremity. Ortopadia Trvmatologia Protezionica 8, 9-11, 1985 (in Russian).

Scott, I.R., Saleh, M. Current techniques in leg lengthening. Surgery 1992; 16: 217-223.

Sidor, M.L., Golyakhovski, V., Frankel, V.H. Humeral lengthening and bone transport using the Ilizarov technique. Bulletin of the Hospital for Joint Diseases Orthopaedic Institute 52: 13-16, 1992.

Simpson, A.H.R.W., Williams, P.E., Kyberd, P.J., Goldspink, G., Kenwright, J. The response of muscle to different rates of distraction. Journal of Bone and Joint Surgery (British Volume) 73-B, 124 (Supplementum II), 1991.

Sofield, H.A. Leg lengthening. Surgical Clinics of North America 19: 69-78, 1939.

Sofield, H.A., Blais, S.J., Millar, E.A. Leg lengthening. A personal follow up of 40 patients some 20 years after the operation. Journal of Bone and Joint Surgery (American Volume) 40A, 311-322, 1958.

Sproul, J.T., Price, C.T. Recent advances in limb lengthening. Part I: clinical advances. Orthopaedic Review 21: 307-314, 1992a.

Sproul, J.T., Price, C.T. Recent advances in limb lengthening. Part II: biological advances. Orthopaedic Review 21: 425-430, 1992b.

Steedman, J.T.Jr., Peterson, H.A. Brachymetatarsia of the first metatarsal treated by surgical lengthening. Journal of Pediatric Orthopaedics 12: 780-785, 1992.

Steen, H., Bjerkreim, I., Holm, I., Folleras, G., Ludvigsen, P. Muscle strength measurements in limb lengthening by callotaxis. A prospective study: preliminary results. (Abstract) The Second Riva Congress: Current perspectives in external and

intramedullary fixation. Riva del Garda, Italy, 27-31 May 1992, Abstract Book, page 235, 1992.

Tachibana, T., Matsubara, T., Mizuno, K., Hirohata, K. Enhancement of new bone formation by hematoma at fracture site. Journal of the Japanese Orthopaedic Association 65: 349-358, 1991.

Tajana, G.F., Morandi, M., Zembo, M.M. The structure and development of osteogenetic repair tissue according to Ilizarov technique in man. Characterization of extracellular matrix. Orthopedics 12: 515-523, 1989.

Terjesen, T., Benum, P., Rossvoll, I., Svenningsen, S., Isern, A.E.F. Leg length discrepancy measured by ultrasonography. Acta Orthopaedica Scandinavica 62: 121-124, 1991.

Tetsworth, K., Krome, J., Paley, D. Lengthening and deformity correction of the upper extremity by the Ilizarov technique. Orthopaedic Clinics of North America 22: 689-713, 1992.

Tiedeman, J.J., Lippiello, L., Connolly, J.F., Strates, B.S. Quantitative roentgenographic densitometry for assessing fracture healing. Clinical Orthopaedics and Related Research 253: 279-286, 1988.

Tjernstrom, B., Thoumas, K.A., Pech, P. Bone remodeling after leg lengthening: evaluation with plain radiographs, and computed tomography and magnetic resonance imaging scans. Journal of Pediatric Orthopaedics 12: 751-755, 1992.

Tornvall, G. Assessment of physical capabilities with

special reference to the evaluation of maximal voluntary isometric muscle strength and maximal working capacity. Acta Physiologica Scandinavica 58, Supplementum 201, 1-102, 1963.

Turk, A.E., Ishida, K., Kobayashi, M., Narloch, J., Kinney, B.M., Verity, M.A., Roy, R.R., Edgerton, V.R., Miller, T.A. The effects of dynamic tension and reduced graft size on muscle regeneration in rabbit free muscle grafts. Plastic and Reconstructive Surgery 88, 299-309, 1991.

Vade, A., Eissenstat, R. Radiographic features of bone lengthening procedures. Radiology 174: 531-537, 1990.

Vanderhoeft, P.J., Kelly, P.J., Janes, J.M., Peterson, L.F.A. Growth and structure of bone distal to an arterio-venous fistula: quantitative analysis of tetracycline-induced transverse growth patterns. Journal of Bone and Joint Surgery (British Volume) 45-B: 582-596, 1963.

Van Roermund, P.M., Romeny, B.M.T.H., Schoonderwoert, G.J., Brandt, C.J.W.M., Sijbrandij, S., Renooij, W. The use of computed tomography to quantitate bone formation after distraction epiphysiolysis in the rabbit. Skeletal Radiology. 16: 52-56, 1987.

Van Roermund, P.M., Hoekstra, B., Romeny, B.M.T.H., Renooij, W. Bone healing during lower limb lengthening by distraction epiphysiolysis. Journal of Nuclear Medicine 29: 1259-1263, 1988.

Velazquez, R.J., Bell, D.F., Armstrong, P.F., Babyn,

P., Tibshirani, R. Complications of use of the Ilizarov technique in the correction of limb deformities in children. Journal of Bone and Joint Surgery (American Volume) 75-A: 1148-1156, 1993.

Vilarrubias, J.M., Ginebreda, I., Jimeno, E. Lengthening of the lower limbs and correction of lumbar hyperlordosis in achondroplasia. Clinical Orthopaedics and Related Research 250: 143-149, 1990.

Villa, A., Paley, D., Catagni, M.A., Bell., D., Cattaneo, R. Lengthening of the forearm by the Ilizarov technique. Clinical Orthopaedics and Related Research 250: 125-137, 1990.

Wagner, H. Operative lengthening of the femur. Clinical Orthopaedics and Related Research 136: 125-142, 1978.

Wagner, H. Allongement chirurgical du femur. A propos d'une serie de 58 cas. Annales de Chirurgie 43: 263-275, 1980.

Walker, C.W., J. Aronson, P.A. Kaplan, W.M. Molpus, J.J. Seibert Radiologic evaluation of limb-lengthening procedures. American Journal of Roentgenology 156: 353-358, 1991.

Wakisaka, T., Yasui, N., Kojimoto, H., Takasu, M., Shimomura, Y. A case of short metatarsal bones lengthened by callus distraction. Acta Orthopaedica Scandinavica 59: 194-196, 1988

Wasserstein, I. Twenty-five years' experience with lengthening of shortened lower extremities using cylindrical allografts. Clinical Orthopaedics and

Related Research 250: 150-153, 1990.

Westin, G. Femoral lengthening using a periosteal sleeve. Report of twenty-six cases. Journal of Bone and Joint Surgery (American Volume) 49-A: 836-854, 1967.

White, S.H., Kenwright, J. The timing of distraction of an osteotomy. Journal of Bone and Joint Surgery (British Volume) 72-B: 356-361, 1990.

White, S.H., Kenwright, J. The importance of delay in distraction of osteotomies. Orthopaedic Clinics of North America 22: 569-579, 1992.

Wilde, G.P., Baker, G.C.W. Circumferential periosteal release in the treatment of children with leg-length inequality. Journal of Bone and Joint Surgery (British Volume) 69-B: 817-821, 1987.

Williamson, S. A comparison of imaging techniques for leg lengthening osteotomies. Radiography Today 57: 20-21, 1991.

Woerman, A.L., Binder-Macleod, S.A. Leg length discrepancy assessment: accuracy and precision in five clinical methods of evaluation. Journal of Orthopaedic and Sports Physical Therapy 5: 230-239, 1984.

Yadav, S.S. Double oblique diaphyseal osteotomy. A new technique for lengthening of deformed and short lower limbs. Journal of Bone and Joint Surgery (British Volume) 75-B: 962-966, 1993.

Young, J.W.R., Kostrubiak, I.S., Resnick, C.S., Paley, D. Sonographic evaluation of bone production at the distraction site in Ilizarov limb-lengthening proce-

dures. American Journal of Roentgenology 154: 125-8, 1990a.

Young, J.W.R., Kovelman, H., Resnick, C.S., Paley, D. Radiologic assessment of bones after Ilizarov procedures. Radiology 177: 89-93, 1990b.

Young, N.L., Davis, R.J., Bell, D.F., Redmond, D.M. Electromyographic and nerve conduction changes after tibial lengthening by the Ilizarov method. Journal of Pediatric Orthopaedics 13: 473-477, 1993.

PAPERS BOUND IN



# ULTRASONOGRAPHIC MONITORING OF LIMB LENGTHENING

NICOLA MAFFULLI, TUDOR HUGHES, JOHN A. FIXSEN

*From the Hospitals for Sick Children, London*

Limb lengthening in nine patients was monitored by radiographs and by ultrasound scans. The distraction gap appeared as a sonolucent area within which echogenic foci developed soon after distraction commenced. By seven weeks a new cortex was detected, and a medullary canal began to develop between seven and eight weeks. Ultrasound scanning can be used to measure distraction, but it was not as useful as radiographs in detecting angulation. Its use in patients undergoing limb lengthening could reduce their exposure to radiation.

During limb lengthening procedures, the quality and alignment of the newly formed bone are usually evaluated with anteroposterior and lateral radiographs taken at intervals of one or two weeks (Young et al 1990b). The decisions, whether to continue or stop the distraction and when to remove the frame, are based on the radiographic density of the new bone and the degree of its corticomedullary differentiation. Since lengthening may take many

weeks, the patient may suffer repeated exposure to radiation; and the assessment of the quality of the new bone is imprecise.

We need a less invasive and more objective method of monitoring new bone formation. Recently, dichromatic bone densitometry (Peretti et al 1988), and ultrasonography (Ricciardi, Perissinotto and Visentin 1986; Peretti et al 1987; Huppertz, Pfeil and Kaps 1990;

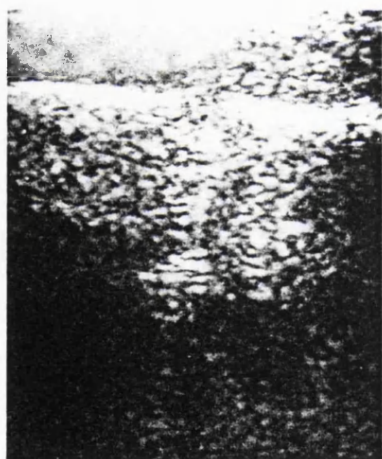


Fig. 1a

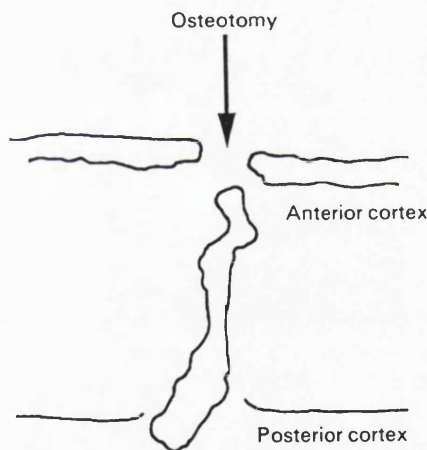


Fig. 1b

Figure 1 - a) Longitudinal ultrasound scan of a distracted corticotomy site immediately after commencing distraction; b) explanatory diagram.

N. Maffulli, MD, DSMSA, DSMSB, Clinical Research Fellow and Orthopaedic Registrar  
T. Hughes, FRCS Ed, Radiology Registrar  
J. A. Fixsen, MChir, FRCS, Consultant Orthopaedic Surgeon  
The Hospitals for Sick Children, Great Ormond Street, London WC1N 3JH, England.

Correspondence should be sent to Dr N. Maffulli at the Department of Orthopaedics, Newham General Hospital, Glen Road, London E13 8RU, England.

© 1992 British Editorial Society of Bone and Joint Surgery  
0301-620X/92/1275 \$2.00  
*J Bone Joint Surg [Br]* 1992; 74-B: 130-32.

Young et al 1990a; Blane, Herzenberg and Di Pietro 1991) have been used.

We report our experience of monitoring limb lengthening by ultrasound.

## PATIENTS AND METHODS

We examined nine patients, eight to ten years old. The reasons for limb lengthening were femoral hypoplasia (4), tibial hypoplasia (4) and diaphyseal aclasia of the




Fig. 2a

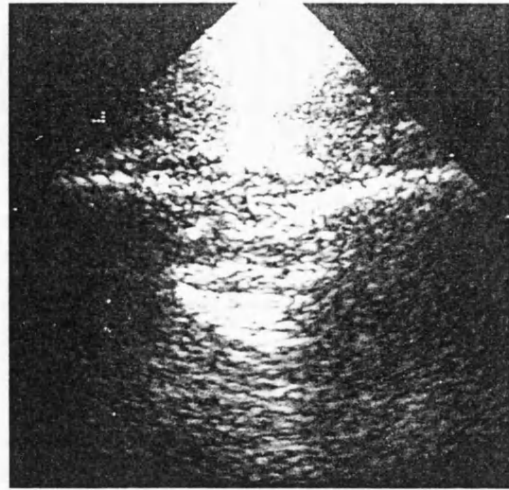


Fig. 2b

Figure 2 – a) Disorganised echogenic foci in the distraction gap, two weeks after starting distraction; b) at four weeks the foci have become aligned, parallel to the long axis of the bone.

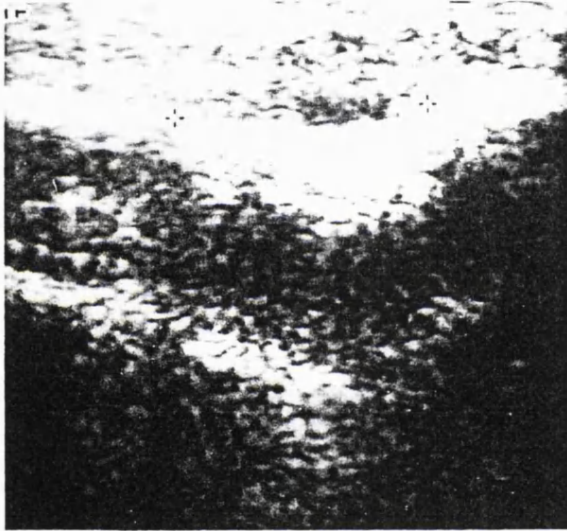


Fig. 3

Ultrasound scan at eight weeks, showing the formation of a medullary canal.

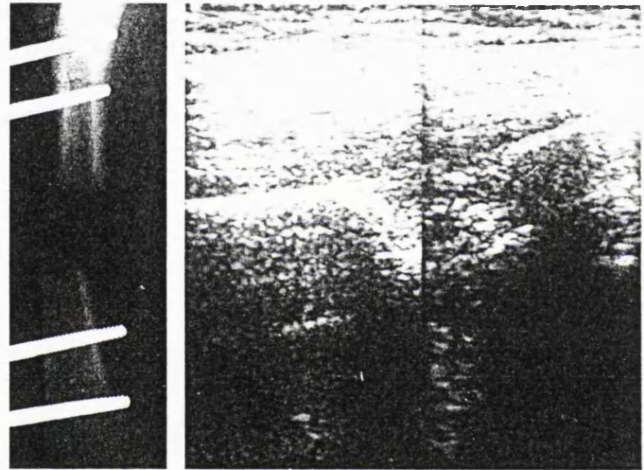


Fig. 4a

Fig. 4b

Figure 4 – a) The radiograph clearly shows angulation at the corticotomy site; b) the ultrasound scan is more difficult to interpret. In the ultrasound scan, the cephalad end of the bone is on the right.

forearm (1). Leg length discrepancy ranged from 4.5 to 8 cm, and the forearm was 26 mm short. All patients had pre-operative scanograms.

The operative techniques used were those described by Ilizarov, Lediaeov and Shitin (1969), De Bastiani et al (1987) and Paley et al (1990). Distraction was started seven to ten days after corticotomy (White and Kenwright 1990), and was continued for an average period of one month per centimetre.

**Ultrasound scanning technique.** Sonograms were obtained in the longitudinal and coronal planes using a 5 MHz phase array or a linear array transducer on an Acuson 128 unit (Acuson Ltd, England). The images were photographed. The radiographs and the ultrasound scans were evaluated by a radiologist (TH) and by either of the

orthopaedic surgeons involved in the study. They noted any malalignment and recorded the size of the gap at the corticotomy and the degree of maturity of the new bone.

## RESULTS

An intact cortex produces a clear-cut acoustic shadow and the distraction gap therefore appears as a sonolucent area (Fig. 1). Initially a few echogenic foci are seen in the gap (Fig. 2a). About four weeks after distraction is started, these echogenic areas begin to show longitudinal alignment (Fig. 2b) and by seven weeks a new cortex begins to appear close to the bone ends. A medullary canal begins to form at seven to eight weeks (Fig. 3). Once corticomedullary differentiation has occurred,

# Lengthening of congenital limb length discrepancy using callotasis: early experience of The Hospital for Sick Children

**Nicola Maffulli MD PhD DSMSA MIBiol**

*Clinical Research Fellow and Orthopaedic Registrar*

**Rodney C Pattinson FRACS**

*Clinical Research Fellow and Orthopaedic Senior Registrar*

**John A Fixsen MChir FRCS**

*Consultant Orthopaedic Surgeon*

The Hospital for Sick Children, London

**Key words:** Limb lengthening; Corticotomy; Congenital anomalies

Seventeen patients were reviewed after callotasis lengthening for congenital limb length discrepancy. The average age at lengthening was 10.8 years. Length discrepancy before lengthening ranged from 4.5 cm to 12 cm for the leg, and 24 mm to 30 mm for the forearm. At completion of the lengthening process, all but one patient had their discrepancy corrected successfully. The difficulties encountered were classified into problems, obstacles and complications. All patients suffered from superficial infection, but in only one case did this become a complication, resulting in a residual femoral discrepancy of 2 cm. Of the other three patients who suffered a complication, one fractured through the newly formed bone. The fracture was treated conservatively. In two further femoral lengthenings, the fixator had to be exchanged under general anaesthesia because it had reached its maximum excursion. Callotasis appears to be a safe and reliable method for correcting congenital limb length discrepancy in children.

Lengthening procedures have become a reliable and predictable means of correcting limb length discrepancies (1-4).

The modern technique involves:

- 1 A corticotomy of the structural bone of the shorter limb segment, whereby, through a small periosteal defect, only the cortex is divided (3,5);
- 2 The application of a circular (3) or a monoaxial (2) distractor proximal and distal to the corticotomy;
- 3 A 7 to 10 day delay to allow early callus formation (6);
- 4 The gradual progressive distraction of the corticotomy, usually at a rate of 0.25 mm four times a day (2,3).

Reports on the results of the callotasis methods have mainly originated from the USSR (3), Italy (1,2) and, lately, from the USA (7,8). English experience using De Bastiani *et al.*'s (2) technique has not been published previously.

We report our preliminary experience of the process of limb lengthening using the Orthofix® device for children with congenital limb length discrepancy.

## Patients and methods

From 1987 to 1990, 17 patients completed 18 bone segment lengthening procedures using the Orthofix device (2). Of those lengthenings, 15 were performed in children for correction of leg length discrepancies. Three children had an ulna lengthened because of diaphyseal aclasis. Eight femurs (average discrepancy 7 cm), seven

Table I. Characteristics of the patients

Patient	Sex	Age at operation	Aetiology	Length discrepancy	Length gained	Healing index (day/cm)	Percentage lengthening
<i>Femoral lengthening</i>							
1	F	7 7/12	CFS	5.5 cm	5.5 cm	27	21
2	M	9 7/12	CFS	7.5 cm	7.5 cm	28	29
3*	M	10 1/12	Ollier's disease	6 cm	6 cm	28	21
4	M	9 3/12	CFS	7.5 cm	7.5 cm	29	28
5	M	10 6/12	CFS	7.5 cm	5.5 cm	32	23
6	M	9 3/12	CFS	8.2 cm	8.2 cm	29	23
7	F	8 9/12	CFS	7 cm	7 cm	28	22
8	M	9 5/12	CFS	6.8 cm	6.8 cm	30	21
CFS, congenital femoral shortening							
<i>Tibial lengthening</i>							
9	F	5 1/12	Popliteal web syndrome	5 cm	5 cm	31	26
10	F	13 4/12	Posterior bowing	5 cm	5 cm	51	18
11*	M	10 1/12	Ollier's disease	6 cm	6 cm	28	24
12	F	12 1/12	CTS	6.7 cm	6.5 cm	32	21
13	M	13 1/12	CTS	6 cm	6 cm	31	23
14	F	10 8/12	CTS	6.2 cm	6.2 cm	30	22
15	M	11 2/12	Popliteal web syndrome	5 cm	5 cm	48	20
CTS, congenital tibial shortening							
<i>Forearm lengthening</i>							
16	F	7 3/12	DA	26 mm	26 mm	39	19
17	M	8 6/12	DA	30 mm	30 mm	37	18
18	M	7 1/12	DA	24 mm	24 mm	39	20
DA, diaphyseal aclasis							

\* Patients 3 and 11 had a simultaneous ipsilateral femoral and tibial lengthening

tibias (average discrepancy 5.7 cm) and three ulnas (average discrepancy 26.6 mm) were thus lengthened.

The children were not affected by any form of dwarfism. The causative factors and the main characteristics of the patients are summarised in Table I. Age at operation ranged from 7.1 years to 13.4 years (average 10.8 years). Leg length discrepancy at the time of surgery ranged from 5 cm to 12 cm, and the average forearm length discrepancy was 26.6 mm. Before surgery, all patients were evaluated clinically and with plain radiographs of both limbs and/or plain or CT scans.

The operative technique used was the one described by De Bastiani *et al.* (2), Ilizarov *et al.* (3), and Paley *et al.* (9). Distraction was applied 7 to 10 days after the initial corticotomy (6), and the time taken for full bridging was approximately 1 month per centimetre (9). All children required regular physiotherapy to retain mobility in the joints proximal and distal to the bone segment lengthened (10).

The process of lengthening was evaluated clinically and radiographically, using both radiography (11,12) and ultrasound scanning (13,14). Clinical and radiological evaluation of the patients and of the problems encountered was carried out at 1–2 week intervals (15).

The healing index was calculated dividing the time in days from the initial corticotomy to the removal of the fixator by the amount of lengthening obtained in centimetres.

According to Paley's (15) classification, a *problem* was defined as a potentially expected difficulty arising during the distraction or fixation period that is fully resolved by the end of the treatment period non-operatively.

An *obstacle* was defined as a potentially expected difficulty arising during the distraction or fixation period that is fully resolved by the end of the treatment period operatively.

*Complications* were defined as a local or systemic intra- or perioperative complication, or a difficulty during

distraction or fixation that is not resolved by the end of the treatment period, and any early or late post-treatment difficulty. True complications were further divided into those interfering with the original goals of treatment and those that did not.

## Results

### Clinical assessment

Limb length discrepancy was corrected successfully in all but one patient, in whom, due to a persistent superficial infection, the fixator was removed and a residual discrepancy of 2 cm was accepted.

### Femoral lengthening

The average femoral lengthening was 6.8 cm (range 5.5–8.2 cm), with an average healing index of 28.9 days. The average percentage lengthening achieved was 23.5%. In one case, when the distractor was locked in the fully extended position, it bent forming an angle of about 170° (Fig. 1). As the amount of lengthening required had been achieved, it was decided not to change the distractor, and accept the position with some varus angulation at the lengthening site.

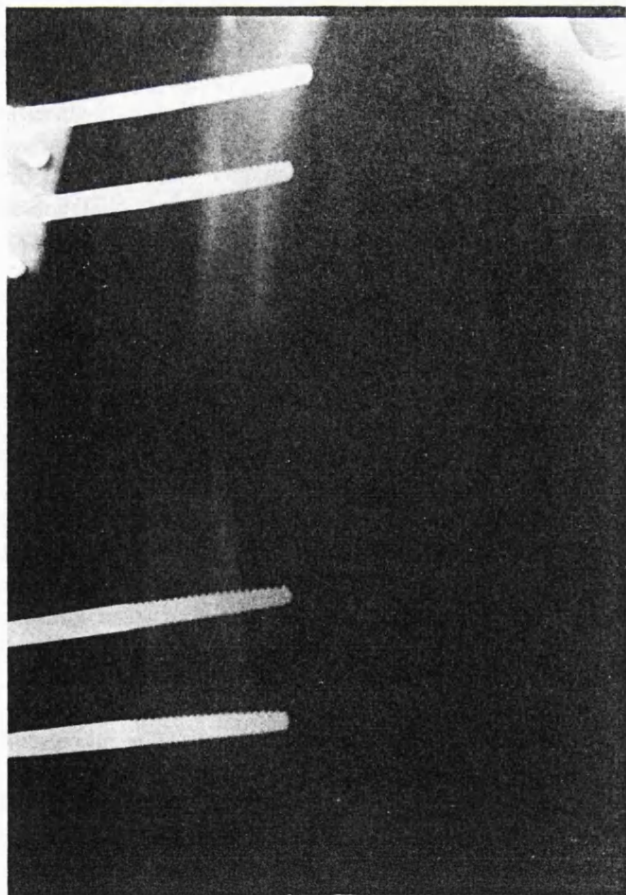


Figure 1. Angulation at the corticotomy site, after locking of the fixator in the fully extended position.

Table II. Difficulties encountered

	Problems	Obstacles	Complications
Femur	8	1	3
Tibia	7	1	1
Ulna	3	1	–

### Tibial lengthening

The average tibial lengthening was 5.7 cm (range 5–6.5 cm), with an average healing index of 35.8 days. The average percentage lengthening achieved was 22%. All but one patient were protected in a below-knee walking plaster-of-Paris cast for 1 month after the fixator had been removed, although the radiographic appearance at the time of fixator removal showed full bridging.

### Ulnar lengthening

The average ulnar lengthening was 26.6 mm, and the healing index 38.3 days per centimetre. The average percentage lengthening achieved was 19%.

### Radiographic features of lengthening

The corticotomy created a defect clearly evident on radiographs. Serial radiographic examination was employed in all patients. Progressive evidence of consolidation of the newly formed bone was seen. The formation of a medullary canal was observed starting from the 7th to the 8th week, and this progressed until a fully formed canal was seen. In no cases were ossification defects detected radiographically. In addition, serial ultrasound scanning was used in some patients. The results have been reported elsewhere (14).

### Difficulties encountered (Table II)

**Problems.** Despite regular daily local cleansing, all children developed superficial infection at the pin sites. These were treated by local cleansing, dressing and oral antibiotics.

**Obstacles.** In two cases (one femoral and one ulnar lengthening), the families were unreliable, and the child needed admission to supervise the initial lengthening period.

In a boy undergoing simultaneous femoral and tibial lengthening for Ollier's disease, a flexion contracture of 30° at the knee developed. This resolved over 12 weeks with regular physiotherapy. Lengthening was stopped for 1 week, but this did not interfere with the final result of the process.

**Complications.** In one femoral lengthening, it was possible to detect an area of bone erosion around the more proximal of the two distal pins. This was associated with

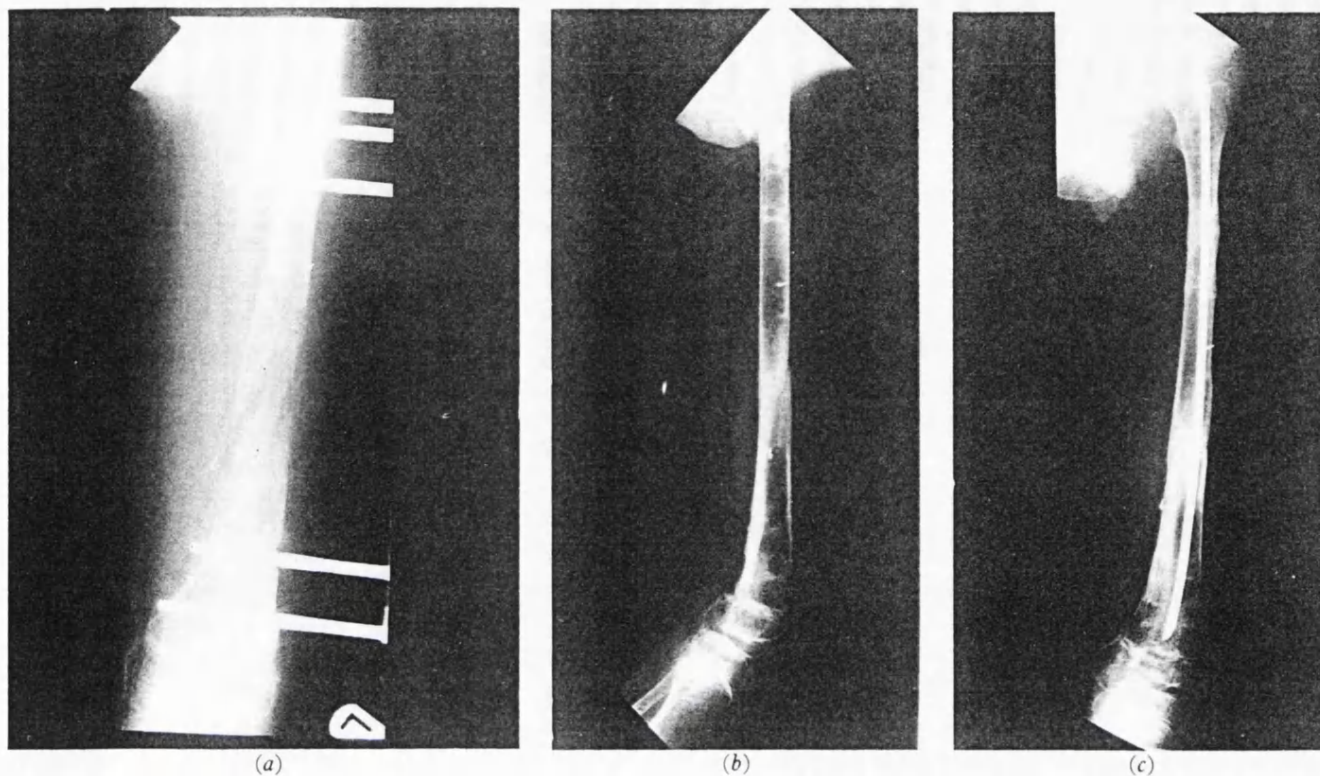


Figure 2. (a) Bone erosion around the more proximal of the two distal pins. Periosteal elevation is also evident on the medial side of the distal femur. (b), After removal of the fixator, the femur was protected in a plaster-of-Paris cast before (c) a rod was inserted.

periosteal elevation medially (Fig. 2a). The fixator was removed because of persisting infection and the femur protected in a long leg plaster-of-Paris back slab for 2 weeks (Fig. 2b). Oral antibiotics were given and an intramedullary rod inserted when the pin sites were healed (Fig. 2c). A residual discrepancy of 2 cm was accepted.

In two children undergoing femoral lengthening, the fixator was exchanged under general anaesthesia because its maximum excursion had been reached. Lengthening proceeded uneventfully.

In the first patient undergoing tibial lengthening for congenital short tibia with a leg length discrepancy of 6 cm near skeletal maturity, the newly formed bone fractured 4 weeks after the removal of the device. He was treated conservatively in a plaster-of-Paris cast for 10 weeks. Recovery was uneventful (Fig. 3). This experience prompted us to protect all tibial lengthening patients in a below-knee walking cast for 4 weeks after the removal of the fixator.

## Discussion

Reliable correction of congenital limb length discrepancy has recently been achieved using the principle of progressive distraction of the corticotomy site (2,3,16).

Our results compare favourably with those reported by De Bastiani *et al.* (2), and, more recently, Price and Cole (8) using the same method. All but one of the patients in

this series achieved the desired length, and all were capable of undertaking their normal activities during the lengthening process. All patients suffered from superficial infection of the pin sites, which can be considered normal, given the stresses placed on the skin around the pin, and the continuous microtrauma that the skin undergoes in these cases (4). Aggressive antibiotic treatment is mandatory to avoid spreading of the infection.

Comparison of the current methods of limb lengthening by Ilizarov *et al.* (3,16), De Bastiani *et al.* (2), Monticelli and Spinelli (17) and other techniques (18,19) is difficult, given the inclusion criteria of patients in the various studies, and the biomechanical characteristics of the different distraction devices used (20).

In the present study, the healing index was quite different in the three bony segments lengthened, with the femur averaging 28.9 days/cm, the tibia 35.8 days/cm, and the ulna 38.3 days/cm. Although the number of patients in each group is too small to allow any statistical analysis, these differences may be significant, as they imply a longer treatment period in the lengthening of the same absolute tibial versus femoral discrepancy. The reasons for this are not clear, but they could be connected with the deeper location, and hence greater vascularity and muscular protection, of the femur. Also, bifocal lengthening could be considered to shorten the duration of the whole procedure, both in the lower limb and in the upper limb (4).

Several factors must be considered when planning a lengthening procedure. Most important are the aetiology

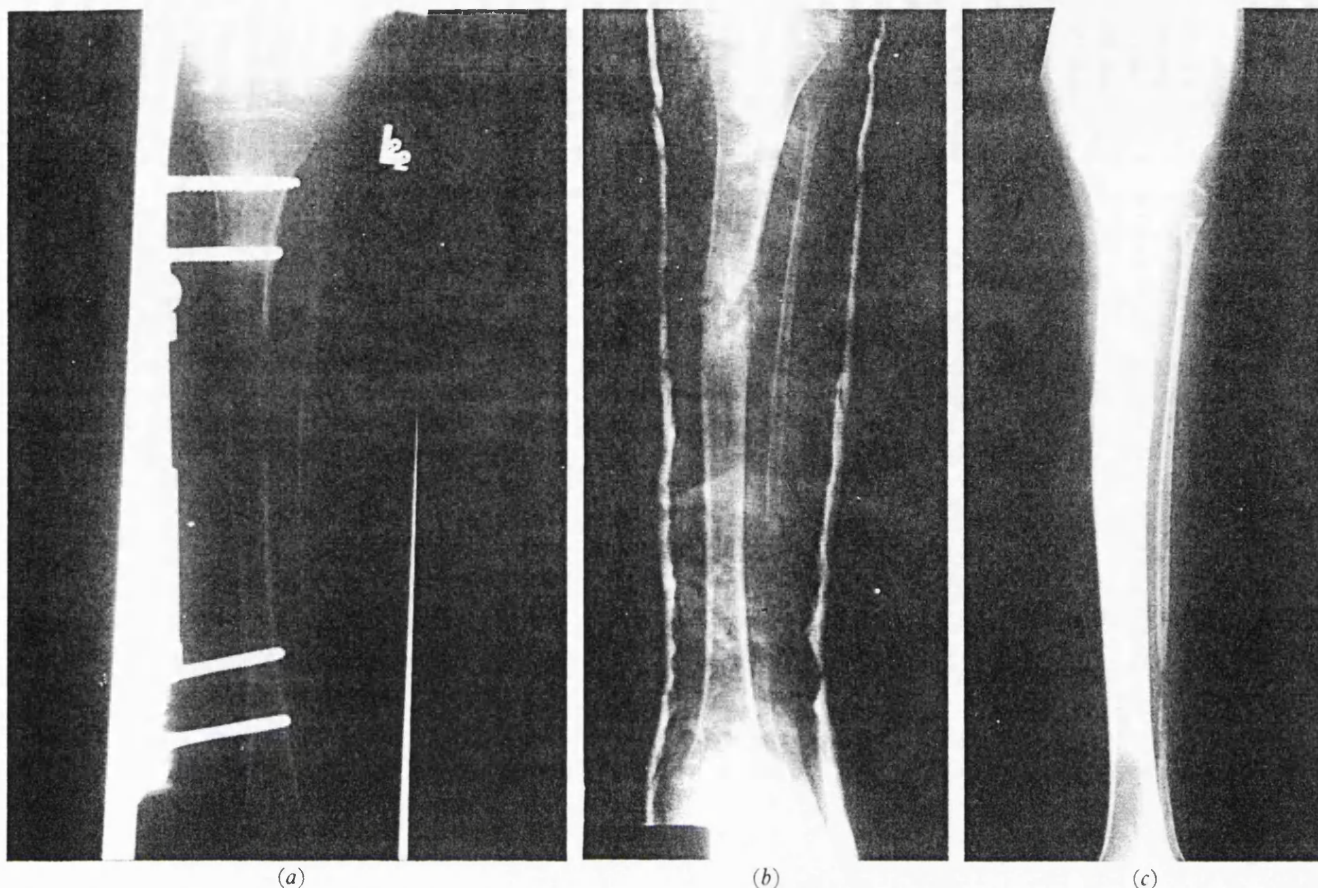


Figure 3. Boy aged 12 years 1 month at the beginning of lengthening for a tibial length discrepancy of 6.7 cm. (a), Close to the end of the lengthening process, with the fixator locked. (b), in a plaster-of-Paris cast after a traumatic fracture through the regenerated bone. (c), Age 13 years 4 months, 3 months after the fracture. The pin tracts are fully ossified, the regenerated bone is mature.

of the length discrepancy and the timing of the correction. Congenitally short bones are probably more difficult to lengthen than post-traumatic or post-infective ones (7). Some conditions, such as congenital insensitivity to pain and post-irradiation syndrome, may be considered absolute contraindications to lengthening (7).

The relatively low complication rate and number of operations per patient reported in this series, especially when compared with the Wagner's method (21), are probably due to the intrinsic safety of the distraction method, a well-planned choice of patients, close liaison with the families, and careful supervision of the children.

Although no definite studies are available, and lengthening has been undertaken on patients well into their twenties (22), the best time to plan a lengthening procedure is probably around puberty (1), as full healing potential is necessary to achieve the best results.

Careful serial analyses of radiographs are required to assess the length of the corticotomy gap, possible malalignment of the corticotomy fragments, and to evaluate the quality of bone formation at the corticotomy site (14). Ultrasound scanning can probably play a role in the decision-making process (12,14).

The timing of fixator removal depends largely on qualitative assessment of the newly formed bone. At least three cortices must be visible in the anteroposterior and lateral radiographs before removal. Care should be taken

to ensure full consolidation of the newly formed bone, in order to avoid complications such as fractures through it.

## References

- 1 Dal Monte A, Donzelli O. Tibial lengthening according to Ilizarov in congenital hypoplasia of the leg. *J Pediatr Orthop* 1987;7:135-8.
- 2 De Bastiani G, Aldegheri R, Renzi-Brivio L, Trivella G. Limb lengthening by callus distraction (callotaxis). *J Pediatr Orthop* 1987;7:129-34.
- 3 Ilizarov GA, Ledyayev VI, Shitin VP. The course of reparative regeneration of the compact bone in distraction osteosynthesis under different conditions of fixation of bone fragments (an experimental study). *Eksp Khir Anest* 1969;14:3-21.
- 4 Paley D. Current techniques of limb lengthening. *J Pediatr Orthop* 1988;8:73-92.
- 5 Paley D. The Ilizarov corticotomy. *Techniques Orthop* 1990;5:41-52.
- 6 White SH, Kenwright J. The timing of distraction of an osteotomy. *J Bone Joint Surg* 1990;72B:356-61.
- 7 Guidera KJ, Hess WF, Highhouse KP, Ogden JA. Extremity lengthening: results and complications with the Orthofix system. *J Pediatr Orthop* 1991;11:90-94.
- 8 Price CT, Cole JD. Limb lengthening by callotaxis for children and adolescents. Early experience. *Clin Orthop* 1990;250:105-11.

- 9 Paley D, Chaudray M, Pirone AM, Lentz P, Katz D. Treatment of malunions and mal-nonunions of the femur and tibia by detailed preoperative planning and the Ilizarov techniques. *Orthop Clin North Am* 1990;21:667-91.
- 10 Green SA. Physiotherapy during Ilizarov fixation. *Techniques Orthop* 1990;5:61-65.
- 11 Vade A, Eissenstat R. Radiographic features of bone lengthening procedures. *Radiology* 1990;174:531-7.
- 12 Young JWR, Kovelman H, Resnik CS, Paley D. Radiologic assessment of bones after Ilizarov procedures. *Radiology* 1990;177:89-93.
- 13 Young JWR, Kostubriak IS, Resnik CS, Paley D. Sonographic evaluation of bone production at the distraction site in Ilizarov limb-lengthening procedures. *AJR* 1990;154:125-8.
- 14 Maffulli N, Hughes T, Fixsen JA. Ultrasound monitoring in mono-axial limb lengthening. *J Bone Joint Surg* 1992;74B:130-32.
- 15 Paley D. Problems, obstacles, and complications of limb lengthening by the Ilizarov technique. *Clin Orthop* 1990;250:81-104.
- 16 Ilizarov GA. The tension-stress effect on the genesis and growth of tissues. Part I. The influence of stability of fixation and soft-tissue preservation. *Clin Orthop* 1989;238:249-81.
- 17 Monticelli G, Spinelli R. Leg lengthening by closed metaphyseal distraction. *Ital J Orthop Traumatol* 1983;9:139-50.
- 18 Mitchell GP. L'elongation du tibia. *Rev Chir Orthop* 1963;49:205-11.
- 19 Wagner H. Allongement chirurgical du femur. A propos d'une serie de 58 cas. *Ann Chir* 1980;43:263-75.
- 20 Gasser B, Boman B, Wyder D, Schneider E. Stiffness characteristics of the circular Ilizarov device as opposed to conventional external fixators. *J Biomech Eng* 1990;112:15-21.
- 21 Blachier D, Trevoux L, Carlioz H. Allongements progressifs due femur selon la technique de Wagner. A propos de 48 cases. *Rev Chir Orthop* 1986;72:495-9.
- 22 Vilarrubias JM, Ginebreda I, Jimeno E. Lengthening of the lower limbs and correction of lumbar hyperlordosis in achondroplasia. *Clin Orthop* 1990;250:143-9.

Received 16 April 1992



# THE ROLE OF ULTRASOUND IN BONE LENGTHENING IMAGING

Veronica Green DCR(R) DMU FETC,  
Associate lecturer in ultrasound,  
Charterhouse College of Radiography.  
Nicola Maffulli MD DSMSA,  
Orthopaedic registrar,  
Newham General Hospital.  
Tudor Hughes FRCR FRCS Ed,  
Radiology senior registrar,  
University College Hospital.

## Introduction

Lengthening procedures have become a reliable and predictable means of correcting limb length discrepancies<sup>(1-4)</sup>. The modern technique involves a corticotomy of the structural bone of the shorter limb segment followed by the application of an external distractor proximal and distal to the corticotomy. A seven to ten day delay allows early callus formation, after which the gradual progressive distraction of the corticotomy is begun, usually at the rate of 0.25mm, four times a day<sup>(1-5)</sup>. The lengthening process must be carefully monitored on an out-patient basis to ensure that:

- superficial pin infections do not progress to osteomyelitis;
- correct alignment is maintained; and
- good quality bone formation occurs.

## The role of ultrasound

Plain radiography is traditionally used in monitoring and guiding the management of these patients, who may be reviewed up to twice a week. Use of the bone densitometer for imaging during leg lengthening osteotomies has been previously reviewed by Williamson<sup>(6)</sup>. The need to reduce the x-ray dose incurred in the monitoring of leg lengthening, especially in view of the length of treatment and the patient's young age, has led to recent research showing that ultrasound can play an important, significant role in assessing progress<sup>(7,8)</sup>.

The age of the patient, underlying pathology and spatial position of the limb are important factors in determining the rate of lengthening. However, Young *et al*<sup>(9,10)</sup> showed it is the early evaluation of bone formation that is most important in determining the subsequent rate of distraction.

A typical length discrepancy of 7cm could be corrected in ten weeks (1mm per day), although this is not usually the case. Using plain radiographs new bone is never seen prior to eight weeks, due to the 'light period' between the time of corticotomy and when callus formation is seen, and it can be a much longer period. Therefore, the lengthening procedure could be over before the new bone is even visible radiographically. Signs such as the 'chewing gum' sign become an interesting but useless feature of over-rapid distraction, since it is too late to slow it down.

With the increased popularity, especially in Britain, of the mono-axial distraction

devices, such as the 'Orthofix' device over the circular 'Ilizarov' style devices, there is much greater access for the ultrasound probe to the skin over the corticotomy site.

It is in the early stages of distraction that ultrasound conveys a wealth of information, namely:

- early detection and assessment of quality of callus; not just a subjective quantity, but also the alignment of the neo-calcified bundles (figures 1 and 2);
- extremely accurate measurements of corticotomy length (figures 3 and 4);

- the detection of wasting of the neo-calcified bundles is an indicator of too rapid distraction — the ultrasound 'chewing gum' sign;

- the detection of ossification defects and cysts in the neo-formed bone. These cysts are not seen on radiographs and yet are within the bone gap. Ultrasound guided therapeutic aspiration of the cysts is possible as it is thought that these delay regeneration of normal bone. It is better to prevent the cysts forming by reducing the rate of distraction when the early signs are visualised, since the cysts indicate poor, weak bone production. This is highly undesirable as weak bone is prone to angulation at the distraction site, which may fracture; and

- axial deviations can be seen, but not evaluated accurately.

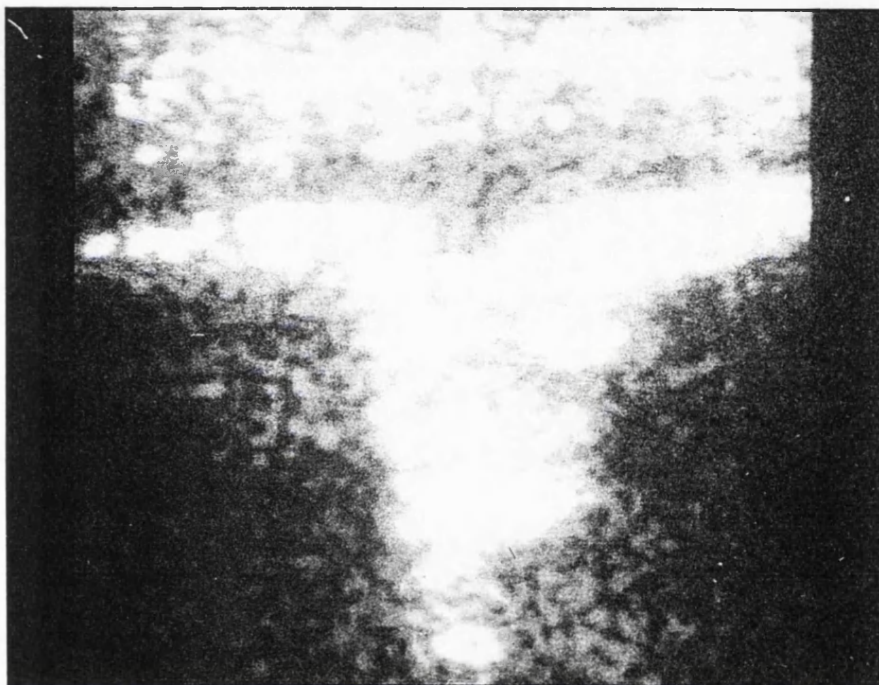
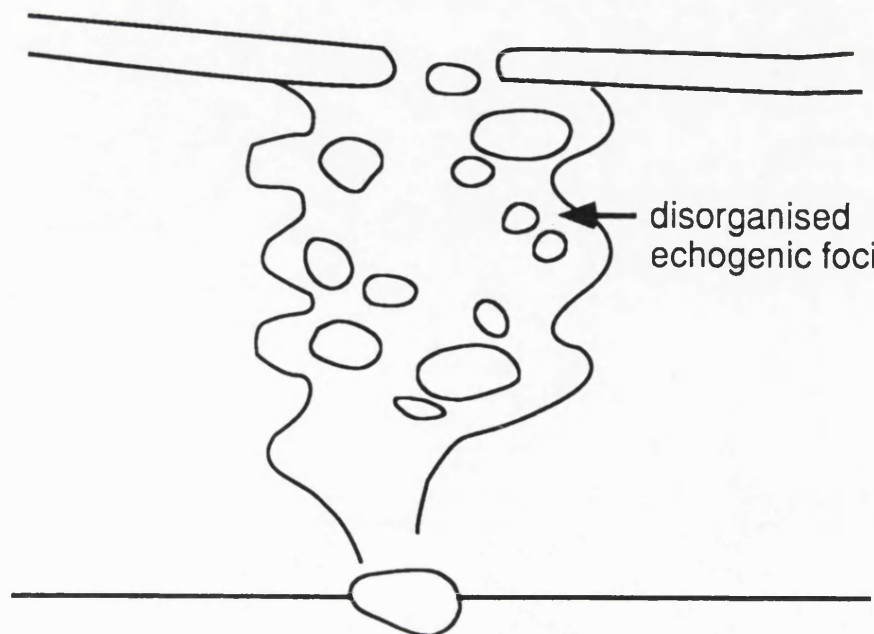


Fig 1 (above) and fig 2 (below): Longitudinal section at the corticotomy site showing corticotomy gap and callus formation at two weeks.



Williamson<sup>16</sup> comments on the poor image quality of ultrasound. However, as trained, experienced sonographers realise, it is a skill which needs to be acquired and takes time to appreciate, but conveys a vast amount of information, providing the operator knows how to best manipulate the ultrasound machine. The probe does not have to be kept perpendicular to the bone as Williamson suggests<sup>17</sup>. Ultrasound, like CT and MRI, is a three-dimensional volume acquisition technique, although standard pictures are taken in the coronal, sagittal and axial planes, oblique views can be useful to obtain a clearer view of the bone ends at the distraction site.

Alignment is not easily detected by ultrasound, but in one patient in the series by Maffulli et al<sup>17</sup> a 10° slip was seen with

ultrasound independently of the confirmatory x-ray findings.

Serial ultrasound scanning reduces x-ray exposure, is relatively fast (each scan takes approximately 15min), is easily available and cheap. Accurate measurements are possible and the process of ossification easily monitored.

The use of dual energy bone densitometry (DEBD) is a useful method of monitoring new bone formation, especially in the later stages of lengthening, but is not the panacea, as it converts 3D bone formation into a 2D picture and a 1D number. Therefore, it could miss quite large defects easily seen with ultrasound. Also DEBD cannot measure alignment, as it acquires information in one plane only<sup>18</sup>. Additionally to accurately measure length using DEBD, one assumes the

bone is parallel to the film, which is often not the case. Finally, unlike ultrasound, DEBD is not available in most departments and its costs are extremely high.

CT scanograms are probably the most accurate way of measuring length discrepancies, assuming the legs can lie near parallel in the scanner and perpendicular to the scan plane. This is a precise, valid and reliable method of initial assessment and operative planning, but is not justified on a cost and irradiation basis for follow-up to measure distraction, especially in view of artifacts introduced by the metalwork.

With the use of the mono-axial distraction devices the question itself conveys the information on the lengthening achieved. What is more important is whether the new bone formation is appropriate to the size of the gap rather than the actual size of the gap itself.

### Conclusion

A possible protocol to take into account the different imaging modalities available could be:

- initial assessment with CT scanogram;
- immediate post-operative AP and lateral radiographs to act as a base-line and to check alignment;
- weekly ultrasound for the first eight weeks;
- monthly AP and lateral radiographs during the lengthening phase and if there is any clinical suspicion of complication during the lengthening or consolidation stage; and
- fortnightly DEBD from eight weeks until remover of fixator (if available).

### References

1. *Tibial lengthening according to Ilizarov in congenital hypoplasia of the leg* by A Dal Monte and O Donzelli. *Journal of Pediatric Orthopaedics*, 1987, vol. 7, pages 135-138.
2. *Limb lengthening by callus distraction (callotaxis)* by G De Bastiani, R Aldegheri, L Renzi-Brivio and G Trivella. *Journal of Pediatric Orthopaedics*, 1987, vol. 7, pages 129-134.
3. *The course of reparative regeneration of the compact bone in distraction osteosynthesis under different conditions of fixation of bone fragments (an experimental study)* by G Ilizarov, V LEdyaev and V Shitun. *Ekspier Khir Anest*, 1969, vol. 14, pages 3-21.
4. *Current techniques of limb lengthening* by D Paley. *Journal of Pediatric Orthopaedics*, 1988, vol. 8, pages 73-92.
5. *The Ilizarov corticotomy* by D Paley. *Techniques in Orthopaedics*, 1990, vol. 5 pages 41-52.
6. *A comparison of imaging techniques for leg lengthening osteotomies* by S Williamson. *Radiography today*, 1991, vol. 57, pages 20-21.
7. *Ultrasonographic monitoring of limb lengthening* by N Maffulli, T Hughes and J Fixsen. *Journal of Bone and Joint Surgery (British Volume)*, 1992, vol. 74B, pages 130-132.
8. *Radiographic imaging for Ilizarov limb lengthening in children* by E Blane, J Herzenberg and M DiPietro. *Pediatric Radiology*, 1991, vol. 21, pages 117-120.
9. *Radiologic assessment of bones after Ilizarov procedures* by J Young, H Kovelman, C Resnick and D Paley. *Radiology*, 1990, vol. 177, pages 89-93.
10. *Sonographic evaluation of bone production at the distraction site in Ilizarov limb-lengthening procedures* by J Young, I Kostubiak, C Resnick and D Paley. *American Journal of Roentgenology*, 1990, vol. 154, pages 125-128.

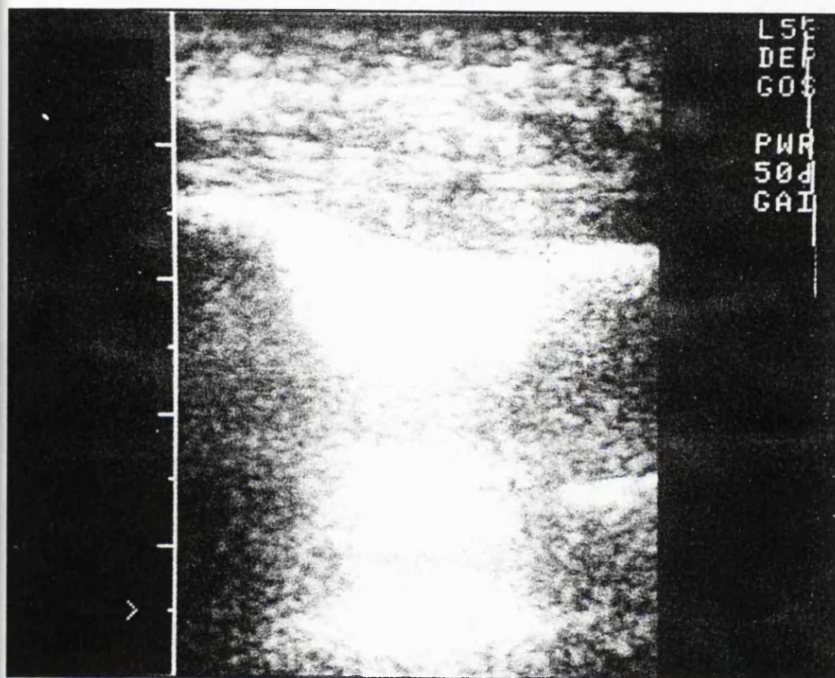


Fig 3 (above) and fig 4 (below): Longitudinal section at the corticotomy site demonstrating corticotomy length and the alignment of neocalcified bundles.

