

# White Matter Integrity in Tanzanian Children With Sickle Cell Anemia

## A Diffusion Tensor Imaging Study

Mboka Jacob, MD, MMed; Hanne Stotesbury, MSc; Jamie M. Kawadler, PhD; Winok Lapadaire, PhD; Dawn E. Saunders, MD; Raphael Z. Sangeda, PhD; Clara Chamba, MD, MMed; Ramadhan Kazema, MD, Mmed; Julie Makani, MD, PhD\*; Fenella J. Kirkham, MD Research\*; Chris A. Clark, PhD\*

**Background and Purpose**—Widespread reductions in white matter integrity are associated with cognitive dysfunction in sickle cell anemia. Silent cerebral infarction (SCI), vasculopathy (VSC), and low hemoglobin concentration (Hb) are implicated; we aimed to determine independent contributions to microstructural white matter injury and whether white matter integrity differs across arterial territories.

**Methods**—Sixty two children with sickle cell anemia aged 6 to 19 years were prospectively studied at Muhimbili National Hospital, Tanzania. SCI± and VSC± were identified on magnetic resonance imaging (MRI)/magnetic resonance angiography (MRA) scans by 2 neuroradiologists. Tract-based spatial statistics tested for voxel-wise differences in diffusion tensor imaging metrics (ie, fractional anisotropy, mean diffusivity, radial diffusivity, and axial diffusivity) between SCI± and VSC± groups, with correlations between diffusion tensor imaging metrics and Hb. In tract-based spatial statistics analyses, potentially mediating factors (ie, age, sex, as well as Hb, SCI, and/or vasculopathy) were covariates. Differences in mean diffusion tensor imaging metrics across regions of interest in arterial territories were explored.

**Results**—Compared with SCI− patients (n=45), SCI+ patients (n=17) exhibited increased radial diffusivity in multiple regions; negative relationships were observed between mean diffusivity, axial diffusivity, and Hb ( $P<0.005$ ). Compared with VSC− patients (n=49), mild (n=6) or moderate (n=7) VSC+ patients exhibited reduced fractional anisotropy in widespread regions ( $P<0.05$ ) including the anterior longitudinal fasciculi, corpus callosum, internal capsule, corona radiata, and corticospinal tracts. Overall, the posterior cerebral arterial territory had higher mean mean diffusivity and mean radial diffusivity than the anterior and middle cerebral arterial territories, although no patient had vasculopathy in this area. There was an interaction between territory and vasculopathy.

**Conclusions**—SCI, vasculopathy, and Hb are independent risk factors, and thus treatment targets, for diffuse white matter injury in patients with sickle cell anemia. Exacerbation of hemodynamic stress may play a role. (*Stroke*. 2020;51:00-00. DOI: 10.1161/STROKEAHA.119.027097.)

**Key Words:** anemia, sickle cell ■ anisotropy ■ hemoglobin ■ magnetic resonance angiography ■ magnetic resonance imaging

Homozygous sickle cell anemia (SCA, HbSS) is a recessive genetic disorder.<sup>1-3</sup> Hemoglobin S (HbS) polymerization under hypoxic conditions is central to many of the manifestations of SCA, which include chronic anemia, hemolysis, and vasculopathy.<sup>4</sup>

Children with SCA are at high risk of cerebral ischemia; without preventative strategies, ≈11% of patients with SCA

will develop stroke by the age of 20,<sup>5</sup> while 50% will develop silent cerebral infarction (SCI)<sup>2</sup> by middle age.<sup>6</sup> Even in the absence of SCI on T2-weighted imaging, focal or global atrophy,<sup>7,8</sup> as well as white matter damage,<sup>9</sup> have been reported.

Understanding SCI and microstructural injury is important in view of the association with neuropsychological

Received July 20, 2019; final revision received November 24, 2019; accepted January 24, 2020.

From the Department of Radiology and Imaging, Muhimbili University of Health and Allied Sciences, Dar Es Salaam, Tanzania (M.J., R.K.); Muhimbili Sickle Cell Program (M.J., R.Z.S., J.M.), Department of Pharmaceutical Microbiology (R.Z.S.), and Department of Haematology and Blood Transfusion (C.C., J.M.), Muhimbili University of Health and Allied Sciences; Developmental Neurosciences Section (H.S., J.M.K., W.L., D.E.S., F.J.K., C.A.C.) and Biomedical Research Unit (F.J.K., C.A.C.), UCL Great Ormond Street Hospital for Children, London, United Kingdom; Clinical Experimental Sciences, University of Southampton, University Hospital Southampton NHS Foundation Trust, United Kingdom (F.J.K.); and King's College Hospital, London, United Kingdom (F.J.K.).

\*Drs Makani, Kirkham, and Clark are joint senior authors.

Correspondence to Mboka Jacob, MD, MMed, Department of Radiology and Imaging, Muhimbili University of Health and Allied Sciences, UN Rd, Upanga, Ilala, Dar es Salaam, Tanzania. Email mbokajacob@gmail.com

© 2020 The Authors. *Stroke* is published on behalf of the American Heart Association, Inc., by Wolters Kluwer Health, Inc. This is an open access article under the terms of the [Creative Commons Attribution License](https://creativecommons.org/licenses/by/4.0/), which permits use, distribution, and reproduction in any medium, provided that the original work is properly cited.

*Stroke* is available at <https://www.ahajournals.org/journal/str>

DOI: 10.1161/STROKEAHA.119.027097

deficits,<sup>10–12</sup> particularly low processing speed,<sup>10–12</sup> with poor school performance.<sup>13</sup> There are, however, limited white matter integrity data in SCA worldwide.<sup>9,12,14–17</sup> Despite the high burden of disease,<sup>18–20</sup> none of the previous white matter integrity data were acquired in Africa.

Vasculopathy is common in SCA, particularly in the anterior circulation,<sup>21,22</sup> and accounts for  $\approx 75\%$  of strokes.<sup>23</sup> Intracranial arterial vasculopathy on MRA<sup>24</sup> has been associated with both stroke<sup>25</sup> and SCI.<sup>26</sup> However, any association between vasculopathy and white matter damage has not been explored. Low hemoglobin concentration (Hb)<sup>27,28</sup> is another established risk factor for stroke<sup>5</sup> and SCI.<sup>29</sup> While low Hb has also been associated with reduced white matter integrity,<sup>9</sup> the effect has yet to be investigated in SCA populations living in Africa, although severe anemia is common.<sup>30</sup>

Assessment of white matter microstructure can be achieved in vivo using diffusion tensor imaging (DTI), a quantitative noninvasive method based on the diffusion of water molecules in the brain. The most commonly used metric, fractional anisotropy (FA), quantifies the degree of diffusion anisotropy. Decreased FA may reflect factors such as loss of highly aligned cellular structures (eg, axons) or replacement of axonal fibres with less ordered cells (eg, glial cells).<sup>31–33</sup> Other DTI metrics include mean diffusivity (MD), axial diffusivity (AD), and radial diffusivity (RD). Increased MD, RD, or AD reflect the net loss of structural barriers to diffusion, such as axonal damage or demyelination (ie, degeneration of microstructural cell barriers).<sup>34</sup>

Studies using tract-based spatial statistics (TBSS), an automated observer-independent method to allow group-wise comparisons of DTI metrics,<sup>35</sup> have shown widespread microstructural changes in patients with SCA.<sup>9,12,15</sup> SCA populations exhibit reduced FA and increased MD compared with age-matched normal controls in multiple white matter regions, including the corpus callosum, centrum semiovale, and cerebellum.<sup>9,15,17</sup>

While studies have demonstrated relationships between DTI metrics and Hb and oxygen saturation in patients with SCA,<sup>9</sup> the effect of vasculopathy and SCI have received little attention. In the current study, we hypothesized that vasculopathy, SCI, and low Hb would be independently associated with widespread reductions in white matter integrity, specifically lower FA, and potentially also higher MD, RD, and AD, in asymptomatic children and adolescents with SCA. We also explored differences in white matter integrity between arterial territories, hypothesizing that integrity would on average be reduced across the anterior cerebral artery (ACA) and middle cerebral artery (MCA) territories, which are most prone to vasculopathy and SCI.

## Methods

### Data Availability

Data are available from the corresponding author on request.

### Participants

The study was institutional review board approved (MUHAS-IRB Ref.2014-11-03/AEC/Vol.IX/32). Individual written consent was

obtained from parents/guardians of minors and from participants above 18 years old. Tanzanian children and adolescents aged 6 to 19 years old with SCA and no history of overt stroke or seizures were recruited. Steady-state Hb was obtained within a week before brain MRI.

### Image Acquisition

MR images from all participants were acquired at Muhimbili National Hospital on a 1.5T Phillips scanner (Achieva; Phillips, Best, the Netherlands) using a 16-channel phased-array head coil. DTI data were acquired using a single-shot echo-planar spin-echo sequence with a data acquisition matrix of 96×101, field of view of 20×20 mm, and repetition time/echo time of 8100/75 ms. Sixty contiguous axial 2.0-mm-thick slices covering the upper part of the brain and posterior fossa were acquired. The protocol comprised 12 noncollinear diffusion gradient directions with *b* values of 0 and 1000 s/mm<sup>2</sup>. The mean acquisition time was 8 minutes and 4 seconds.

Data from a standard clinical diagnostic protocol, including an axial turbo spin-echo T2-weighted sequence, a coronal turbo spin-echo T2-weighted sequence, an axial fluid-attenuated inversion recovery sequence, and a 3-dimensional time-of-flight MRA, with source and maximum intensity projection were also acquired and were evaluated by 2 neuroradiologists (Drs Jacob and Saunders) for clinical diagnosis and verification of subject conditions. The final diagnosis was reached by consensus.

### Silent Cerebral Infarction and Vasculopathy (Arteriopathy) Classification

The SCI definition developed for the Silent Infarct Transfusion trial was used: a lesion in an asymptomatic patient measuring at least 3 mm in the greatest linear dimension and visible in at least 2 planes on T2-weighted images.<sup>2</sup> Vasculopathy on MRA was graded according to severity of signal loss in the terminal internal carotid artery and in the A1, M1, M2, P1, and P2 segments of the basal vessels (0, none—normal; 1, minor signal attenuation/turbulence—mild vasculopathy; 2, obvious signal attenuation, but presence of distal flow—moderate vasculopathy; 3, signal loss and no distal flow—severe vasculopathy).<sup>24</sup> The worst vasculopathy in any vessel was recorded.

### DTI Preprocessing

All scans were visually inspected for abnormalities due to motion or other artefacts. Images with moderate to severe motion and significant cutoff of the imaging field of view were excluded.

### Tract-Based Spatial Statistics

The DTI data were preprocessed using TractoR version 2.3<sup>36</sup> and FMRIB Software Library version 5.0.<sup>37</sup> Within each subject, a reference *b*=0 volume was extracted, and diffusion-weighted volumes were registered to this volume to correct for eddy current distortions. A diffusion tensor was fitted at each voxel using a standard least-squares process, providing voxel-wise maps of FA, MD, RD, and AD.

To prepare DTI metric maps for voxel-wise statistical analysis using TBSS, FA maps were skull-stripped and nonlinearly aligned into the common Montreal Neurological Institute space. Next, a mean FA image was created and thresholded at 0.2 to create a mean FA skeleton. Aligned maps for each subject were then projected onto this skeleton and the resulting data fed into voxel wise cross-subject statistics. The specifics of this approach have been described elsewhere.<sup>35</sup>

### Creation of Digital Arterial Territories Maps

We used an established arterial territory atlas for creation of ACA, MCA, and posterior cerebral artery (PCA) territory maps.<sup>38</sup> Maps were drawn on the mean FA skeleton overlaid in a T1-weighted image. Left and right ACA, MCA, and PCA maps were merged to create combined arterial territory maps. Masks for each arterial territory by DTI matrices (FA, MD, RD, and AD) were created and compared with existing vascular territory maps.<sup>38</sup> Mean DTI values

across voxels in the TBSS skeleton within each vascular territory were extracted for statistical analysis.

## Statistics

To describe an independent association between SCI and white matter microstructure, vasculopathy, age, sex, and Hb were included as covariates in the TBSS analyses comparing DTI metrics between patients with and without SCI (SCI+ and SCI-). To describe an independent association between vasculopathy and white matter microstructure, SCI, age, sex, and Hb were included as covariates in the TBSS analyses comparing DTI metrics between patients with vasculopathy grade 0 (VSC-) and vasculopathy grade 1 or 2 (VSC+) on MRA. Correlations between DTI metrics and Hb were restricted to patients with all available data, with SCI, vasculopathy, age, and sex included as covariates. Multiple comparisons were corrected for using threshold-free cluster enhancement. A 95% significance level was chosen for statistical inference. For visual representation, mean DTI metrics were calculated across voxels.

For the exploratory arterial territory analyses, where statistical assumptions were met, mixed 2-way ANOVA was conducted with mean DTI metrics (FA, MD, RD, and AD) across arterial territories (ACA, MCA, PCA) as the repeated measures within-subjects factor, and vasculopathy status (grades 0, 1, 2) as the between-subjects factor. Where assumptions for a 2-way ANOVA were violated, the between-subjects factor was dropped, and 1-way repeated measures ANOVA were conducted, comparing mean DTI metrics between arterial territories across the sample as a whole. The Statistical package for Social Sciences (SPSS) version 24 was used. A difference at  $P < 0.05$  was considered statistically significant.

## Results

Two hundred twenty-six neurologically asymptomatic children and adolescents with SCA had brain MRI/MRA. Only 176 had DTI datasets, of which 104 were excluded from TBSS analysis due to poor quality data as assessed by an experienced DTI practitioner (Dr Kawadler). The final sample with useable DTI data comprised 62 patients. There were no differences in mean age (DTI: 12.97 years; no DTI: 13.22 years;  $t = 0.438$ ;  $P = 0.662$ ), sex (DTI: 26 male, 36 female; no DTI: 88 male, 76 female;  $\chi^2 = 2.027$ ;  $P = 0.116$ ), or mean hemoglobin (DTI<sub>(56)</sub>: 7.62 g/dL; no DTI<sub>(154)</sub>: 7.75 g/dL;  $t = -580$ ;  $P = 0.563$ ) between those with and without useable DTI data.

Of the 62 patients with good quality DTI data, 45 (73%) had no abnormality on MRI (SCI-), and 17 (27%) had silent cerebral infarction (SCI+). On MRA, 49 (79%) had vasculopathy grade 0 (no vasculopathy), 6 had grade 1 (mild vasculopathy), and 7 had grade 2 (moderate vasculopathy). No patient had grade 3, or severe, vasculopathy, and no vasculopathy was

observed in the PCA. Patient demographics in relation to the MRI and MRA findings are summarized in Table 1.

## Differences as a Function of MRI and MRA Abnormalities

Compared with those without SCI (n=45), patients with SCI (n=17) had increased RD in multiple regions (Figure 1). We also observed decreased FA in patients with vasculopathy grades 1 or 2 (mild-moderate vasculopathy n=13) in multiple brain regions compared with those with vasculopathy grade 0 (n=49; Figure 2). The multiple regions included the anterior cingulum, inferior fronto-occipital fasciculus, superior longitudinal fasciculus, inferior longitudinal fasciculus, corpus callosum, corona radiata, and corticospinal tracts, as well as the anterior and posterior limb of the internal capsule, and the middle cerebellar peduncles including the anterior cingulum, inferior fronto-occipital fasciculus, superior longitudinal fasciculus, inferior longitudinal fasciculus, corpus callosum, corona radiata, and corticospinal tracts, as well as the anterior and posterior limb of the internal capsule, and the middle cerebellar peduncles. There were no further significant differences in DTI metrics between patients with and without SCI or vasculopathy.

## Correlation With Hemoglobin Concentration

There was a significant negative correlation between AD and Hb in multiple brain regions, particularly posteriorly, including the inferior fronto-occipital fasciculus, superior longitudinal fasciculus, and corticospinal tracts (Figure 3). There was also a significant negative correlation between MD and Hb in multiple posterior brain regions including the cingulum, inferior fronto-occipital fasciculus, superior longitudinal fasciculus, corona radiata, body and splenium of corpus callosum, retro-lenticular part of the internal capsule, corticospinal tracts, and middle cerebellar peduncles ( $P < 0.005$ ). A trend-level negative correlation was found between FA and Hb in the right temporal lobe, subcortical white matter, and superior longitudinal fasciculus ( $P < 0.1$ ) and between RD and hemoglobin in the body and splenium of the corpus callosum ( $P < 0.1$ ).

## Distribution of DTI Metrics Across ACA, MCA, PCA Arterial Territories

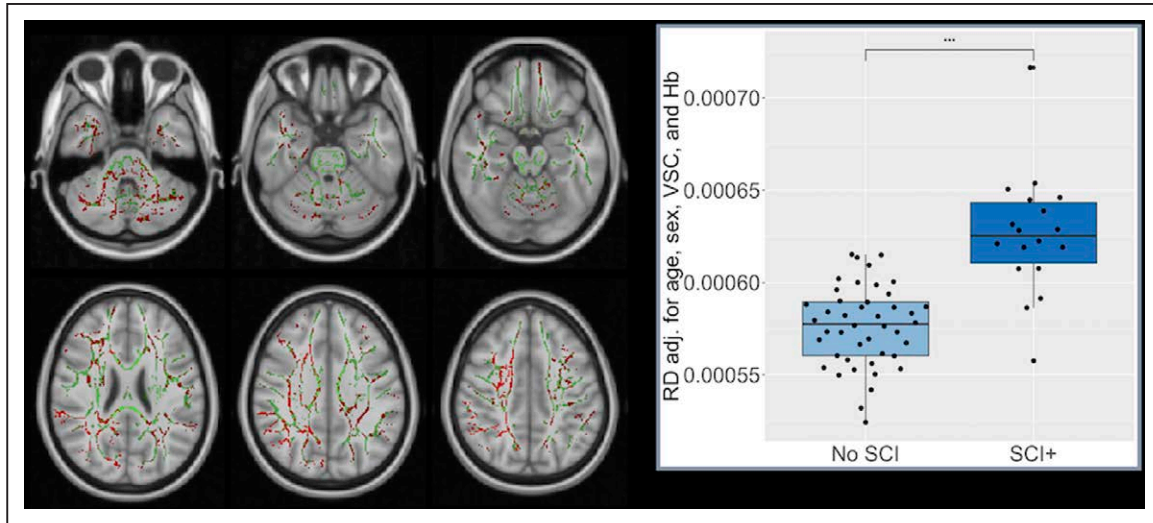
The 2-way ANOVA assumptions of sphericity and/or the Levene test were met across all territories for FA but violated for MD, RD, and AD. For FA, 2-way mixed ANOVA revealed

Table 1. Demographic and MRI/MRA Characteristics of the Study Participants

	SCI+ n=17	SCI- n=45		No Vasculopathy n=49	Vasculopathy Grades 1 or 2 n=13	
Age, y (SD)	12.194 (3.514)	13.633 (3.815)	$t = 1.353$	12.982 (3.852)	14.208 (3.367)	$t = -1.045$
			$P = 0.181$			$P = 0.300$
Sex	8M	18M	$\chi^2 = 0.25$	22M	4M	Fisher exact test $P = 0.53$
	9F	27F		27F	9F	
Hemoglobin,* g/dL; mean (SD)	7.637 (1.071)	7.534 (1.385)	$t = -0.260$	7.623 (1.157)	7.341 (1.758)	$t = 0.663$
			$P = 0.796$			$P = 0.510$

MRA indicates magnetic resonance angiography; MRI, magnetic resonance imaging; SCI+, presence of silent cerebral infarction; and SCI-, no SCI.

\*Hemoglobin available for 55 patients (SCI+: n=15, SCI-: n=40).

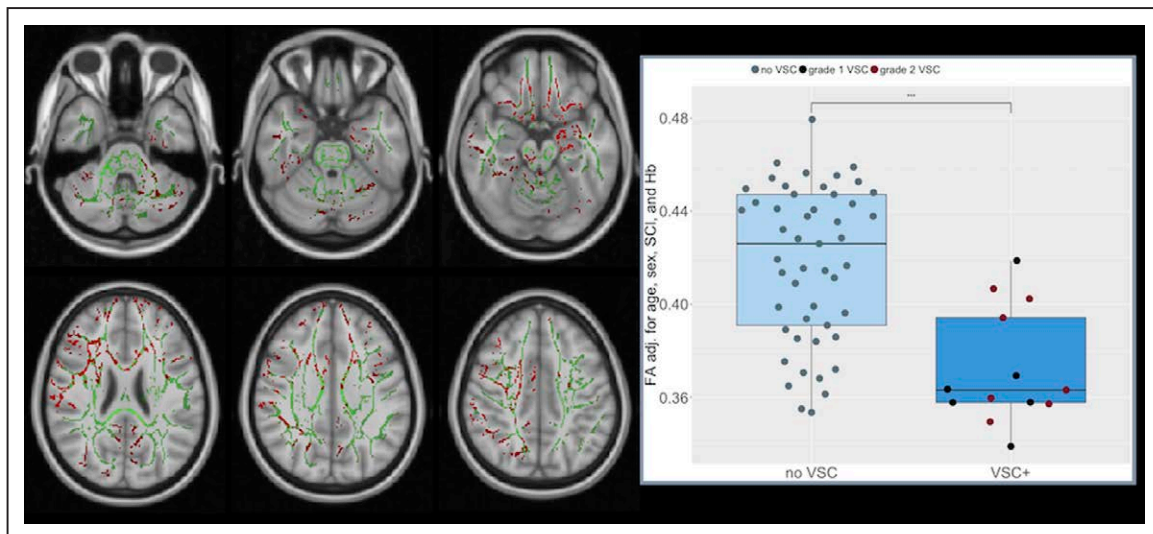


**Figure 1.** Radial Diffusivity (RD) red voxels indicate multiple brain areas in which patients with sickle cell anemia with silent cerebral infarction (SCI) had significantly higher radial diffusivity (RD) than those with no SCI. The results were significant at  $P < 0.05$  (threshold-free cluster enhancement–corrected) and overlaid on the group white matter skeleton (green) and the study-specific mean fractional anisotropy template. The boxplot shows tract-based spatial statistics results for RD in those with (SCI+) and without (no SCI) SCI; individual results are plotted as black circles. Hb indicates hemoglobin; and VSC vasculopathy.

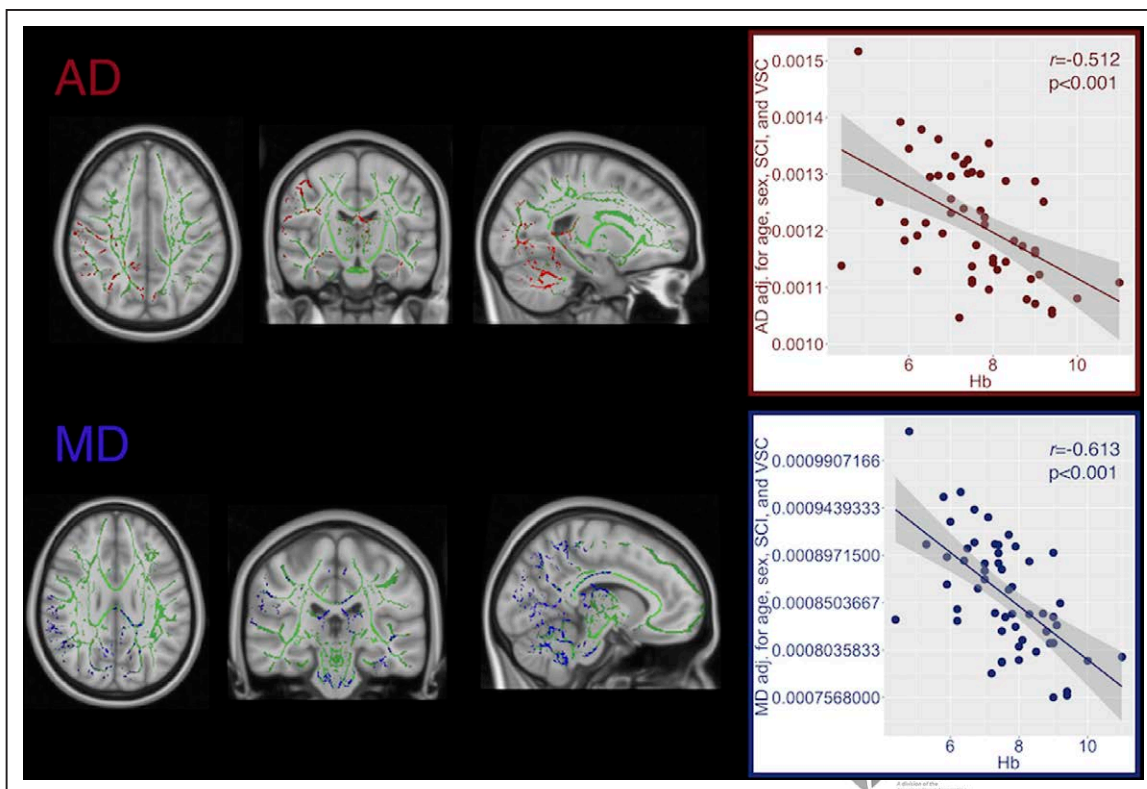
a trend-level effect of territory but no overall effect of vasculopathy. However, there was an interaction between FA and vasculopathy; FA in the ACA was higher than the MCA and PCA in those without vasculopathy, whereas FA in the ACA and PCA was lower than in the MCA in those with grade 1 or 2 vasculopathy. Although the pattern was relatively consistent across other DTI metrics, the 2-way ANOVA assumptions of sphericity and/or the Levene test were not met; therefore, only Greenhouse-Geisser corrected results from the 1-way ANOVA are reported. Across the sample as a whole, there were significant main effects of territory on MD, RD, and AD, with post hoc comparisons revealing higher MD in the PCA than the MCA and ACA, higher AD in the ACA and PCA, and higher RD in the PCA than ACA and MCA (Table 2; Figure 4).

### Discussion

This is the first study to use DTI to characterize brain microstructural changes in sub-Saharan African patients with SCA, linking indices of brain microstructure with SCI on MRI and vascular abnormalities on MRA. After accounting for possibly mediating factors, we observed higher RD values, but not lower FA, in patients with SCI compared with those with no SCI in multiple brain regions. We also observed lower FA values but not higher MD, RD, or AD, in patients with mild to moderate vasculopathy compared with those with no MRA abnormality in widespread regions, particularly anteriorly. Significant negative correlations were also found between MD, AD, and Hb in multiple brain regions, particularly posteriorly. There may be compensatory steal from the posterior circulation when the circulation is compromised by reduced



**Figure 2.** Fractional anisotropy (FA) red voxels indicate multiple brain areas in which patients with sickle cell anemia with vasculopathy (VSC) grades 1 or 2 (VSC+) had significantly lower FA than those with no vasculopathy. The results were significant at  $P < 0.05$  (threshold-free cluster enhancement–corrected) and overlaid on the group white matter skeleton (green) and the study-specific mean FA template. The boxplot shows tract-based spatial statistics results for FA, which is lower in those with VSC grades 1 (black circles) and 2 (red circles) than in those without VSC (gray circles). Hb indicates hemoglobin; and SCI, silent cerebral infarction.



**Figure 3.** Tract-based spatial statistics correlations with steady-state hemoglobin (Hb). Top: red voxels indicate areas in which axial diffusivity (AD) correlated with Hb. Bottom: blue voxels indicate areas in which mean diffusivity (MD) correlated with Hb ( $P < 0.05$ ). Results were age, sex, silent cerebral infarction (SCI), vasculopathy (VSC), and threshold-free cluster enhancement–corrected and overlaid on the group white matter skeleton (green) and the study-specific mean fractional anisotropy template.

vasodilatory capacity secondary to Hb-driven increases in CBF. Across the whole sample, the PCA territory had lower FA than the ACA, and higher mean MD and mean RD than the ACA and MCA territories, although no patient had vasculopathy in this area. One explanation is the slower time course of myelination posteriorly. There was evidence for reversal of the pattern in those with vasculopathy, with lower FA in the ACA and PCA than the MCA. Our findings suggest that presence of SCI, vascular abnormalities, and low Hb may all be risk factors for diffuse white matter alterations in patients with SCA.

Patients with SCA without SCI on T2-weighted imaging can still exhibit macro- and microstructural brain changes,<sup>8,9</sup> which can be associated with cognitive impairment across domains including general intelligence<sup>11,39,40</sup> and executive function.<sup>10</sup> In our study, there were widespread increases in RD in patients with SCI as compared with those without SCI after accounting for other potentially mediating factors, implying that SCI and white matter microstructure may be involved the same pathological processes in SCA. Increased RD reflects the net loss of structural barriers to diffusion, such as axonal damage.<sup>34</sup> In the context of SCA, the SCI and the microstructural damage could occur secondary to the chronic hypoxic-ischemic exposure, including relatively low white matter cerebral blood flow,<sup>41</sup> compromised oxygen delivery,<sup>27</sup> and vasculopathy.<sup>28</sup> However, downstream effects of tissue injury following SCI could also play a role.

Vasculopathy in patients with SCA may involve both small and large vessels<sup>42</sup> but the definition of vasculopathy is currently controversial.<sup>43</sup> The studies which originally defined stenosis as  $>50\%$  or  $>70\%$  narrowing reported cohorts of patients who had a clinical stroke<sup>42</sup> or SCI.<sup>26</sup> However, lesser degrees of stenosis may have an effect on brain tissue in neurologically symptomatic or asymptomatic patients with SCA.<sup>7</sup> We attempted to further examine the effect of any degree of vasculopathy on white matter integrity. As MRA signal is based on velocity of flow and not structure of the vessel, severity of vasculopathy may more accurately be categorized as degree of signal loss rather than degree of stenosis.<sup>24,44</sup> Importantly, our data suggest that vasculopathy detectable by radiologists is associated with differences in tissue integrity, which may have an effect on neurocognitive function.<sup>12</sup> Our results thus support and extend recent findings,<sup>7</sup> indicating that any degree of vasculopathy is associated with widespread reductions in white matter integrity, including mild vasculopathy. Reduced FA can be caused by reduced axonal calibre and density, decreased myelin, or decreased fiber coherence.<sup>31,45</sup>

We also observed significant negative correlations between MD, AD, and Hb and a trend level correlation between FA, RD, and Hb in the current study. Another study of similar size also showed a trend-level correlation between Hb and RD<sup>9</sup> over a different range. As we accounted for covariates including SCI, vasculopathy, age, and sex, our findings are consistent with the notion that Hb alone may play a significant role in the accumulation of white matter damage in SCA.

**Table 2. Diffusion Tensor Imaging Metrics for Arterial Territories for the Overall Sample and Those Without Vasculopathy and With Vasculopathy Grades 1 and 2**

DTI Metrics mm <sup>2</sup> /s×10 <sup>-3</sup>	ACA	MCA	PCA	Post Hoc	Post Hoc P Value
<b>FA</b>					
Overall sample (n=62)	0.419906 (0.029316)	0.400312 (0.028348)	0.396343 (0.032994)	MCA<ACA	0.001*
				PCA<ACA	<0.0005*
No VSC grade 0 (n=49)	0.425042 (0.0288924)	0.397696 (0.028513)	0.395443 (0.033693)	...	...
VSC grade 1 (n=6)	0.400435 (0.026511)	0.408997 (0.028642)	0.392198 (0.033008)	...	...
VSC grade 2 (n=7)	0.400645 (0.021130)	0.411180 (0.026706)	0.406196 (0.031139)	...	...
<b>MD</b>					
Overall sample (n=62)	0.085303 (0.003844)	0.083065 (0.003252)	0.087492 (0.004260)	PCA>MCA	<0.0005*
				PCA>ACA	0.002*
				ACA>MCA	<0.0005*
No VSC grade 0 (n=49)	0.085086 (0.003512)	0.084094 (0.027229)	0.088831 (0.003619)	...	...
VSC grade 1 (n=6)	0.083450 (0.002220)	0.080117 (0.001795)	0.082950 (0.001862)	...	...
VSC grade 2 (n=7)	0.088414 (0.005684)	0.078386 (0.001626)	0.082014 (0.002561)		
<b>AD</b>					
Overall sample (n=62)	0.125524 (0.006779)	0.119408 (0.0058969)	0.125456 (0.000081)	ACA>MCA	<0.0005*
				PCA>MCA	<0.0005*
No VSC grade 0 (n=49)	0.125843 (0.006879)	0.120541 (0.005678)	0.127112 (0.007762)	...	...
VSC grade 1 (n=6)	0.120817 (0.003408)	0.116450 (0.005361)	0.119167 (0.005388)	...	...
VSC grade 2 (n=7)	0.127329 (0.007840)	0.114014 (0.003915)	0.119257 (0.006563)		
<b>RD</b>					
Overall sample (n=62)	0.065179 (0.003312)	0.064890 (0.002753)	0.068495 (0.003180)	PCA>MCA	<0.0005*
				PCA>ACA	<0.0005*
No VSC grade 0 (n=49)	0.064698 (0.002763)	0.065871 (0.002120)	0.069669 (0.002407)	...	...
VSC grade 1 (n=6)	0.064733 (0.002756)	0.061967 (0.000197)	0.064867 (0.000350)		
VSC grade 2 (n=7)	0.068929 (0.005064)	0.060529 (0.001574)	0.063386 (0.001214)	...	...

ACA indicates anterior cerebral artery; AD, axial diffusivity; DTI, diffusion tensor imaging; FA, fractional anisotropy; MCA, middle cerebral artery; MD, mean diffusivity; PCA, posterior cerebral artery; RD, radial diffusivity; and VSC, vasculopathy.

\*Significant after correction for multiple tests.

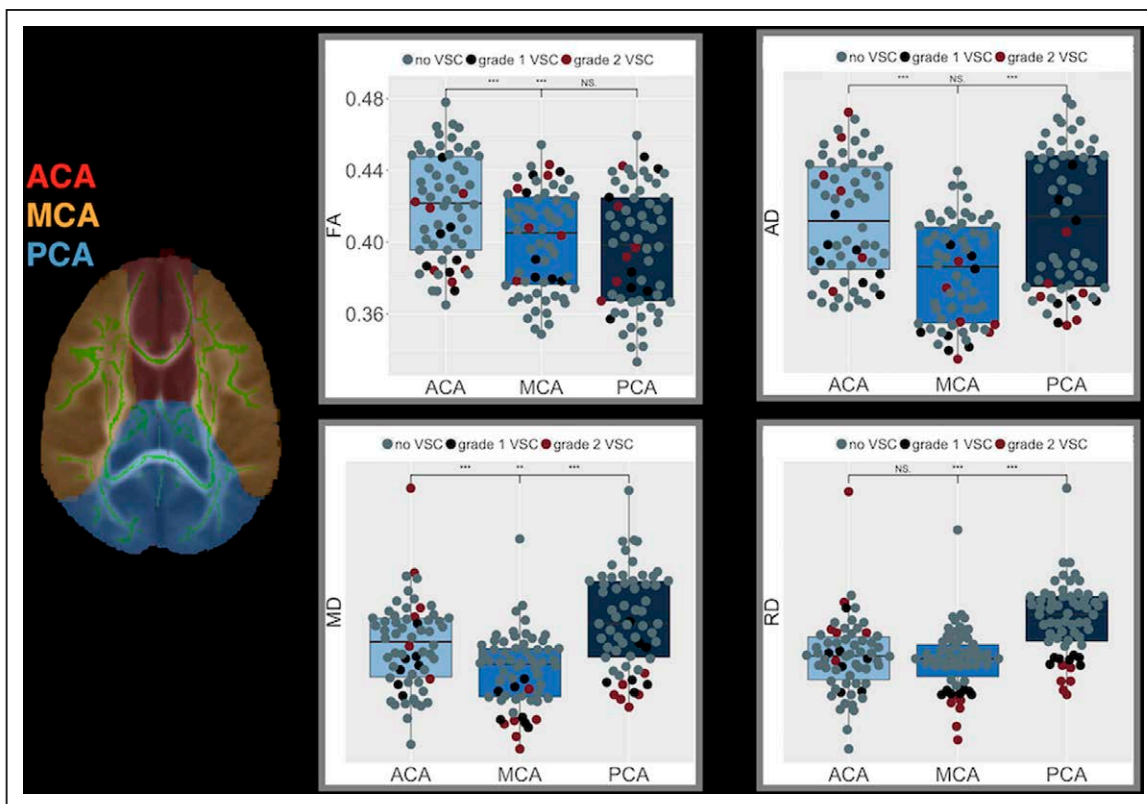
However, our findings also point to a role for several mechanisms, including hemodynamic compensation for reduced arterial oxygen content as well as flow-restricting stenoses.<sup>46</sup>

In exploratory analyses, we found lower mean FA in the PCA and MCA territories and higher mean MD and RD in the PCA territory than in the MCA and ACA territories. In subjects with diabetes mellitus for >15 years, abnormal DTI metrics were found in the posterior circulation.<sup>47</sup> In our study, we primarily observed associations between Hb, a major determinant of CBF in patients with SCD,<sup>48</sup> and integrity across posterior regions. FA is related to CBF in healthy individuals, and there may be differences in hemodynamics in the posterior circulation in children with SCD.<sup>49</sup> Whether right-to-left shunting, which can occur in SCD,<sup>50</sup> also plays a role, as in migraine without aura,<sup>51</sup> is worth exploring. The pattern of reduced integrity in the PCA territory as compared with the ACA and MCA territories appeared to be somewhat reversed in patients with SCD with vasculopathy, with reduced FA as a measure of white matter integrity. This is consistent with the ACA and PCA being affected in a majority of vasculopathy

patients and suggest that diffusivity metrics may be sensitive to downstream effects on integrity in these regions. Further work is required to establish whether this reversal represents a breakdown in a compensatory hemodynamic response (eg, steal) that otherwise favors the anterior circulation.

A limitation of the current study is the moderate sample size. We used TBSS; hence an individual level analysis could not be performed. Contemporaneous oxygen saturation was not available, so we were not able to explore any effect of arterial oxygen content in addition to Hb. We did not measure cerebral blood flow globally or within the arterial territories, for example with arterial spin labeling, although this would be of interest. The analysis of the arterial territories is exploratory; further comparisons across watershed regions would be of interest.

In conclusion, the current study findings provide further insight into microstructural white matter changes in SCA, suggesting that children with SCA with SCI, low hemoglobin, and any degree of vasculopathy, may be at risk of widespread white matter damage. Adding MRI for SCI



**Figure 4.** Left middle; arterial territory map overlaid on the group white matter skeleton (green) and study-specific mean fractional anisotropy (FA) template anterior cerebral artery (ACA; red), middle cerebral artery (MCA; yellow), and posterior cerebral artery (PCA; blue). The boxplots show significantly lower FA in MCA and PCA than in ACA, significantly higher mean diffusivity (MD) in ACA and PCA than in MCA, significantly higher axial diffusivity (AD) in ACA and PCA than in MCA, and significantly higher radial diffusivity (RD) in PCA than in ACA or MCA.

and MRA for vasculopathy evaluation to existing screening protocols may help identify patients at-risk of microstructural brain injury in African countries. Future studies on underlying mechanisms, as well as possible interventions targeting the risk factors identified, are warranted in this vulnerable population.

### Acknowledgments

We acknowledge the efforts of the Muhimbili National Hospital MRI technologists and research assistants without whom the study would not have been possible.

### Sources of Funding

Dr Jacob was funded by Swedish International Development Cooperation Agency-Muhimbili University of Health and Allied Sciences (MUHAS; 2016-12-14/AEC/Vol.XII/04). H. Stotesbury was funded by Action Medical Research (GN2509 to Dr Kirkham). Dr Kawadler was funded by Great Ormond Street Children’s Charity (V4615). The study benefitted from funding from the NIHR to the Great Ormond Street Hospital Biomedical Research Centre (IS-BRC-1215-20012). The cohort was supported by the Muhimbili Sickle Cell program, Muhimbili National Hospital, MUHAS, Dar es Salaam Tanzania funded by Wellcome Trust, United Kingdom (Fellowship Julie Makani 072064, 093727; Project grant 080025; Strategic award 084538).

### Disclosures

Dr Kirkham reports grants from Action Medical Research during the conduct of the study; personal fees from Global Blood Therapeutics (GBT) outside the submitted work. The other authors report no conflicts.

### References

- Sundt P, Gladwin MT, Novelli EM. Pathophysiology of sickle cell disease. *Annu Rev Pathol.* 2019;14:263–292. doi: 10.1146/annurev-pathmechdis-012418-012838
- Casella JF, King AA, Barton B, White DA, Noetzel MJ, Ichord RN, et al. Design of the silent cerebral infarct transfusion (SIT) trial. *Pediatr Hematol Oncol.* 2010;27:69–89. doi: 10.3109/08880010903360367
- Rees DC, Williams TN, Gladwin MT. Sickle-cell disease. *Lancet.* 2010;376:2018–2031. doi: 10.1016/S0140-6736(10)61029-X
- Wang WC. The pathophysiology, prevention, and treatment of stroke in sickle cell disease. *Curr Opin Hematol.* 2007;14:191–197. doi: 10.1097/MOH.0b013e3280ec5243
- Ohene-Frempong K, Weiner SJ, Sleeper LA, Miller ST, Embury S, Moehr JW, et al. Cerebrovascular accidents in sickle cell disease: rates and risk factors. *Blood.* 1998;91:288–294.
- Bernaudo F, Verlhac S, Arnaud C, Kamdem A, Chevret S, Hau I, et al. Impact of early transcranial doppler screening and intensive therapy on cerebral vasculopathy outcome in a newborn sickle cell anemia cohort. *Blood.* 2011;117:1130–1140; quiz 1436. doi: 10.1182/blood-2010-06-293514
- Guilliams KP, Fields ME, Ragan DK, Chen Y, Eldeniz C, Hulbert ML, et al. Large-vessel vasculopathy in children with sickle cell disease: a Magnetic Resonance Imaging Study of infarct topography and focal atrophy. *Pediatr Neurol.* 2017;69:49–57. doi: 10.1016/j.pediatrneurol.2016.11.005
- Kawadler JM, Clayden JD, Kirkham FJ, Cox TC, Saunders DE, Clark CA. Subcortical and cerebellar volumetric deficits in paediatric sickle cell anaemia. *Br J Haematol.* 2013;163:373–376. doi: 10.1111/bjh.12496
- Kawadler JM, Kirkham FJ, Clayden JD, Hollocks MJ, Seymour EL, Edey R, et al. White matter damage relates to oxygen saturation in children with sickle cell anemia without silent cerebral infarcts. *Stroke.* 2015;46:1793–1799. doi: 10.1161/STROKEAHA.115.008721
- Berkelhammer LD, Williamson AL, Sanford SD, Dirksen CL, Sharp WG, Margulies AS, et al. Neurocognitive sequelae of pediatric sickle cell disease: a review of the literature. *Child Neuropsychol.* 2007;13:120–131. doi: 10.1080/09297040600800956
- Kawadler JM, Clayden JD, Clark CA, Kirkham FJ. Intelligence quotient in paediatric sickle cell disease: a systematic review and

- meta-analysis. *Dev Med Child Neurol.* 2016;58:672–679. doi: 10.1111/dmcn.13113
12. Stotesbury H, Kirkham FJ, Kölbl M, Balfour P, Clayden JD, Sahota S, et al. White matter integrity and processing speed in sickle cell anemia. *Neurology.* 2018;90:e2042–e2050. doi: 10.1212/WNL.0000000000005644
  13. Wang W, Enos L, Gallagher D, Thompson R, Guarini L, Vichinsky E, et al; Cooperative Study of Sickle Cell Disease. Neuropsychologic performance in school-aged children with sickle cell disease: a report from the Cooperative Study of sickle cell disease. *J Pediatr.* 2001;139:391–397. doi: 10.1067/mpd.2001.116935
  14. Balci A, Karazincir S, Beyoglu Y, Cingiz C, Davran R, Gali E, et al. Quantitative brain diffusion-tensor MRI findings in patients with sickle cell disease. *AJR Am J Roentgenol.* 2012;198:1167–1174. doi: 10.2214/AJR.11.7404
  15. Sun B, Brown RC, Hayes L, Burns TG, Huamani J, Bearden DJ, et al. White matter damage in asymptomatic patients with sickle cell anemia: screening with diffusion tensor imaging. *AJNR Am J Neuroradiol.* 2012;33:2043–2049. doi: 10.3174/ajnr.A3135
  16. Kapustin D, Leung J, Odame I, Williams S, Shroff M, Kassner A. Hydroxycarbamide treatment in children with sickle cell anaemia is associated with more intact white matter integrity: a quantitative MRI study. *Br J Haematol.* 2019;187:238–245. doi: 10.1111/bjh.16063
  17. Scantlebury N, Mabbott D, Janzen L, Rockel C, Widjaja E, Jones G, et al. White matter integrity and core cognitive function in children diagnosed with sickle cell disease. *J Pediatr Hematol Oncol.* 2011;33:163–171. doi: 10.1097/MPH.0b013e3182036f33
  18. Piel FB, Patil AP, Howes RE, Nyangiri OA, Gething PW, Dewi M, et al. Global epidemiology of sickle haemoglobin in neonates: a contemporary geostatistical model-based map and population estimates. *Lancet.* 2013;381:142–151. doi: 10.1016/S0140-6736(12)61229-X
  19. World Health Organization & March of Dimes. (2006). Management of birth defects and Haemoglobin Disorders: report of a joint WHO-March of Dimes Meeting. Switzerland: Geneva; 17–19 May 2006. <https://apps.who.int/iris/handle/10665/43587>. Accessed August 13, 2014.
  20. Grosse SD, Odame I, Atrash HK, Amendah DD, Piel FB, Williams TN. Sickle cell disease in Africa: a neglected cause of early childhood mortality. *Am J Prev Med.* 2011;41(6 suppl 4):S398–S405. doi: 10.1016/j.amepre.2011.09.013
  21. Stockman JA, Nigro MA, Mishkin MM, Oski FA. Occlusion of large cerebral vessels in sickle-cell anemia. *N Engl J Med.* 1972;287:846–849. doi: 10.1056/NEJM197210262871703
  22. Rothman SM, Fulling KH, Nelson JS. Sickle cell anemia and central nervous system infarction: a neuropathological study. *Ann Neurol.* 1986;20:684–690. doi: 10.1002/ana.410200606
  23. Elsharawy MA, Moghazy KM, Shawarby MA. Atherosclerosis in sickle cell disease - a review. *Int J Angiol.* 2009;18:62–66. doi: 10.1055/s-0031-1278326
  24. Dlamini N, Saunders DE, Bynevelt M, Trompeter S, Cox TC, Bucks RS, et al. Nocturnal oxyhemoglobin desaturation and arteriopathy in a pediatric sickle cell disease cohort. *Neurology.* 2017;89:2406–2412. doi: 10.1212/WNL.0000000000004728
  25. Helton KJ, Adams RJ, Kesler KL, Lockhart A, Aygun B, Driscoll C, et al; SWITCH Investigators. Magnetic resonance imaging/angiography and transcranial doppler velocities in sickle cell anemia: results from the SWITCH trial. *Blood.* 2014;124:891–898. doi: 10.1182/blood-2013-12-545186
  26. Thangaraj M, Yang G, Fuchs D, Ponisio MR, McKinstry RC, Jaju A, et al. Magnetic resonance angiography-defined intracranial vasculopathy is associated with silent cerebral infarcts and glucose-6-phosphate dehydrogenase mutation in children with sickle cell anaemia. *Br J Haematol.* 2012;159:352–359. doi: 10.1111/bjh.12034
  27. Chai Y, Bush AM, Coloigner J, Nederveen AJ, Tamrazi B, Vu C, et al. White matter has impaired resting oxygen delivery in sickle cell patients. *Am J Hematol.* 2019;94:467–474. doi: 10.1002/ajh.25423
  28. Fields ME, Williams KP, Ragan DK, Binkley MM, Eldeniz C, Chen Y, et al. Regional oxygen extraction predicts border zone vulnerability to stroke in sickle cell disease. *Neurology.* 2018;90:e1134–e1142. doi: 10.1212/WNL.0000000000005194
  29. DeBaun MR, Kirkham FJ. Central nervous system complications and management in sickle cell disease. *Blood.* 2016;127:829–838. doi: 10.1182/blood-2015-09-618579
  30. Makani J, Tluway F, Makubi A, Soka D, Nkya S, Sangeda R, et al. A ten year review of the sickle cell program in muhimbili national hospital, Tanzania. *BMC Hematol.* 2018;18:33. doi: 10.1186/s12878-018-0125-0
  31. Pierpaoli C, Basser PJ. Toward a quantitative assessment of diffusion anisotropy. *Magn Reson Med.* 1996;36:893–906. doi: 10.1002/mrm.1910360612
  32. Rollin N, Guyotat J, Streichenberger N, Honnorat J, Tran Minh VA, Cotton F. Clinical relevance of diffusion and perfusion magnetic resonance imaging in assessing intra-axial brain tumors. *Neuroradiology.* 2006;48:150–159. doi: 10.1007/s00234-005-0030-7
  33. Horsfield MA, Jones DK. Applications of diffusion-weighted and diffusion tensor MRI to white matter diseases - a review. *NMR Biomed.* 2002;15:570–577. doi: 10.1002/nbm.787
  34. Gass A, Niendorf T, Hirsch JG. Acute and chronic changes of the apparent diffusion coefficient in neurological disorders—biophysical mechanisms and possible underlying histopathology. *J Neurol Sci.* 2001;186(suppl 1):S15–S23. doi: 10.1016/S0022-510X(01)00487-7
  35. Smith SM, Jenkinson M, Johansen-Berg H, Rueckert D, Nichols TE, Mackay CE, et al. Tract-based spatial statistics: voxelwise analysis of multi-subject diffusion data. *Neuroimage.* 2006;31:1487–1505. doi: 10.1016/j.neuroimage.2006.02.024
  36. Clayden JD, Maniega SM, Storkey AJ, King MD, Bastin ME, Clark CA. TractoR: magnetic resonance imaging and tractography with R. *J Stat Softw.* 2011;44:1–18.
  37. Smith SM, Jenkinson M, Woolrich MW, Beckmann CF, Behrens TE, Johansen-Berg H, et al. Advances in functional and structural MR image analysis and implementation as FSL. *Neuroimage.* 2004;23(suppl 1):S208–S219. doi: 10.1016/j.neuroimage.2004.07.051
  38. Tatu L, Moulin T, Vuillier F, Bogousslavsky J. Arterial territories of the human brain. *Front Neurol Neurosci.* 2012;30:99–110. doi: 10.1159/000333602
  39. Bernaudin F, Verhac S, Fréard F, Roudot-Thoraval F, Benkerrou M, Thuret I, et al. Multicenter prospective study of children with sickle cell disease: radiographic and psychometric correlation. *J Child Neurol.* 2000;15:333–343. doi: 10.1177/088307380001500510
  40. Chen R, Krejza J, Arkuszewski M, Zimmerman RA, Herskovits EH, Melhem ER. Brain morphometric analysis predicts decline of intelligence quotient in children with sickle cell disease: a preliminary study. *Adv Med Sci.* 2017;62:151–157. doi: 10.1016/j.advms.2016.09.002
  41. Ford AL, Ragan DK, Fellah S, Binkley MM, Fields ME, Williams KP, et al. Silent infarcts in sickle cell disease occur in the border zone region and are associated with low cerebral blood flow. *Blood.* 2018;132:1714–1723. doi: 10.1182/blood-2018-04-841247
  42. Steen RG, Emudianughe T, Hankins GM, Wynn LW, Wang WC, Xiong X, et al. Brain imaging findings in pediatric patients with sickle cell disease. *Radiology.* 2003;228:216–225. doi: 10.1148/radiol.2281020943
  43. Williams KP, Fields ME, Dowling MM. Advances in understanding ischemic stroke physiology and the impact of vasculopathy in children with sickle cell disease. *Stroke.* 2019;50:266–273. doi: 10.1161/STROKEAHA.118.020482
  44. Kija EN, Saunders DE, Munubhi E, Darekar A, Barker S, Cox TCS, et al. Transcranial doppler and magnetic resonance in tanzanian children with sickle cell disease. *Stroke.* 2019;50:1719–1726. doi: 10.1161/STROKEAHA.118.018920
  45. Beaulieu C. The basis of anisotropic water diffusion in the nervous system - a technical review. *NMR Biomed.* 2002;15:435–455. doi: 10.1002/nbm.782
  46. Stotesbury H, Kawadler JM, Saunders DE, Hales PW, Clark CA, Kirkham FJ. Vascular instability and neurological morbidity in sickle cell disease: an integrative framework. *Front Neurol.* 2019;10:871. doi: 10.3389/fneur.2019.00871
  47. Kodl CT, Franc DT, Rao JP, Anderson FS, Thomas W, Mueller BA, et al. Diffusion tensor imaging identifies deficits in white matter microstructure in subjects with type 1 diabetes that correlate with reduced neurocognitive function. *Diabetes.* 2008;57:3083–3089. doi: 10.2337/db08-0724
  48. Bush AM, Borzage MT, Choi S, Václavů L, Tamrazi B, Nederveen AJ, et al. Determinants of resting cerebral blood flow in sickle cell disease. *Am J Hematol.* 2016;91:912–917. doi: 10.1002/ajh.24441
  49. Hales PW, Kawadler JM, Aylett SE, Kirkham FJ, Clark CA. Arterial spin labeling characterization of cerebral perfusion during normal maturation from late childhood into adulthood: normal 'reference range' values and their use in clinical studies. *J Cereb Blood Flow Metab.* 2014;34:776–784. doi: 10.1038/jcbfm.2014.17
  50. Dowling MM, Quinn CT, Ramaciotti C, Kanter J, Osunkwo I, Inusa B, et al; PFAST Investigators. Increased prevalence of potential right-to-left shunting in children with sickle cell anaemia and stroke. *Br J Haematol.* 2017;176:300–308. doi: 10.1111/bjh.14391
  51. Xie H, Bian Y, Jian Z, Huo K, Liu R, Zhu D, et al. Right-to-left shunt may be prone to affect the white matter integrity of posterior circulation in migraine without aura. *Neurol Sci.* 2018;39:119–125. doi: 10.1007/s10072-017-3161-9