

## Systemic Therapies for Intrahepatic Cholangiocarcinoma

Robin Katie Kelley<sup>1</sup>, John Bridgewater<sup>2</sup>, Gregory J. Gores<sup>3</sup>, Andrew X. Zhu<sup>4</sup>

<sup>1</sup>University of California, San Francisco, CA, USA

<sup>2</sup>Department of Medical Oncology, UCL Cancer Institute, London, United Kingdom

<sup>3</sup>Division of Gastroenterology and Hepatology, Mayo Clinic, Rochester, MN 55905, USA

<sup>4</sup>Director, Liver Cancer Research, Harvard Medical School, Massachusetts General Hospital Cancer Center

*Address for Correspondence:* Gregory J. Gores, M.D.  
Professor of Medicine and Physiology  
Mayo Clinic  
200 First Street SW, Rochester, MN 55905  
Tel: 507-284-0686; Fax: 507-284-0762  
Email: [gores.gregory@mayo.edu](mailto:gores.gregory@mayo.edu)

### Financial Support/conflicts of interest

RKK reports consulting fees for advisory or steering committee roles from Agios, Astra Zeneca, and Bristol-Myers Squibb (all to institution); consulting fees for IDMC membership from Genentech/Roche (to individual); and research funding (to institution) from Adaptimmune, Agios, Astra Zeneca, Bayer, Bristol-Myers Squibb, Eli Lilly, EMD Serono, Exelixis, Medimmune, Merck, Novartis, QED, and Taiho.

JB is funded in part by the University College London Hospitals/ University College London biomedical centre and has no conflicts of interest relevant to this manuscript.

GJG acknowledges support from Mayo Clinic, and has no conflicts of interest relevant to this manuscript.

AXZ

**Author Contributions:** All 4 authors contributed to the conceptual outline, writing and editing of this manuscript.

*Short Title:* Cholangiocarcinoma

*Keywords:* adjuvant therapy, checkpoint inhibitors, FGFR, IDH.

Number of pages:

Title characters: 54

Abstract (words):

Total word count (including references):

References: 92

Figures: 1

Tables: 4

## **Abstract**

Intrahepatic cholangiocarcinoma (iCCA) is a highly lethal hepatobiliary neoplasm whose incidence is increasingly. Largely neglected for decades as a rare malignancy and frequently misdiagnosed as carcinoma of unknown primary, considerable clinical and investigative attention has recently been focused on iCCA worldwide. Standard of care first-line (gemcitabine and cisplatin), second line (FOLFOX) and adjuvant (capecitabine) systemic chemotherapy has been established. As compared to hepatocellular carcinoma, iCCA is genetically distinct with several targetable genetic aberrations identified to date. Indeed, FGFR2 and NRTK fusions, and IDH1 and BRAF targetable mutations have been comprehensively characterized and clinical data is emerging on targeting these oncogenic drivers pharmacologically. Also, the role of immunotherapy has been examined and is an area of intense investigation. Herein, in a timely and topical manner we will review these advances, and highlight future directions of investigations.

Cholangiocarcinoma (CCA) can be defined by anatomic subtypes including intrahepatic CCA (iCCA), perihilar CCA (pCCA), and distal CCA (dCCA).<sup>1</sup> pCCA arise between the second order bile ducts and the insertion of the cystic duct into the common bile duct; iCCA are characterized as CCA proximal to the second order bile ducts, and dCCA as cancers below of the insertion of the cystic duct into the common bile duct. The anatomic subtypes display different clinical presentations, histomorphology, and molecular aberrations.<sup>2</sup> For example, iCCA usually presents as intrahepatic mass lesions, whereas, pCCA and dCCA often present as jaundice without a substantial mass lesion identified on cross-sectional imaging modalities. The genetics of the disease are also different.<sup>3</sup> This review is focused on systemic therapy for iCCA, and therefore, pCCA and dCCA will not be discussed further. Likewise, we are reviewing systemic therapies so we also will not review advances in surgical resection or transplantation for iCCA.

The epidemiology of iCCA is fraught with misclassification of pCCA as iCCA, and of iCCA as cancer of unknown primary.<sup>4</sup> Nonetheless, studies have suggested the incidence of iCCA is increasing.<sup>4</sup> Risk factors for iCCA include fibroinflammatory biliary tract disease such as primary sclerosing cholangitis (PSC), caroli's disease, hepatolithiasis, and liver fluke infestations.<sup>2,5,6</sup> Other identified risk factors include cirrhosis, viral hepatitis, obesity associated liver disease, and diabetes.<sup>5</sup> Given the increasing incidence and prevalence of obesity associated liver disease and diabetes, these risk factors may also be contributing to the increasing incidence of iCCA in various populations.<sup>7</sup> It is important to note however that approximately 50% of iCCA cases have no identifiable risk factors.

iCCA, presumably arising from small bile ducts, are frequently characterized by small-

sized tubular or acinar adenocarcinoma, and display minimal or no mucin production.<sup>8</sup> These cancers more frequently have fibroblast growth factor receptor (FGFR) 2 fusion gene aberrations or isocitrate dehydrogenase 1 or 2 (IDH1 or 2) gain of function genetic mutations.<sup>9,10</sup> Genetic alterations of FGFR2 or IDH have implications for therapy (vide infra). Also, iCCA are highly desmoplastic cancers with a rich tumor stroma.<sup>6</sup> This observation has raised interest in immunotherapy for iCCA.<sup>6</sup> Although to date, such immunotherapy approaches have been disappointing (vide infra) in the absence of DNA mismatch repair defects; however, this therapy is in its infancy as evolving immunotherapy strategies remain promising.

Herein, we now review evidence-based approaches for systemic therapy for iCCA. We review what is known regarding cytotoxic chemotherapy, precision medicine based targeted therapy, and immunotherapy.

### **Systemic, non-targeted, cytotoxic chemotherapy for iCCA**

There are a few dedicated systemic chemotherapy studies dedicated to iCCA alone. The majority are in series comprising all anatomic subtypes of CCA (intrahepatic, perihilar and distal CCA), and often gallbladder cancer (GBC). For many of these studies CCA and GBC were simply included together in studies of biliary tract cancer (BTC). Only a few studies have reported on the iCCA. As such the comments that follow largely refer to CCA as a whole; however, we will focus largely on prospective randomised data.

There are now 2 published randomised studies for iCCA using adjuvant chemotherapy (Table 1). The adjuvant standard of care (SoC) for all CCA subtypes has been established as capecitabine based on the BilCap study and reiterated in the NCCN guidelines,<sup>11</sup> and as such patients with CCA treated with capecitabine as adjuvant therapy may anticipate a survival of

51.1 months. The PRODIGE 12 study employed gemcitabine plus oxaliplatin (GEMOX) in an adjuvant setting was clearly negative; perhaps because it was underpowered to predict outcome. The iCCA subgroups of BilCap (n=84) and PRODIGE12 (n=86) appeared to benefit (hazard ratio (HR) 0.65 (0.35–1.18) and HR 0.718 (0.431 to 1.196) respectively, although neither reached statistical significance. It must be emphasised that these post-hoc analyses are exploratory rather than conclusive, particularly as the primary endpoint of the PRODIGE12 study was negative.

There is a single randomised study comparing chemotherapy to best supportive care in patients with CCA. Glimelius and colleagues compared the 5-fluorouracil, etoposide, and leucovorin combination in 37 patients with CCA in a study combined with pancreas cancer patients.<sup>12</sup> The survival favoured chemotherapy (6.5 months vs. 2.5 months) but was not significant (P=0.1).

Treatment for advanced disease has been defined through the ABC series (Table 2). The ABC-02 study established the SoC for advanced CCA with the cisplatin and gemcitabine regimen (CisGem) demonstrating a 3 month survival advantage over gemcitabine alone, with a median overall survival (OS) of 11.7 months.<sup>13</sup> These data were confirmed by the BT22 study, a Japanese study with a similar design<sup>14</sup> and a meta-analysis of BT22 and ABC-02.<sup>15</sup> Subsequent additions to CisGem (merestininib or ramacicirumab<sup>16</sup>, cedirinib<sup>17</sup> and cetuximab<sup>18</sup>) have to date failed to demonstrate significant added benefit. The benefit of CisGem is maintained in the iCCA subgroup (n=108, HR 0.61 (0.41–0.91)). {Lamarca, 2019 #5744}

The ABC-06 study randomised patients to active supportive care with or without FOLFOX chemotherapy in second line following 1<sup>st</sup> line CisGem failure. {Lamarca, 2019

#5786} The study was positive with an HR of 0.69 (95% CI 0.50-0.97; p=0.031) and the 1 year survival is significantly improved (25.9% vs. 11.4%) although the median survival improvement was modest (5.3 to 6.2 months). The benefit was maintained in the iCCA component (HR 0.64 0.38-1.06) although not statistically significant. Of note is that these studies were performed for the most part before the advent of targeted therapies so that these data are likely to represent true outcomes for chemotherapy alone.

The results of the ABC studies should be considered in the context of heterogeneity of the anatomical subtypes of biliary tract cancer. Of 534 patients recruited into the ABC-01, -02 and -03 studies, 109 (20.4%) had iCCA. {Lamarca, 2019 #5744} Most patients (n=86; 78.9%) had metastatic disease at the time of recruitment and 52 patients (47.7%) had liver-only disease. The majority of patients (66, 60.6%) received CisGem. The median OS was 15.4 months (11.1 - 17.9) compared to 12.6 months for the whole cohort. Of these 66 patients, 34 patients (51.5%) had liver-only disease for which the median OS was 16.7 months (8.7 - 20.2). Multivariable analysis confirmed that iCCA had a longer OS compared to other non-iCCA BTCs (HR 0.58, 0.35-0.95; p-value = 0.03). Liver-only iCCA also showed longer OS even though findings did not reach statistical significance (HR 0.65, 0.36-1.19; p-value = 0.16). As such, iCCA are likely to have an improved prognosis regardless of type of chemotherapy treatment, reflecting unique biological characteristics.<sup>3</sup>

### **Targeted therapies in cholangiocarcinoma**

In contrast to other malignancies, i.e. lung cancer, where targeted therapy has transformed the treatment landscape, the progress for targeted therapy development in BTCs including intrahepatic cholangiocarcinoma (iCCA) has been modest. Earlier efforts focused on

inhibiting known targets implicated in carcinogenesis in cholangiocarcinoma including EGFR and VEGF/VEGFR. Based on the strong rationale of targeting *EGFR* in BTCs and early interesting results with single arm phase II trials suggesting the benefits of *EGFR* inhibitors either as single agents or in combination with chemotherapy, randomized phase II studies were conducted, but failed to confirm the benefits of targeting *EGFR* in advanced BTCs.<sup>18,20</sup> One randomized phase III trial with 133 patients demonstrated that the addition of an *EGFR* inhibitor, erlotinib, to gemcitabine-oxaliplatin (GEMOX) significantly improved response rates (RR) versus GEMOX alone in advanced BTCs, but did not demonstrate any benefit in survival with a median OS of 9.5 months in both arms.<sup>21</sup> Similarly efforts have been made to assess the therapeutic relevance of targeting angiogenesis. Single arm phase II trials with *VEGF/VEGFR* inhibitors including bevacizumab, sunitinib and vandetanib have demonstrated limited efficacy. In the ABC-03 randomized phase II trial, the addition of cediranib, a potent oral *VEGFR* 1-3 inhibitor, was evaluated in combination of gemcitabine/cisplatin in advanced BTCs.<sup>17</sup> Of the 124 patients enrolled (62 in each arm), the addition of cediranib improved the response rate (44% in the cediranib arm vs. 19% in the placebo arm,  $P = 0.004$ ) but did not improve the median progression free survival (PFS) (8.0 months in cediranib arm and 7.4 months in placebo arm, HR 0.93,  $P = 0.72$ ) or OS (14.1 months in cediranib arm and 11.9 months in placebo arm, HR 0.86,  $P = 0.44$ ).

Recent progress in targeted therapy development in BTCs, particularly in iCCA, was made possible based on extensive research and insights obtained from modern molecular genetic analyses. Targeted and whole exome sequencing genomic analyses have demonstrated the molecular heterogeneity of BTCs and refined the genetic landscape of iCCA. More

importantly these efforts have led to the identification of novel actionable drivers in iCCA pathogenesis<sup>6,22</sup> and rapid clinical trial development targeting IDH mutations, FGFR2 fusions, and RAF mutations among others.

Several groups have identified and characterized *IDH* mutations in iCCA.<sup>9,23,24</sup> *IDH1* mutations are more common than *IDH2* mutations - “hotspot” *IDH1/2* mutations are point mutations located in the arginine 132 (R132) residue in *IDH1* or the arginine 172 (R172) residue in *IDH2*. These mutations are present at higher frequency in iCCA than extrahepatic cholangiocarcinoma. Mutant IDH loses its normal enzymatic activity and gains a new ability to produce the oncometabolite 2-hydroxyglutarate (2-HG), which can be detected in the tumor and blood.<sup>9,23-25</sup> Pharmacologic inhibitors highly specific to the individual IDH-mutant alleles (e.g., *IDH1*-R132 and *IDH2*-R172) have been developed. These specific inhibitors can block the function of mutant *IDH1* or *IDH2* at nanomolar concentrations, leading to reduced 2-HG levels.

*IDH* inhibitors have demonstrated growth inhibition in tumor cell lines harboring specific *IDH* mutations.<sup>26</sup> AG-120 (Ivosidenib) is a first-in-class, potent, oral inhibitor of mutant *IDH1* and was examined in a phase I study in mutant *IDH1* solid tumors including iCCA.<sup>27</sup> AG120 was well tolerated and of the 73 patients with *IDH1* mutant advanced CCA enrolled, 72 patients were evaluable for efficacy. Four (5%; 95% CI 1.5–13.4) patients had a partial response. Median PFS was 3.8 months (95% CI 3.6–7.3), 6-month PFS rate was 40.1% (28.4–51.6), and 12-month PFS rate was 21.8% (12.3–33.0). Median overall survival was 13.8 months (95% CI 11.1–29.3). All of the patients responding to ivosidenib exhibited a reduction in circulating 2-HG level ranging from 73% to 99%, and a reduction in Ki67 nuclear staining



ranging from 22% to 96% from baseline. However, the emergence of acquired resistance to mutant IDH1 inhibition has been reported and was associated with development of an oncogenic IDH2 mutation in cholangiocarcinoma.<sup>28</sup> A global, phase 3, randomized, double-blind study of ivosidenib vs placebo in patients with advanced cholangiocarcinoma with an IDH1 mutation (ClarIDHy) has completed the targeted enrollment (NCT02073994). Patients with mutant IDH1 advanced cholangiocarcinoma were randomized in a 2:1 ratio to ivosidenib at 500 mg once daily or matched placebo. Crossover from placebo to ivosidenib was permitted at radiographic progressive disease (PD). The primary endpoint of the study was PFS by central review. The study has met the primary endpoint for improved PFS based on the recent press release and the results are eagerly awaited. This would be an important milestone in targeted therapy development in cholangiocarcinoma. Other IDH1 and IDH2 inhibitors ([NCT02273739](#), [NCT02381886](#), [NCT02481154](#)) are also now in clinical trials and are enrolling patients with cholangiocarcinoma.

The recent discovery of *FGFR2* fusions in 11–45% of patients with iCCA has rapidly translated this into a promising therapeutic target.<sup>10,29-31</sup> The identification of various *FGFR* aberrations (fusions, amplifications, mutations) in multiple tumor types has led to the rapid clinical development of several *FGFR*-selective inhibitors in patients with iCCA with *FGFR* pathway alterations. These second-generation inhibitors represent an improvement over the early generation of multi-kinase inhibitors with activity against *FGFR* (e.g. dovitinib and ponatinib), which lack sufficient specificity and potency to effectively treat *FGFR*-driven tumors. The most mature data of selective *FGFR* inhibition in iCCA is with the oral agent BGJ-398 (Infigratinib, Novartis/QED). In the phase II study of BGJ-398 in advanced iCCA with

FGFR aberrations after first-line chemotherapy,<sup>32</sup> 61 patients with *FGFR2* fusion (n = 48), mutation (n = 8), or amplification (n = 3) were enrolled. The overall response rate was 14.8% (18.8% in patients with *FGFR2* fusions), disease control rate was 75.4%, and estimated median PFS was 5.8 months (95% CI, 4.3 to 7.6 months). In a phase 1/2 trial of 29 patients with *FGFR2* fusion-positive advanced iCCA, derazantinib (ARQ 087), another oral multi-kinase inhibitor with pan-FGFR activity, demonstrated an overall response rate of 20.7% and estimated median PFS of 5.7 months.<sup>33</sup> Other selective FGFR inhibitors including INCB54828 (Incyte, [NCT02924376](#)), BAY1163877 (Bayer, [NCT01976741](#)), and Debio1347 (Debiopharm International, NCT01948297) have also been tested in phase I trials in solid tumors including iCCA, with early evidence of antitumor activity. Some of these agents have proceeded to phase III trials comparing FGFR inhibitors with standard gemcitabine/cisplatin based chemotherapy in newly diagnosed treatment naïve advanced cholangiocarcinoma whose tumors harboring *FGFR2* fusions and other abnormalities.

The third-generation, irreversible FGFR inhibitor TAS-120 covalently binds to a highly conserved P-loop cysteine residue in the ATP pocket of FGFR (C492 in the *FGFR2-IIIb* isoform).<sup>34</sup> TAS-120 exhibits *in vitro* potency at low nanomolar concentrations and high specificity against wild-type *FGFR1-4* as well as against some *FGFR2* kinase domain mutations. In a phase I basket study of TAS-120 in patients with refractory advanced solid tumors, TAS-120 showed an ORR of 25.0% and a DCR of 78.6% in 28 patients with iCCA harboring *FGFR2* fusions, including some patients who had received prior therapy with an ATP-competitive FGFR inhibitor.<sup>35</sup>

As observed with other tumors treated with tyrosine kinase inhibitors, acquired resistance limits the durability of response of FGFR inhibitors. Indeed, the first evidence of clinically acquired resistance to FGFR inhibition was recently reported in three patients with FGFR2-fusion positive iCCA who were treated with BGJ398.<sup>36</sup> Sequencing of cell-free DNA and biopsy samples collected at baseline and post-progression revealed polyclonal secondary mutations in the FGFR2 kinase domain, including the gatekeeper mutation FGFR2 V564F in all three patients. In a follow up study,<sup>37</sup> they were able to show that TAS-120 demonstrated efficacy in four patients with FGFR2-fusion-positive iCCA who developed resistance to BGJ398 or Debio1347. Examination of serial biopsies, circulating tumor DNA (ctDNA), and patient-derived CCA cells revealed that TAS-120 was active against multiple FGFR2 mutations conferring resistance to BGJ398 or Debio1347. These findings demonstrate that strategic sequencing of FGFR inhibitors, guided by serial biopsies and ctDNA, may prolong the duration of benefit from FGFR inhibition in patients with FGFR2 fusion positive iCCA.

Other relatively rare actionable signatures, which include HER-2 amplification, RAF mutation, NTRK translocations, ROS1 fusions, and BRCA1/2 mutations, have been identified in cholangiocarcinoma and successful interventions targeting these signatures have been reported. In a basket trial with rare tumors including cholangiocarcinoma harboring *RAF* V600E mutations, the BRAF inhibitor dabrafenib and the MEK inhibitor trametinib resulted in a response rate of 42% per investigator assessment in 35 patients with cholangiocarcinoma.<sup>38</sup> The median progression-free survival by investigator assessment was 9.2 months, and the median overall survival was 11.7 months in this cohort.

### **(Katie Kelly) Immunotherapy in Intrahepatic Cholangiocarcinoma**

The human immune system holds the remarkable potential to identify and destroy malignant cells. This interaction is regulated by a complex system of immune checkpoint proteins, a counterbalance to the potential for the same mechanisms to incur catastrophic autoimmune disease. In recent years, immune checkpoint inhibitors (ICI) targeting the programmed cell death protein (PD-1) or the cytotoxic T-lymphocyte associated antigen 4 (CTLA-4) checkpoints have demonstrated the potential for relatively tumor-specific immune disinhibition, with durable efficacy and low rates of immune related adverse events across a range tumor types in oncology.<sup>39-41</sup> Though ICI and other immunotherapy approaches become a standard of care with unprecedented efficacy for many cancers, the role for immunotherapy in cholangiocarcinoma and other biliary tract cancers remains to be established.

### **Rationale for Immunotherapy in Intrahepatic Cholangiocarcinoma**

Intrahepatic cholangiocarcinoma is a heterogeneous subtype of biliary cancers owing to a complex interplay of many factors including tumor genetics, etiology, and microenvironment.<sup>3,42-45</sup> Subsets of intrahepatic cholangiocarcinomas display features associated with responsiveness – as well as non-response – to ICI in other tumor types, with a selection of these factors described further below.

#### *Tumor genetics*

Tumor genetics can impact the likelihood of tumor antigenicity, with certain mutations resulting in the expression and presentation of aberrant tumor proteins via major histocompatibility complexes (MHCs) on tumor cells themselves or by antigen presenting cells such as macrophages in the surrounding tumor microenvironment.<sup>46,47</sup>

Tumor mismatch repair (MMR) protein deficiency, which results in the genetic signature of

microsatellite instability (MSI) with high rates of somatic mutation and increased expression of tumor associated antigens, predicts responsiveness to ICI across tumor types.<sup>48,49</sup> In studies of patients with solid tumors known to be MMR deficient, PD-1 inhibition with pembrolizumab or nivolumab has achieved confirmed response rates exceeding 40%, with strikingly prolonged median durations of response and some cases with complete response.<sup>49-51</sup> Despite the relatively small sample sizes and uncontrolled design of these studies to date, the frequency and quality of the observed tumor responses led to the regulatory approval of pembrolizumab for MMR-deficient and/or MSI-high solid tumors, becoming the first histology-agnostic drug approval in oncology.<sup>52</sup> MMR deficiency, whether sporadic or inherited, may be present in up to 10% of intrahepatic cholangiocarcinomas based upon a review of published studies reporting on rates of MSI or MMR deficiency in biliary cancers by anatomic location,<sup>53</sup> though other studies suggest lower frequency.<sup>49,54</sup>

Tumor mutational load, also known as tumor mutation burden (TMB), is another genetic feature which has shown association with likelihood of response to ICI across tumor types.<sup>55-57</sup> As with MMR deficiency leading to microsatellite instability, high TMB is presumed to result in an increased likelihood of tumor-specific neoantigens recognizable by the immune system. While the majority of biliary tract cancers have low to intermediate TMB, retrospective mutation profiling of biliary cancer cohorts suggest that around 4-6% of biliary cancers are hypermutated, estimates which generally include cases with deficient MMR as discussed above.<sup>3,44</sup>

Conversely, tumors with oncogene addiction such as non-small cell lung cancer with *ALK* fusion or *EGFR* mutation have been shown to have lower TMB and lower likelihood of

response to ICI in lung cancer.<sup>58,59</sup> While these findings require validation across tumor types and contexts, they raise the hypothesis that tumors with a single gene driver – such as intrahepatic cholangiocarcinomas with *FGFR2* fusions -- may harbor fewer tumor associated antigens and consequently could have lower response rates to ICI. Future subanalyses of ICI studies in cholangiocarcinoma according to tumor mutation status are needed to confirm whether certain genetically-defined subgroups are more or less likely to respond to ICI.

#### *Etiology of cholangiocarcinomas*

In South East Asia, chronic liver inflammation caused by flukes such as *Opisthorchis viverrini* and *Clonorchis sinensis* accounts for over 8000 cases of cholangiocarcinoma annually.<sup>60</sup> Fluke-associated cholangiocarcinomas demonstrate distinct DNA methylation and transcriptional profiles as well as significantly higher mutation rate by comparison with fluke-negative cholangiocarcinomas,<sup>44</sup> suggesting potential for differential response to ICI though this has not been studied in clinical cohorts to date. Viral hepatitis B and C are also common risk factors for cholangiocarcinoma worldwide. Though virally-associated cancers have shown promising rates of response to ICI in retrospective analyses across other tumor types,<sup>61,62</sup> it is unknown whether underlying viral hepatitis impacts ICI response in cholangiocarcinoma.

#### *Tumor immune microenvironment*

The liver maintains a chronic state of immune tolerance, mediated in part by resident macrophages called Kupffer cells, to avoid severe inflammation in its constant state of exposure to non-pathogenic gut commensal bacteria and other antigens from the digestive system.<sup>63,64</sup> Kupffer cells and dendritic cells in liver express tolerogenic factors including PD-L1,<sup>63</sup> and these mechanisms may be exploited by liver tumors which further induce T cell exhaustion by

upregulation of immune checkpoints including TIM3, LAG3, PD-1, and CTLA-4.<sup>65-68</sup> In studies of tumor infiltrating lymphocytes harvested from human cholangiocarcinoma or hepatocellular carcinoma tumors, *ex vivo* administration of ICI resulted in T cell proliferation and stimulation,<sup>67,69</sup> suggesting the potential for ICI to restore anti-tumor immunity in these liver tumors.

Other unique features of the intrahepatic cholangiocarcinoma microenvironment which could impact responsiveness to ICI include a tumor reactive stroma which can induce desmoplasia, limiting drug or immune cell penetration;<sup>43</sup> the enterohepatic bile acid circulation which regulates hepatic natural killer T cell recruitment and interferon gamma production;<sup>70</sup> and frequent exposure to antibiotics owing to propensity for biliary obstruction, which may modulate the gut microbiome and is associated with poorer outcomes on ICI therapy across tumor types.<sup>71-73</sup>

Collectively, the heterogeneity of intrahepatic cholangiocarcinomas underscores the potential for differential responses to therapies targeting the immune system. Subanalyses of large cohorts of cholangiocarcinoma patients treated with ICI are needed identify the tumor and microenvironment factors associated with likelihood of response as well as non-response.

### **Clinical Data for ICI as Monotherapy in Intrahepatic Cholangiocarcinoma**

Though numerous clinical trials studying ICI are underway in intrahepatic cholangiocarcinoma, the existing clinical data remain predominantly limited to small single arm studies and subanalyses of basket trials. In studies of patients with MMR deficient solid tumors treated with pembrolizumab, the objective response rate has exceeded 40%, including a few patients with MMR-deficient cholangiocarcinoma with prolonged partial or complete responses.<sup>49,50</sup>

These findings are supported by case reports also detailing profound and prolonged responses to ICI in cholangiocarcinoma patients with known MSI or MMR deficiency, high TMB, or high rates of insertion or deletion mutations, which can result in neoantigens.<sup>74-78</sup>

In microsatellite-stable, non-mismatch repair deficient cholangiocarcinomas, however, the objective response rate to ICI monotherapy appears much lower, though data are mixed. KEYNOTE-158 (NCT02628067) is the largest study to date of ICI monotherapy with pembrolizumab in advanced biliary cancers without known MMR deficiency after progression on or intolerance to at least one line of standard therapy.<sup>79</sup> Among 104 patients, the confirmed objective response rate by RECIST 1.1<sup>80</sup> by independent central review was 5.8%, with median duration of response not reached and 50% of responses ongoing for at least 24 months. Tumor MSI status was non-MSI-high for 99 patients (95.2%) and missing for 5 patients (4.8%); none were known to be MSI-high. Tumor PD-L1 expression was assessed as a combined positive score (CPS) with  $\geq 1\%$  considered positive; among the approximately 60% of patients positive for PD-L1, the ORR was 6.6% compared to 2.9% for those negative. TMB, tumor mutation profiles, and the proportions of patients with intrahepatic versus extrahepatic cholangiocarcinoma or gall bladder carcinoma were not reported in this cohort. The adverse event profile of pembrolizumab in KEYNOTE-158 was similar to that of other tumor types, with one event of grade 3 immune-related hepatitis and one event of grade 5 immune-related renal failure.

Table 3 provides a summary of preliminary results from selected completed studies of ICI monotherapy in cholangiocarcinoma, with objective response rates ranging from 3-22%.<sup>79,81-83</sup>

Interpretation of these studies is limited by a variety of factors, including single-arm designs



with small sample sizes, inconsistent availability of MSI/MMR status and other candidate biomarkers, and heterogeneous or unreported proportions with intrahepatic versus extrahepatic or gallbladder sites of primary tumor. Reassuringly consistent across studies, however, is the finding of acceptable safety profiles, similar to studies of ICI monotherapy in other tumor types, without any apparent increase in rates of biliary complications or immune-related hepatitis in this population at risk for biliary obstruction and hepatic dysfunction.

Overall, these trials suggest a modest objective response rate for ICI as monotherapy in biliary tract cancers, though the efficacy specific to intrahepatic cholangiocarcinoma has been reported only from one trial; none of the responders had MMR deficiency in that study.<sup>82</sup> Despite the lower rates of response, however, the quality of responses was robust and durable across these studies, as has been seen with ICI in other tumor types, and warrants further studies to identify biomarkers and of combination strategies to augment the proportion with response.

### **Immunotherapy Combination Approaches in Development for Intrahepatic Cholangiocarcinoma**

Many studies are now ongoing to determine the efficacy and safety of immunotherapies in combination with other agents, with the goal of improving upon the proportion of patients with response to ICI. Table 4 displays a selection of approaches designed to increase tumor associated antigen exposure, enhance T cell activation, reduce immunosuppressive factors, or otherwise modulate the immune microenvironment to promote an immune response.

### **Summary of Current Role and Future Directions for Immunotherapy in Intrahepatic Cholangiocarcinoma**

Despite a complex tumor and immune microenvironment with features suggesting the potential

for anti-tumor immune responses, the studies of ICI monotherapy in biliary tract cancers have shown limited efficacy to date, though the safety profile has been reassuring and similar to other cancer types.

The dramatic and durable responses to ICI therapies in MSI-high and MMR deficient solid tumors including cholangiocarcinoma warrant testing for tumor MSI/MMR status in all patients with advanced biliary cancers. Our practice is to request this testing at the time of diagnosis with advanced disease or after resection in cases with high risk for recurrence, and to treat advanced cholangiocarcinoma patients with MSI-high or MMR deficient cholangiocarcinomas with pembrolizumab early in the course of advanced disease, soon after failure of first-line chemotherapy.

### **Future Directions**

Advanced iCCA still remains a difficult to treat disease, and therapy remains palliative. Future studies will continue to focus on targeting genetic aberrations (FGFR2, IDH, BRAF, etc). We need to better understand which agents are best tolerated, most therapeutic, and which combinations of drugs are most effective. The value of assessing circulating DNA and tumor cells in identifying these mutations and targeted drug resistance also requires further studies.

The occurrence of meaningful and durable responses with immunotherapy in small subsets of iCCA patients without MSI/MMR deficiency, suggests unrecognized pathways may influence response in this heterogeneous group of cancers. To characterize these pathways and biomarkers thereof, it is essential that future studies of immunotherapy collect and report information on important clinical covariates (e.g. anatomic site, viral hepatitis status, region of world) along with blood and tumor samples for testing of candidate biomarkers, including MSI,

MMR, TMB, and PDL-1 status and tumor somatic mutations in order to define those patients most likely to benefit. The next generation of clinical trials studying immunotherapy combinations designed to augment the immune anti-tumor response are also underway. With subanalyses of clinical covariates and translational research on tumor and microenvironment factors which impact the immune response, immunotherapy could become part of the treatment landscape for intrahepatic cholangiocarcinoma in the future.

We also note that iCCA is frequently a disease of genetic aberrations of chromatin modifiers such as BAP1 and ARID1.<sup>84</sup> ARID1 mutations have been linked to defective DNA repair processes which sensitizes cells to PARP inhibitors.<sup>85</sup> Likewise, BAP1 mutations have also been linked to cellular sensitivity to apoptosis following treatment with the PARP inhibitor olaparib.<sup>86</sup> Trials examining PARP inhibitors in patients with these cellular defects are currently ongoing and eagerly awaited.

iCCA also has a rich stroma of cancer associated fibroblasts (CAF). Therapeutically targeting these cells may also be beneficial in this cancer {Chen, 2019 #173}. Indeed, in preclinical murine models of iCCA, these cells have been therapeutically targeted with CCA suppressive effects {Rizvi, 2014 #201}. We also anticipate further studies coupling other therapies with CAF directed therapy for the treatment of iCCA.

## **Acknowledgements**

We are indebted to the outstanding administrative and manuscript production services of Ms. Courtney Hoover. She was instrumental in assembling this document and in coordinating activities amongst all the multi-institutional authors.

## References:

- [1] Blechacz B, Komuta M, Roskams T, Gores GJ. Clinical diagnosis and staging of cholangiocarcinoma. *Nat Rev Gastroenterol Hepatol* 2011;8:512-522.
- [2] Razumilava N, Gores GJ. Cholangiocarcinoma. *Lancet* 2014;383:2168-2179.
- [3] Nakamura H, Arai Y, Totoki Y, Shirota T, Elzawahry A, Kato M, et al. Genomic spectra of biliary tract cancer. *Nat Genet* 2015;47:1003-1010.
- [4] Khan SA, Tavolari S, Brandi G. Cholangiocarcinoma: Epidemiology and risk factors. *Liver Int* 2019;39 Suppl 1:19-31.
- [5] Rizvi S, Gores GJ. Pathogenesis, diagnosis, and management of cholangiocarcinoma. *Gastroenterology* 2013;145:1215-1229.
- [6] Rizvi S, Khan SA, Hallemeier CL, Kelley RK, Gores GJ. Cholangiocarcinoma - evolving concepts and therapeutic strategies. *Nat Rev Clin Oncol* 2018;15:95-111.
- [7] Petrick JL, Thistle JE, Zeleniuch-Jacquotte A, Zhang X, Wactawski-Wende J, Van Dyke AL, et al. Body Mass Index, Diabetes and Intrahepatic Cholangiocarcinoma Risk: The Liver Cancer Pooling Project and Meta-analysis. *Am J Gastroenterol* 2018;113:1494-1505.
- [8] Kendall T, Verheij J, Gaudio E, Evert M, Guido M, Goepfert B, et al. Anatomical, histomorphological and molecular classification of cholangiocarcinoma. *Liver Int* 2019;39 Suppl 1:7-18.
- [9] Kipp BR, Voss JS, Kerr SE, Barr Fritcher EG, Graham RP, Zhang L, et al. Isocitrate dehydrogenase 1 and 2 mutations in cholangiocarcinoma. *Hum Pathol* 2012;43:1552-1558.
- [10] Graham RP, Barr Fritcher EG, Pestova E, Schulz J, Sitailo LA, Vasmatzis G, et al. Fibroblast growth factor receptor 2 translocations in intrahepatic cholangiocarcinoma. *Hum Pathol* 2014;45:1630-1638.
- [11] Shroff RT, Kennedy EB, Bachini M, Bekaii-Saab T, Crane C, Edeline J, et al. Adjuvant Therapy for Resected Biliary Tract Cancer: ASCO Clinical Practice Guideline. *J Clin Oncol* 2019;37:1015-1027.
- [12] Glimelius B, Hoffman K, Sjoden PO, Jacobsson G, Sellstrom H, Enander LK, et al. Chemotherapy improves survival and quality of life in advanced pancreatic and biliary cancer. *Ann Oncol* 1996;7:593-600.
- [13] Valle J, Wasan H, Palmer DH, Cunningham D, Anthony A, Maraveyas A, et al. Cisplatin plus gemcitabine versus gemcitabine for biliary tract cancer. *N Engl J Med* 2010;362:1273-1281.
- [14] Okusaka T, Nakachi K, Fukutomi A, Mizuno N, Ohkawa S, Funakoshi A, et al. Gemcitabine alone or in combination with cisplatin in patients with biliary tract cancer: a comparative multicentre study in Japan. *Br J Cancer* 2010;103:469-474.
- [15] Valle JW, Furuse J, Jitlal M, Beare S, Mizuno N, Wasan H, et al. Cisplatin and gemcitabine for advanced biliary tract cancer: a meta-analysis of two randomised trials. *Annals of Oncology* 2013.
- [16] Sama AR, Denlinger CS, Vogel A, He AR, Bousmans N, Zhang W, et al. Gemcitabine and cisplatin plus ramucirumab or merestinib or placebo in first-line treatment for advanced or metastatic biliary tract cancer: A double-blind, randomized phase II trial. *Journal of Clinical Oncology* 2017;35:TPS509-TPS509.
- [17] Valle JW, Wasan H, Lopes A, Backen AC, Palmer DH, Morris K, et al. Cediranib or placebo

in combination with cisplatin and gemcitabine chemotherapy for patients with advanced biliary tract cancer (ABC-03): a randomised phase 2 trial. *Lancet Oncol* 2015;16:967-978.

[18] Malka D, Cervera P, Foulon S, Trarbach T, de la Fouchardiere C, Boucher E, et al. Gemcitabine and oxaliplatin with or without cetuximab in advanced biliary-tract cancer (BINGO): a randomised, open-label, non-comparative phase 2 trial. *Lancet Oncol* 2014;15:819-828.

[19] Lamarca A, Ross P, Wasan HS, Hubner RA, McNamara MG, Lopes A, et al. Advanced intrahepatic cholangiocarcinoma: post-hoc analysis of the ABC-01, -02 and -03 clinical trials. *J Natl Cancer Inst* 2019.

[20] Chen JS, Hsu C, Chiang NJ, Tsai CS, Tsou HH, Huang SF, et al. A KRAS mutation status-stratified randomized phase II trial of gemcitabine and oxaliplatin alone or in combination with cetuximab in advanced biliary tract cancer. *Ann Oncol* 2015;26:943-949.

[21] Lee J, Park SH, Chang HM, Kim JS, Choi HJ, Lee MA, et al. Gemcitabine and oxaliplatin with or without erlotinib in advanced biliary-tract cancer: a multicentre, open-label, randomised, phase 3 study. *Lancet Oncol* 2012;13:181-188.

[22] Valle JW, Lamarca A, Goyal L, Barriuso J, Zhu AX. New Horizons for Precision Medicine in Biliary Tract Cancers. *Cancer Discov* 2017;7:943-962.

[23] Borger DR, Tanabe KK, Fan KC, Lopez HU, Fantin VR, Straley KS, et al. Frequent mutation of isocitrate dehydrogenase (IDH)1 and IDH2 in cholangiocarcinoma identified through broad-based tumor genotyping. *Oncologist* 2012;17:72-79.

[24] Wang P, Dong Q, Zhang C, Kuan PF, Liu Y, Jeck WR, et al. Mutations in isocitrate dehydrogenase 1 and 2 occur frequently in intrahepatic cholangiocarcinomas and share hypermethylation targets with glioblastomas. *Oncogene* 2013;32:3091-3100.

[25] Borger DR, Goyal L, Yau T, Poon RT, Ancukiewicz M, Deshpande V, et al. Circulating oncometabolite 2-hydroxyglutarate is a potential surrogate biomarker in patients with isocitrate dehydrogenase-mutant intrahepatic cholangiocarcinoma. *Clin Cancer Res* 2014;20:1884-1890.

[26] Rohle D, Popovici-Muller J, Palaskas N, Turcan S, Grommes C, Campos C, et al. An inhibitor of mutant IDH1 delays growth and promotes differentiation of glioma cells. *Science* 2013;340:626-630.

[27] Lowery MA, Burris HA, 3rd, Janku F, Shroff RT, Cleary JM, Azad NS, et al. Safety and activity of ivosidenib in patients with IDH1-mutant advanced cholangiocarcinoma: a phase 1 study. *Lancet Gastroenterol Hepatol* 2019.

[28] Harding JJ, Lowery MA, Shih AH, Schvartzman JM, Hou S, Famulare C, et al. Isoform Switching as a Mechanism of Acquired Resistance to Mutant Isocitrate Dehydrogenase Inhibition. *Cancer Discov* 2018;8:1540-1547.

[29] Arai Y, Totoki Y, Hosoda F, Shirota T, Hama N, Nakamura H, et al. Fibroblast growth factor receptor 2 tyrosine kinase fusions define a unique molecular subtype of cholangiocarcinoma. *Hepatology* 2014;59:1427-1434.

[30] Sia D, Losic B, Moeini A, Cabellos L, Hao K, Revill K, et al. Massive parallel sequencing uncovers actionable FGFR2-PPHLN1 fusion and ARAF mutations in intrahepatic cholangiocarcinoma. *Nat Commun* 2015;6:6087.

[31] Wu YM, Su F, Kalyana-Sundaram S, Khazanov N, Ateeq B, Cao X, et al. Identification of targetable FGFR gene fusions in diverse cancers. *Cancer Discov* 2013;3:636-647.

- [32] Javle M, Lowery M, Shroff RT, Weiss KH, Springfield C, Borad MJ, et al. Phase II Study of BGJ398 in Patients With FGFR-Altered Advanced Cholangiocarcinoma. *J Clin Oncol* 2018;36:276-282.
- [33] Mazzaferro V, El-Rayes BF, Droz Dit Busset M, Cotsoglou C, Harris WP, Damjanov N, et al. Derazantinib (ARQ 087) in advanced or inoperable FGFR2 gene fusion-positive intrahepatic cholangiocarcinoma. *Br J Cancer* 2019;120:165-171.
- [34] Kalyukina M, Yosaatmadja Y, Middleditch MJ, Patterson AV, Smaill JB, Squire CJ. TAS-120 Cancer Target Binding: Defining Reactivity and Revealing the First Fibroblast Growth Factor Receptor 1 (FGFR1) Irreversible Structure. *ChemMedChem* 2019;14:494-500.
- [35] Goyal L, Arkenau H-T, Tran B, Soria J-C, Bahleda R, Mak G, et al. O-020 Early clinical efficacy of TAS-120, a covalently bound FGFR inhibitor, in patients with cholangiocarcinoma. *Annals of Oncology* 2017;28.
- [36] Goyal L, Saha SK, Liu LY, Siravegna G, Leshchiner I, Ahronian LG, et al. Polyclonal Secondary FGFR2 Mutations Drive Acquired Resistance to FGFR Inhibition in Patients with FGFR2 Fusion-Positive Cholangiocarcinoma. *Cancer Discov* 2017;7:252-263.
- [37] Goyal L, Shi L, Liu LY, Fece de la Cruz F, Lennerz JK, Raghavan S, et al. TAS-120 Overcomes Resistance to ATP-Competitive FGFR Inhibitors in Patients with FGFR2 Fusion-Positive Intrahepatic Cholangiocarcinoma. *Cancer Discov* 2019;9:1064-1079.
- [38] Wainberg ZA, Lassen UN, Elez E, Italiano A, Curigliano G, Braud FGD, et al. Efficacy and safety of dabrafenib (D) and trametinib (T) in patients (pts) with BRAF V600E -mutated biliary tract cancer (BTC): A cohort of the ROAR basket trial. *Journal of Clinical Oncology* 2019;37:187-187.
- [39] Postow MA, Callahan MK, Wolchok JD. Immune Checkpoint Blockade in Cancer Therapy. *J Clin Oncol* 2015;33:1974-1982.
- [40] Topalian SL, Hodi FS, Brahmer JR, Gettinger SN, Smith DC, McDermott DF, et al. Safety, activity, and immune correlates of anti-PD-1 antibody in cancer. *N Engl J Med* 2012;366:2443-2454.
- [41] Postow MA, Sidlow R, Hellmann MD. Immune-Related Adverse Events Associated with Immune Checkpoint Blockade. *N Engl J Med* 2018;378:158-168.
- [42] Farshidfar F, Zheng S, Gingras MC, Newton Y, Shih J, Robertson AG, et al. Integrative Genomic Analysis of Cholangiocarcinoma Identifies Distinct IDH-Mutant Molecular Profiles. *Cell Rep* 2017;19:2878-2880.
- [43] Hogdall D, Lewinska M, Andersen JB. Desmoplastic Tumor Microenvironment and Immunotherapy in Cholangiocarcinoma. *Trends Cancer* 2018;4:239-255.
- [44] Jusakul A, Cutcutache I, Yong CH, Lim JQ, Huang MN, Padmanabhan N, et al. Whole-Genome and Epigenomic Landscapes of Etiologically Distinct Subtypes of Cholangiocarcinoma. *Cancer Discov* 2017;7:1116-1135.
- [45] Rhee H, Ko JE, Chung T, Jee BA, Kwon SM, Nahm JH, et al. Transcriptomic and histopathological analysis of cholangiolocellular differentiation trait in intrahepatic cholangiocarcinoma. *Liver Int* 2018;38:113-124.
- [46] Schumacher TN, Schreiber RD. Neoantigens in cancer immunotherapy. *Science* 2015;348:69-74.
- [47] Ward JP, Gubin MM, Schreiber RD. The Role of Neoantigens in Naturally Occurring and Therapeutically Induced Immune Responses to Cancer. *Adv Immunol* 2016;130:25-74.

- [48]Gubin MM, Zhang X, Schuster H, Caron E, Ward JP, Noguchi T, et al. Checkpoint blockade cancer immunotherapy targets tumour-specific mutant antigens. *Nature* 2014;515:577-581.
- [49]Le DT, Durham JN, Smith KN, Wang H, Bartlett BR, Aulakh LK, et al. Mismatch repair deficiency predicts response of solid tumors to PD-1 blockade. *Science* 2017;357:409-413.
- [50]Le DT, Uram JN, Wang H, Bartlett BR, Kemberling H, Eyring AD, et al. PD-1 Blockade in Tumors with Mismatch-Repair Deficiency. *N Engl J Med* 2015;372:2509-2520.
- [51]Overman MJ, McDermott R, Leach JL, Lonardi S, Lenz HJ, Morse MA, et al. Nivolumab in patients with metastatic DNA mismatch repair-deficient or microsatellite instability-high colorectal cancer (CheckMate 142): an open-label, multicentre, phase 2 study. *Lancet Oncol* 2017;18:1182-1191.
- [52]Rizvi S, Gores GJ. Fibroblast Growth Factor Receptor Inhibition for Cholangiocarcinoma: Looking Through a Door Half-Opened. *Hepatology* 2018;68:2428-2430.
- [53]Silva VW, Askan G, Daniel TD, Lowery M, Klimstra DS, Abou-Alfa GK, et al. Biliary carcinomas: pathology and the role of DNA mismatch repair deficiency. *Chin Clin Oncol* 2016;5:62.
- [54]Williams AS, Huang WY. The analysis of microsatellite instability in extracolonic gastrointestinal malignancy. *Pathology* 2013;45:540-552.
- [55]Chen H, Chong W, Wu Q, Yao Y, Mao M, Wang X. Association of LRP1B Mutation With Tumor Mutation Burden and Outcomes in Melanoma and Non-small Cell Lung Cancer Patients Treated With Immune Check-Point Blockades. *Front Immunol* 2019;10:1113.
- [56]Hellmann MD, Callahan MK, Awad MM, Calvo E, Ascierto PA, Atmaca A, et al. Tumor Mutational Burden and Efficacy of Nivolumab Monotherapy and in Combination with Ipilimumab in Small-Cell Lung Cancer. *Cancer Cell* 2019;35:329.
- [57]Singal G, Miller PG, Agarwala V, Li G, Kaushik G, Backenroth D, et al. Association of Patient Characteristics and Tumor Genomics With Clinical Outcomes Among Patients With Non-Small Cell Lung Cancer Using a Clinicogenomic Database. *JAMA* 2019;321:1391-1399.
- [58]Berghoff AS, Bellosillo B, Caux C, de Langen A, Mazieres J, Normanno N, et al. Immune checkpoint inhibitor treatment in patients with oncogene-addicted non-small cell lung cancer (NSCLC): summary of a multidisciplinary round-table discussion. *ESMO Open* 2019;4:e000498.
- [59]Blons H, Garinet S, Laurent-Puig P, Oudart JB. Molecular markers and prediction of response to immunotherapy in non-small cell lung cancer, an update. *J Thorac Dis* 2019;11:S25-S36.
- [60]Jusakul A, Kongpetch S, Teh BT. Genetics of *Opisthorchis viverrini*-related cholangiocarcinoma. *Curr Opin Gastroenterol* 2015;31:258-263.
- [61]Gao P, Lazare C, Cao C, Meng Y, Wu P, Zhi W, et al. Immune checkpoint inhibitors in the treatment of virus-associated cancers. *J Hematol Oncol* 2019;12:58.
- [62]Woller N, Gurlevik E, Fleischmann-Mundt B, Schumacher A, Knocke S, Kloos AM, et al. Viral Infection of Tumors Overcomes Resistance to PD-1-immunotherapy by Broadening Neoantigenome-directed T-cell Responses. *Mol Ther* 2015;23:1630-1640.
- [63]Heymann F, Tacke F. Immunology in the liver--from homeostasis to disease. *Nat Rev Gastroenterol Hepatol* 2016;13:88-110.
- [64]Krenkel O, Tacke F. Liver macrophages in tissue homeostasis and disease. *Nat Rev Immunol* 2017;17:306-321.



- [65] Kasper HU, Drebber U, Stippel DL, Dienes HP, Gillessen A. Liver tumor infiltrating lymphocytes: comparison of hepatocellular and cholangiolar carcinoma. *World J Gastroenterol* 2009;15:5053-5057.
- [66] Unitt E, Rushbrook SM, Marshall A, Davies S, Gibbs P, Morris LS, et al. Compromised lymphocytes infiltrate hepatocellular carcinoma: the role of T-regulatory cells. *Hepatology* 2005;41:722-730.
- [67] Zhou G, Sprengers D, Boor PPC, Doukas M, Schutz H, Mancham S, et al. Antibodies Against Immune Checkpoint Molecules Restore Functions of Tumor-Infiltrating T Cells in Hepatocellular Carcinomas. *Gastroenterology* 2017;153:1107-1119 e1110.
- [68] Ye Y, Zhou L, Xie X, Jiang G, Xie H, Zheng S. Interaction of B7-H1 on intrahepatic cholangiocarcinoma cells with PD-1 on tumor-infiltrating T cells as a mechanism of immune evasion. *J Surg Oncol* 2009;100:500-504.
- [69] Zhou G, Sprengers D, Mancham S, Erkens R, Boor PPC, van Beek AA, et al. Reduction of immunosuppressive tumor microenvironment in cholangiocarcinoma by ex-vivo targeting immune checkpoint molecules. *Journal of hepatology* 2019.
- [70] Ma C, Han M, Heinrich B, Fu Q, Zhang Q, Sandhu M, et al. Gut microbiome-mediated bile acid metabolism regulates liver cancer via NKT cells. *Science* 2018;360.
- [71] Elkrief A, El Raichani L, Richard C, Messaoudene M, Belkaid W, Malo J, et al. Antibiotics are associated with decreased progression-free survival of advanced melanoma patients treated with immune checkpoint inhibitors. *Oncoimmunology* 2019;8:e1568812.
- [72] Ouaknine Krief J, Helly de Tauriers P, Dumenil C, Neveux N, Dumoulin J, Giraud V, et al. Role of antibiotic use, plasma citrulline and blood microbiome in advanced non-small cell lung cancer patients treated with nivolumab. *J Immunother Cancer* 2019;7:176.
- [73] Tinsley N, Zhou C, Tan G, Rack S, Lorigan P, Blackhall F, et al. Cumulative Antibiotic Use Significantly Decreases Efficacy of Checkpoint Inhibitors in Patients with Advanced Cancer. *Oncologist* 2019.
- [74] Czink E, Kloor M, Goepfert B, Frohling S, Uhrig S, Weber TF, et al. Successful immune checkpoint blockade in a patient with advanced stage microsatellite-unstable biliary tract cancer. *Cold Spring Harb Mol Case Stud* 2017;3.
- [75] Alshari OM, Dawaymeh TA, Tashtush NA, Aleshawi AJ, Al Manasra ARA, Obeidat KA. Completely resolved advanced biliary tract cancer after treatment by pembrolizumab: a report of two cases. *Onco Targets Ther* 2019;12:5293-5298.
- [76] Gbolahan O, Hashemi-Sadraei N, O'Neil B. Prolonged Response to Anti-PD-1 Antibody Therapy in Chemotherapy-Refractory Cholangiocarcinoma With High Tumor Mutational Burden. *J Natl Compr Canc Netw* 2019;17:644-648.
- [77] Mou H, Yu L, Liao Q, Hou X, Wu Y, Cui Q, et al. Successful response to the combination of immunotherapy and chemotherapy in cholangiocarcinoma with high tumour mutational burden and PD-L1 expression: a case report. *BMC Cancer* 2018;18:1105.
- [78] Sui M, Li Y, Wang H, Luo Y, Wan T, Wang X, et al. Two cases of intrahepatic cholangiocellular carcinoma with high insertion-deletion ratios that achieved a complete response following chemotherapy combined with PD-1 blockade. *J Immunother Cancer* 2019;7:125.
- [79] Bang Y-Ju MM, D.; Chung, H.C.; Nagrial, A.; Kelley, R.K.; et al. . Pembrolizumab (pembro) for advanced biliary adenocarcinoma: Results from the KEYNOTE-028 (KN028) and KEYNOTE-158 (KN158) basket studies. . *Journal of Clinical Oncology* 2019.

- [80] Eisenhauer EA, Therasse P, Bogaerts J, Schwartz LH, Sargent D, Ford R, et al. New response evaluation criteria in solid tumours: revised RECIST guideline (version 1.1). *Eur J Cancer* 2009;45:228-247.
- [81] Ioka TU MO, D-Y; et al. Evaluation of safety and tolerability of durvalumab (D) with or without tremelimumab (T) in patients (pts) with biliary tract cancer (BTC). *Journal of Clinical Oncology* 2019.
- [82] Kim RKA, O.B.; et al. A phase II study of nivolumab in patients with advanced refractory biliary tract cancers (BTC). *Journal of Clinical Oncology* 2019.
- [83] Ueno M, Ikeda M, Morizane C, Kobayashi S, Ohno I, Kondo S, et al. Nivolumab alone or in combination with cisplatin plus gemcitabine in Japanese patients with unresectable or recurrent biliary tract cancer: a non-randomised, multicentre, open-label, phase 1 study. *Lancet Gastroenterol Hepatol* 2019;4:611-621.
- [84] Braconi C, Roessler S, Kruk B, Lammert F, Krawczyk M, Andersen JB. Molecular perturbations in cholangiocarcinoma: Is it time for precision medicine? *Liver Int* 2019;39 Suppl 1:32-42.
- [85] Shen J, Peng Y, Wei L, Zhang W, Yang L, Lan L, et al. ARID1A Deficiency Impairs the DNA Damage Checkpoint and Sensitizes Cells to PARP Inhibitors. *Cancer Discov* 2015;5:752-767.
- [86] Borchert S, Wessolly M, Schmeller J, Mairinger E, Kollmeier J, Hager T, et al. Gene expression profiling of homologous recombination repair pathway indicates susceptibility for olaparib treatment in malignant pleural mesothelioma in vitro. *BMC Cancer* 2019;19:108.
- [87] Edeline J, Benabdelghani M, Bertaut A, Watelet J, Hammel P, Joly JP, et al. Gemcitabine and Oxaliplatin Chemotherapy or Surveillance in Resected Biliary Tract Cancer (PRODIGE 12-ACCORD 18-UNICANCER GI): A Randomized Phase III Study. *J Clin Oncol* 2019;37:658-667.
- [88] Primrose JN, Fox RP, Palmer DH, Malik HZ, Prasad R, Mirza D, et al. Capecitabine compared with observation in resected biliary tract cancer (BILCAP): a randomised, controlled, multicentre, phase 3 study. *Lancet Oncol* 2019.
- [89] Valle J, Wasan H, Palmer DH, Cunningham D, Anthoney A, Maraveyas A, et al. Cisplatin plus Gemcitabine versus Gemcitabine for Biliary Tract Cancer. *N Engl J Med* 2010;362:1273-1281.
- [90] Bang Y-JU, M; Malka, D; Chung, HC; Nagrial, A; Kelley, RK; et al. Pembrolizumab (pembro) for advanced biliary adenocarcinoma: Results from the KEYNOTE-028 (KN028) and KEYNOTE-158 (KN158) basket studies. *American Society of Clinical Oncology Annual Meeting; 2019; Chicago, IL: J Clin Oncol* 2019.
- [91] Kim RK, DW; Alese, OB; et al. A phase II study of nivolumab in patients with advanced refractory biliary tract cancers (BTC). *American Society of Clinical Oncology Annual Meeting; 2019; Chicago, IL: J Clin Oncol; 2019.*
- [92] Ioka TU, M; Oh, D-Y; et al. Evaluation of safety and tolerability of durvalumab (D) with or without tremelimumab (T) in patients (pts) with biliary tract cancer (BTC). *Gastrointestinal Cancers Symposium; 2019; San Francisco, CA: J Clin Oncol; 2019.*

**Table 1. Randomized adjuvant chemotherapy studies for CCA.**

<b>Study</b> [clinicaltrials.gov ID]	<b>Population</b>	<b>N</b>	<b>Arms</b>	<b>vs</b>	<b>Outcome</b>
<b>PRODIGE12</b> France [NCT01313377] <sup>87</sup>	CCA & GBC	190	Observation	GemOx	Negative
<b>BilCap</b> UK [NCT00363584] <sup>88</sup>	CCA & GBC	437	Observation	Capecitabine	Positive

**Table 2. Advanced Biliary Cancer (ABC) Systemic Chemotherapy trials.**

<b>Study</b>	<b>Population</b>	<b>N</b>	<b>Arms</b>	<b>Vs</b>	<b>Outcome</b>
<b>ABC01/2</b> <sup>89</sup>	CCA & GBC	410	Gem	CisGem	Positive
<b>ABC03</b> <sup>17</sup>	CCA & GBC	126	CisGem	CisGem cedirinib	Negative
<b>ABC06</b>	CCA & GBC	162	Observation	FOLFOX	Positive

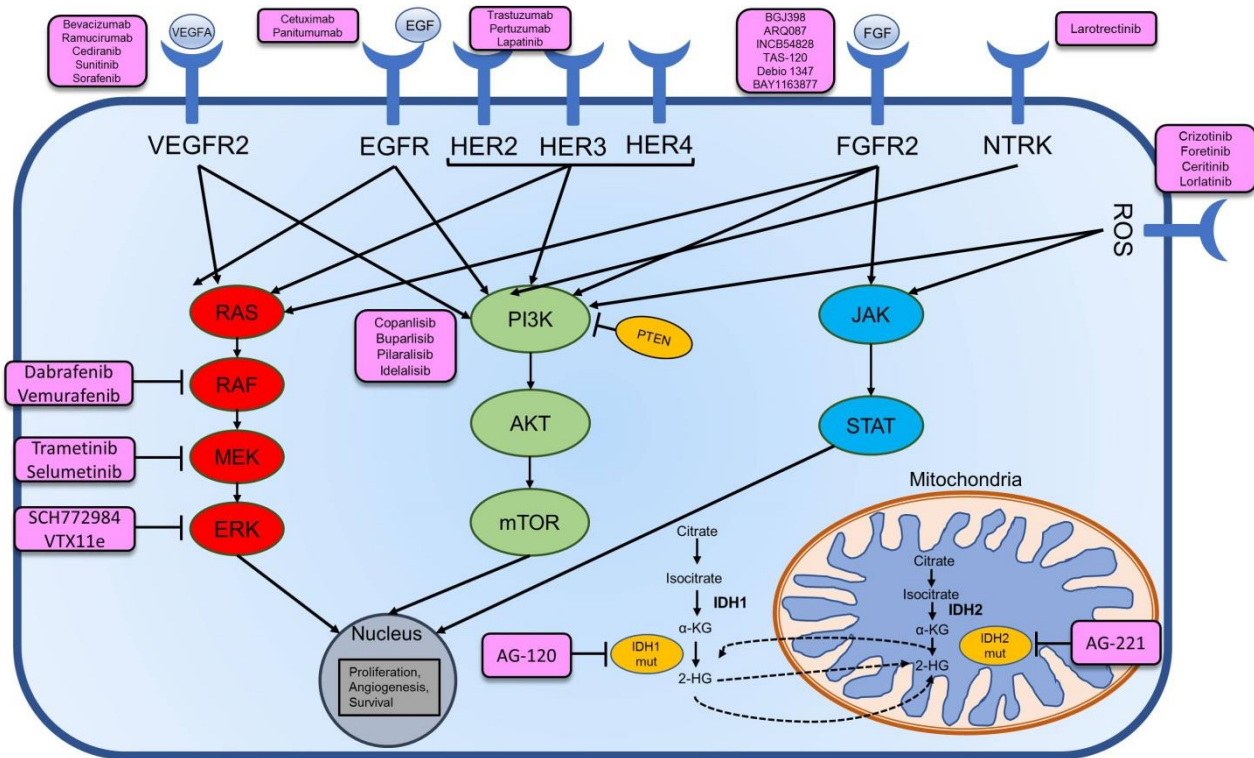
**Table 3. Clinical Trials of ICI Monotherapy in Cholangiocarcinoma**

	Pembrolizumab <sup>90</sup>	Nivolumab <sup>91</sup>	Nivolumab <sup>83</sup>	Durvalumab <sup>92</sup>
Phase of Study	2	2	1	1
Region	International	U.S.	Japan	Asia
Sample Size	104	54	30	42
Anatomic Site				
ICC	NR	59%	37%	31%
ECC		11%	23%	19%
GBC		30%	33%	45%
MSI/MMR Status	Non-MSI-H: 95.2% Unknown: 4.8%	NR*	NR	NR
PD-L1+ by IHC	58.7%	46%	NR	59.4%
TRAE Grade $\geq$ 3	13.5%	NR	10%	19%
ORR	5.8%	22%* ICC: 21.4%	3.0%	4.8%
Median PFS (mos.)	2.0	3.8	1.4	1.5
Median OS (mos.)	7.4	10.3	5.2	8.1

Key: ICC, intrahepatic cholangiocarcinoma; ECC, extrahepatic cholangiocarcinoma; GBC, gallbladder carcinoma. NR, not reported. MSI-H, MSI-high; MMR, mismatch repair. IHC, immunohistochemistry. TRAE, treatment-related adverse events. ORR, objective response rate. DOR, duration of response. PFS, progression-free survival. OS, overall survival. \*All 10 cases with partial response were MMR-proficient; 9 cases were not evaluable for response.

**Table 4. Clinical Trials of ICI Combinations and Other Novel Immunotherapies in Cholangiocarcinoma**

NCT	Title	ICI or other IO	Combination Agent	Phase	Rationale
		Pembrolizumab	GEMCIS	III	Increase tumor antigen exposure
		Durvalumab	GEMCIS		
		Atezolizumab	GEMCIS, PEGPH20		Microenvironment/stroma
		Durvalumab	Tremelimumab		ICI combination
		Nivolumab	Cabiralizumab		CSF1R
		Pembro	GMCSF		Improve antigen presentation
		M7824 bispecific			TGFBR1 rationale



**Figure 1. Schematic of targetable oncogenic signaling pathways in iCCA.**