

## Accepted Manuscript

Title: A case of unidirectional exit block during pulmonary vein isolation

Authors: Gabor Sandorfi M.D. Wim Bories BS Hein Heidbuchel M.D., Ph.D, FEHRA, FESC Andrea Sarkozy M.D., Ph.D.



PII: S1561-8811(17)30070-6  
DOI: <http://dx.doi.org/doi:10.1016/j.jicc.2017.07.001>  
Reference: JICC 426

To appear in:

Received date: 27-4-2017  
Revised date: 9-6-2017  
Accepted date: 10-7-2017

Please cite this article as: Gabor SandorfiWim BoriesHein HeidbuchelAndrea Sarkozy A case of unidirectional exit block during pulmonary vein isolation (2017), <http://dx.doi.org/10.1016/j.jicc.2017.07.001>

This is a PDF file of an unedited manuscript that has been accepted for publication. As a service to our customers we are providing this early version of the manuscript. The manuscript will undergo copyediting, typesetting, and review of the resulting proof before it is published in its final form. Please note that during the production process errors may be discovered which could affect the content, and all legal disclaimers that apply to the journal pertain.

**A case of unidirectional exit block during pulmonary vein isolation**

Gabor Sandorfi, M. D., Wim Bories, BS, Hein Heidbuchel, M.D., Ph.D, FEHRA, FESC,

Andrea Sarkozy, M.D., Ph.D.

Department of Cardiology, Electrophysiology Section, University Hospital Antwerp,

Antwerp, Belgium

Address for correspondence: Gabor Sandorfi, Cardiologie, Universitair Ziekenhuis

Antwerpen,

Wilrijkstraat 10, 2650 Edegem, Belgium.

Tel.: +32 3 821 3571

Fax: +32 3 821 4909

Email: sandorfidr@gmail.com

## Abstract

We present a case of unidirectional exit block from a pulmonary vein (PV) during a pulmonary vein isolation procedure. Following circumferential antral applications around the right PVs, PV pacing showed capture without exit. Meanwhile coronary sinus pacing showed continuous presence of delayed PV potentials. Our case is a rare example of unidirectional exit block since unidirectional block usually concerns entrance block.

Key words: atrial fibrillation; pulmonary vein isolation; unidirectional block.

Accepted Manuscript

## Introduction

Pulmonary vein isolation (PVI) is an accepted therapy in patients with atrial fibrillation<sup>1</sup>. Proving bidirectional block is the endpoint of this catheter ablation. The presence of unidirectional exit block is a very rare conduction block after PV ablation.

## Case report

A 71-year-old man with atrial fibrillation (AF) presented for pulmonary vein isolation. A decapolar catheter was placed into the coronary sinus (CS), and after transseptal puncture a duodecapolar circular mapping catheter (LASSO, Biosense Webster, Diamond Bar, CA) was advanced into the PVs. Following wide antral circumferential ablation, pacing manoeuvres were performed from the atrium and from the different PVs to confirm entry and exit block, respectively.

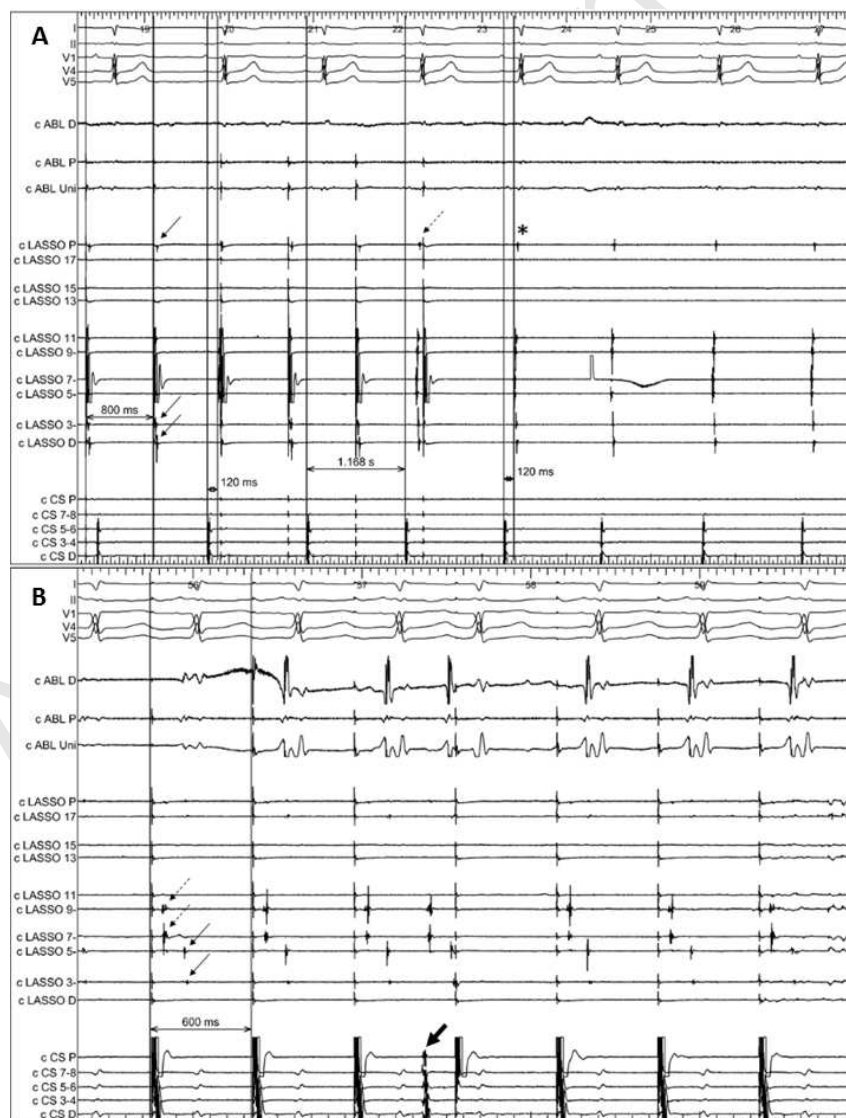
## Discussion

During pacing at a cycle length (CL) of 800 msec from LASSO pole 7-8 in the right superior PV (RSPV) small electrograms are visible on other LASSO bipoles (arrows, Panel A) proving PV capture. This was not associated with conduction to the atrium, i.e. exit block. Meanwhile an independent sinus rhythm is continuing with a CL of 1170 msec. At the sixth beat, an early sinus beat activates the vein before the next stimulus within the vein (dotted line arrow). Atrium-to-PV conduction is further confirmed when PV activation with the same activation sequence is seen during sinus rhythm after stopping pacing the PV (beats 7 to 9; asterisk). Also pacing from the CS (while the LASSO was in a more antral position) showed 1-to-1 entrance conduction (Panel B). Double potentials appear; the first potentials are antral LA electrograms (dotted line small arrows) and second potentials are PV potentials (small arrows). The PV potentials appear on the same LASSO poles with the same activation pattern

and similar coupling interval as compared to the fourth, spontaneous premature beat (Panel B, big arrow).

### Conclusion

Unidirectional entrance block has previously been described as a rare condition, occurring in 0,6% of the cases<sup>2</sup>. Although based on source-sink mismatch theory, unidirectional exit block should be more frequent than entrance block, it has rarely been reported at slow pacing rates. This is likely due to the clinical practice, usually performing exit pacing only after achieving entrance block during PVI. The clinical significance of unidirectional exit block is that in such cases PV pacing with mapping of earliest LA exit site for gap localization is not feasible<sup>3</sup>.



## References

1. Calkins H, Kuck KH, Cappato R, Brugada J, Camm AJ, Chen SA et al. 2012 HRS/EHRA/ECAS Expert Consensus Statement on Catheter and Surgical Ablation of Atrial Fibrillation: recommendation for patient selection, procedural techniques, patient management and follow-up, definitions, endpoints, and research trial design. *Europace* 2012;14:528-606.
2. Duytschaever M, De Meyer G, Acena M, El-Haddad M, De Greef Y, Van Heuverswyn F, et al. Lessons from dissociated pulmonary vein potentials: entry block implies exit block. *Europace* 2013;15:805-812.
3. Salas J, Castellanos E, Peinado R, Madero S, Barrio-López T, Ortiz M, et al. Atrial mapping during pulmonary vein pacing: a novel maneuver to detect and close residual conduction gaps in an ablation line. *J Interv Card Electrophysiol*. 2016;47:299-30.