

The Safety Profile of Intentional or Iatrogenic Sacrifice of the Artery of Adamkiewicz and Its Vicinity's Spinal Segmental Arteries: A Systematic Review

Terence Tan, MBBS^{1,2} , Joost Rutges, MD, PhD³ , Travis Marion, MD⁴, Charles Fisher, MD, MHSc⁵, and Jin Tee, MD, FRACS^{1,2}

Global Spine Journal
2020, Vol. 10(4) 464-475
© The Author(s) 2019
Article reuse guidelines:
sagepub.com/journals-permissions
DOI: 10.1177/2192568219845652
journals.sagepub.com/home/gsj



Abstract

Study Design: Systematic review.

Objectives: There is paucity of consensus on whether (1) the artery of Adamkiewicz (AoA) and (2) the number of contiguous segmental spinal arteries (SSAs) that can be safely ligated without causing spinal cord ischemia. The objective of this review is to determine the risk of motor neurological deficits from iatrogenic sacrifice of the (1) AoA and (2) its vicinity's SSAs.

Methods: Systematic review of the spine and vascular surgery was carried out in accordance to PRISMA guidelines. Outcomes in terms of risk of postoperative motor neurological deficit with occlusion of the AoA, bilateral contiguous SSAs, or unilateral contiguous SSAs were analyzed.

Results: Ten articles, all retrospective case series, were included. Three studies (total N = 50) demonstrated a postoperative neurological deficit risk of 4.0% when the AoA is occluded. When 1 to 6 pairs of SSAs (without knowledge of AoA location) were ligated, the postoperative neurological deficit risk was 0.6%, as compared with 5.4% when more than 6 bilateral pairs of SSAs were ligated (relative risk [RR] = 0.105, 95% CI 0.013-0.841, $P = .0337$). For unilateral ligation of SSAs of two to nine levels, the risk of postoperative neurological deficit does not exceed 1.3%.

Conclusion: The current best evidence indicates that (1) occlusion of the AoA and (2) occlusion of up to 6 pairs of SSAs is associated with a low risk of postoperative neurological deficit. This limited number of low quality studies restrict the ability to draw definitive conclusions. Ligation of AoA and SSAs should only be undertaken when absolutely required to mitigate the small but devastating risk of paralysis.

Keywords

artery of Adamkiewicz, radiculomedullary artery, spinal segmental artery, iatrogenic, occlusion, postoperative complication, spinal cord injury, spinal cord ischemia

Introduction

The spinal cord is classically described to be supplied by a single anterior spinal artery and paired posterior spinal arteries.¹ The arterial supply of the spinal cord is heavily augmented by segmental blood supply in the cervical, thoracic, and lumbar region by branches of the respective segmental spinal arteries (SSAs), and are known variously as medullary arteries, or radiculomedullary arteries.² The contingent contributor, and main radiculomedullary artery supplying the anterior spinal artery is the artery of Adamkiewicz (AoA), first described by Albert Wojciech Adamkiewicz in 1882.³ This artery arises

¹ The Alfred Hospital, Melbourne, Victoria, Australia

² National Trauma Research Institute Melbourne, Victoria, Australia

³ Erasmus MC, Rotterdam, Netherlands

⁴ Northern Ontario School of Medicine, Sudbury, Ontario, Canada

⁵ University of British Columbia and Vancouver General Hospital, Vancouver, British Columbia, Canada

Corresponding Author:

Jin Tee, Department of Neurosurgery, Level 1, Old Baker Building, The Alfred Hospital, 55 Commercial Road, Melbourne, Victoria 3004, Australia.
Email: jtee.neurosurgery@gmail.com



from the thoracolumbar region, frequently from T9-L2 on the left side, either from an intercostal artery or lumbar artery.⁴ Segmental spinal cord arterial supply (which branch from the SSA), have a highly variable distribution from individual to individual.

In clinical practice, certain surgical pathologies require iatrogenic sacrifice of the segmental spinal artery at the involved vertebral level. These pathologies include primary bone tumors, secondary bony metastases, spinal deformity, and spinal trauma.^{5,6} Procedures such as total en bloc spondylectomies, vertebrectomies, and anterior releases for deformity frequently cause compromise to the spinal cord arterial supply.

There has been a paucity of current and high-level evidence in humans with regard to the sacrifice of the AoA or its vicinity's segmental arteries, its potential neurological detriment and preventative or restorative measures taken to treat spinal cord ischemia or infarction. As there are significant ethical issues with performing such studies, animal studies have been performed to elucidate these findings. Animal studies have demonstrated the safety of permanent ligation of up to 3 bilateral SSAs,⁷ and the risk of functional neurological injury in ligation of 4 or more bilateral SSAs, including the AoA,⁸ or in the ligation of 5 or more bilateral SSAs not including the AoA.⁹

By systematically reviewing the spine and vascular surgery literature, this study aims to clarify (1) if the AoA (with or without concomitant SSA occlusion) can be occluded safely without postoperative neurological deficit and (2) the number/range of SSAs (without knowledge of the location of the AoA) that can be safely occluded without postoperative neurological deficit. AoA and SSA ligation in spine and vascular surgeries have obvious pathophysiological differences in terms of resultant spinal cord perfusion and ability to recruit collateral circulation. However, expansion of the search strategy to include vascular studies has the relative advantage of increasing the dispersion of results and thus capturing the expected range of true effects. The authors also provide a brief updated review on spinal cord vascular physiology.

Methods

This systematic review was conducted in accordance with the Preferred Reporting Items for Systematic Reviews and Meta-Analysis (PRISMA) guidelines.¹⁰

Article Search Strategy

A systematic electronic search using Medline, PubMed, EMBASE, Cochrane Database of Systematic Reviews, and Google Scholar was performed from their date of inception to April 30, 2018. A deliberately open search strategy was used to achieve the maximum number of articles for subsequent title and abstract review. For the PubMed search, combinations of the following MeSH (medical subject headings) terms were used to query the database: "Spinal Cord," "Spinal Cord Ischemia," "Blood Supply," "Treatment Outcome," and "Postoperative Complications." For all databases,

combinations of the following terms were used as key words for the search: "Adamkiewicz," "Radiculomedullary Artery," "Medullary Artery," "Segmental Artery," "Ligation," "Occlusion," "Spinal Cord," "Spinal Cord Ischemia," "Neurological Function," and "Postoperative Complication." All published English-language articles from the spine and vascular literature were included. The titles and abstracts of retrieved articles were screened by 2 authors (TT and JT) and selected articles by either author progressed to full-text review for final inclusion. The bibliography and citation list for all included articles were further screened to identify additional eligible articles.

Selection Criteria

Studies from both the spine and vascular literature were included for consideration. To determine if the AoA (with or without concomitant SSA occlusion) can be safely occluded, studies were included only if they met the following inclusion criteria: (1) human studies; (2) angiographically confirmed (digital subtraction, computed tomography, magnetic resonance) AoA; (3) occlusion of AoA explicitly stated in article; and (4) postoperative neurological status recorded. Concomitant ligation of SSAs was allowed. The number/range of SSAs occluded in addition to the AoA had to be explicitly stated or verified from the results, tables, or figures from the respective articles. To determine the number of SSAs (without knowledge of the location of the AoA) that can be safely ligated, the following inclusion criteria were used: (1) human studies; (2) number, or range of SSAs ligated explicitly stated; and (3) postoperative neurological status recorded. In this review, articles were excluded if they (1) included less than 5 subjects, (2) are case reports, or (3) are editorials, conference presentations, commentary, or expert opinions.

Study Quality and Risk of Bias Assessment

Levels of evidence, in accordance to the hierarchical quality rating system proposed by Wright et al¹¹ was assigned to each individual study. Internal validity and quality of the included studies were appraised using a modified version of the assessment tool developed by Cowley et al¹² for nonrandomized studies. The studies were independently assessed by 2 reviewers (TT and JT) and any discrepancies resolved by consensus.

Data Extraction and Analyses

From the included studies, number of subjects, literature type (spine or vascular), type of study, method of AoA identification (where applicable), level and laterality of AoA occluded, number/range of SSAs occluded, laterality, level of SSAs occluded and length of follow-up were recorded. Data was collated on an electronic spreadsheet (Microsoft Excel) created prior to the literature search. Postoperative neurological deficit was recorded in terms of motor impairment only, as assessed by

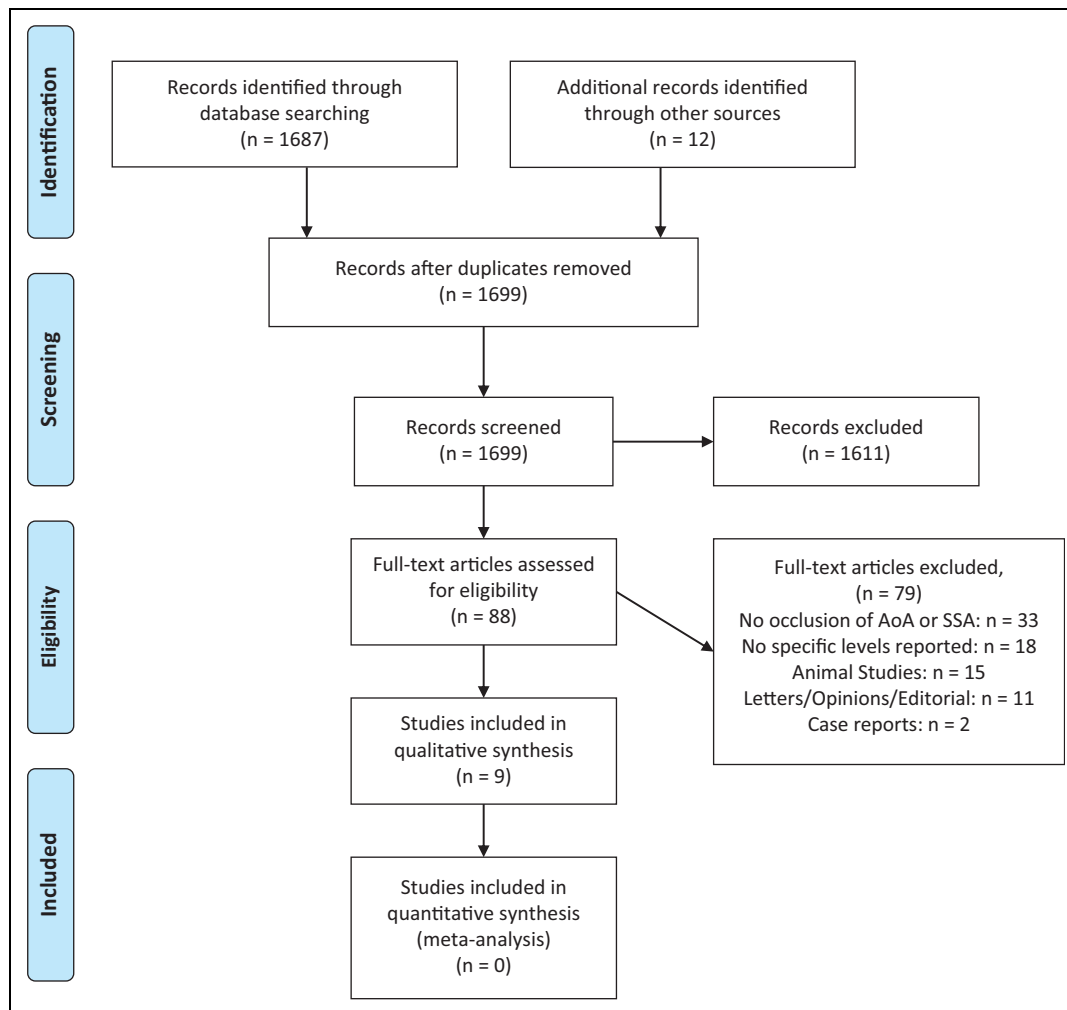


Figure 1. PRISMA (Preferred Reporting Items for Systematic Reviews and Meta-Analyses) flow diagram of study identification and inclusion.

any method from bedside examination to formal grading/functional scales.

Because of the heterogeneity of study data, quantitative meta-analysis was not performed. Outcome variables are simply reported as proportions and percentages. Relative risk with 95% confidence intervals were reported where appropriate. Arbitrary cutoffs of the range of SSAs occluded was used for ease of data interpretation. The primary outcome variable is the crude risk of postoperative motor neurological deficit, defined as immediate, or delayed, postoperative paraplegia, or paraparesis. Secondary outcome variables include the risk of immediate paraplegia, risk of immediate paraparesis, risk of delayed neurological deficit, and the proportion of patients with neurological recovery after postoperative neurological deficit. All data was extracted from article full texts, tables, and figures.

Results

The search algorithm returned a total of 1699 unique articles. After exclusion of articles based on title and abstract screening, 88 articles remained for full text assessment (Figure 1). Most

studies were excluded at this stage due to the articles: (1) not specifying occlusion of the AoA, (2) not specifying occlusion of the number/range of SSAs, or (3) being animal studies. After full text review, 9 articles were selected for inclusion. One additional article¹³ was included after screening the bibliography and citations of the included articles. As such, a total of 10 articles are included in this review (Table 1). The included studies were all retrospective case series, with 7 published in the spine literature,¹⁴⁻²⁰ and 3 in the vascular literature.^{13,21,22} Included studies had a range of 5 to 346 patients (median, N = 31.5). Four studies reported a length of follow-up ranging from 16 days to 51 months. Six articles did not state the length of follow-up (Table 1).

Studies With Occlusion of Artery of Adamkiewicz

There were 3 studies with data on outcomes after occlusion of the AoA. Murakami et al¹⁴ published a retrospective case series (n = 15) to determine the neurological outcomes after ligation of the AoA in total en bloc spondylectomy. Patients had primary bony tumors or metastatic tumors coincidentally at the

Table 1. Overview of Included Studies.

Author/Year	Field of Study	Type of Study	No. of Subjects	Average Age (Range), Years	Spinal Levels Involved	Information on AoA Occlusion	Information on SSA Occlusion	Follow-up
Etz/2006	Vascular	Case series	100	67 (27-86)	T3-L5	No	Yes	16.0 ± 15.2 days
Griep/1996	Vascular	Case series	93	65 (NR)	Thoracolumbar	No	Yes	NR
Murakami/2010	Spinal	Case series	79	NR	Thoracic	No	Yes	46 months
Tsirikos/2008	Spinal	Case series	346	12.3 (3-18)	Thoracolumbar	No	Yes	NR
Murakami/2010	Spinal	Case series	15	54.7 (13-67)	T4-L2	Yes	No	51 months
Soubeyrand/2011	Spinal	Case series	97	49 (7-76)	C7 to L3	No	Yes	NR
Zhao/2017	Spinal	Case series	11	15.7 (11-26)	T6-L1	No	Yes	12 months
Salame/2016	Spinal	Case series	5	42.2 (36-75)	T6-T11	Yes	Yes	NR
Wu/2006	Spinal	Case series	31	15.7 (13-23)	T5-T11	No	Yes	NR
Fukui/2016	Vascular	Case series	32	73.5 (29-89)	T1-L4	Yes	Yes	NR

Abbreviations: AoA, artery of Adamkiewicz; SSA, segmental spinal artery; NR, not reported.

level of the AoA thus requiring surgical ligation and sacrifice. The AoA was confirmed via digital subtraction angiography and was defined as “a spinal branch of the segmental artery that supplied the anterior spinal artery extending to lumbar enlargement.” The segmental arteries, including the AoA, were bilaterally dissected at the pathological vertebral level and divided at the level of the nerve roots. Postoperative neurological ambulatory function was assessed using Frankel grade. In this study, 8 patients had 1 vertebra excised (1 pair of segmental arteries, including AoA), 3 had 2 vertebrae excised (2 pairs of segmental arteries, including AoA), and 4 had 3 vertebrae excised (3 pairs of segmental arteries, including AoA). There were zero cases of postoperative neurologic deterioration according to Frankel grade.

Fukui et al¹³ reported on a series of 32 patients with thoracoabdominal aortic aneurysms who were treated with thoracic endovascular aortic repair. All patients had their AoA visualized by computed tomography angiography prior to endovascular treatment and had their AoA occluded as a consequence of deployment of the stent graft across the segmental artery supplying the AoA. The total number of pairs of segmental arteries (including the AoA) occluded ranged from 3 to 12 pairs. Postprocedure paraplegia/paresis occurred in 2 (6.3%) of 32 patients, who had 8 and 10 pairs of segmental arteries inclusive of the AoA occluded by the stent graft, respectively. Of these 2 patients, 1 (with 10 segments occluded) remained paraplegic, while the other subsequently regained ambulatory status.

Salame et al²⁰ published a small case series investigating the safety of endovascular embolization for vertebral tumors using endovascular coils or onyx. Intraprocedural neurophysiological monitoring was used as an adjunct. Of the 5 patients in the study, 3 patients had their index pathology at the level of their AoA, resulting in AoA occlusion in these 3 patients. These 3 patients each had 3 pairs of segmental arteries inclusive of the AoA occluded. There were no electrophysiological changes (somatosensory-evoked potentials, transcranial-electric motor-evoked potentials) during temporary occlusion of the AoA. There were zero cases of postoperative neurological motor deterioration according to clinical examination.

From these 3 studies, the crude cumulative risk of postoperative neurological motor deficit, be it immediate or delayed, is 4.0% (2/50) when the AoA is occluded. This figure is influenced solely by the 2 patients with postprocedure neurological deficit in the article by Fukui et al.¹³ The current small body of level IV evidence in the literature will suggest a low risk of postoperative spinal cord injury after occlusion of the AoA together with its vicinity's SSA. Furthermore, occlusion of up to 7 pairs of SSAs, inclusive of the AoA, has not been found to cause spinal cord injury in the current literature.

Studies With Occlusion of Spinal Segmental Arteries (Without Knowledge of the Location of the AoA)

Eight articles met the inclusion criteria, 6 articles^{15-17,19,20,23} from the spinal surgical literature, and 2 articles^{21,22} from the vascular surgical literature. Only 2 studies^{19,21} had information on the exact vertebral levels where the SSAs were occluded. The remaining five studies had information on the range of SSAs occluded only.

Bilateral Spinal Segmental Artery Occlusion

Five articles^{15,17,21-23} had information on clinical outcomes after bilateral occlusion of contiguous SSAs. Table 2 summarizes the results from these 5 articles.

From the spinal literature, Murakami et al¹⁵ reviewed a series of 79 patients who underwent total en bloc spondylectomy for vertebral tumors. Patients had 1 to 3 bilateral segmental arteries ligated as part of their operation, and there was no postoperative neurological deficit as assessed by Frankel grade in all patients. Soubeyrand et al¹⁷ published a case series including a subset of 22 patients who had up to 5 levels of SSA ligation as part of total vertebrectomy surgery for various primary and secondary osseous pathology. One of these 22 patients, who had 5 bilateral SSAs ligated, suffered a postoperative motor deficit. Zhao et al²³ reported no postoperative neurological motor deficits in a series of 11 patients operated on for kyphoscoliosis. The patients in this study had between 1 and 3 pairs of SSAs ligated between the T6 to L1 vertebral level.

Table 2. Bilateral Spinal Segmental Artery Occlusion.

Author/Year (N)	Number/Range of Bilateral SSAs Occluded	Method Neurological Assessment	Crude Rate: Neurological Deficit (%)	Rate: Immediate Paraplegia (%)	Rate: Immediate Paraparesis (%)	Rate: Delayed Neurological Deficit (%)	Rate: Neurologic Recovery (%)
Etz/2006 (100)	2-15: n = 100	Clinical exam	2.0	1.0	0	1.0	0
Griep/1996 (93)	2-6: n = 36 7-10: n = 36 11-15: n = 21	Clinical exam	5.4	1.1	3.2	1.1	75
Murakami/2010 (79)	1-3: n = 79	Frankel	0	0	0	0	NA
Soubeyrand/2011 (22)	1-5: n = 22	Clinical exam	4.5	0	0	4.5	100
Zhao/2017 (11)	1: n = 3 2: n = 6 3: n = 2	Clinical exam	0	0	0	0	NA

Abbreviations: SSA, segmental spinal artery; NA, not applicable.

Table 3. Combined Analysis of 305 Patients with Bilateral Spinal Segmental Artery Occlusion.

Bilateral SSA Occlusion	N	Crude Rate: Neurological Deficit, % (n)	Rate: Immediate Paraplegia, % (n)	Rate: Immediate Paraparesis, % (n)	Rate: Delayed Neurological Deficit, % (n)	Rate: Neurologic Recovery, % (n)
1-6 pairs	176	0.6 (1)	0	0	0.6 (1)	100 (1)
>6 pairs	129	5.4 (7)	1.6 (2)	2.3 (3)	1.6 (2)	42.9 (3)

Abbreviation: SSA, segmental spinal artery.

From the vascular literature, Griep et al²² investigated the relationship between the number of SSAs sacrificed to postoperative paraplegia in thoracic and thoracoabdominal aortic aneurysms. There was a positive relationship between the number of bilateral SSAs sacrificed and the incidence of postoperative paraplegia/paresis. This study found an odds ratio of 29 of developing postoperative paraplegia when 10 or more pairs of SSAs was sacrificed, when compared with less than 10 pairs. Etz et al,²¹ in their case series of thoracic and thoracoabdominal aortic aneurysms, studied the impact of a policy of non-reimplantation of SSAs in open aortic aneurysm repairs. In this study, 2 of 100 patients developed postoperative paraplegia, one due to known intraoperative dissection and 6 hours of lower body ischemia, and the other due to a postoperative respiratory arrest requiring resuscitation. In this study, no patients with less than 9 bilateral SSAs ligated had paraplegia.

Results from the above 5 studies were combined for a total of 305 patients (Table 3). The crude risk of neurological deficit in patients with 1 to 6 pairs of SSAs ligated was 0.6% (n = 1), as compared with 5.4% (n = 7) when more than 6 pairs of SSAs were ligated (relative risk [RR] = 0.105, 95% CI 0.013-0.841, $P = .0337$). In terms of neurological recovery, there was a 42.9% rate of neurological recovery in patients with more than 6 pairs of SSAs ligated and who suffered from a postoperative neurological motor deficit.

Unilateral Spinal Segmental Artery Occlusion

Three articles^{16,17,19} had information on clinical outcomes after unilateral occlusion of contiguous SSAs. All 3 are from the spinal literature.

Soubeyrand et al¹⁷ published a case series including a subset of 75 patients who had 2 to 6 levels of hemivertebrectomy for various primary and secondary osseous pathology. One of these patients, who had 6 levels of unilateral SSA ligation, suffered postoperative paraplegia. Wu et al,¹⁹ in their case series of 31 patients with thoracic scoliosis, reported no cases of postoperative neurological deficits after anterior corrective surgery. All patients had 7 unilateral contiguous levels of SSAs (from T5 to T11) ligated 2 cm from the intervertebral foramen. Tsirikos et al¹⁶ reported on 346 patients who underwent anterior deformity correction. All patients had 6 to 9 unilateral contiguous SSAs ligated. There was 1 case of postoperative hemiparesis.

The data in the above 3 tables were unsuitable to be jointly analyzed. Table 4 shows the respective rates of neurological deficits for each study according to the range or number of unilateral SSAs ligated. For unilateral SSA ligation of 2 to 9 levels, the crude risk of postoperative neurological deficit does not exceed 1.3%.

Summary of Patients With Postoperative Neurological Deficit

From the 10 included studies, there was a total of 12 patients with postoperative motor neurological deficits when SSAs (with or without AoA) was occluded (Table 5). Three patients (25.0%) were from the spine literature, and the remaining 9 (75.0%) from the vascular literature. Four percent (9 of 225 patients) of all vascular patients and 0.5% (3 of 584 patients) of all spine patients had a motor neurological deficit after occlusion of SSAs with or without AoA occlusion.

Table 4. Unilateral Spinal Segmental Artery Occlusion

Author/Year	N	Number/Range of Unilateral SSAs Occluded	Crude Rate: Neurologic Deficit, %	Rate: Immediate Paraplegia, %	Rate: Immediate Paraparesis, %	Rate: Delayed Neurological Deficit, %	Rate: Neurologic recovery, %
Soubeyrand/2011	75	2-6	1.3 (n = 1)	1.3 (n = 1)	0	0	100
Wu/2006	31	7	0	0	0	0	—
Tsirikos/2008	346	6-9	0.3 (n = 1)	0	0.3 (n = 1)	0	0

Abbreviation: SSA, segmental spinal artery.

Study Quality and Risk of Bias Assessment

All included studies were retrospective case series, and thus were all of level IV evidence in accordance to Wright et al.¹¹ The overall body of evidence surrounding this topic of interest is thus of a low quality. Using the assessment tool by Cowley et al,¹² 2 articles^{14,15} were graded A (high quality), 1 study²³ graded B (moderate quality) and the remaining 7 studies graded C (poor quality). Cowley grade C studies most frequently had no systematic, defined criteria for measuring postoperative neurological outcomes. Tables 6 and 7 demonstrate the score and breakdown of the Cowley assessment tool with regard to the 10 included articles.

Discussion

The essence of this study lies in the arterial supply of the spinal cord, presence/degree of collateral and compensatory arterial supply, and susceptibility of the spinal cord to ischemic injury. Much is known regarding the traditional arterial supply of the spinal cord.²⁴ The lone anterior spinal artery, and paired posterior spinal arteries, run longitudinally around the spinal cord and supplies it via (1) a ring of vessels (vasa coronae) that surrounds the spinal cord and (2) penetrating arteries, for example, the anterior central sulcal artery and artery of the posterior median septum.² The anterior and posterior spinal arteries are augmented by multiple medullary arteries throughout the length of the spinal cord. The largest, and thus presumably most important, is the AoA. The AoA is described as a large medullary artery, that meets the anterior spinal artery via a hairpin turn and is usually found arising on the left side (in 80% of subjects)²⁵ from the levels of T9-L2 (in 85% of subjects).⁴ The AoA originates from the medial trunk of its parent spinal segmental artery, which in itself arises from its respective intercostal artery or lumbar artery directly from the descending aorta. Microanatomical cadaveric studies have found that the medial trunk (AoA) courses toward the intervertebral foramen and is found at the rostral and ventral aspect of the dorsal root ganglion–ventral root complex before it makes a rostral turn to pierce the nerve root sleeve to continue its course intradurally.²⁶ Most surgeons, where possible, prefer to ligate the SSA at a distance of 1 to 2 cm distal to the intervertebral foramen, so that any collateral supply to the medial trunk of the SSA will theoretically not be compromised. Studies have also found that there is no correlation between the diameter of AoA and the diameter of its parent SSA.²⁷

In human cadaveric studies, it has been found that ligation of SSAs result in a lower quantity and density of intramedullary blood vessels, with effects of bilateral ligation worse than unilateral ligation.²⁸ Physiologically, there exist anastomotic connections between the anterior spinal artery and posterior spinal artery, and also within the vasa coronae surrounding the spinal cord. More recently, the concept of a collateral network of spinal cord perfusion has emerged.²⁹ Etz et al³⁰ demonstrated, in Yorkshire pigs, the presence of multiple connections between the anterior spinal artery and epidural vessels. There was also extensive collateral supply of the intraspinal arterial network by the paraspinous muscular network supplied by the SSAs. In a separate study,³¹ ligation of all SSAs in Yorkshire pigs resulted in significant dynamic changes of this collateral perfusion network, including increased dimensions of the anterior spinal artery, epidural arterial collaterals, and paraspinous muscular collaterals within 1 to 5 days postligation. The vascular literature has advocated a 2-stage repair of thoracoabdominal aortic aneurysms³² to reduce the incidence of postoperative spinal cord injury, in part due to the theoretical recruitment of collateral circulation of the spinal cord between operative stages. Yuyama et al,³³ in a series of 3 patients whose AoA were ligated postspendylectomy for tumor, found no postoperative neurological deficits and the development of a “new” AoA within 2 months of surgery on digital subtraction angiography. In this regard, the article by Fukui et al¹³ (included in this review) is instructive. A total of 32 patients with thoracic and thoracoabdominal aortic aneurysms were treated with endovascular stent grafting, with coverage of the AoA by the stent graft. Computed tomography angiography of the spinal cord blood supply was performed before and at least 2 weeks after endovascular treatment. In 71.8% of these patients, the same AoA (ie, at the same spinal level) remained patent, with the AoA now fed by collateralization from a SSA distal to the site of the stent graft, or by the left subclavian artery or left external iliac artery. As such, focal occlusion (in this case at the origin of the SSA supplying the AoA) of the AoA or its parent SSA does not necessarily result in cessation of blood flow through that AoA. The authors are unaware of any study that has investigated the exact point of connection between the AoA and its collateral supply, but ligation of the AoA (or its parent SSA) at the proximal-most point, closest to its aortic origin, will theoretically allow any collateralization present to maintain flow into the AoA. However, the relevance, presence, and extent of the spinal cord collateral perfusion network with

Table 5. Summary of Patients With Neurological Deficits.

Age (Years)/ Gender	Patient	Type of Occlusion	Literature	Indication	Point of Occlusion	Location of AoA	Level	Number/ Laterality of SSA Occluded	Degree of Deficit
Unknown	Etz 1	Surgical, open aortic repair	Vascular, open	Thoracoabdominal aortic aneurysm	Not stated; presumed juxta-aortic	Unknown	T6-L2	9 pairs, bilateral	Paraplegia, permanent
Unknown	Etz 2	Surgical, open aortic repair	Vascular, open	Thoracoabdominal aortic aneurysm	Not stated; presumed juxta-aortic	Unknown	T3-L3	13 pairs, bilateral	Paraplegia, permanent
65/male	Fukui 1	Endovascular stent graft repair	Vascular, endovascular	Thoracoabdominal aortic aneurysm	At aortic origin (stent graft)	I	T3-T10	8 pairs, bilateral	Paraplegia, permanent
89/male	Fukui 2	Endovascular stent graft repair	Vascular, endovascular	Thoracoabdominal aortic aneurysm	At aortic origin (stent graft)	I	T3-T12	10 pairs, bilateral	Paraplegia, temporary, partial recovery
Unknown	Griep 1	Surgical, open aortic repair	Vascular, open	Thoracoabdominal aortic aneurysm	Not stated; presumed juxta-aortic	Unknown	NR	14 pairs, bilateral	Paraplegia, permanent
Unknown	Griep 2	Surgical, open aortic repair	Vascular, open	Thoracoabdominal aortic aneurysm	Not stated; presumed juxta-aortic	Unknown	NR	14 pairs, bilateral	Paraplegia, permanent
Unknown	Griep 3	Surgical, open aortic repair	Vascular, open	Thoracoabdominal aortic aneurysm	Not stated; presumed juxta-aortic	Unknown	NR	Between 8 and 14 pairs, bilateral	Paraparesis, temporary, full recovery
Unknown	Griep 4	Surgical, open aortic repair	Vascular, open	Thoracoabdominal aortic aneurysm	Not stated; presumed juxta-aortic	Unknown	NR	Between 8 and 14 pairs, bilateral	Paraparesis, temporary, full recovery
Unknown	Griep 5	Surgical, open aortic repair	Vascular, open	Thoracoabdominal aortic aneurysm	Not stated; presumed juxta-aortic	Unknown	NR	Between 8 and 14 pairs, bilateral	Paraparesis, temporary
72/female	Soubeyrand 1	Surgical, hemi-vertebrectomy	Spine	Chondrosarcoma	Not stated	0	NR	6, unilateral	Monoplegia, permanent
44/female	Soubeyrand 2	Surgical, total vertebrectomy	Spine	Chondrosarcoma	Not stated	0	T4-T8	5 pairs, bilateral	Paraplegia, temporary, full recovery
14/female	Tsirikos 1	Surgical, scoliosis correction, anterior approach	Spine	Congenital thoracic scoliosis	Mid-portion of vertebral body	Unknown	NR	7, unilateral	Monoplegia, permanent

Abbreviations: AoA, artery of Adamkiewicz; SSA, segmental spinal artery; NR, not recorded.

regard to spinal surgery requires further elucidation. Patients with degenerative vascular diseases (eg, aortic aneurysms) have multiple segments of intercostal and lumbar arteries chronically stenosed or occluded, and thus depend on recruitment of a rich collateral network for spinal cord blood supply.³⁴ The presence, extent, and rate of recruitment of a collateral perfusion network in the general population, or in the spinal

surgical patient, requires further investigation. The theoretical risk of spinal cord injury paradoxically exists for the nonvasculopathic patient without a reliable collateral spinal cord supply³⁵ requiring iatrogenic occlusion of their AoA or SSA.

The arterial supply of the spinal cord, as evidenced above, is robust and dynamic. Ligation of the AoA per se without its vicinity's SSAs, probably has a low risk of causing clinical

Table 6. Cowley Score and Individual Grading of Key Criteria.

Author/Year	Cowley Score ^a	Method of Selection of Patients Identified and Appropriate	Number of Patients Deceased or Lost to Follow-up Reported or Included in Appropriate Statistical Analysis	Follow-up Period, Range, and Mean Given	Prosthesis Models Specified	Clearly Defined Criteria for Measuring Outcomes
Etz/2006	C	+	+	—	NA	—
Griep/1996	C	+	+	—	NA	—
Murakami/2010	A	+	+	+	NA	+
Tsirikos/2008	C	+	+	—	NA	—
Murakami/2010	A	+	+	+	NA	+
Soubeyrand/2011	C	+	+	—	NA	—
Zhao/2017	B	+	+	+	NA	—
Salame/2016	C	+	+	—	NA	—
Wu/2006	C	+	+	—	NA	—
Fukui/2016	C	+	+	—	NA	—

Abbreviation: NA, not applicable.

^aCowley A—meets all key criteria, and at least half of the others; Cowley B—some uncertainty on one or more of key criteria, or fails to meet most of the other criteria; Cowley C—clearly fails to meet one or more of the key criteria, validity of results given were considered very doubtful.

postoperative spinal cord injury. Similarly, ligation of a limited number of SSAs can be safe as long as dynamic changes to spinal cord arterial perfusion keeps the spinal cord above the threshold for ischemic injury. Intraoperative neuromonitoring can aid in gauging this ischemic threshold, but its specificity in predicting postoperative clinical deficits is low and there is no firm consensus on its usefulness in terms of detecting spinal cord injury from a vascular aetiology.^{36,37}

Nonetheless, multiple individual case reports have reported development of postoperative weakness after ligation or occlusion of SSAs. Doita et al³⁸ reported a case of a patient who underwent T10 to T12 total spondylectomy for giant cell tumor. A preoperative angiogram was performed, but the AoA was unable to be detected. The T10 to T12 bilateral SSAs, and the left T8, T9, L1, L2 SSAs were ligated as part of a 2-stage thoracolumbar decompression and fusion procedure. The patient developed postoperative (after stage 2) lower limb paraplegia and incontinence theorized to be due to spinal cord ischemia and resultant anterior spinal artery syndrome. Kennedy et al³⁹ reported 2 cases of spinal cord injury with bilateral lower limb paralysis after particulate corticosteroid lumbar transforaminal injection. Magnetic resonance imaging for these patients were consistent with spinal cord infarction, with the presumed mechanism being inadvertent intra-arterial medullary artery (postulated to be the AoA) puncture and embolization with particulate corticosteroids. These cases more likely point to the low, but not negligible risk of spinal cord injury after perturbation of critical spinal cord arterial vasculature.

There was only 1 study¹⁴ from the spine literature that addressed the question of the effects of ligation of the AoA on the occurrence of postoperative neurological deficits. There were zero cases of neurological deterioration after surgery as assessed by Frankel grade. Despite the small number of patients in this series (n = 15), this study provides low level (level IV) but definitive proof-of-concept of the possibility to safely ligate 1 to 3 bilateral SSAs inclusive of the AoA.

Three studies^{13,14,20} had information on the effects of AoA occlusion with a crude postoperative motor neurological deficit rate of 4.0% (2 of 50 total patients). The number of bilateral SSAs occluded (including the AoA) in these 3 articles ranged from 1 to 12 pairs. The 2 patients who had a postoperative deficit were both from the endovascular surgical article of Fukui et al¹³ and had 8 and 10 pairs of SSAs occluded respectively. It will be unusual for this high number of bilateral SSAs to be required to be occluded in spine surgery. The current evidence available will suggest that occlusion of the AoA and limiting the number of its vicinity's SSAs that is concomitantly occluded, results in a low risk of postoperative motor neurological deficit. It should be noted that there are no studies or evidence available pertaining to outcomes when only the AoA per se (without contiguous SSAs) is occluded.

The crude risk of postoperative neurological motor deficit after bilateral SSA occlusion is 0.6% when 6 or less pairs of SSAs are occluded, and 5.4% when more than 6 pairs of SSAs are occluded. This is a statistically significant (RR = 0.105, *P* = .0337) result but should be interpreted with caution given the small and heterogenous number of studies included. Ideally, knowledge of the location of the AoA and segmental medullary arteries preoperatively may help refine the risk of postoperative spinal cord injury. However, in absence of this information, the authors recommend that ligation of SSAs be performed only when absolutely necessary. Ligation of up to 6 pairs of SSA carries a low but nonnegligible risk of devastating lower limb paralysis or paresis.

The proportion of vascular patients who had a neurological deficit is higher than that of spinal patients (4.0% vs 0.5%, respectively) when SSAs, with or without AoA is occluded. This is likely secondary to the different pathophysiology between vascular and spinal patients, the different surgical techniques employed, and the differences in the number of SSAs that has to be occluded as part of the procedure. Furthermore, it should be noted that the point of vascular occlusion in

Table 7. "Other Criteria" Components of Cowley Score.

Author/ Year	Valid Statistical Analyses	Data Given for Deceased Patients	Age Range and Mean Age Reported	Number of Men and Women Given	Weight Range and Mean Weight Given	Preoperative Diagnoses With % Of Patients Given	Clinical Evaluation Independent of Operating Surgeon	Radiologic Evaluation Independent and Blinded to Clinical Results	Results Given for Specific Models	Quantification of Outcomes	Follow-up Data Compared With Preoperative Data (Mean and Range)	Independence of Investigators (No Vested Interest) Stated
Etz/2006	+	+	+	+	-	+	+	NA	NA	+	+	-
Griepp/ 1996	+	+	+	+	-	+	+	NA	NA	+	+	-
Murakami/ 2010	+	+	-	-	-	+	+	NA	NA	+	+	+
Tsirikos/ 2008	+	+	+	-	-	+	+	NA	NA	+	+	+
Murakami/ 2010	+	-	+	+	-	+	+	NA	NA	+	+	+
Soubeyrand/ 2011	+	-	+	+	-	+	+	NA	NA	+	+	-
Zhao/2017	+	+	+	+	+	+	+	NA	NA	+	+	+
Salame/ 2016	+	+	+	+	-	+	+	NA	NA	+	+	+
Wu/2006	+	+	+	+	-	+	+	NA	NA	+	+	-
Fukui/2016	+	-	+	+	-	+	+	NA	NA	+	+	-

Abbreviation: NA, not applicable.

spinal and vascular surgery is different. In spine surgery, SSA occlusion is distal and generally 1 to 2 cm from the intervertebral foramen,⁵ while that in vascular surgery (endovascular or open) is proximal and at the aortic origin. The mechanism of spinal cord injury in both vascular and spinal patient also requires further consideration. The pathophysiology of spinal cord ischemia as a result of hypoperfusion is different from that of thromboembolism. In the latter, recruitment of collateral pathways can have minimal effect on spinal cord perfusion due to selective occlusion of end arteries.

In vascular surgery, the approach to reimplantation of SSA in the treatment of thoracic/thoracoabdominal aortic aneurysms is a well-researched field. Many of these articles were not included in this review as they did not meet the inclusion criteria. Nonetheless, they provide indirect evidence of the sacrificibility of the AoA and SSAs in spine surgery. Multiple studies have explored the impact of reimplantation of SSAs, or selective reimplantation of SSAs supplying the spinal cord (ie, AoA, medullary arteries) versus no reimplantation of SSAs⁴⁰⁻⁴³ in the mid thoracic to mid lumbar region (where the AoA normally is located). The preponderance of evidence demonstrates no significant benefit in selective, or complete reimplantation of SSAs in preventing postoperative spinal cord injury in thoracic/thoracoabdominal aortic aneurysm surgery. This provides indirect evidence of the potential ability to occlude long segments of bilateral SSAs (up to 15 pairs) including the AoA without precipitating spinal cord injury. Nonetheless, the analogy to spine surgery can only be taken so far, as patients with aortic aneurysms are a different pathology altogether with the point of ligation of SSA in these patients (near the aortic origin) being vastly different from that in spine surgery (approximately 1-2 cm from the intervertebral foramen).

Neuroprotective strategies employed in vascular surgery and traumatic spinal cord injury deserves special mention, as they use techniques to augment spinal cord perfusion that can be similarly employed in spine surgery. Intraoperative hypothermia has been consistently found to decrease the risk of spinal cord injury in aortic aneurysm surgery.^{44,45} This is due to the theoretical decrease in spinal cord metabolism and with attenuation of the cytotoxic and inflammatory processes. The spinal cord ischemic threshold is also lowered in hypothermia, with targets ranging from 15°C to 20°C used in vascular surgery.⁴⁶ These temperatures are likely inappropriate in spine surgery. If postoperative hypothermia is desired, the strategy of employing modest hypothermia (eg, 32°C to 34°C) for 48 hours postoperatively, is comparatively more feasible and has been found to potentially prevent further neurological deterioration in patients with traumatic spinal cord injury.⁴⁷ Spinal cord perfusion pressure (SCPP) is calculated as the difference between mean arterial pressure (MAP) and cerebrospinal fluid pressure (CSFP) [SCPP = MAP - CSFP]. Cerebrospinal fluid drainage via a lumbar drain is a well-recognized intervention in preventing and treating spinal cord injury after thoracoabdominal aortic aneurysm surgery, especially in the setting of delayed paraplegia.⁴⁸ In a randomized controlled trial by Coselli et al,⁴⁹ the authors demonstrated that cerebrospinal

fluid drainage commenced intraoperatively and continued for a period of 48 hours, with a CSFP target of 10 mm Hg or less, resulted in an 80% relative risk reduction in postoperative neurological deficits. Increases in SCPP can also be achieved via hemodynamic augmentation of the MAP. In vascular surgery, a protocol aiming for a postoperative MAP of more than 80 to 90 mm Hg, or a maintenance of the individual patient's preoperative MAP, is generally accepted.⁴⁸ This is akin to the traumatic spinal cord injury literature, where prospective level II studies have found that a MAP aim of more than 85 to 90 mm Hg for 5 to 7 days post injury being beneficial in maintaining or improving lost neurological function.⁵⁰

Strength and Limitations

The assessment tool by Cowley et al¹² is recommended to assess the internal validity of noncomparative studies.⁵¹ Risk of bias of the selected articles in this review is generally moderate to high as assessed by the Cowley grade. Grade C studies were mostly downgraded due to a lack of information on the period of follow-up and/or a lack of clearly defined criteria for measuring postoperative neurological function. Only the studies by Murakami et al^{14,15} formally graded postoperative function using the Frankel grade. All other studies included in this review implicitly relied on general bedside clinical examination for postoperative assessment. Validated measures of postoperative neurological function will aid in more nuanced interpretation of the effects of AoA and SSA occlusion. However, the information, as presented in the included articles, nonetheless enable an all-or-nothing (ie, presence vs absence of deficit) assessment and analyses of the effects of AoA and SSA ligation on incidence of postoperative deficit. The poor reporting of follow-up duration in the included studies is mitigated by the fact that neurological deficit is expected to occur during the perioperative period, thus partially obviating the need for long-term follow-up for the purposes of this review.

Besides the risk of bias of the included studies, other limitations of this review include the low level of evidence (level IV) of the individual studies. The search strategy was deliberately wide and to the authors' knowledge, there exists no randomized controlled trials, or even prospective comparative studies on this topic. While randomized controlled trials will be extremely difficult to conduct in this area, the recommendations in this review nonetheless serve as a useful starting point for future high-quality prospective comparative studies in this field of spinal surgery.

Conclusion

The current best evidence (low level) indicate that occlusion of the AoA, and occlusion of up to 6 pairs of its vicinity's SSA (without knowledge of the location of the AoA), is associated with a low risk of postoperative neurological deficits. The limited number of included studies and moderate- to poor-quality evidence restricts the ability to draw definitive conclusions regarding the impact of sacrificing the AoA and SSAs. Ligation

of AoA and SSAs should only be undertaken when absolutely required to mitigate the small but devastating risk of paralysis. Further studies are required to understand the vascular tolerance of the spinal cord as new surgical techniques enable more extensive surgical procedures.


Declaration of Conflicting Interests


The author(s) declared no potential conflicts of interest with respect to the research, authorship, and/or publication of this article.

Funding

The author(s) received no financial support for the research, authorship, and/or publication of this article.

ORCID iD

Terence Tan, MBBS  <https://orcid.org/0000-0003-2145-0214>

Joost Rutges, MD, PhD  <https://orcid.org/0000-0002-9452-415X>

References

- Romanes GJ. The arterial blood supply of the human spinal cord. *Paraplegia*. 1965;2:199-207.
- Sliwa JA, Maclean IC. Ischemic myelopathy: a review of spinal vasculature and related clinical syndromes. *Arch Phys Med Rehabil*. 1992;73:365-372.
- Skalski JH, Zembala M. Albert Wojciech Adamkiewicz: the discoverer of the variable vascularity of the spinal cord. *Ann Thorac Surg*. 2005;80:1971-1975.
- Lazorthes G, Gouaze A, Zadeh JO, Santini JJ, Lazorthes Y, Burdin P. Arterial vascularization of the spinal cord. Recent studies of the anastomotic substitution pathways. *J Neurosurg*. 1971;35:253-262.
- Tomita K, Kawahara N, Murakami H, Demura S. Total en bloc spondylectomy for spinal tumors: improvement of the technique and its associated basic background. *J Orthop Sci*. 2006;11:3-12.
- Lenke LG, Sides BA, Koester LA, Hensley M, Blanke KM. Vertebral column resection for the treatment of severe spinal deformity. *Clin Orthop Relat Res*. 2010;468:687-699.
- Ueda Y, Kawahara N, Tomita K, Kobayashi T, Murakami H, Nambu K. Influence on spinal cord blood flow and function by interruption of bilateral segmental arteries at up to three levels: experimental study in dogs. *Spine (Phila Pa 1976)*. 2005;30:2239-2243.
- Kato S, Kawahara N, Tomita K, Murakami H, Demura S, Fujimaki Y. Effects on spinal cord blood flow and neurologic function secondary to interruption of bilateral segmental arteries which supply the artery of Adamkiewicz: an experimental study using a dog model. *Spine (Phila Pa 1976)*. 2008;33:1533-1541.
- Fujimaki Y, Kawahara N, Tomita K, Murakami H, Ueda Y. How many ligations of bilateral segmental arteries cause ischemic spinal cord dysfunction? An experimental study using a dog model. *Spine (Phila Pa 1976)*. 2006;31:E781-E789.
- Liberati A, Altman DG, Tetzlaff J, et al. The PRISMA statement for reporting systematic reviews and meta-analyses of studies that evaluate health care interventions: explanation and elaboration. *J Clin Epidemiol*. 2009;62:e1-34.
- Wright JG, Swiontkowski MF, Heckman JD. Introducing levels of evidence to the journal. *J Bone Joint Surg Am*. 2003;85-A:1-3.
- Cowley DE. Prostheses for primary total hip replacement. A critical appraisal of the literature. *Int J Technol Assess Health Care*. 1995;11:770-778.
- Fukui S, Tanaka H, Kobayashi K, et al. Development of collaterals to the spinal cord after endovascular stent graft repair of thoracic aneurysms. *Eur J Vasc Endovasc Surg*. 2016;52:801-807.
- Murakami H, Kawahara N, Tomita K, Demura S, Kato S, Yoshioka K. Does interruption of the artery of Adamkiewicz during total en bloc spondylectomy affect neurologic function? *Spine (Phila Pa 1976)*. 2010;35:E1187-E1192.
- Murakami H, Kawahara N, Demura S, Kato S, Yoshioka K, Tomita K. Neurological function after total en bloc spondylectomy for thoracic spinal tumors Clinical article. *J Neurosurg Spine*. 2010;12:253-256.
- Tsirikos AI, Howitt SP, McMaster MJ. Segmental vessel ligation in patients undergoing surgery for anterior spinal deformity. *J Bone Joint Surg Br*. 2008;90:474-479.
- Soubeyrand M, Court C, Fadel E, et al. Preoperative imaging study of the spinal cord vascularization: interest and limits in spine resection for primary tumors. *Eur J Radiol*. 2011;77:26-33.
- Zhao QH, Tian JW, Wang L, et al. Posterior fusion versus posterior interbody fusion in segmental spinal fixation for aged spondylolisthesis [in Chinese]. *Zhonghua Yi Xue Za Zhi*. 2009;89:1779-1782.
- Wu L, Qiu Y, Ling W, Shen Q. Change pattern of somatosensory-evoked potentials after occlusion of segmental vessels: possible indicator for spinal cord ischemia. *Eur Spine J*. 2006;15:335-340.
- Salame K, Maimon S, Regev GJ, et al. Electrophysiological monitoring during preoperative angiography to guide decisions regarding permanent occlusion of major radicular arteries in patients undergoing total en bloc spondylectomy. *Neurosurg Focus*. 2016;41:E19.
- Etz CD, Halstead JC, Spielvogel D, et al. Thoracic and thoracoabdominal aneurysm repair: is reimplantation of spinal cord arteries a waste of time? *Ann Thorac Surg*. 2006;82:1670-1677.
- Griep RB, Ergin MA, Galla JD, et al. Looking for the artery of Adamkiewicz: a quest to minimize paraplegia after operations for aneurysms of the descending thoracic and thoracoabdominal aorta. *J Thorac Cardiovasc Surg*. 1996;112:1202-1213.
- Zhao Z, Xie JM, Wang YS, et al. The effect from different numbers of segmental arteries ligation to the spinal cord in the clinical practice of posterior vertebral column resection correction. *Eur Spine J*. 2017;26:1937-1944.
- Colman MW, Hornicek FJ, Schwab JH. Spinal cord blood supply and its surgical implications. *J Am Acad Orthop Surg*. 2015;23:581-591.
- Biglioli P, Roberto M, Cannata A, et al. Upper and lower spinal cord blood supply: the continuity of the anterior spinal artery and the relevance of the lumbar arteries. *J Thorac Cardiovasc Surg*. 2004;127:1188-1192.
- Alleyne CH Jr, Cawley CM, Shengelaia GG, Barrow DL. Microsurgical anatomy of the artery of Adamkiewicz and its segmental artery. *J Neurosurg*. 1998;89:791-795.

27. Koshino T, Murakami G, Morishita K, Mawatari T, Abe T. Does the Adamkiewicz artery originate from the larger segmental arteries? *J Thorac Cardiovasc Surg.* 1999;117:898-905.
28. Yuan L, Ni GX, Luk KK, et al. Effect of segmental artery ligation on the blood supply of the thoracic spinal cord during anterior spinal surgery: a quantitative histomorphological fresh cadaver study. *Spine (Phila Pa 1976).* 2005;30:483-486.
29. Griep EB, Di Luozzo G, Schray D, Stefanovic A, Geisbüsch S, Griep RB. The anatomy of the spinal cord collateral circulation. *Ann Cardiothorac Surg.* 2012;1:350-357.
30. Etz CD, Kari FA, Mueller CS, et al. The collateral network concept: a reassessment of the anatomy of spinal cord perfusion. *J Thorac Cardiovasc Surg.* 2011;141:1020-1028.
31. Etz CD, Kari FA, Mueller CS, Brenner RM, Lin HM, Griep RB. The collateral network concept: remodeling of the arterial collateral network after experimental segmental artery sacrifice. *J Thorac Cardiovasc Surg.* 2011;141:1029-1036.
32. O'Callaghan A, Mastracci TM, Eagleton MJ. Staged endovascular repair of thoracoabdominal aortic aneurysms limits incidence and severity of spinal cord ischemia. *J Vasc Surg.* 2015;61:347-354.e1.
33. Yuyama T, Ri M, Dezawa A, Kamada S. A study of spinal cord blood flow after ligation of segmental artery that Adamkiewicz artery diverges from [in Japanese]. *Kanto J Orthop Trauma.* 1986;17:356-358.
34. Jacobs MJ, de Mol BA, Elenbaas T, et al. Spinal cord blood supply in patients with thoracoabdominal aortic aneurysms. *J Vasc Surg.* 2002;35:30-37.
35. von Oppell UO, Dunne TT, De Groot KM, Zilla P. Spinal cord protection in the absence of collateral circulation: meta-analysis of mortality and paraplegia. *J Card Surg.* 1994;9:685-691.
36. Guerit JM, Dion RA. State-of-the-art of neuromonitoring for prevention of immediate and delayed paraplegia in thoracic and thoracoabdominal aorta surgery. *Ann Thorac Surg.* 2002;74:S1867-S1869.
37. Leung YL, Grevitt M, Henderson L, Smith J. Cord monitoring changes and segmental vessel ligation in the "at risk" cord during anterior spinal deformity surgery. *Spine (Phila Pa 1976).* 2005;30:1870-1874.
38. Doita M, Marui T, Nishida K, Kurosaka M, Yoshiya S, Sha N. Anterior spinal artery syndrome after total spondylectomy of T10, T11, and T12. *Clin Orthop Relat Res.* 2002;(405):175-181.
39. Kennedy DJ, Dreyfuss P, Aprill CN, Bogduk N. Paraplegia following image-guided transforaminal lumbar spine epidural steroid injection: two case reports. *Pain Med.* 2009;10:1389-1394.
40. Kawaharada N, Morishita K, Fukada J, et al. Thoracoabdominal or descending aortic aneurysm repair after preoperative demonstration of the Adamkiewicz artery by magnetic resonance angiography. *Eur J Cardiothorac Surg.* 2002;21:970-974.
41. Acher CW, Wynn MM, Mell MW, Tefera G, Hoch JR. A quantitative assessment of the impact of intercostal artery reimplantation on paralysis risk in thoracoabdominal aortic aneurysm repair. *Ann Surg.* 2008;248:529-540.
42. Wynn M, Acher C, Marks E, Acher CW. The effect of intercostal artery reimplantation on spinal cord injury in thoracoabdominal aortic aneurysm surgery. *J Vasc Surg.* 2016;64:289-296.
43. Tanaka H, Ogino H, Minatoya K, et al; Japanese Study of Spinal Cord Protection in Descending and Thoracoabdominal Aortic Repair investigators. The impact of preoperative identification of the Adamkiewicz artery on descending and thoracoabdominal aortic repair. *J Thorac Cardiovasc Surg.* 2016;151:122-128.
44. Kieffer E, Koskas F, Walden R, et al. Hypothermic circulatory arrest for thoracic aneurysmectomy through left-sided thoractomy. *J Vasc Surg.* 1994;19:457-464.
45. Kouchoukos NT, Rokkas CK. Hypothermic cardiopulmonary bypass for spinal cord protection: Rationale and clinical results. *Ann Thorac Surg.* 1999;67:1940-1942.
46. Griep RB, Griep EB. Spinal cord protection in surgical and endovascular repair of thoracoabdominal aortic disease. *J Thorac Cardiovasc Surg.* 2015;149(2 suppl):S86-S90.
47. Ahmad FU, Wang MY, Levi AD. Hypothermia for acute spinal cord injury—a review. *World Neurosurg.* 2014;82:207-214.
48. Etz CD, Weigang E, Hartert M, et al. Contemporary spinal cord protection during thoracic and thoracoabdominal aortic surgery and endovascular aortic repair: a position paper of the vascular domain of the European Association for Cardio-Thoracic Surgery. *Eur J Cardiothorac Surg.* 2015;47:943-957.
49. Coselli JS, LeMaire SA, Koksoy C, Schmittling ZC, Curling PE. Cerebrospinal fluid drainage reduces paraplegia after thoracoabdominal aortic aneurysm repair: results of a randomized clinical trial. *J Vasc Surg.* 2002;35:631-639.
50. Saadeh YS, Smith BW, Joseph JR, et al. The impact of blood pressure management after spinal cord injury: a systematic review of the literature. *Neurosurg Focus.* 2017;43:E20.
51. Deeks JJ, Dinnes J, D'Amico R, et al. Evaluating non-randomised intervention studies. *Health Technol Assess.* 2003;7:iii-x,1-173.