

University of Nebraska - Lincoln

DigitalCommons@University of Nebraska - Lincoln

Publications from USDA-ARS / UNL Faculty

U.S. Department of Agriculture: Agricultural
Research Service, Lincoln, Nebraska

2-19-2018

Sarcocystis cymruensis: discovery in Western Hemisphere in the Brown rat (*Rattus norvegicus*) from Grenada, West Indies: redescription, molecular characterization, and transmission to IFN- γ gene knockout mice via sporocysts from experimentally infected domestic cat (*Felis catus*)

Fernando H. Antunes Murata

Beltsville Agricultural Research Center, Beltsville

Camila K. Cerqueira-Cézar

Beltsville Agricultural Research Center, Beltsville

Peter C. Thompson

Beltsville Agricultural Research Center, Beltsville

Keshaw Tiwari

St. George's University, St. George's

Joseph D. Mowery

Follow this and additional works at: <https://digitalcommons.unl.edu/usdaarsfacpub>
Beltsville Agricultural Research Center, Building 12, Beltsville

Antunes Murata, Fernando H.; Cerqueira-Cézar, Camila K.; Thompson, Peter C.; Tiwari, Keshaw; Mowery, Joseph D.; Verma, Shiv K.; Rosenthal, Benjamin M.; Sharma, Ravindra N.; and Dubey, J. P., "Sarcocystis cymruensis: discovery in Western Hemisphere in the Brown rat (*Rattus norvegicus*) from Grenada, West Indies: redescription, molecular characterization, and transmission to IFN- γ gene knockout mice via sporocysts from experimentally infected domestic cat (*Felis catus*)" (2018). *Publications from USDA-ARS / UNL Faculty*. 2224.

<https://digitalcommons.unl.edu/usdaarsfacpub/2224>

This Article is brought to you for free and open access by the U.S. Department of Agriculture: Agricultural Research Service, Lincoln, Nebraska at DigitalCommons@University of Nebraska - Lincoln. It has been accepted for inclusion in Publications from USDA-ARS / UNL Faculty by an authorized administrator of DigitalCommons@University of Nebraska - Lincoln.

Authors

Fernando H. Antunes Murata, Camila K. Cerqueira-Cézar, Peter C. Thompson, Keshaw Tiwari, Joseph D. Mowery, Shiv K. Verma, Benjamin M. Rosenthal, Ravindra N. Sharma, and J. P. Dubey



Sarcocystis cymruensis: discovery in Western Hemisphere in the Brown rat (*Rattus norvegicus*) from Grenada, West Indies: redescription, molecular characterization, and transmission to IFN- γ gene knockout mice via sporocysts from experimentally infected domestic cat (*Felis catus*)

Fernando H. Antunes Murata¹ · Camila K. Cerqueira-Cézar¹ · Peter C. Thompson¹ · Keshaw Tiwari² · Joseph D. Mowery³ · Shiv K. Verma¹ · Benjamin M. Rosenthal¹ · Ravindra N. Sharma² · Jitender P. Dubey¹

Received: 6 December 2017 / Accepted: 31 January 2018 / Published online: 19 February 2018

© This is a U.S. Government work and not under copyright protection in the US; foreign copyright protection may apply 2018

Abstract

Rodents are intermediate hosts for many species of *Sarcocystis*. Little is known of *Sarcocystis cymruensis* that uses the Brown rat (*Rattus norvegicus*) as intermediate hosts and the domestic cat (*Felis catus*) as experimental definitive host. Here, we identified and described *Sarcocystis cymruensis* in naturally infected *R. norvegicus* from Grenada, West Indies. Rats ($n = 167$) were trapped in various locations in two parishes (St. George and St. David). Microscopic, thin ($< 1 \mu\text{m}$) walled, slender sarcocysts were found in 11 of 156 (7.0%) rats skeletal muscles by squash examination. A laboratory-raised cat fed naturally infected rat tissues excreted sporocysts that were infectious for interferon gamma gene knockout (KO) mice, but not to Swiss Webster outbred albino mice. All inoculated mice remained asymptomatic, and microscopic *S. cymruensis*-like sarcocysts were found in the muscles of KO mice euthanized on day 70, 116, and 189 post inoculation (p.i.). Sarcocysts from infected KO mice were infective for cats at day 116 but not at 70 days p.i. By transmission electron microscopy, the sarcocyst wall was “type 1a.” Detailed morphological description of the cyst wall, merozoites, and bradyzoites is given for the first time. Additionally, molecular data on *S. cymruensis* are presented also for the first time. Molecular characterization of sarcocysts *18S rDNA* and *28S rDNA*, *ITS-1*, and *cox1* loci showed the highest similarity with *S. rodentifelis* and *S. muris*. In conclusion, the present study described the natural infection of *S. cymruensis* in Brown rat for the first time in a Caribbean country and provided its molecular characteristics.

Keywords *Sarcocystis cymruensis* · *Rattus norvegicus* · Grenada · Ultrastructure · Phylogeny

Introduction

Sarcocystis species have worldwide distribution. Some species of *Sarcocystis* are pathogenic to humans and animals, and

some are zoonotic. Most *Sarcocystis* species are host-specific but some have a wide host range. Rodents, especially immunosuppressed, have been used to study biology of *Sarcocystis*. The Brown rat (*Rattus norvegicus*) is an intermediate host for seven or more *Sarcocystis* species; *S. cymruensis*, *S. murinotrichis*, *S. singaporensis*, *S. villivillosi*, *S. zuoi*, *S. zamani*, and *S. dispersa*-like (Dubey et al. 2016). Of these, *S. cymruensis* and *S. singaporensis* are of biologic interest. With respect to *S. cymruensis*, its life cycle can be easily completed in the laboratory because domestic cat (*Felis catus*) is its definitive host and it has been reported that rats can act as both the intermediate and definitive host (Hu et al. 2011). For *S. singaporensis*, python (*Python reticulatus*) is the definitive host and it is highly pathogenic for the rat but host-specific. Thus,

✉ Jitender P. Dubey
jitender.dubey@ars.usda.gov

¹ United States Department of Agriculture, Agricultural Research Service, Animal Parasitic Diseases Laboratory, Beltsville Agricultural Research Center, Beltsville, MD 20705-2350, USA

² Pathobiology Department, School of Veterinary Medicine, St. George's University, St. George's, West Indies, Grenada

³ United States Department of Agriculture, Agricultural Research Service, Electron and Confocal Microscopy Unit, Beltsville Agricultural Research Center, Building 12, Beltsville, MD 20705-2350, USA

feed intentionally contaminated with *S. singaporensis* sporocysts has been proposed as a biological control for rats (Jäkel et al. 1996).

Sarcocystis cymruensis was named and described from the Brown rat (*Rattus norvegicus*) from the UK and sarcocysts were found in 36 (17.5%) of 205 rats (Ashford 1978). Domestic cats fed naturally infected rat muscle excreted sporocysts; dogs and ferrets fed tissue did not excrete sporocysts. *Rattus norvegicus* became infected when fed sporocysts from experimentally infected cats, sarcocysts, sarcocysts became grossly visible 6-month post inoculation (p.i.). The parasite was not transmissible to laboratory-raised house mice (*Mus musculus*) (Ashford 1978). Jäkel et al. (1997) reported *S. cymruensis* sarcocysts in six of nine *R. norvegicus* in Thailand. Jäkel et al. (1996) mentioned that one Brown rat and two Roof rats (*Rattus rattus frugivorus*) were naturally infected with *S. cymruensis*; these rats were caught in Egypt and were used for experimental infection with *S. singaporensis* in Germany.

Hu et al. (2011) discovered *S. cymruensis* sarcocysts in 22 (11.6%) of 198 wild rats (*Rattus* sp.) from China. Domestic cats fed naturally infected rat tissues excreted sporocysts. Sporocysts from cats were infective to *R. norvegicus* but not the outbred *M. musculus*. Additionally, sporocysts were detected in the lamina propria of small intestines of *R. norvegicus* fed sarcocysts from experimentally infected rats.

A new species of *Sarcocystis*, *Sarcocystis rodentifelis*, was described from Russia with a broad host range and unusual life cycle (Griekienienė et al. 1993). The Norway rat was the type intermediate host; bank vole (*Clethrionomys glareolus*), and the laboratory-raised house mouse (*Mus musculus*) acted as additional intermediate hosts. The laboratory rat acted both as the intermediate and definitive host (Griekienienė et al. 1993; Griekienienė and Kutkienė 1998). Rats fed sarcocysts excreted numerous sporocysts in feces (Griekienienė and Kutkienė 1998). Additionally, the domestic cat also acted as definitive host and *S. rodentifelis* could be transmitted transplacentally in rats (Griekienienė et al. 1993). Morphologically, *S. rodentifelis* was indistinguishable from *S. muris* and *S. cymruensis* (Griekienienė et al. 1993). Based on unusual characteristics, the authors proposed a subgenus *Levitia* for *S. rodentifelis* (Griekienienė et al. 1993).

The objective of the present paper is to document natural infection of *S. cymruensis* in Brown rats from Grenada, describe morphological and molecular characteristics, and experimental transmission.

Material and methods

Sample collection

As part of an epidemiological study of rodent pathogens, from February to July 2017, 167 rats (78 females, 89 males) were

caught using live traps (45 cm L × 15 cm w × 15 cm h) with cheese and/or various local fruits as bait. Rats were trapped in various locations in two parishes (St. George and St. David) which were densely populated compared to four remaining parishes. Attempts were made to trap the rats near residential buildings. Traps were placed in the evening and visited next morning. Traps with rats were covered with black cloth and transported to the necropsy laboratory of the St. George's University School of Veterinary Medicine and euthanized using isoflurane, and necropsied.

Samples from heart and limb muscle from 167 rats were shipped on ice by overnight delivery to the United States Department of Agriculture (USDA), Animal Parasitic Diseases Laboratory (APDL) in Beltsville, MD, USA, for protozoal testing, including *Toxoplasma gondii* (to be reported separately). The rats were received at APDL in 17 batches of 6, 3, 2, 4, 10, 5, 11, 13, 7, 14, 24, 8, 13, 11, 13, 16, and 7 samples storage in individual bags. Two to 4 days elapsed between euthanasia and receipt at APDL.

Testing of rat muscle for *Sarcocystis*

Samples were examined by muscle squash, pepsin digestion, histology, bioassay, transmission electron microscopy (TEM), and DNA sequencing. For muscle squashes, 1–3 mm of muscle from leg of 156 rats and myocardium of 167 rats were pressed between a slide and coverslip, and examined microscopically at 100–400 × magnification. For pepsin digestion, tissues (165 hearts, 154 muscles) were pooled in batches of two to ten rats (total pools 29, homogenized in saline (aqueous 0.9% NaCl), incubated in acid pepsin solution for 1 h at 37 °C in a water bath, and examined for bradyzoites of cyst forming coccidian as described previously for *T. gondii* (Dubey 2010). In this process, protozoan bradyzoites are released as soon as the cyst wall is in contact with pepsin and bradyzoites can survive in the digest for several hours. The pepsin product was filtered, centrifuged, and suspended in saline, and a drop (0.1 ml) of the digest was spread on a slide, covered with a coverslip, and examined microscopically for bradyzoites.

For TEM, six sarcocysts were teased out of muscle at APDL, fixed in 2.5% buffered glutaraldehyde and processed as described previously (Trupkiewicz et al. 2016).

Bioassay of *Sarcocystis* in cats

For bioassay in cats, five parasite-free (14–34 weeks old) cats from the USDA cat colony were used to obtain sporocysts; management of the cat colony has been described previously (Dubey 1995). Feces were collected daily and examined for *Sarcocystis* sporocysts as described (Verma et al. 2017a). Cats were euthanized between day seven to 13 p.i. The entire small intestine from each animal was removed, slit open, mucosa

scraped, homogenized in water, and examined microscopically for sporocysts as described (Dubey et al. 2016).

Bioassay of *Sarcocystis* in mice

For murine bioassay, outbred albino Swiss Webster (SW) and interferon gamma gene knockout (KO) mice were used. Two SW and four KO mice were orally inoculated with sporocysts from a cat that had been fed muscle from two naturally infected rats. The number of sporocysts given to mice was unknown (< 1000) because the cat had excreted only a few sporocysts. Two SW and two KO mice were euthanized day 70 p.i., one KO mouse was euthanized day 116 p.i., and one KO mouse was euthanized day 189 p.i.; multiple samples of muscle were squeezed between the slide and coverslip and examined for the presence of *Sarcocystis* sarcocysts. Samples of muscle, heart, tongue, lung, liver, eye, spleen, kidney, brain, and intestine of all mice were fixed in 10% buffered formalin, and processed for histology. Sections were cut 5- μ m thick and examined microscopically after staining with hematoxylin and eosin (HE). Additionally, carcasses of mice were homogenized and digested in pepsin. The product of digestion was smeared on a slide, fixed in methanol and stained with Giemsa, and examined microscopically for bradyzoites.

Bradyzoites released from sarcocysts deriving from the KO mouse euthanized day 116 p.i. were fed to two KO mice. For this, a piece of muscle from the KO mouse was smashed and digested in pepsin for 5 min to release bradyzoites from sarcocysts. The pepsin digest was neutralized with 3% NaOH, centrifuged, and orally inoculated into two KO mice; more than 100,000 bradyzoites were ascertained in the inocula. These two KO mice were euthanized day 6 p.i. and sections of small intestine were fixed in 10% buffered formalin. The remaining small intestine was homogenized in 50 ml of distilled water, shaken for 1 h to lyse the intestinal epithelial cells, centrifuged, and suspended in distilled water, and a drop (0.1 ml) was spread on a slide, covered with a coverslip and examined microscopically for sporocysts.

The KO mouse euthanized day 189 p.i. was heavily infected with sarcocysts. After fixing samples of internal organs, pieces of gastrocnemius muscle with hundreds of sarcocysts were chopped with scissors and saved for feeding to KO mice. After removing viscera and skin, the carcass was homogenized in blender with saline, incubated in acid pepsin at 37 °C for 15 min, neutralized with 3% NaOH and Hanks Balanced Salt Solution (HBSS), centrifuged, and suspended in 3 ml of HBSS. After counting bradyzoites, the suspension of bradyzoites (15 million per mouse) was orally inoculated into four KO mice. Additionally, the same four KO mice were fed on heavily infected mouse muscle. For this, the finely chopped muscle was left in Petri dish in the mouse cage; the mice ate all infected muscle. These four KO mice were euthanized on days 1–6; one on day 1 p.i., one on day 4 p.i., and two

on day 6 p.i. For the mice euthanized day 1 and 4 p.i., the entire small intestine was cut in to small pieces and fixed in formalin, and paraffin-embedded sections were examined after staining with HE. From the two KO mice euthanized day 6 p.i., after removing 1-cm piece for histology, the remaining small intestines from both mice were pooled, homogenized in 50 ml of distilled water in a blender, shaken for 1 h at 37 °C, centrifuged, and suspended in 5 ml water, and a drop of it was spread on a slide for microscopic examination. Because we did not find *Sarcocystis* sporocysts, the homogenate was further digested in a bleach solution (6.0% sodium hypochlorite) for 10 min to dissolve most of the host tissue, centrifuged with water, and a drop (0.1 ml) of the final 1 ml suspension of the pellet was examined microscopically for sporocysts.

Molecular characterization

Sarcocysts excised from two naturally infected rats were individually placed in 20 μ l of saline (0.85%) and frozen at –20 °C until DNA was isolated.

Genomic DNA was extracted using the DNeasy Blood and Tissue Kit (Qiagen Inc., Valencia, CA, USA) according to manufacturer's instructions. Nuclear ribosomal DNA (*18S rDNA*, *28S rDNA*, and *ITS-1*) and mitochondrial cytochrome c oxidase subunit 1 (*cox1*) were amplified by PCR using previously published primers as described (Gjerde 2013; Gjerde 2014; Gjerde and Josefsen 2015). Each locus was amplified independently using 3- μ l template, 1 μ l of forward and reverse primers (20 mM final concentration), 12.5 μ l of Taq PCR Master Mix (Qiagen, USA), and 8.5 μ l of distilled water. Following an initial denaturation step of 5 min at 95 °C, 40 cycles of PCR were conducted for all reactions with the following cycling conditions (95 °C for 45 s, 56.5 °C for 45 s, and 72 °C for 1 min), ending with 10 min at 72 °C for final extension. Excess primers and nucleotides were removed using ExoSap-It (Thermo Fisher Scientific, USA) according to manufacturer's instructions, then PCR fragments were sequenced using original amplification primers and BigDye Terminator v3.1 cycle sequencing chemistry (Applied Biosystems, Foster City, CA, USA). Sequencing products were analyzed on an ABI 3730 Sequencer.

Sequencing chromatograms were examined in Geneious R10.2.3 (Biomatters Limited, New Zealand), and consensus sequences for each sample were generated only from areas where both forward and reverse sequencing were present. Consensus sequences were then compared to other *Sarcocystis* sequences deposited in GenBank (<https://www.ncbi.nlm.nih.gov/genbank>).

In order to establish phylogenetic relationships between *Sarcocystis* species, sequences were aligned using the Geneious v.10.2.3 MUSCLE plug-in and neighbor-joining trees were built with the HKY substitution model in the Geneious v.10.2.3 Tree Builder. Consensus trees were constructed from

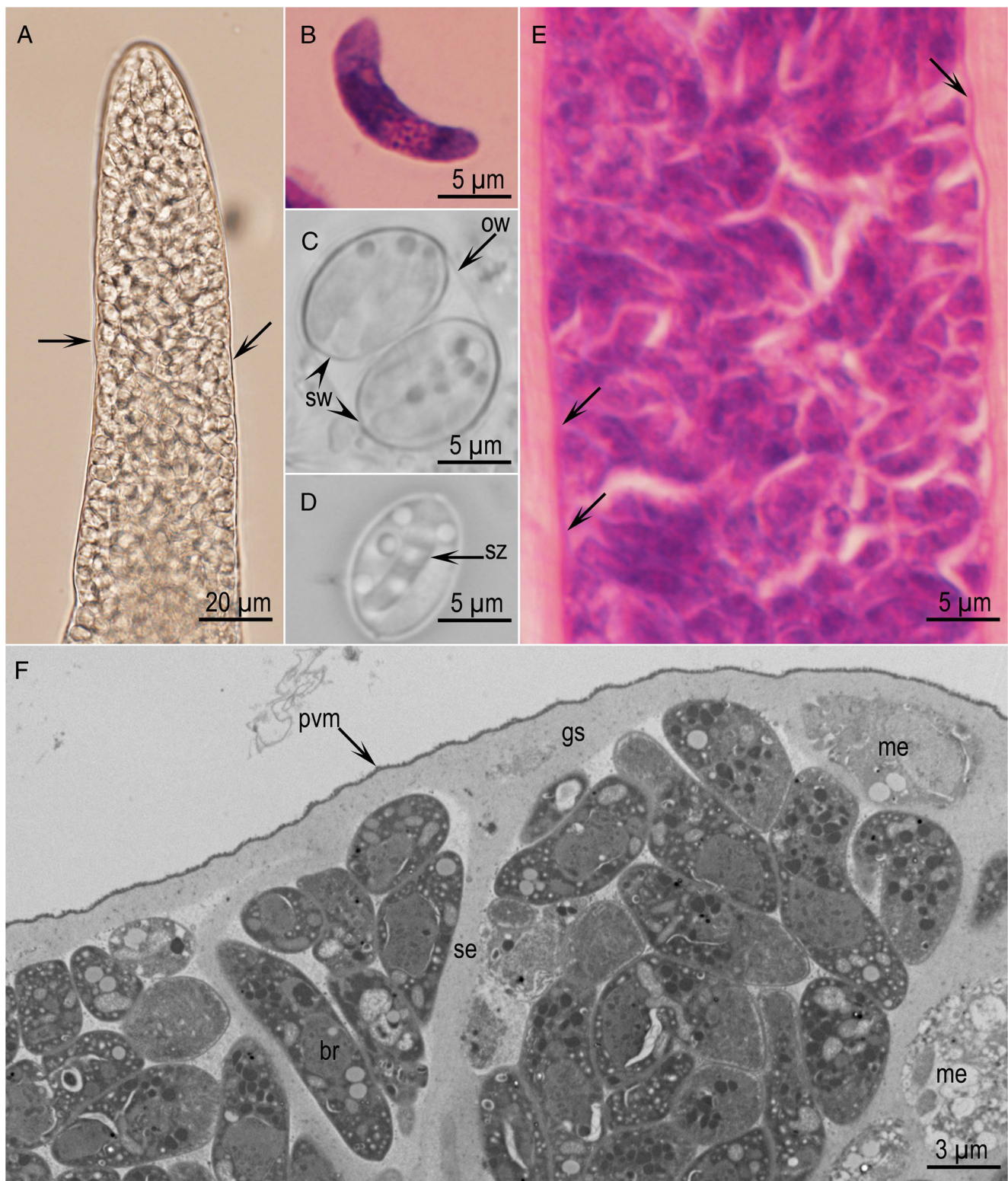


Fig. 1 *Sarcocystis cymruensis* stages. **a** Part of sarcocyst from leg muscle of a naturally infected rat #7. The sarcocyst wall is thin (arrows) and encloses bradyzoites. Unstained. **b** Bradyzoite in pepsin digest of muscle. Giemsa stain. **c** Sporulated oocyst with a thin oocyst wall (ow), enclosing two sporozoites with prominent walls (sw). Unstained. **d** Sporozoite containing

sporozoites (sz). Unstained. **e** Longitudinal section of a sarcocyst in skeletal muscle of KO mouse, 70 days p.i. Note thin sarcocyst wall (arrows). Hematoxylin and eosin stain. **f** TEM of a part of sarcocyst wall. Note thin parasitophorous vacuolar membrane (pvm), smooth ground substance layer (gs), thick septa (se), metrocytes (me), and bradyzoites (br). Cyst #1

alignments of 1118 sites from 23 taxa at the *18S rDNA* locus and 760 sites from 14 taxa at the *28S rDNA* locus. Alignments were constrained by the length of the *S. cymruensis* sequence at the *18S rDNA* locus and the *S. rodentifelis* sequence at the *28S rDNA* locus. Insertions or deletions (indels) accounted for the difference between the length of alignment and the length of the shortest sequence. These indels were ignored for the purposes of tree building. Support for the resultant trees was assessed using 1000 bootstrap replicates.

Ethics

Research at the Beltsville laboratory was performed in accordance with Animal Protocols #15-018 Toxoplasmosis in cats, approval date May 19, 2015, and #15-017 Toxoplasmosis in mice, approval date May 19, 2015, Chair for both protocols Dr. Ransom Baldwin, Beltsville Institutional Animal Care and Use Committee (BAACUC). These protocols are good for 3 years and can be amended.

The project (Detection of zoonotic pathogens in brown rats (*Rattus norvegicus*) in Grenada) was approved by the Institutional Animal Care and Use Committee (IACUC #16009-R, approval date May 23, 2016, Chair Dr. Karin Guerrero) of the St. George's University, Grenada.

Results

Sarcocysts were found in fresh muscle squashes of skeletal muscle of 11 (7.0%) of 156 rats but not in any heart; infected rats were captured in St. Georges (6 rats) and St. David (5 rats). In fresh squashes, sarcocysts were slender, up to 5028- μm long and 255- μm wide, and had a thin wall (Fig. 1a). Bradyzoites (Fig. 1b) were detected microscopically in pepsin digests in six pools of muscles derived from 123 rats. Histologically, sarcocysts were thin walled in sections of muscle stained with HE (Fig. 1e).

The cat fed naturally infected rat tissues excreted few sporulated oocysts and sporocysts 6 days p.i. (Fig. 1c, d). The mice inoculated with sporocysts from cat remained asymptomatic. Sarcocysts were detected microscopically in muscle squashes of two KO mice but not in two SW mice euthanized day 70 p.i. *Sarcocystis* bradyzoites were detected in pepsin digests and HE-stained sections of muscles from the two KO mice. Neither bradyzoites in carcass digests nor sarcocysts in HE-stained sections were found in muscles of SW mice. Bradyzoites in stained smears averaged $16.3 \times 3.3 \mu\text{m}$ with a range of $12.5\text{--}19.5 \times 1.9\text{--}4.8 \mu\text{m}$ ($n = 35$). No *Sarcocystis* sporocysts were found in feces or small intestine of the two cats fed muscle of two KO and two SW mice euthanized day 70 p.i.

Numerous mature slender sarcocysts were detected in the KO mouse euthanized day 116 p.i. Live bradyzoites were $12.1 \times 3.4 \mu\text{m}$ ($10.5\text{--}13.5 \times 2.7\text{--}4.5$, $n = 30$). *Sarcocystis* sporocysts

were found in the small intestine of the cat fed mouse carcass euthanized on day 116 p.i. No *Sarcocystis* sporocysts were found in the small intestine of six KO mice fed bradyzoites.

Numerous sarcocysts were found in muscles of the KO euthanized day 189 p.i. This KO mouse remained asymptomatic. Sarcocysts were mature, confined to skeletal muscle, and were not grossly visible. The muscle mass seems to be increased although there was no inflammation (Fig. 2). Numerous sarcocysts were present in histologic sections and millions of mature bradyzoites were present in the carcass digest.

Six sarcocysts were studied ultrastructurally. TEM examination confirmed that the sarcocyst wall was thin (Figs. 1f, 3a–d). The parasitophorous vacuolar membrane (pvm) was lined by a 40–60-nm thick layer with variable density (edl). The pvm had 100-nm blebs (evaginations) with a stalk. Depending on the plane of section, some blebs appeared hyphenated (Fig. 3c, d). The pvm was invaginated at irregular distances (Fig. 3c) that appeared like pits on the wall; the edl had thinned out in pits. Beneath the pvm was the smooth ground substance layer (gs). The gs was usually 400–500-nm thick, lacked microtubules, but had few granules (gr). The character of the cyst wall at 116 and 189 days p.i. was identical. Sarcocysts studied were mature and contained numerous bradyzoites and few metrocytes, juxtaposed with gs. The metrocytes (me) were irregular in shape, divided by endodyogeny, and had few organelles (Fig. 4). Longitudinally cut bradyzoites were 9.9×3.0 ($7.7\text{--}11.2\text{--}2.7\text{--}3.5$) μm , and contained a conoid, micronemes (mn),

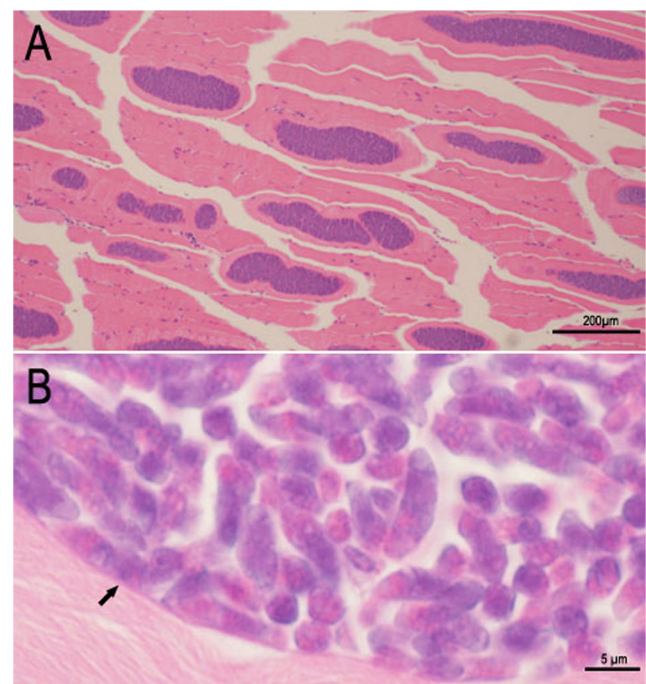


Fig. 2 *Sarcocystis cymruensis* sarcocysts in gastrocnemius muscle of a KO mouse 189 days post inoculation. Hematoxylin and eosin stain. **(a)** Note numerous mature sarcocysts. **(b)** Higher magnification of a sarcocyst. Note thin cyst wall (arrow) enclosing mature bradyzoites

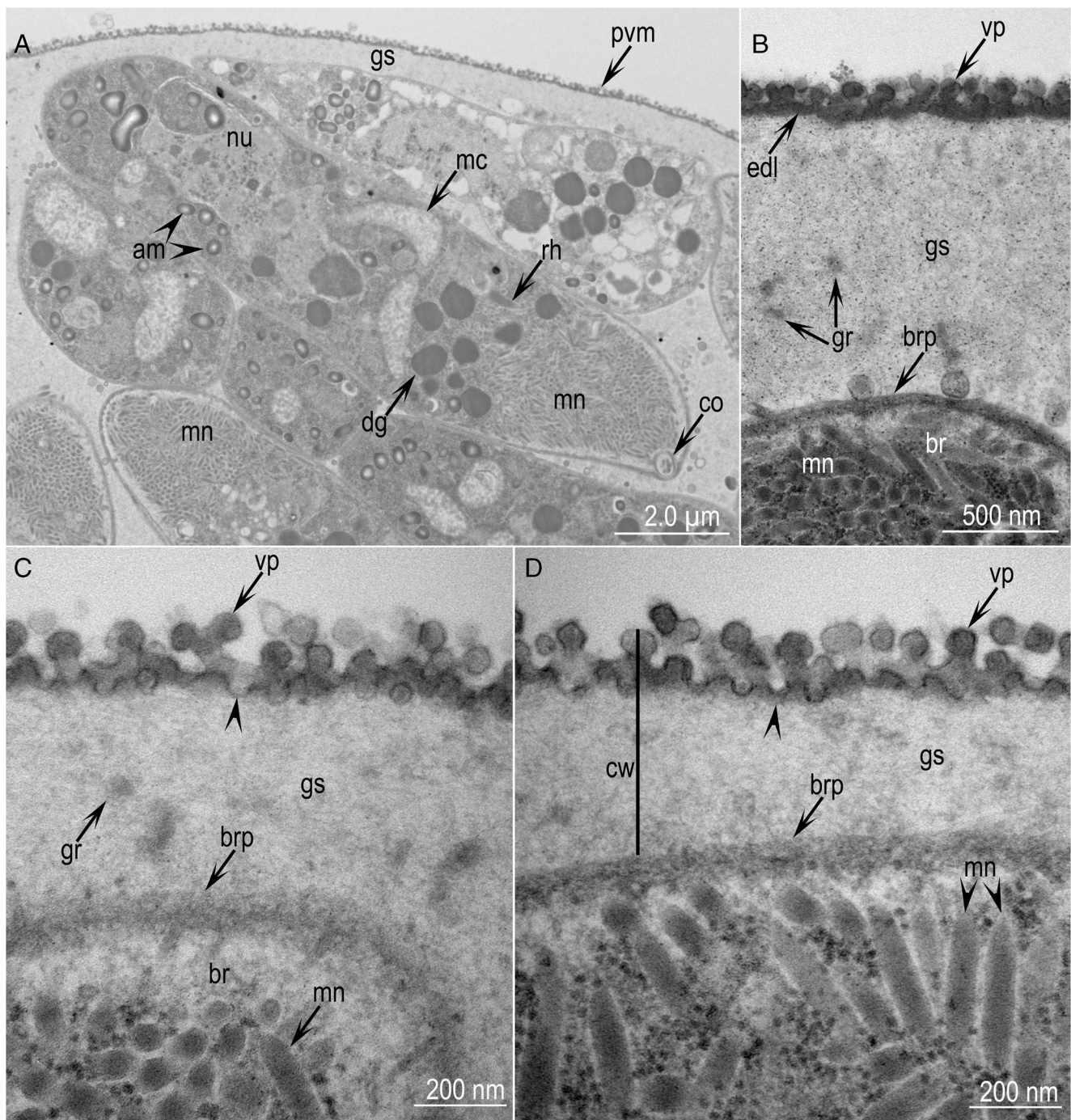


Fig. 3 TEM of *S. cymruensis* sarcocysts. Note cyst wall (cw), parasitophorous vacuolar membrane (pvm), electron dense layer (edl), villar protrusion (vp) ground substance layer (gs), bradyzoite pellicle (brp), bradyzoite (br), nucleus (nu), microneme (mn), amylopectin (am),

dense granules (dg), rhoptry (rh), conoid (co), and mitochondrion (mc). **a** A longitudinally cut and parts of several other bradyzoites. Cyst #2. **b** Note bleb-like vp, gs with few granules (gr). **c, d** Note pits (arrowheads) the pvm. Cyst #2

rhoptries (rh), dense granules (dg), amylopectin granules (am), nucleus (nu), and a mitochondrion (mc) (Fig. 5). The pellicle of bradyzoite was thickened at the conoidal end (Fig. 5b). The micronemes were about 320×60 nm and distributed both haphazardly and in rows (Fig. 3d, 5b). Only one rhoptry was seen in any bradyzoite. There were several dense granules (dg), often concentrated at the conoidal half of the bradyzoite.

Several amylopectin granules (am) were concentrated in the distal half the bradyzoite. The nucleus was subterminal.

Molecular analyses

Partial DNA sequences were successfully acquired from *18S rDNA*, *28S rDNA*, *ITS-1*, and *cox1*. At all loci, DNA

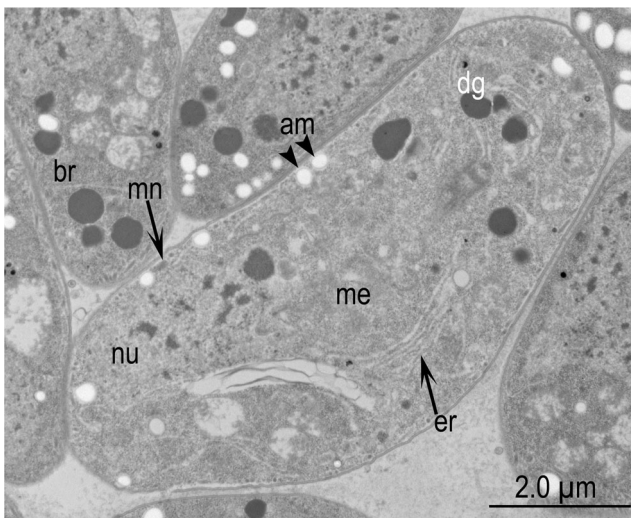


Fig. 4 TEM of *S. cymruensis* showing a metrocyte (me) and parts of 4 bradyzoites (br). Note the metrocyte (me) has no rhoptry, only 1 microneme (mn), 6 dense granules (dg), smooth endoplasmic reticulum (er), few amylopectin granules (am), and a large nucleus (nu). Cyst #3

sequences were identical from sarcocysts isolated from two different mice. These sequences were submitted to NCBI GenBank with accession numbers MG564723 (*18S rDNA*), MG564724 (*28S rDNA*), MG582596 (*ITS-1*), and MG571085 (*cox1*) and designated as *S. cymruensis* from naturally infected *R. norvegicus* from Grenada. BLAST searches revealed that sequences from the *18S rDNA* (987 bp in length) and *28S rDNA* (1511 bp in length) ribosomal DNA were most similar

to published sequences from *S. muris* (KC877996 and AF012883, respectively) and *S. rodentifelis* (AY015111 and AF513496). *Sarcocystis cymruensis 18S rDNA* and *28S rDNA* sequences were 100 and 96.8% identical to *S. muris* sequences, respectively, while *S. rodentifelis* sequences shared 99.5% and 99.3% identity with them; *S. rodentifelis* sequences were considerably shorter at the *28S rDNA* locus. BLAST searches determined that *cox1* (998 bp) shared 95.5% identity with *S. speeri* (KT207461) or *S. lutrae* (KM657808); there were no published *cox1* sequences for *S. muris* or *S. rodentifelis* in GenBank. While *ITS-1* flanking sequences corresponding to the last 71 bases of *18S rDNA* and first 62 bases of *5.8S rDNA* were similar to those from *S. lutrae* (93% identity), the *ITS-1* sequences (743 bp) generated from *S. cymruensis* did not return any significant BLAST hits, despite searching various subsections of the molecule.

Phylogenetic trees for both *18S rDNA* and *28S rDNA* showed 100% bootstrap support for *S. cymruensis*, *S. muris*, and *S. rodentifelis* belonging to an independent clade in the *Sarcocystis* tree (Fig. 6a, b). There are no *cox1* or *ITS-1* sequences for *S. muris* or *S. rodentifelis* in GenBank, negating complete phylogenetic analysis across all loci sequenced.

Discussion

This is the first report of *S. cymruensis* in the Americas. The 7.0% prevalence in the present study is lower than 11.6%

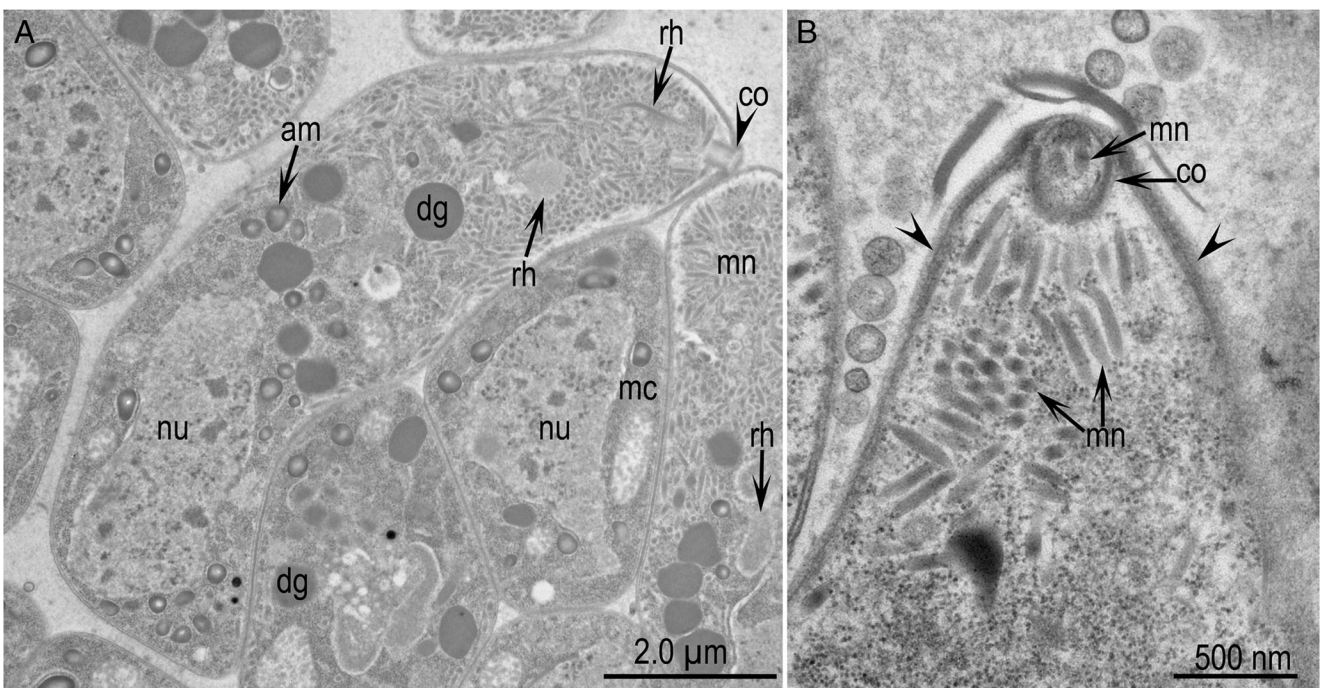


Fig. 5 TEM of *S. cymruensis* bradyzoites. **a** A longitudinally cut and parts of other bradyzoites. Note nucleus (nu), microneme (mn), amylopectin (am), dense granules (dg), rhoptry (rh), conoid (co), and

mitochondrion (mc). **b** Conoidal end of a bradyzoite showing details of conoid and micronemes. Note thickening of the bradyzoite pellicle (arrowheads). Cyst #3

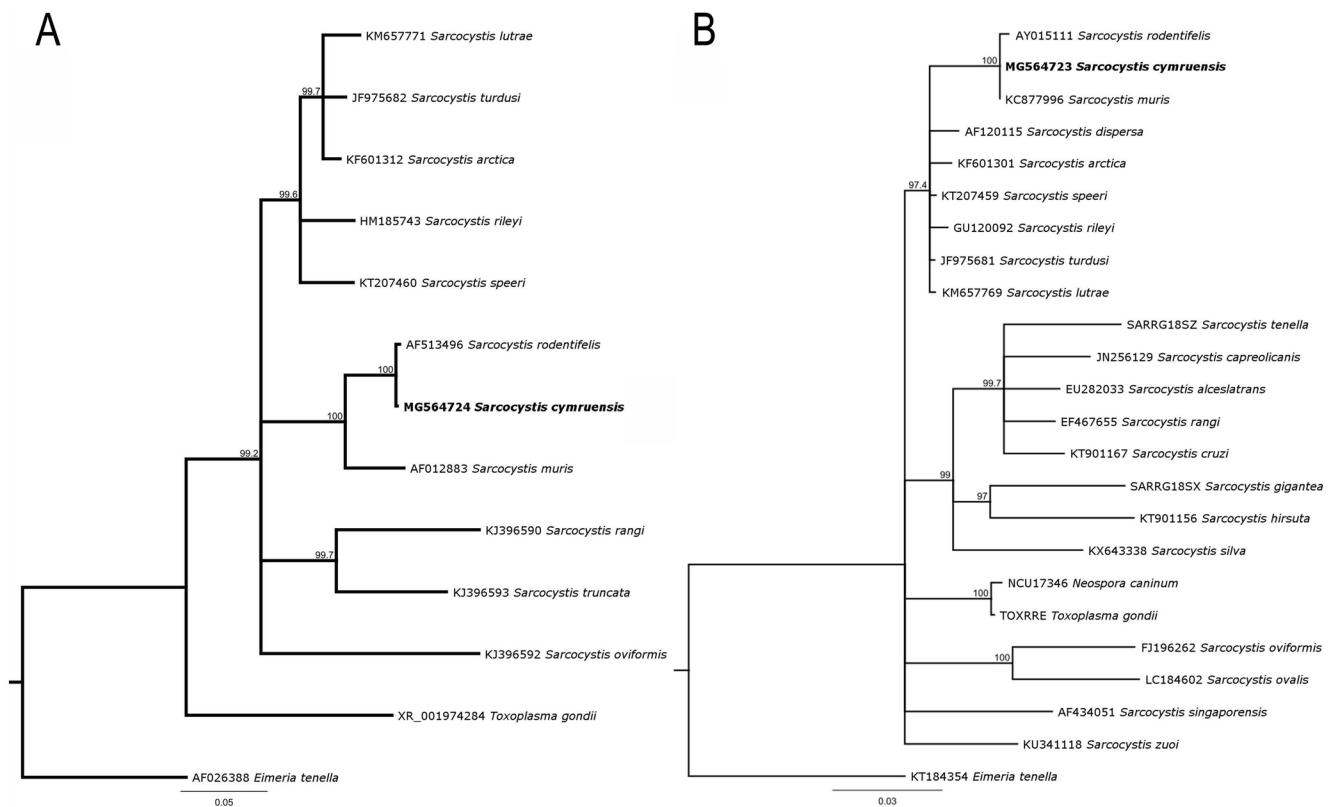


Fig. 6 Phylogenetic relationships among *Sarcocystis* species based on **a** 28S *rDNA* ribosomal DNA sequences and **b** 18S *rDNA* ribosomal DNA sequences. Neighbor-joining trees for each locus were constructed from

HKY genetic distances with 1000 bootstrap replicates. In both trees, an independent clade is formed with 100% bootstrap support which contains *S. cymruensis*, *S. muris*, and *S. rodentifelis*

prevalence in China (Hu et al. 2011) and 17.5% prevalence in the UK (Ashford 1978). The distribution of definitive host may be important concerning prevalence. The natural definitive host for *S. cymruensis* remains unknown; cat is the experimental definitive host.

The present study confirmed the separate identity of *S. cymruensis* although its sarcocyst is morphologically similar to *S. muris* of mice. *Sarcocystis cymruensis* was not transmissible to immunocompetent house mouse (Ashford 1978); here, we have confirmed this. Additionally, we demonstrated that *S. cymruensis* is transmissible to immunodeficient KO mice, as in *S. muris* (Al-Kappany et al. 2013). The KO mice have proved very useful in studying the biology of *Sarcocystis neurona*, a parasite that causes fatal neurological disease in horses and many other mammals (Dubey et al. 2016). Recently, some species of *Sarcocystis* from snakes and red-tailed hawks (Verma et al. 2016; Verma et al. 2017b, c) induced schizont-associated neurological disease in KO mice. In the present study, the KO mice fed *S. cymruensis* sporocysts remained asymptomatic but developed sarcocysts. The sarcocysts in KO mice euthanized 70 days p.i. contained bradyzoites but were apparently not infectious to cat. To maximize chances of detection of few sporocysts, the intestinal mucosa was treated with undiluted bleach (5.25% sodium hypochlorite) to dissolve host tissue (Dubey et al. 2016). The period prior to becoming infectious for *S. cymruensis* is

unknown; in previous studies (Ashford 1978; Hu et al. 2011), cats were fed tissues with grossly visible sarcocysts from naturally infected rats whose infection duration was unknown. We chose to euthanize KO mice at 70, 116, and 189 days p.i. because in most sarcocyst species, sarcocysts become mature at 70 days p.i. (Dubey et al. 2016), but some species take longer. *Sarcocystis muris* sarcocysts became infectious for cats beginning at 76 days p.i., while sarcocysts at 65 days p.i. were not infectious (Ruiz and Frenkel 1976). Thus, the morphologic appearance of bradyzoites may not equate with infectivity. In the present study of KO mice euthanized day 70 p.i., intact, motile bradyzoites were seen in pepsin digest, confirmed by TEM, but were not infectious for cats. Infectivity in cats was only seen after day 116 p.i. in KO mice. Therefore, the range of the development of infectivity is between 70 and 116 days.

In the present study, KO mice acted as intermediate hosts but not as definitive hosts for *S. cymruensis* from Grenada. These findings are different than those obtained with *S. rodentifelis* in rats (Grikenienė et al. 1993) and *S. cymruensis* in rats (Hu et al. 2011). In the present study, four KO mice had ingested millions of free bradyzoites and hundreds of intact sarcocysts from a very heavily infected KO mouse euthanized 189 days p.i. The KO mice were euthanized on days 1, 4, and 6; the prepatent period for *S. cymruensis* is < 8 days. We could not find gamonts, oocysts, or sporocysts in KO mice euthanized 1–6 days p.i. In

addition to examination of histological sections, the entire small intestines were digested in bleach to dissolve the host tissue. Whether these findings are related to different intermediate hosts (rats versus KO mice) or to different parasites is uncertain and requires further studies.

The results of the present study supplement the preliminary description of sarcocyst and bradyzoites by Ashford (1978) and Hu et al. (2011). The ultrastructure of cyst wall is a useful criterion in taxonomy of *Sarcocystis* for species within a given host (Dubey et al. 2016). Based on structure, the sarcocyst wall was grouped into 42 types with subdivisions within a type. The simplest of all wall types, “type 1,” occurs in *S. muris* and several other species; it was further subdivided in “type 1a–h.” In type 1a, the wall has bleb-like protrusions that have a stalk as described in detail for *S. muris* (Sheffield et al. 1977). Dubey et al. (2016), in their review considered *S. cymruensis* as “type 1c” because in the paper by Ashford (1978), the blebs were hyphenated. Results of the present study showed that the hyphae appearance is because of angle of sectioning. Therefore, *S. cymruensis* wall should be regarded as belonging to type 1a, the same as in *S. muris*. We have also supplemented the morphologic description of *S. cymruensis* bradyzoites.

We also provide the first molecular data from *S. cymruensis*, revealing it to be a close relative to *S. muris* and *S. rodentifelis*. While *S. cymruensis* 18S rDNA sequences were identical to that of *S. muris*, 28S rDNA sequences were more similar to *S. rodentifelis* sequence. The *cox1* sequence most closely resembled sequences from *S. lutrae* and *S. speeri*, but was limited in its phylogenetic utility with absence of published *cox1* sequences for *S. muris* or *S. rodentifelis*. At the 18S rDNA and 28S rDNA loci, *S. cymruensis* had 97.3% and 93.0% identity with *S. lutrae*, respectively, placing *S. cymruensis*, *S. muris*, and *S. rodentifelis* in a separate clade of the *Sarcocystis* tree. Additional sequencing would be required to determine which two species in the *S. cymruensis*, *S. muris*, and *S. rodentifelis* clade are most closely related and divergence times among them. The combined divergence at the 18S and 28S loci and the lack of infectivity in immunocompetent house mice supports *S. cymruensis* as probably being distinct from *S. muris*.

Based on the molecular data from the present paper and review of literature, there is uncertainty concerning taxonomic status of *S. cymruensis*/*S. rodentifelis* and additional studies are required to resolve this issue.

Acknowledgements This research was supported in part by an appointment to the Agricultural Research Service (ARS) Research Participation Program administered by the Oak Ridge Institute for Science and Education (ORISE) through an interagency agreement between the U.S. Department of Energy (DOE) and the U.S. Department of Agriculture (USDA). ORISE is managed by ORAU under DOE contract number DE-SC0014664.

Compliance with ethical standards

Disclaimer All opinions expressed in this paper are the author’s and do not necessarily reflect the policies and views of USDA, ARS, DOE, or ORAU/ORISE.

References

- Al-Kappany YM, Abu-Elwafa SA, Hilali M, Rosenthal BM, Dunams DB, Dubey JP (2013) Experimental transmission of *Sarcocystis muris* (Apicomplexa: Sarcocystidae) sporocysts from a naturally infected cat (*Felis catus*) to immunocompetent and immunocompromised mice. *J Parasitol* 99(6):997–1001. <https://doi.org/10.1645/13-274.1>
- Ashford RW (1978) *Sarcocystis cymruensis* n. sp., a parasite of rats *Rattus norvegicus* and cats *Felis catus*. *Ann Trop Med Parasitol* 72(1):37–43. <https://doi.org/10.1080/00034983.1978.11719277>
- Dubey JP (1995) Duration of immunity to shedding of *Toxoplasma gondii* oocysts by cats. *J Parasitol* 81(3):410–415. <https://doi.org/10.2307/3283823>
- Dubey JP (2010) *Toxoplasmosis of animals and humans*, 2nd edn. CRC Press, Boca Raton, Florida, pp 1–313
- Dubey JP, Calero-Bernal R, Rosenthal BM, Speer CA, Fayer R (2016) *Sarcocystosis of animals and humans*, 2nd edn. CRC Press, Boca Raton, Florida, pp 1–481
- Gjerde B (2013) Phylogenetic relationships among *Sarcocystis* species in cervids, cattle and sheep inferred from the mitochondrial cytochrome c oxidase subunit I gene. *Int J Parasitol* 43(7):579–591. <https://doi.org/10.1016/j.ijpara.2013.02.004>
- Gjerde B (2014) Morphological and molecular characteristics of four *Sarcocystis* spp. in Canadian moose (*Alces alces*), including *Sarcocystis taeniata* n. sp. *Parasitol Res* 113(4):1591–1604. <https://doi.org/10.1007/s00436-014-3806-z>
- Gjerde B, Josefsen TD (2015) Molecular characterisation of *Sarcocystis lutrae* n. sp. and *Toxoplasma gondii* from the musculature of two Eurasian otters (*Lutra lutra*) in Norway. *Parasitol Res* 114(3):873–886. <https://doi.org/10.1007/s00436-014-4251-8>
- Grikienienė J, Kutkienė L (1998) New experimental data on the laboratory rat as a definitive host of *Sarcocystis rodentifelis*. *Acta Zool Lituanica Parasitologia* 8(1):121–124. <https://doi.org/10.1080/13921657.1998.10541451>
- Grikienienė J, Arnastauskienė T, Kutkienė L (1993) On some disregarded ways of sarcosporidians circulation and remarks about systematics of the genus *Sarcocystis* Lankester, 1882 with the description of the new species from rodents. *Ekologija* 1:16–24 (In Russian)
- Hu JJ, Liao JY, Meng Y, Guo YM, Chen XW, Zuo YX (2011) Identification of *Sarcocystis cymruensis* in wild *Rattus flavipectus* and *Rattus norvegicus* from People’s Republic of China and its transmission to rats and cats. *J Parasitol* 97(3):421–424. <https://doi.org/10.1645/GE-2633.1>
- Jäkel T, Burgstaller H, Frank W (1996) *Sarcocystis singaporensis*: studies on host specificity, pathogenicity, and potential use as a biocontrol agent of wild rats. *J Parasitol* 82(2):280–287. <https://doi.org/10.2307/3284161>
- Jäkel T, Khoprasert Y, Sorger I, Kliemt D, Seehabutr V, Suasa-ard K, Hongnark S (1997) Sarcosporidiasis in rodents from Thailand. *J Wildl Dis* 33(4):860–867. <https://doi.org/10.7589/0090-3558-33.4.860>
- Ruiz A, Frenkel JK (1976) Recognition of cyclic transmission of *Sarcocystis muris* by cats. *J Infect Dis* 133:409–418
- Sheffield HG, Frenkel JK, Ruiz A (1977) Ultrastructure of the cyst of *Sarcocystis muris*. *J Parasitol* 63(4):629–641. <https://doi.org/10.2307/3279561>
- Trupkiewicz JG, Calero-Bernal R, Verma SK, Mowery J, Davison S, Habecker P, Georoff TA, Ialeggio DM, Dubey JP (2016) Acute, fatal

- Sarcocystis calchasi*-associated hepatitis in Roller pigeons (*Columba livia f. dom.*) at Philadelphia Zoo. *Vet Parasitol* 216: 52–58. <https://doi.org/10.1016/j.vetpar.2015.11.008>
- Verma SK, Lindsay DS, Rosenthal BM, Dubey JP (2016) Ancient, globally distributed lineage of *Sarcocystis* from sporocysts of the eastern rat snake (*Pantherophis alleghaniensis*) and its relation to neurological sequelae in intermediate hosts. *Parasitol Res* 115(7):2697–2704. <https://doi.org/10.1007/s00436-016-5086-2>
- Verma SK, Lindsay DS, Grigg ME, Dubey JP (2017a) Isolation, culture and cryopreservation of *Sarcocystis* species. *Curr Protoc Microbiol* 45:20D
- Verma SK, Lindsay DS, Mowery JD, Rosenthal BM, Dubey JP (2017b) *Sarcocystis pantherophisi* n. sp., from eastern rat snakes (*Pantherophis alleghaniensis*) as definitive hosts and interferon gamma gene knockout mice as experimental intermediate hosts. *J Parasitol* 103(5):547–554. <https://doi.org/10.1645/17-2>
- Verma SK, Von Dohlen AR, Mowery JD, Scott D, Rosenthal BM, Dubey JP, Lindsay DS (2017c) *Sarcocystis jamaicensis*, n. sp. from red-tailed hawks (*Buteo jamaicensis*) definitive host and IFN- γ gene knockout mice as experimental intermediate host. *J Parasitol* 103(5):555–564. <https://doi.org/10.1645/17-10>