



This is a repository copy of *Cardiotoxicity and myocardial hypoperfusion associated with anti-vascular endothelial growth factor therapies: prospective cardiac magnetic resonance imaging in patients with cancer.*

White Rose Research Online URL for this paper:  
<http://eprints.whiterose.ac.uk/160795/>

Version: Published Version

---

**Article:**

Dobbin, S.J.H., Mangion, K., Berry, C. et al. (9 more authors) (2020) Cardiotoxicity and myocardial hypoperfusion associated with anti-vascular endothelial growth factor therapies: prospective cardiac magnetic resonance imaging in patients with cancer. *European Journal of Heart Failure*. 1847. ISSN 1388-9842

<https://doi.org/10.1002/ejhf.1847>

---

**Reuse**

This article is distributed under the terms of the Creative Commons Attribution (CC BY) licence. This licence allows you to distribute, remix, tweak, and build upon the work, even commercially, as long as you credit the authors for the original work. More information and the full terms of the licence here:  
<https://creativecommons.org/licenses/>

**Takedown**

If you consider content in White Rose Research Online to be in breach of UK law, please notify us by emailing [eprints@whiterose.ac.uk](mailto:eprints@whiterose.ac.uk) including the URL of the record and the reason for the withdrawal request.



[eprints@whiterose.ac.uk](mailto:eprints@whiterose.ac.uk)  
<https://eprints.whiterose.ac.uk/>

## RESEARCH LETTER

doi:10.1002/ejhf.1847

### Cardiotoxicity and myocardial hypoperfusion associated with anti-vascular endothelial growth factor therapies: prospective cardiac magnetic resonance imaging in patients with cancer

By interrupting tumour angiogenesis, vascular endothelial growth factor signalling pathway inhibitors (VSPIs) represent a major advance in the treatment of a wide variety of cancers.<sup>1</sup> However, their oncological benefits have been accompanied by considerable cardiovascular toxicity, including hypertension, left ventricular systolic dysfunction (LVSD) and heart failure.<sup>2</sup> These may be severe and can limit the dose and duration of anti-cancer treatment.

The timing, frequency, and pathophysiological basis of VSPI-associated myocardial toxicity is incompletely defined. In addition to the detrimental effect of an abrupt rise in left ventricular afterload as a result of VSPI-associated hypertension, inhibition of vascular endothelial growth factor may have direct myocardial toxic effects. This may be the consequence of inhibition of tyrosine kinases required both for tumour growth and normal cardiac function. Furthermore, VSPIs are associated with peripheral microvascular rarefaction<sup>3</sup> and it remains unclear whether myocardial micro-arterial constriction or vessel loss is implicated in the pathogenesis of VSPI-associated LVSD. The only prior study to evaluate prospectively the effects of VSPIs upon cardiac function used echocardiography and demonstrated a 9.7% incidence of cardiotoxicity, defined as  $\geq 10\%$  reduction in left ventricular ejection fraction (LVEF) to a value less than 50%.<sup>4</sup> There are inherent limitations of echocardiography for the reproducible detection of changes in myocardial function and it does not allow assessment of myocardial perfusion, vascular permeability, or myocardial tissue characterisation. We therefore used multi-parametric cardiac

magnetic resonance imaging, including adenosine stress-perfusion to measure myocardial blood flow and vascular permeability in patients before and during VSPI treatment.<sup>5</sup>

All patients over the age of 18 years at the Beatson West of Scotland Cancer Centre in Glasgow, Scotland, who were planned to commence VSPI therapy were considered for participation. Enrolment took place between December 2018 and March 2019. Exclusion criteria included an estimated glomerular filtration rate  $< 30$  mL/min/1.73 m<sup>2</sup> of body surface area, persistent or permanent atrial fibrillation, second- or third-degree atrioventricular block, and a history of allergy to adenosine or gadolinium contrast.

Patients underwent stress-perfusion cardiac magnetic resonance imaging (3.0T Siemens MAGNETOM Prisma; Siemens Healthcare, Erlangen, Germany) at baseline and after 4 to 6 weeks of treatment. Biventricular mass and function, myocardial feature-tracking strain, and tissue characterisation by T1 mapping and perfusion imaging were assessed. Myocardial T1 mapping measures the myocardial longitudinal magnetic relaxation time (also known as spin–lattice relaxation time) of different molecules found within the myocardium. Intravenous adenosine infusion was used to induce hyperaemia to simulate myocardial stress.

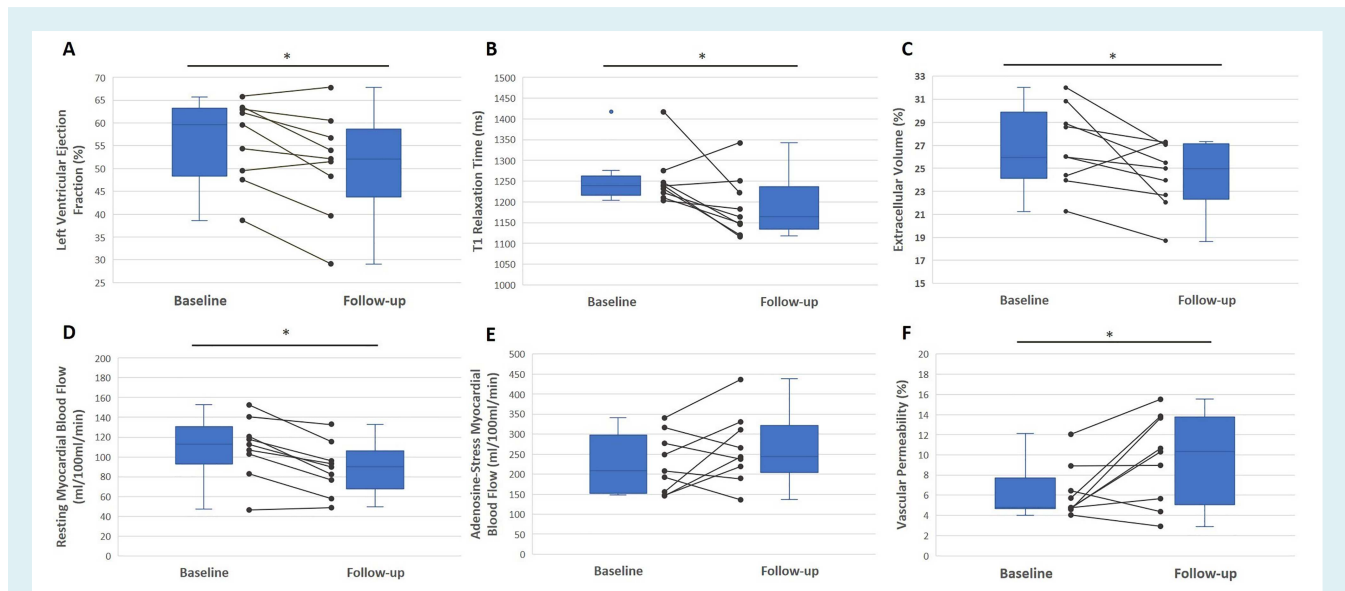
Ten patients were enrolled. All had incurable cancer. One withdrew because of severe tumour-related symptoms. The average age was  $60.8 \pm 7.5$  years and most participants were male ( $n = 7$ ). Eight had renal cell cancer and one patient had sarcoma. VSPI therapies included pazopanib ( $n = 6$ ), sunitinib ( $n = 2$ ) and tivozanib ( $n = 1$ ). Cardiovascular comorbidities were common at baseline, including hypertension (56%) and hypercholesterolaemia (22%). The average body mass index was  $29.3 \pm 4.4$  kg/m<sup>2</sup>. Eight patients (89%) developed new or worsening hypertension with VSPI therapy. Both systolic and diastolic blood pressure increased after 4 weeks of treatment by  $27.6 \pm 22.0$  mmHg ( $P = 0.006$ ) and  $18.8 \pm 11.2$  mmHg ( $P = 0.001$ ), respectively.

After 4 weeks of VSPI treatment, LVEF fell from  $55.9 \pm 3.1\%$  to  $51.0 \pm 3.8\%$  ( $P = 0.019$ ) and five patients had a reduction in LVEF of at least 5% (Figure 1A). Myocardial T1 relaxation times reduced from 1239 ms [interquartile

range (IQR) 1222–1247 ms] at baseline, to 1165 ms (IQR 1147–1222 ms) at follow-up ( $P = 0.038$ ). Extra-cellular volume also declined from  $26.9 \pm 1.2\%$  to  $24.4 \pm 1.0\%$  ( $P = 0.047$ ) at 4–6 weeks (Figure 1B and 1C). After 4–6 weeks, resting myocardial blood flow was 18% lower than baseline ( $P = 0.002$ ) (Figure 1D) but adenosine-induced stress myocardial blood flow was unchanged by VSPI treatment ( $P = 0.152$ ). Additionally, after 4–6 weeks, there was an increase in contrast agent extraction fraction (a marker of vascular permeability) at rest ( $P = 0.041$ ), with no change during adenosine-induced stress ( $P = 0.772$ ) (Figure 1E and 1F).

In this hypothesis-generating study, VSPI therapy was associated with a reduction in LVEF and it is possible that the incidence of a more substantial drop in LVEF decline may be greater than previously appreciated. Although systemic hypertension may contribute to these phenomena, alterations in myocardial tissue characteristics, including reduced T1 relaxation time, may reflect direct myocardial toxic effects. The observed rise in vascular permeability supports a role for microvascular endothelial dysfunction in the development of VSPI-associated LVSD. Furthermore, reduced resting myocardial blood flow is consistent with VSPI-induced microvascular constriction and consequent myocardial hypoperfusion. The normalisation of myocardial blood flow with adenosine-induced stress suggests that VSPI-induced microvascular vasoconstriction may be reversible and that vasodilator agents might be a potential strategy to prevent or treat the early cardiotoxic effects of VSPI. It remains to be established whether such microvascular changes remain reversible in patients exposed to VSPI therapies and indeed, whether any of the potential cardiotoxic effects or injury sustained or progressed in the longer term.

Further prospective evaluation of larger groups of patients is necessary to provide robust data relating to the incidence and pathophysiology of VSPI-induced cardiotoxicity. This is required urgently to allow balanced decision-making before prescribing these effective anti-cancer therapies whilst minimising cardiovascular risk. Optimised cardiovascular surveillance strategies and mechanistically-targeted strategies to reduce



**Figure 1** Changes in (A) left ventricular ejection fraction, (B) T1 relaxation time, (C) extracellular volume, (D) myocardial blood flow at rest and (E) stress, and (F) vascular permeability at rest with 4–6 weeks of vascular endothelial growth factor signalling pathway inhibitor therapy.

VSPI-induced cardiovascular toxicity are both overdue.

### Funding

This study was supported by NHS Greater Glasgow and Clyde Research and Development and by funds from the British Heart Foundation (RE/18/6/34217).

**Conflicts of interest:** none declared.

**Stephen J.H. Dobbin<sup>1</sup>,  
Kenneth Mangion<sup>1</sup>, Colin Berry<sup>1</sup>,  
Giles Roditi<sup>2</sup>, Susmita Basak<sup>3</sup>,  
Steven Sourbron<sup>4</sup>, Jeff White<sup>5</sup>,  
Balaji Venugopal<sup>5</sup>, Rhian M. Touyz<sup>1</sup>,  
Robert J. Jones<sup>5</sup>, Mark C. Petrie<sup>1</sup>, and  
Ninian N. Lang<sup>1\*</sup>**

<sup>1</sup>BHF Glasgow Cardiovascular Research Centre, Institute of Cardiovascular and Medical Sciences,

University of Glasgow, Glasgow, UK; <sup>2</sup>Department of Radiology, Glasgow Royal Infirmary, Glasgow, UK; <sup>3</sup>Division of Medical Physics, University of Leeds, Leeds, UK; <sup>4</sup>Department of Infection, Immunity, and Cardiovascular Disease, University of Sheffield, Sheffield, UK; and <sup>5</sup>Institute of Cancer Sciences, University of Glasgow, Beatson West of Scotland Cancer Centre, Glasgow, UK  
\*Email: ninian.lang@glasgow.ac.uk

### References

- Quaresma M, Coleman MP, Rachet B. 40-year trends in an index of survival for all cancers combined and survival adjusted for age and sex for each cancer in England and Wales, 1971–2011: a population-based study. *Lancet* 2015;**385**:1206–1218.
- Zamorano JL, Lancellotti P, Muñoz DR, Aboyans V, Asteggiano R, Galderisi M, Habib G, Lenihan DJ, Lip GY, Lyon AR, Lopez Fernandez T, Mohty D, Piepoli MF, Tamargo J, Torbicki A, Suter TM. 2016 ESC Position Paper on cancer treatments and cardiovascular toxicity developed under the auspices of the ESC

Committee for Practice Guidelines: the Task Force for Cancer Treatments and Cardiovascular Toxicity of the European Society of Cardiology (ESC). *Eur J Heart Fail* 2017;**19**:9–42.

- Steeghs N, Gelderblom H, Roodt JO, Christensen O, Rajagopalan P, Hovens M, Putter H, Rabelink TJ, de Koning E. Hypertension and rarefaction during treatment with telatinib, a small molecule angiogenesis inhibitor. *Clin Cancer Res* 2008;**14**:3470–3476.
- Narayan V, Keefe S, Haas N, Wang L, Puzanov I, Putt M, Catino A, Fang J, Agarwal N, Hyman D, Smith AM, Finkelman BS, Narayan HK, Ewer S, ElAmm C, Lenihan D, Ky B. Prospective evaluation of sunitinib-induced cardiotoxicity in patients with metastatic renal cell carcinoma. *Clin Cancer Res* 2017;**23**:3601–3609.
- Papanastasiou G, Williams MC, Dweck MR, Mirsadraee S, Weir N, Fletcher A, Lucatelli C, Patel D, van Beek EJ, Newby DE, Semple SI. Multimodality quantitative assessments of myocardial perfusion using dynamic contrast enhanced magnetic resonance and <sup>15</sup>O-labeled water positron emission tomography imaging. *IEEE Trans Radiat Plasma Med Sci* 2018;**2**:259–271.