

University of Northern Colorado

## Scholarship & Creative Works @ Digital UNC

---

2020 Undergraduate Presentations

Research Day 2020

---

4-2020

### **The Role of Creatine Supplementation in Alleviating Doxorubicin Induced Hepatotoxicity**

Michael Viereckl

Nouf Alojibaily

David Hydock

Yuyan Han

Follow this and additional works at: [https://digscholarship.unco.edu/ug\\_pres\\_2020](https://digscholarship.unco.edu/ug_pres_2020)

---



# The Role of Creatine Supplementation in Alleviating Doxorubicin Induced Hepatotoxicity

Michael Viereckl, Nouf Alojibaily, Jammie Henderson, David Hydock, Yuyan Han



## Background:

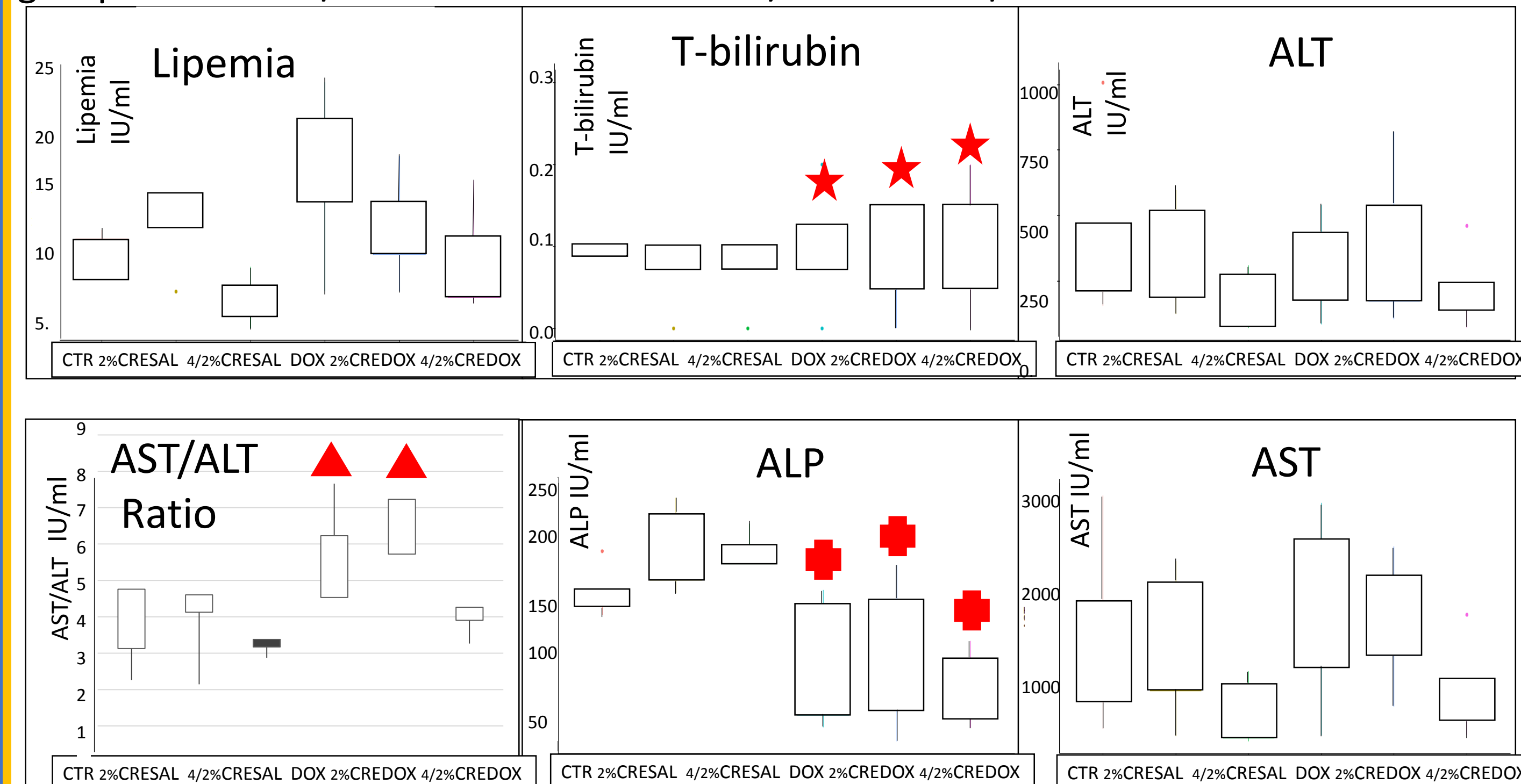
- Doxorubicin AKA “the red devil” is a chemotherapeutic drug used to treat a wide range of cancers.<sup>[1]</sup>
- Doxorubicin’s mechanism of inducing toxicity is multifaceted in this regard. The overall result being cell death.
  - It is believed to a.) induce mitochondrial stress leading to an increase of reactive oxygen species and b.) inhibit the activity of DNA repair mechanisms.<sup>[1]</sup>
- While advantageous when fighting doxorubicin toxicity presents a serious risk to a patients own tissues. Severe cases of cardiotoxicity are often associated with treatment, manifesting within weeks or years of treatment.<sup>[2]</sup>
  - Liver failure is another rare but serious side effect.<sup>[3]</sup>
  - Routes of mitigating these deleterious symptoms is an ongoing area of research. Creatine is a proposed intervention due to its ergogenic and safe use.
    - Creatine can increase intracellular ATP availability in numerous tissues.<sup>[4]</sup> Creatine has been shown to successfully reduce the dystrophic effects on skeletal muscle and reduce cardio myocellular injury.<sup>[4]</sup>

## Question and Methods:

**Experimental Question:** Does creatine supplementation alleviate doxorubicin induced hepatotoxicity and if so, what dose works best?

- Sprague-Dawley rats (*Rattus norvegicus*) were used as a model organism
- Six treatment groups consisting of four rats each received either saline (CTR), 2% creatine/saline (2%CRE/SAL), 4X2%creatine/saline (4/2CRE/SAL), doxorubicin (DOX), 2%creatine/doxorubicin (2%CRE/DOX), 4X2% creatine/doxorubicin (4/2CRE/DOX).
- Creatine supplementation lasted for 2 weeks, followed by an injection of doxorubicin.
- The treatment groups were anesthetized and sacrificed after treatment. Liver samples and serum were then collected. Tissue was snap frozen with liquid nitrogen.
- Liver function was examined by serum chemistry.
- Liver to bodyweight ratio was calculated.
- H&E staining, Senescence staining and Sirius red staining were used to examine the liver damage and liver fibrosis histologically.
- Genomic DNA and total RNA was also isolated and used to examine global methylation and apoptotic, senescent and fibrotic biomarkers through ELISA and qPCR.

**Figure 1:** Serum chemistry and H&E stain indicate signs of hepatotoxicity in doxorubicin and 2% creatine/doxorubicin group. Serum ALT/AST ratio attenuated in 4/2% creatine/doxorubicin.



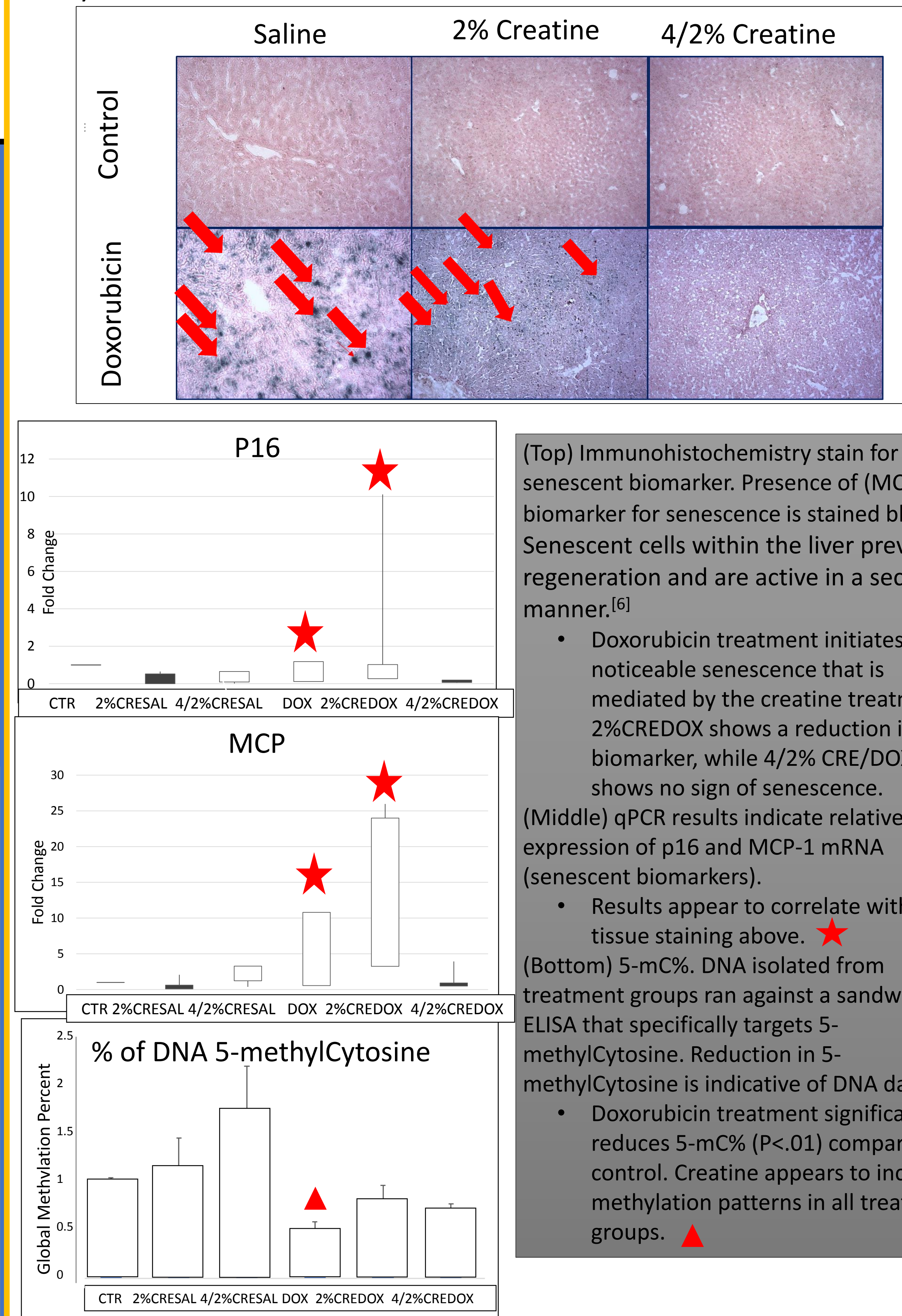
(Top) Serum chemistry analysis of CREDOX sample groups using lipids (lipemia), liver metabolites (t-bilirubin), and liver enzymes (ALP, ALT/AST ratio, ALT, AST). Clinical significance is indicated by the AST/ALT ratio.<sup>[5]</sup>

- Bilirubin elevated in doxorubicin treatments (DOX, 2%CRE/DOX, 4/2%CRE/DOX). ★
- Significantly elevated AST/ALT ratio (P<.05) and elevated AST in DOX and 2%CRE/DOX indicate liver toxicity. ▲
- Significant difference between 2%CRE/SAL and 4/2%CRE/DOX (P<.05) and between 4/2%CRE/SAL and 4/2%CRE/DOX (P<.05) for ALP. ●

(Bottom) H&E staining of hepatic portal vein, artery, and biliary duct. Nucleus stained dark purple, acidic proteins in cytoplasm stained pink.

- Noticeably thicker vascular walls and more nuclei in control groups compared to doxorubicin treatment. ●
- Pink eosin staining appears more intense in doxorubicin groups which indicates protein accumulation or lower pH. Signs of cell stress. □
- 4/2% CRE/DOX sample tissue dried and difficult to distinguish.

**Figure 2:** Creatine supplementation reverses doxorubicin induced global methylation reduction and senescence.



(Top) Immunohistochemistry stain for senescent biomarker. Presence of (MCP-1) biomarker for senescence is stained black. Senescent cells within the liver prevent regeneration and are active in a secretory manner.<sup>[6]</sup>

- Doxorubicin treatment initiates noticeable senescence that is mediated by the creatine treatment; 2%CRE/DOX shows a reduction in biomarker, while 4/2% CRE/DOX shows no sign of senescence.

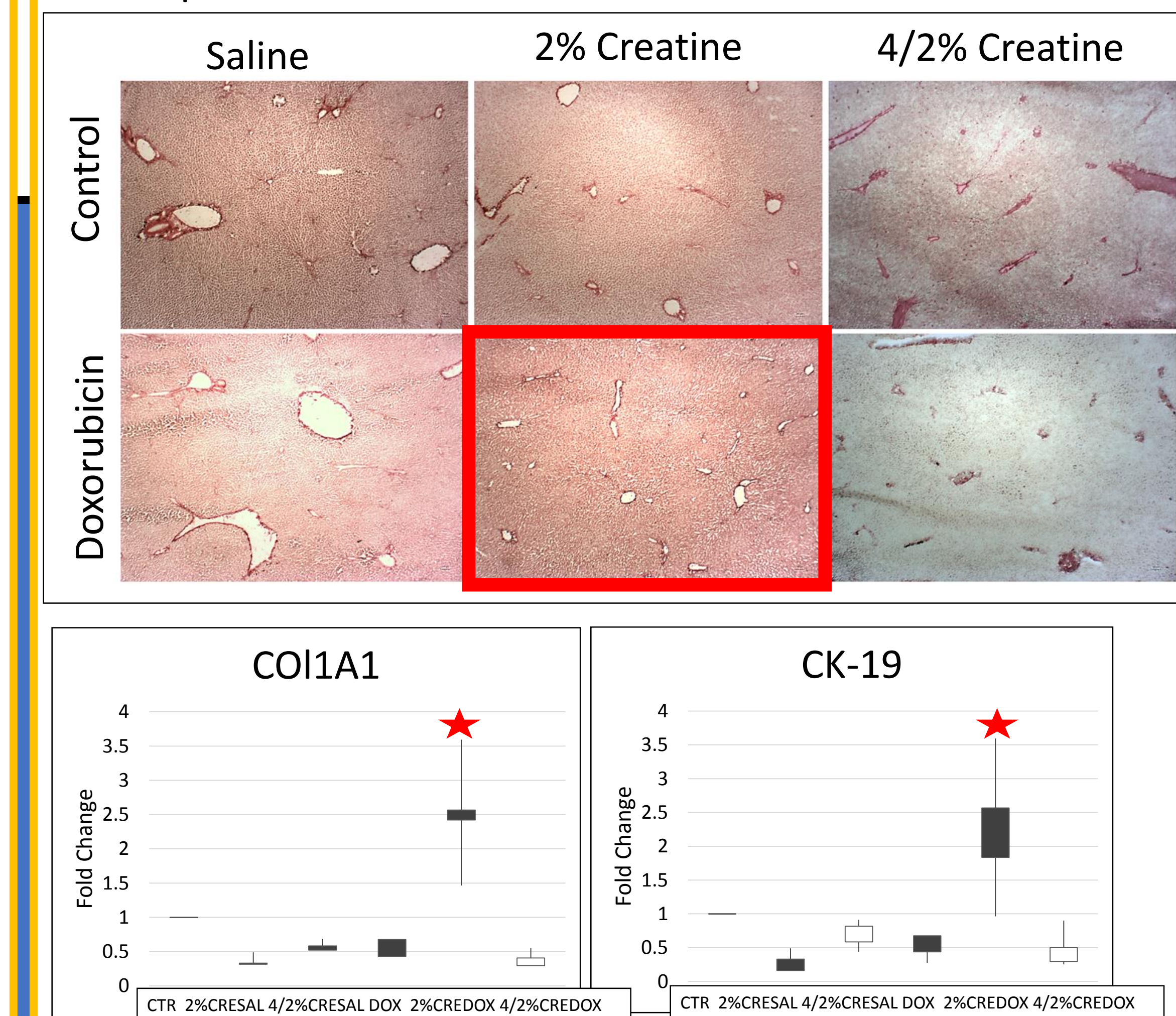
(Middle) qPCR results indicate relative expression of p16 and MCP-1 mRNA (senescent biomarkers).

- Results appear to correlate with tissue staining above. ★

(Bottom) 5-mC%. DNA isolated from treatment groups ran against a sandwich ELISA that specifically targets 5-methylCytosine. Reduction in 5-methylCytosine is indicative of DNA damage.

- Doxorubicin treatment significantly reduces 5-mC% (P<.01) compared to control. Creatine appears to increase methylation patterns in all treatment groups. ▲

**Figure 4:** Creatine/Doxorubicin treatment induces fibrosis in a dose dependent manner.



(Top) Sirius red staining. Nucleus appear dark. Lipids stained yellow and collagen fibers selectively stained red. Sirius red selectively shows fibrosis. Red pixels quantified using imaging software.

- Significant difference (P<.05) between DOX treatment group and 2%CRE/DOX group. □

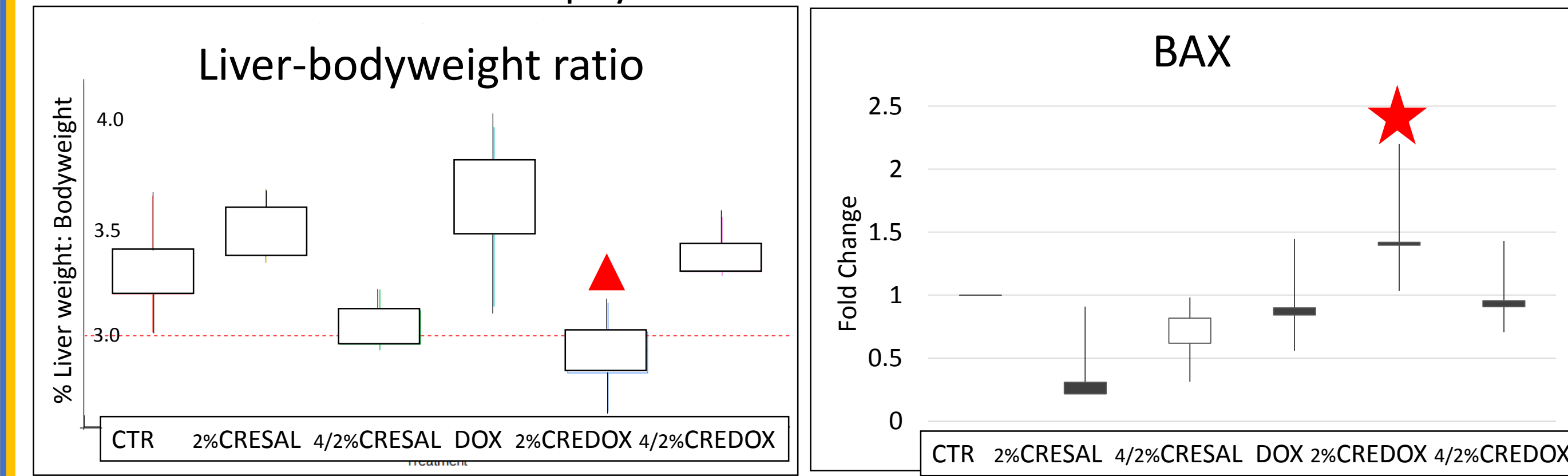
(Bottom) qPCR results indicate relative expression of Col1A1 (marker for fibrosis) and CK-19 (marker for biliary damage).

- Results show elevated markers in 2%CRE/DOX group. ★

**Conclusion:** Creatine alleviates doxorubicin toxicity in a dose dependent manner. Higher doses (4X2% creatine) appear to mediate and reverse the signs of hepatotoxicity. Lower doses (2%creatine) interact negatively and show signs of amplifying hepatotoxicity.

1. Significant changes in serum chemistry indicates liver toxicity in doxorubicin and 2%Creatine/Doxorubicin treatments which is alleviated in the 4X2% Creatine/Doxorubicin treatment. (Figure 1)
  - i. Intense eosin in H&E staining shows protein accumulation in doxorubicin treatments and degrading vascular wall in 2%Creatine/Doxorubicin treatment. (Figure 1)
2. Senescence induced by doxorubicin is reversed by creatine treatment. (Figure 2)
  - i. Magnitude appears to be affected by dose. (Figure 2)
3. Global hypomethylation is improved with creatine treatment. (Figure 2)
4. Creatine causes higher levels of liver atrophy and fibrosis in the 2%Creatine treatment compared to the 4X2% Creatine treatments. (Figure 3 & 4)

**Figure 3:** Doxorubicin treatment results in body-mass atrophy, adding creatine results in additional liver atrophy



(Left) Liver to bodyweight ratio. Line drawn at 3.0% is “normal” ratio.

- Liver-Bodyweight ratio elevated with doxorubicin treatment. Significant difference between DOX/SAL & 2% CRE/DOX (P-value: 0.00071). Bodyweight decreased with doxorubicin treatment while liver weight remained normal. Bodyweight and liver weight decrease with creatine treatment. ▲

(Right) qPCR indicate elevated mRNA expression of BAX (apoptotic marker) all CRE/DOX treatments. ★

References:  
 1.) Thom CF, Oshiro C, Marsh S, et al. Doxorubicin pathways: pharmacokinetics and adverse effects. *Pharmacogenomics*. 2011;21(7):440-446. doi:10.1089/prf.2010.13.5283-531056  
 2.) Mitry MA, Edwards JG. Doxorubicin induced heart failure: Phenotype and molecular mechanisms. *Int J Cardiol Heart Vasc*. 2016;10:17-24. doi:10.1016/j.ijch.2015.11.004  
 3.) LiverTox: Clinical and Research Information on Drug-Induced Liver Injury [Internet]. Bethesda (MD): National Institute of Diabetes and Digestive and Kidney Diseases; 2012. Doxorubicin. [Updated 2018 Jan 15]. Available from: <http://www.ncbi.nlm.nih.gov/books/NBK548622/>  
 4.) Zoltan A, Torok, Raquel B, Butsekus R, David S, Hydock (2020) Effects of Creatine Supplementation on Muscle Fatigue in Rats Receiving Doxorubicin Treatment, Nutrition and Cancer, 22:2, 252-259, DOI: 10.1080/10103253.2019.1621939  
 5.) Giannini EG, Testa R, Savarino V. Liver enzyme alteration: a guide for clinicians. *CMAJ*. 2005;172(3):367-379. doi:10.1503/cmaj.1040752  
 6.) Huda N, Liu G, Hong H, Yan S, Khamba B, Yin XM. Hepatic senescence, the good and the bad. *World J Gastroenterol*. 2019;25(34):5069-5081. doi:10.3748/wjg.v25.i34.5069