

2020

Macrophage Activation Syndrome as a Complication of Systemic Lupus Erythematosus in an Adult Male

Rajesh Gopalarathinam, Vamsee Chirumamilla, and Balachandran Vaidyanathan

Author Affiliations

Rajesh Gopalarathinam (*Marshall University Joan C. Edwards School of Medicine, Huntington, West Virginia*)

Vamsee Chirumamilla MBBS (*New York Presbyterian Weill Cornell Medical Center, New York, NY*)

Balachandran Vaidyanathan MBBS (*University of Louisville, Louisville, KY*)

Corresponding Author

Rajesh Gopalarathinam

Marshall University Joan C. Edwards School of Medicine

Huntington, West Virginia

Email: gopalarathin@marshall.edu

Follow this and additional works at: <https://mds.marshall.edu/mjm>



Part of the [Rheumatology Commons](#)

Recommended Citation

Gopalarathinam, Rajesh; Chirumamilla, Vamsee; and Vaidyanathan, Balachandran (2020) "Macrophage Activation Syndrome as a Complication of Systemic Lupus Erythematosus in an Adult Male," *Marshall Journal of Medicine*: Vol. 6: Iss. 2, Article 7.

DOI: [10.33470/2379-9536.1261](https://doi.org/10.33470/2379-9536.1261)

Available at: <https://mds.marshall.edu/mjm/vol6/iss2/7>

DOI: [10.33470/2379-9536.1261](https://doi.org/10.33470/2379-9536.1261)

Author Footnote: Rajesh Gopalarathinam: involved in patient care, collected the histopathological image and drafted the manuscript. Vamsee Chirumamilla: structured the discussion. Balachandran Vaidyanathan: structured the discussion. All authors reviewed and approved the final version of the manuscript.

Open Access | 

Macrophage activation syndrome as a complication of systemic lupus erythematosus in an adult male

Abstract

Macrophage activation syndrome (MAS) is a rare life-threatening complication that can occur in patients with systemic lupus erythematosus (SLE) and other connective tissue diseases. It is universally fatal without treatment and therefore prompt diagnosis and initiation of treatment are of vital importance.

Keywords

Systemic Lupus Erythematosus, Macrophage Activation Syndrome, Anakinra, Hyperferritinemia, Methylprednisolone

Introduction

Our case report highlights the rare occurrence of MAS as a complication of SLE in a young adult male and the importance of timely diagnosis and treatment to reduce morbidity and mortality.

Case Presentation

A 31-year old male with no significant past medical history presented with a 2-day history of progressively worsening bilateral lower extremity edema and facial puffiness. Associated symptoms were fatigue, chills, myalgia, and arthralgia of both hands and feet. Initial workup revealed acute kidney injury in the setting of nephrotic syndrome. Autoimmune workup revealed elevated titers of antinuclear antibodies (ANA) (1:640), positive anti-Smith antibody titer (467 units/ml), low complement levels (C3 – 46 mg/dl and C4 – 3.4 mg/dl) with negative titers of anti-double-stranded DNA(dsDNA) antibodies, cytoplasmic antinuclear cytoplasmic antibodies (c-ANCA) and perinuclear antinuclear cytoplasmic antibodies (p-ANCA). The infectious workup was negative. Renal biopsy was consistent with class V lupus nephritis. Subsequently, the rheumatology team was consulted and the patient was started on 60 mg IV methylprednisolone daily and 500 mg oral mycophenolate mofetil twice daily. Over the next 1-2 days, with IV steroids and IV diuresis, the patient clinically improved. Subsequently, IV methylprednisolone was tapered and switched to oral prednisone. However, the patient deteriorated again and developed persistent high-grade fever with chills. Lab work (see investigations below) revealed an acute drop in cell counts, worsening liver function, and elevated inflammatory markers.

Hemoglobin – 8.1 mg/dl (was 12.5 mg/dL 24 hours prior)

White blood cell (WBC count) – 3.66 k/mcl (was 9.09 k/mcl 24 hours prior)

Platelet count – 70 k/mcl (was 167 k/mcl 24 hours prior)

Alanine transaminase (ALT) – 93 U/L (was 29 U/L 24 hours prior)

Aspartate transaminase (AST)- 239 U/L (was 38 U/L 24 hours prior)

Alkaline phosphatase – 95 U/L (was 62 U/L 24 hours prior)

Total Bilirubin – 2.0 mg/dl (was 0.2 mg/dL 24 hours prior)

C-reactive protein (CRP) – 40.8 mg/dl (was 7.3 mg/dL 48 hours prior)

Erythrocyte sedimentation rate (ESR) - > 140 mm/hr

C3 – 110 mg/dL

C4 – 5.8 mg/dL

Sepsis was ruled out after an extensive infectious workup including blood cultures, CT imaging of chest/abdomen/pelvis and transthoracic echo revealed no evidence of infection. Lupus flare was considered to be less likely due to elevated C3 and C4 levels. Further workup revealed an elevated serum ferritin level at 303,520 ng/ml. Fibrinogen level was elevated at 451 mg/dl. Triglyceride level was elevated at 872 mg/dl. Based on pancytopenia, transaminitis, hypertriglyceridemia, and hyperferritinemia, MAS was strongly suspected. Subsequently, a bone marrow biopsy was done which was consistent with MAS showing histiocytes with phagocytized hematopoietic cells and debris (Figure 1). Immunohistochemistry and phenotyping of the bone marrow specimen did not reveal any evidence of leukemia or lymphoma.

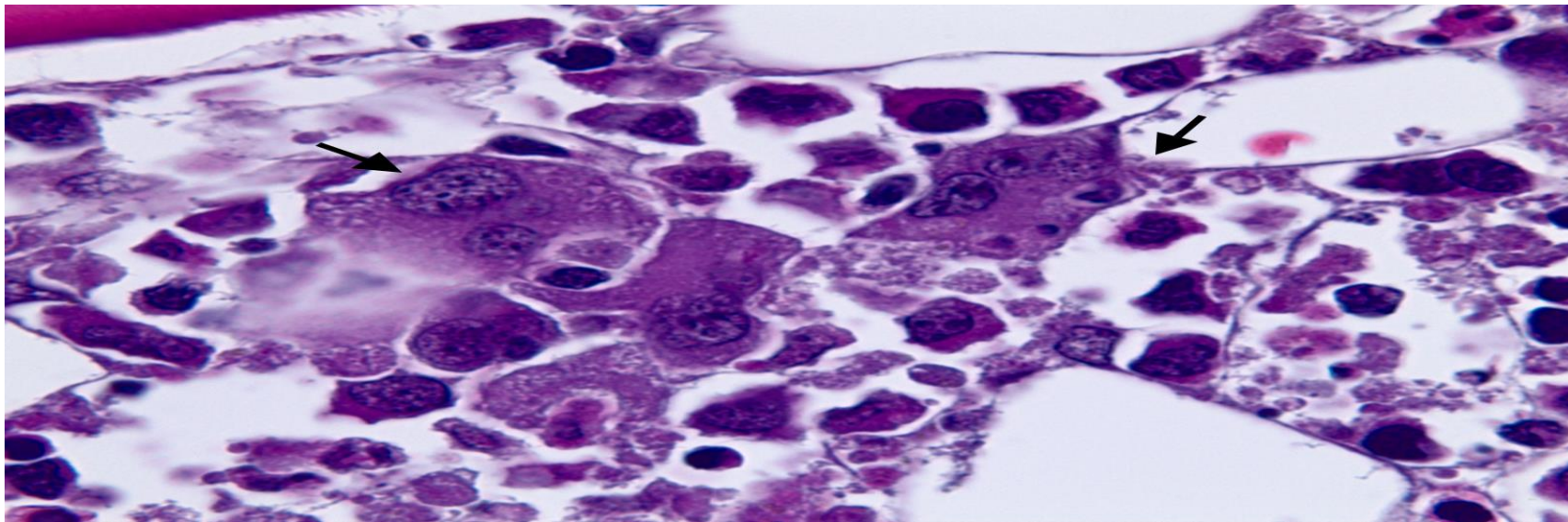


Figure 1. Bone marrow biopsy showing multinucleated histiocytes (shown by arrows) with phagocytosed hematopoietic cells and debris consistent with the diagnosis of macrophage activation syndrome.

Subsequently, the patient was started on IV pulse methylprednisolone 1000 mg daily for 3 days following which there was a significant improvement both clinically as well as with laboratory function tests. The patient was started on anakinra 100 mg subcutaneously and IV methylprednisolone 60 mg twice daily for treatment of the MAS. Unfortunately, after 3 days of treatment with anakinra, the patient developed fevers with acute respiratory distress. Chest X-ray showed a new lung infiltrate and sputum cultures revealed *Klebsiella* pneumonia. Anakinra was discontinued and IV methylprednisolone was continued. With IV antibiotics the patient's pneumonia improved. He was continued on IV methylprednisolone taper. After a prolonged and complicated hospital course lasting 3 months, he was finally discharged to a rehabilitation facility. He was discharged on hydroxychloroquine 400 mg daily and IV methylprednisolone 15 mg twice daily. During his rehabilitation stay, he was transitioned to oral prednisone taper. Over the next few months, he continued to improve clinically and regained his physical strength and was able to function independently. He was started on 500 mg oral mycophenolate mofetil twice daily and is currently doing well on this as well as 2.5 mg oral prednisone daily and hydroxychloroquine 400 mg daily.

Discussion

Macrophage activation syndrome (MAS) is a life-threatening complication that is classified among the group of histiocytic disorders called hemophagocytic lymphohistiocytosis (HLH).^{1,2} The incidence of MAS in autoimmune rheumatic disorders is 4.2% and the mortality is 40%.³ MAS was first described in a case of systemic-onset juvenile rheumatoid arthritis by Hadchouel et al.⁴ It is commonly seen as a complication of systemic-onset juvenile idiopathic arthritis (SJIA), Kawasaki disease, SLE, adult-onset Still's disease (AOSD), rheumatoid arthritis (RA), ankylosing spondylosis (AS), sarcoidosis and dermatomyositis.⁵ The prevalence of MAS among SLE patients ranges from 0.9% - 4.6%.^{2,6}

The exact pathogenesis of MAS is not fully understood but is hypothesized to involve uncontrolled activation and proliferation of natural killer (NK) and cytotoxic T cells within the reticuloendothelial system resulting in a hyper-inflammatory state.⁷ This immune dysregulation results in a surge of macrophage colony-stimulating factor (M-CSF) and Th1 cytokines (interferon- γ , interferon- α , interleukin-1, interleukin-6), promoting inappropriate activation of macrophages resulting in various clinical features of MAS.⁸

The clinical symptoms and signs of MAS may include persistent fever, splenomegaly, hepatomegaly, renal involvement, mental status changes, and hemorrhagic manifestations.⁹ Laboratory abnormalities may include bi-cytopenia or pancytopenia, hypofibrinogenemia, hypertriglyceridemia, hyperferritinemia, and transaminitis. Numerous macrophages containing phagocytized cell elements (typically leukocytes or erythrocytes) can be seen on bone marrow biopsy.^{10, 11} A key pathologic finding of HLH related disorders is the presence of hemophagocytes in the bone marrow, spleen or lymph nodes. However, the presence of hemophagocytes is not considered a pathognomic feature as it has a sensitivity up to 83% but a specificity of only 60%.¹² It should be noted that hyperferritinemia is the best indicator to distinguish MAS complicating SLE from SLE flare, with a high sensitivity and specificity.¹³

Modified HLH 2004 diagnostic criteria (Table 1), proposed by Henter et al, is a widely accepted guide used to diagnose MAS complicating SLE.¹⁴

TABLE 1. Revised Diagnostic Guidelines for HLH
<p>The diagnosis HLH can be established if one of either 1 or 2 below is fulfilled</p> <p>(1) A molecular diagnosis consistent with HLH</p> <p>(2) Diagnostic criteria for HLH fulfilled (≥ 5 of the 8 criteria below)</p> <p>Fever</p> <p>Splenomegaly</p> <p>Cytopenias (affecting ≥ 2 of 3 lineages in the peripheral blood):</p> <ul style="list-style-type: none"> -Hemoglobin < 90 g/L (in infants < 4 weeks: hemoglobin < 100 g/L) -Platelets $< 100 \times 10^9/L$ - Neutrophils $< 1.0 \times 10^9/L$ <p>Hypertriglyceridemia and/or hypofibrinogenemia:</p> <ul style="list-style-type: none"> -Fasting triglycerides ≥ 3.0 mmol/L (i.e. ≥ 265 mg/dl) -Fibrinogen ≤ 1.5 g/L <p>Hemophagocytosis in bone marrow or spleen or lymph nodes</p> <ul style="list-style-type: none"> -No evidence of malignancy <p>Low or absent NK-cell activity (according to local laboratory reference)</p> <p>Elevated ferritin (≥ 500 mg/L)</p> <p>Soluble CD25 (i.e., soluble IL-2 receptor) $\geq 2,400$ U/ml</p>

HLH = Hemophagocytic Lymphohistiocytosis, NK cell = Natural Killer cell.

According to the 2004 HLH criteria, MAS diagnosis is made when either molecular testing is done for gene mutation or when 5 out of 8 diagnostic criteria are met. The initial treatment of MAS includes control of the hyperinflammatory state with intravenous high dose pulse methylprednisolone, identification, and treatment of the underlying trigger as well as the use of biologic drugs such as infliximab, etanercept or rituximab (anti-CD20 monoclonal antibody).¹⁰ Anakinra, which is an interleukin-1 (IL-1) inhibitor, has become a more favored treatment option regardless of underlying autoimmune disorder.^{15, 16} Hematopoietic stem cell transplant (HCT) is the gold standard of treatment in genetic cases and familial HLH as it is the only curative option with survival rates of 50-70% at 5 years.¹⁷

In conclusion, MAS is a rare but fatal complication that can occur among autoimmune rheumatic disorders. Physicians should have a high degree of suspicion for diagnosing MAS in the setting of appropriate clinical symptoms and signs. Timely initiation of treatment is critical to prevent the high mortality rate.

References

1. George MR. Hemophagocytic lymphohistiocytosis: review of etiologies and management. *Journal of blood medicine*. 2014;5:69.
2. Fukaya S, Yasuda S, Hashimoto T, Oku K, Kataoka H, Horita T, et al. Clinical features of haemophagocytic syndrome in patients with systemic autoimmune diseases: analysis of 30 cases. *Rheumatology*. 2008;47(11):1686-91.
3. Boom V, Anton J, Lahdenne P, Quartier P, Ravelli A, Wulffraat NM, et al. Evidence-based diagnosis and treatment of macrophage activation syndrome in systemic juvenile idiopathic arthritis. *Pediatric Rheumatology*. 2015;(1):55.
4. Dubuc CA, Ecenarro MU, Villalba CM, Cáceres VA, Rubio IH, Otano JB. Hemophagocytic syndrome as the initial manifestation of systemic lupus erythematosus. *Reumatología Clínica (English Edition)*. 2014;10(5):321-4.
5. Bennett TD, Fluchel M, Hersh AO, Hayward KN, Hersh AL, Brogan TV, et al. Macrophage activation syndrome in children with systemic lupus erythematosus and children with juvenile idiopathic arthritis. *Arthritis & Rheumatism*. 2012;64(12):4135-42.
6. Parodi A, Davì S, Pringe AB, Pistorio A, Ruperto N, Magni-Manzoni S, et al. Macrophage activation syndrome in juvenile systemic lupus erythematosus: a multinational multicenter study of thirty-eight patients. *Arthritis & Rheumatism: Official Journal of the American College of Rheumatology*. 2009;60(11):3388-99.
7. Shah AR, Muzzafar T, Assi R, Schellingerhout D, Estrov Z, Tamamyam G, et al. Hemophagocytic lymphohistiocytosis in adults: an under recognized entity. *BBA clinical*. 2017;7:36-40.
8. Bihl F, Emmenegger U, Reichen J, Neftel KA, Zimmermann A, Cerny A. Macrophage activating syndrome is associated with lobular hepatitis and severe bile duct injury with cholestasis. *Journal of hepatology*. 2006;44(6):1208-12.
9. Minoia F, Davì S, Horne A, Demirkaya E, Bovis F, Li C, et al. Clinical features, treatment, and outcome of macrophage activation syndrome complicating systemic juvenile idiopathic arthritis: a multinational, multicenter study of 362 patients. *Arthritis & rheumatology*. 2014;66(11):3160-9.
10. Ravelli A, Magni-Manzoni S, Pistorio A, Besana C, Foti T, Ruperto N, et al. Preliminary diagnostic guidelines for macrophage activation syndrome complicating systemic juvenile idiopathic arthritis. *The Journal of pediatrics*. 2005;146(5):598-604.
11. Granata G, Didona D, Stifano G, Feola A, Granata M. Macrophage activation syndrome as onset of systemic lupus erythematosus: a case report and a review of the literature. *Case reports in medicine*. 2015;2015.
12. Goel S, Polski JM, Imran H. Sensitivity and specificity of bone marrow hemophagocytosis in hemophagocytic lymphohistiocytosis. *Annals of Clinical & Laboratory Science*. 2012;42(1):21-5.
13. Vilaiyuk S, Sirachainan N, Wanitkun S, Pirojsakul K, Vaewpanich J. Recurrent macrophage activation syndrome as the primary manifestation in systemic lupus erythematosus and the benefit of serial ferritin measurements: a case-based review. *Clinical rheumatology*. 2013;32(6):899-904.
14. Henter JI, Horne A, Aricó M, Egeler RM, Filipovich AH, Imashuku S, et al. HLH-2004: diagnostic and therapeutic guidelines for hemophagocytic lymphohistiocytosis. *Pediatric blood & cancer*. 2007;48(2):124-31.
15. Durand M, Troyanov Y, Laflamme P, Gregoire G. Macrophage activation syndrome treated with anakinra. *The Journal of Rheumatology*. 2010;37(4):879-80.
16. Kelly A, Ramanan AV. A case of macrophage activation syndrome successfully treated with anakinra. *Nature Clinical Practice Rheumatology*. 2008;4(11):615-20.
17. Schram AM, Berliner N. How I treat hemophagocytic lymphohistiocytosis in the adult patient. *Blood, The Journal of the American Society of Hematology*. 2015;125(19):2908-14.