

OLIVE CAKE IN THE FEEDING OF FATTENING RABBITS: HISTOPATHOLOGICAL CHANGES

V. Rupić, Svjetlana Luterotti, M. Čačić, Vlatka Romanović, Ivana Čačić

Summary

Nutritive effect of different levels (10% and 20%) of dried olive cake on the body mass, feed conversion ratio and histopathological changes in tissues in conventionally bred Hyla rabbits was investigated. During a 56-day experimental feeding regime, 60 rabbits were divided into a control group and two experimental groups with 20 animals each (10 males and 10 females). Control group received no olive cake, while the first experimental group received 10% and the second experimental group 20% of dried olive cake throughout the whole feeding period. No significant differences in the body mass were found between the groups in the trial. In both experimental groups, feed conversion was better than in the control group. Histopathological tests were performed on a total of 28 rabbits. Histopathological changes observed in the brain, heart and kidneys of rabbits were the consequence of pathological activity of microsporidian *Encephalitozoon cuniculi* found in all groups. In the rabbits of both experimental groups fed with olive cake, deposition of fat in the heart, liver, lymph nodes, thyroid gland, adrenal gland and pancreas might be explained by the greater amount of fat from olive oil in the meal. Statistically significant was only the fat deposition in the liver, namely, in hepatocytes. Histopathological screening identified pathological action of fungus *Cyniclomyces guttulatus* in the digestive tract of all rabbit groups which caused inflammation of the mucous membranes (enteritis) of the entire digestive system (from the stomach to the large intestine) and therefore possibly interfered with the absorption of certain nutrients (vitamins, minerals, etc.).

Key words: rabbits, nutrition, olive cake, histopathological changes

Introduction

Cultivation of olives has a long-standing tradition in many countries throughout the world, but it is particularly well developed in the Mediterranean area. Olive cake is the industrial by-product left following the extraction of oil from olives. Considerable quantities of olive cake can be used as food for certain categories of livestock. Alternatively, they are simply deposited in the garden area around olive trees, where due to their long period of degradation, they pollute the environment for prolonged period of time. For certain species of animals (ruminants, rabbits, etc.) olive cake can be used as food in somewhat greater quantities, while for chicken and pigs olive cake should be used in a smaller portion of their daily diet. Depending on the technological procedure used in the extraction of olive oil, the olive cake contains 3.5 – 8.5% of oil and 2.5 – 6.0% of crude proteins but also some other nutrients (Manoukas et al., 1973; Rupić et al., 1992; Vešnik et al., 1993, 1994).

Vlatko Rupić, PhD, DVM., Ivana Čačić, mag.chem., Faculty of Agriculture, Department of Animal Science, University of Zagreb, Svetošimunska cesta 25, 10000 Zagreb, Croatia; Svjetlana Luterotti, PhD, Faculty of Pharmacy and Biochemistry, University of Zagreb, Ante Kovačića 1, 10000 Zagreb, Croatia; Mato Čačić, PhD, Ministry of agriculture of Republic of Croatia, Ulica grada Vukovara 78, 10000 Zagreb, Croatia; Vlatka Romanović, mag.educ.biol. et chem., Secondary school, Stjepana Ferenčaka 25, 10370 Dugo Selo, Croatia; E-mail: vlatko.rupic@zg.htnet.hr

Olive cake also contains a high volume of crude fiber (220 – 350 g/kg) which can be harmful when used in poultry and pig diet but is beneficial to ruminants and rabbits. When obtained by using the centrifugal separation process (Van Soest, 1975; Martilotti, 1983; Sansoucy, 1985) olive cake retains a high content of water (430 – 570 g/kg) and it is therefore necessary for it to be allowed to drain well before it is used as food. When added to feed mixtures, however, it should be completely dried.

Most of the studies carried out to date were focused on the use of olive cake in the feeding of ruminants (Belibasakis, 1984, 1991; Nefzaoui and Vanbelle, 1986; O'Donovan, 1984; Boucque and Fiemes, 1986; Omar and Gavoret, 1995; Datillo and Congiu, 1995; Christaki et al., 1995, Kostelić, 2003, Mioč et al., 2007; Molina-Alcaide and Yanez-Ruiz, 2008; Sadeghi et al., 2009; Vera et al., 2009, 2013; Gül et al., 2010; Estaun et al., 2014).

Only few research projects have dealt with pigs (Rupić et al., 1997; Joven et al., 2014; Garcia-Casco et al., 2017; Ferrer et al., 2018) and poultry (Amici et al., 1991; Rupić et al., 1992; Christaki et al., 1994; Georgopoulou, 1994; Rabayaa, 2000; Abo-Omar, 2000, 2005; Zangeneh and Toriki, 2011; El-Samee and Hashish, 2011, Al-Harhi, 2016).

Available literature offers only limited data related to the use of olive cake as food for rabbits, in particular for fattened rabbits. Feeding experiments with olive cake in fattening rabbits were conducted by Rayan et al. (1994), Chaabane et al. (1997), Rupić et al. (1999a, 1999b), Lebas (2004), Kadi et al. (2004), Dal Bosco et al. (2007, 2012), Tsantila et al. (2010), Nasopoulou and Zabetakis (2013), Dorbane et al. (2016, 2019).

The aim of the present study was to establish nutritive effects of large quantities (10% and 20%) of dried olive cake, that is to say, of its chemical composition, on the health of conventionally farmed rabbits, based on histopathological changes of tissues in fattened Hyla rabbits throughout the 56-day experimental period.

Materials and methods

Animals and feeding régime

Sixty (30 males and 30 females) 30-day-old weaned Hyla rabbits were used. The rabbits were divided into 3 groups, each group comprising 20 animals: a control group (C) and two experimental groups (E_1 and E_2). All the rabbits were marked with numbers from 1 to 60, tattooed on the right ear. Each rabbit group (10 males and 10 females) was housed in a stainless steel cage, all three located in the same room and on the top of each battery. The room was air-conditioned with temperature maintained at 18 to 20 °C and relative humidity between 60 and 70%. In order to decrease the risk of infection, all cages and equipment were treated with a chlorine disinfectant prior to the experiment.

Rabbits of all groups in the assay were weighed every 7 days throughout the experimental period. Initial body mass of group C rabbits was 666.2 ± 79.0 g, while the masses of the rabbits in two experimental groups were 659.9 ± 83.4 g (E_1) and 648.3 ± 82.3 g (E_2) (n=20 in each group). No significant differences were found at significance level of $p \leq 0.01$.

Throughout the entire 56-day experimental period, the rabbits were fed the feed mixtures described in Tables 1 and 2; group C rabbits received food containing no olive cake, while those

in group E₁ received food containing 10% and group E₂ containing 20% of dried olive cake. The feed conversion was followed throughout the experimental period of 8 weeks; it was calculated as the ratio of the feed consumed and the average body mass gain in each group for each week.

The rabbits used in this study were maintained in facilities approved by the Croatian Association for the Accreditation of Laboratory Animals Care, and in accordance with current regulations and standards as laid down by the Croatian Ministry of Agriculture. Bioethical Committee for Animals Protection and Welfare of the Faculty of Agronomy, University in Zagreb, Croatia, released the approval to perform the experiments (Class: 114-04/18-03/01: Number: 251-71-29-02/11-18-1).

Feed mixtures

Olive cake from the Punat oil mill (island Krk, Croatia) was used. It was obtained by centrifugal separation process (Martilotti, 1983). Fresh olive cake, containing 487.2 g/kg of water, was dried at a temperature of 35 °C to a water content of 19.5 g/kg. Then it was reduced to 2-mm sized particles in a hammer mill. All conventionally bred rabbits involved in the experiment were fed with pelleted feed mixture from automatic feeders. Water was provided *ad libitum* from automatic dispensers.

Feed mixtures were prepared separately from each other; mixtures E₁ and E₂ contained 10 and 20%, resp., of dried olive cake. Animal feed, olive cake and feed mixtures were analyzed according to official HRN ISO directives (Tables 1 and 2).

The content of amino acids in dried olive cake ranged 0.2-6 g/kg by analysis (Csapó et al, 1986) and calculational estimates in the control feed mixture (Rhone-Poulenc, 1993) 3-14 g/kg (Tables 1 and 2). In fact, contrary to the calculational values, after mixing, somewhat lowered levels of amino acids in the feed mixtures E₁ and E₂ should have been expected compared to the initial feed, followed by the crude protein content. On the contrary, crude fat content increased in feed mixture E₁ and particularly in E₂ group feed mixture, compared to the control (Table 2).

Table 1 Ingredients of olive cake pulp (g/kg in original matter)

Tablica 1. Sastav komine masline (g/kg u originalnoj tvari)

	Water	Ash	Crude protein	Crude fat	Crude fibre	NFE	Ca	P	Amino acid*														
Fresh olive cake	487.2	8.1	27.9	39.2	259.8	177.8	0.7	0.4	Methionine	Lysine	Threonine	Arginine	Glycine	Histidine	Phenyl-alanine	Leucine	Isoleucine	Valine	Serine	Tyrosine	Alanine	Glutamine	Asparagine
Dried olive cake	19.5	15.6	53.4	75.0	497.0	339.5	1.4	0.8	0.20	0.70	2.80	2.40	3.10	0.70	2.70	4.20	2.30	3.30	2.90	0.60	2.90	6.00	4.00

NFE - nitrogen-free extract

*Analyses data (Csapó et al., 1986)

Table 2 Ingredients and chemical composition of feed mixtures

Tablica 2. Sadržaj i kemijski sastav krmnih smjesa (peleta)

Ingredient	Group of animals (% as fed)		
	C (control)	E ₁	E ₂
Dried olive cake	0.00	10.00	20.00
Corn	28.40	31.90	34.70
Barley meal	5.00	3.00	3.00
Wheat middlings	6.00	5.00	6.00
Soya-bean meal	0.00	10.00	17.40
Sunflower meal	18.50	11.00	8.00
Dehydrated alfalfa meal	41.00	27.80	9.00
Dibasic calcium phosphate	0.00	0.00	0.20
Limestone	0.30	0.50	0.90
Sodium chloride	0.30	0.30	0.30
Mineral-vitamin mix	0.50	0.50	0.50
Total	100.00	100.00	100.00
<i>Analysis as fed, dry matter basis (g/kg)*</i>			
Dry matter	881.00	888.10	887.60
Crude protein	224.70	226.80	224.20
Crude fat	42.50	43.90	52.95
Crude fiber	197.20	202.50	189.50
Ash	67.65	63.10	53.00
Nitrogen-free extract (NFE)	348.95	351.80	367.95
Ca	10.44	9.35	8.56
P	7.38	6.19	5.97
Metabolic energy(ME) (MJ/kg)**	12.86	12.71	12.62
<i>Amino acid (g/kg)***</i>			
Methionine	3.30	3.10	3.00
Lysine	6.70	7.80	8.50
Threonine	6.90	7.00	6.80
Arginine	10.80	11.10	11.80
Glycine	9.00	8.20	7.60
Histidine	4.20	4.30	4.30
Phenylalanine	8.90	8.70	8.50
Leucine	13.60	13.80	13.60
Isoleucine	8.00	8.00	7.70
Valine	8.60	11.00	14.90
Serine	6.90	10.40	13.60
Tyrosine	5.10	6.50	7.90

ME - metabolic energy, NFE - nitrogen-free extract

*A.O.A.C. methods (2005)

**Calculated data (Allen, 1993)

***Calculated data (Rhône Poulenc Animal Nutrition, 1993)

Histopathological examinations

Histopathological tests were performed on a total of 28 rabbits, randomly chosen, namely, 9 rabbits (5 males and 4 females) in each the control group (C) and first experimental group (E_1), and 10 rabbits (5 males and 5 females) in the second experimental group (E_2).

After experiment completion and 12 hours of starvation, all the abovementioned rabbits were sacrificed under narcosis. From all the sacrificed rabbits the following tissues were sampled: lung, heart, hepatic tissue (liver), renal tissue (kidney), spleen, lymph nodes (*ln. mandibulares*, *ln. mesenterici*, *ln. prescapulares*), the large and small brain (cerebrum and cerebellum), thyroid gland, pancreas, adrenal gland, skeletal muscle, testicles and ovaries, gastric tissue (stomach), duodenum, jejunum, ileum and colon (large intestine). The tissue of each rabbit was sampled for histopathological analysis immediately after bleeding out. Samples were sugar-cube sized, depending on the size of the organ. Samples were fixed in 10% of neutral protein formalin solution at the room temperature. After fixation, the samples were frozen 24 - 48 hours and then cut into slices with thickness of 4-6 mm with freezing microtome after which they were dyed with the hematoxylin and eosin (HE method). The slides were viewed with Carl Zeiss laboratory research microscope and images were captured using Kodak camera, Ektachrome 64 T, EPY-36 film. Results of histopathological analyses are shown in Table 3.

Statistics

One-way ANOVA analysis of variance (GLM procedure) (SAS, 1989) and non-parametric chi-square test were applied. Statistical significance was set at $p < 0.05$ and $p \leq 0.01$.

Results

Body masses and feed conversion

After 56 days of feeding, the following mean body masses were achieved: 2334.5 ± 186.3 g (C), 2341.0 ± 222.1 g (E_1) and 2397.5 ± 187.7 g (E_2) (Rupić et al., 1999a, 1999b). No significant differences in body mass between group C and the experimental groups were found. In the course of the experiment (0-8 weeks), rabbits in the control group (C) consumed a total of 7042.3 g of feed per rabbit, or a daily average of 125.7 g per rabbit, rabbits in the test group E_1 consumed a total of 6673.2 g of food per rabbit, or a daily average of 119.2 g per rabbit, whereas the rabbits in the test group E_2 consumed 6699.7 g of food per rabbit, or a daily average of 119.6 g per rabbit. Throughout the experimental period feed conversion (kg/kg) reached, on an average, the overall values of 4.22, 3.97 and 3.83 for groups C, E_1 and E_2 , resp. Feed conversion value raised gradually with time, with the biggest jump observed in the 6th week of the trial (data not shown). Rabbits fed with 10% olive cake (E_1), and particularly those consuming 20% olive cake (E_2) in their daily feed, manifested somewhat better, still not significantly, feed conversion, than rabbits in group C, whose feed mixture contained no olive cake. This clearly follows from the fact that rabbits in groups E_1 and E_2 gained higher body masses by consuming lower feed intake. This corroborates well with the chemical composition of the respective feed mixtures.

Table 3 Histopathological analyses of tissues in control and experimental groups of rabbits
Tablica 3. Histopatološka analiza tkiva u kontrolnoj i pokusnim skupinama kunića

Tissue/ exp. group	Frequency of histopathological changes			Statistical inference*
	C	E ₁	E ₂	
Stomach	4/9 desq. muc. gastritis	4/9 desq. muc. gastritis	2/10 desq. muc. gastritis	C/E ₁ /E ₂ : NS
CG†	0/9 hyperplastic gastritis	0/9 hyperplastic gastritis	2/10 hyperplastic gastritis	C/E ₁ /E ₂ : NS
Duodenum	2/9 desq. muc. duodenitis	2/9 desq. muc. duodenitis	1/10 desq. muc. duodenitis	C/E ₁ /E ₂ : NS
CG†	0/9 necrotizing duodenitis	0/9 necrotizing duodenitis	9/10 necrotizing duodenitis	C/E ₁ /E ₂ : $p=8.95 \times 10^{-5}$, S C vs. E ₁ : NS C/E ₁ vs. E ₂ , $p=5.34 \times 10^{-4}$, S
Jejunum	1/9 desq. muc. jejunitis	1/9 desq. muc. jejunitis	3/10 desq. muc. jejunitis	C/E ₁ /E ₂ : NS
CG†	0/9 necrotic jejunitis	0/9 necrotic jejunitis	1/10 necrotic jejunitis	C/E ₁ /E ₂ : NS
Ileum	1/9 muc. ileitis	1/9 desq. muc. ileitis	1/10 desq. muc. ileitis	C/E ₁ /E ₂ : NS
CG†	0/9 necrotizing ileitis	0/9 necrotizing ileitis	2/10 necrotizing ileitis	C/E ₁ /E ₂ : NS
Large intestine	1/9 desq. muc. colitis	1/9 desq. muc. colitis	0/10 desq. muc. colitis	C/E ₁ /E ₂ : NS
CG†	0/9 necrotizing colitis	0/9 necrotizing colitis	2/10 necrotizing colitis	C/E ₁ /E ₂ : NS
Lung	0/9 anthracosis	3/9 anthracosis	5/10 anthracosis	C/E ₁ /E ₂ : NS
	4/9 emphysema	1/9 emphysema	2/10 emphysema	C/E ₁ /E ₂ : NS
	4/9 pneumonia	4/9 pneumonia	5/10 pneumonia	C/E ₁ /E ₂ : NS
	0/9 hyperplasia	1/9 hyperplasia	1/10 hyperplasia	C/E ₁ /E ₂ : NS
Heart EC‡	3/9 myocarditis	5/9 myocarditis	5/10 myocarditis	C/E ₁ /E ₂ : NS
	0/9 fat deposition	1/9 fat deposition	1/10 fat deposition	C/E ₁ /E ₂ : NS
	6/9 hepatitis	7/9 hepatitis	10/10 hepatitis	C/E ₁ /E ₂ : NS
Liver	0/9 fatty hepatocyte inf.	7/9 fatty hepatocyte inf.	10/10 fatty hepatocyte inf.	C/E ₁ /E ₂ : $p=2.13 \times 10^{-4}$, S C vs. E ₁ : $p=3.72 \times 10^{-3}$, S C vs. E ₂ : $p=9.67 \times 10^{-5}$, S E ₁ vs. E ₂ : NS
Kidney EC‡	1/9 glomerulo-nephritis	3/9 nephritis	5/10 nephritis	C/E ₁ /E ₂ : NS
	3/9 tubulo-nephrosis	0/9 tubulo-nephrosis	1/10 tubulo-nephrosis	C/E ₁ /E ₂ : NS
	0/9 glomerulo-nephrosis	0/9 glomerulo-nephrosis	1/10 glomerulo-nephrosis	C/E ₁ /E ₂ : NS
Spleen	0/9 hemosiderosis	0/9 hemosiderosis	1/10 hemosiderosis	C/E ₁ /E ₂ : NS
	0/9 lymphopenia	0/9 lymphopenia	1/10 lymphopenia	C/E ₁ /E ₂ : NS
	3/9 hyperplasia	6/9 hyperplasia	6/10 hyperplasia	C/E ₁ /E ₂ : NS
Lymph nodes	6/9 hyperplasia	5/9 hyperplasia	4/10 hyperplasia	C/E ₁ /E ₂ : NS
	0/9 fat deposition	0/9 fat deposition	3/10 fat deposition	C/E ₁ /E ₂ : NS
Cerebrum/ cerebellum EC‡	3/9 meningo-encephalitis	4/9 meningo-encephalitis	5/10 meningo-encephalitis	C/E ₁ /E ₂ : NS

Thyroid gland	1/9 goitr	0/9 goitre	2/10 goitre	C/E ₁ /E ₂ : NS
	2/9 hypertrophy	0/9 hypertrophy	0/10 hypertrophy	C/E ₁ /E ₂ : NS
	0/9 interf. hyperplasia	3/9 interf. hyperplasia	3/10 interf. hyperplasia	C/E ₁ /E ₂ : NS
Pancreas	0/9 fat deposition	0/9 fat deposition	1/10 fat deposition	C/E ₁ /E ₂ : NS
	1/9 pancreatitis	0/9 pancreatitis	0/10 pancreatitis	C/E ₁ /E ₂ : NS
	0/9 hypertrophy, hyperplasia	1/9 hypertrophy, hyperplasia	0/10 hypertrophy, hyperplasia	C/E ₁ /E ₂ : NS
	0/9 parenh. deg., pancreolysis	1/9 pancreolysis	2/10 pancreolysis	C/E ₁ /E ₂ : NS
	0/9 fat deposition	2/9 fat deposition	0/10 fat deposition	C/E ₁ /E ₂ : NS
	0/9 epit. cells atrophy	1/9 epit. cells atrophy	0/10 epit. cells atrophy	C/E ₁ /E ₂ : NS
	Adrenal gland	2/9 hyperaemia	0/9 hyperaemia	0/10 hyperaemia
0/9 hyperplasia		1/9 hyperplasia	4/10 hyperplasia	C/E ₁ /E ₂ : NS
0/9 fatty infiltration		1/9 fatty infiltration	1/10 fatty infiltration	C/E ₁ /E ₂ : NS
Skeletal muscles CG [†]	3/9 fiber hyaline deg., dys.	3/9 fiber hyaline deg., dys.	3/10 fiber hyaline deg., dys.	C/E ₁ /E ₂ : NS
Genitals (testicle, ovary)	0/9 pathol. changes	0/9 pathol. changes	0/10 pathol. changes	no pathol. changes

C - control group, E₁, E₂ - experimental groups, deg. – degenerative, desq. - desquamative, dys. – dystrophy, inf. – infiltration, interf. – interfollicular, muc. – mucinous, paren. – parenchymatous, pathol. – pathological, NS, S – statistically (non)significant.

*Significance level set at $p < 0.01$: chi-square test (Yates correction).

†CG - Fungus *Cyniclomyces guttulatus* in C, E₁, E₂; ‡EC - Microsporidian *Encephalitozoon cuniculi* in C, E₁, E₂.

Histopathological findings

The major changes in the tested tissues were observed in group E₂, and in E₁ to a lesser extent, relative to group C (Table 3). The most differences were found in duodenum (significant necrotizing duodenitis only in E₂), lungs (anthracosis in E₁ and E₂), fat deposition in liver, lymph nodes, heart, pancreas, thyroid and adrenal glands (the only significant fat infiltration in hepatocytes in both E₁ and E₂). Histopathological analyses of skeletal muscles, genitals (testicles and ovaries) and cerebrum/cerebellum did not show differences between groups, but some tissues like gastrointestinal tract showed small, non-significant changes like hyperplastic gastritis, necrotic jejunitis, ileitis and colitis. The signs of nephritis, pancreolysis and hyperplasia of adrenal glands were sporadically observed in the experimental groups.

Histopathological changes were diagnosed in all parts of the gastrointestinal tract (stomach, duodenum, jejunum, ileum and colon), in rabbit groups E₁ and E₂, and also in the rabbits of control (C) group. High significance in χ^2 test indicated necrotizing duodenitis in E₂ but not in C and E₁ groups. Similarly, although detected in both E₁ and E₂ groups, mononuclear lymphocytic hepatitis might have been significant in E₂ only (data not shown). Fatty infiltration was found highly significant in hepatocytes in both E₁ and E₂ compared to the control group, the effect being directly dose dependent (Fig. 3).

Moreover, fungus *Cyniclomyces guttulatus* (Fig. 1) was detected throughout the whole digestive tract and in skeletal muscles, whereas microsporidian *Encephalitozoon cuniculi* was found in brain, kidney and heart, in animals of all three groups (Fig. 2).

Discussion

Body mass gain

It may be assumed that different proportions of olive cake added to the animal feed had no significant effect on the final body mass of the fattened rabbits. Feed conversion differed between the three groups. In fact, rabbits in the control group consumed the larger quantity of feed than the groups E₁ and E₂. Interestingly, the E₁ and E₂ animals showed bigger body mass gain, still not significant (data not shown), than group C at the end of the experiment. This data indicates that the increased quantities of dried olive cake (10% and 20%) used in a daily diet decreased feed consumption in fattened rabbits but improved animal body mass gain. This might be due to the more efficient feed conversion in groups E₁ and E₂ than in group C, this effect being directly dose dependent. In fact, it might be assumed that increased fat intake in feed mixtures in E₁ and E₂ was the only factor responsible for body mass gain and fat infiltration in several tissues.

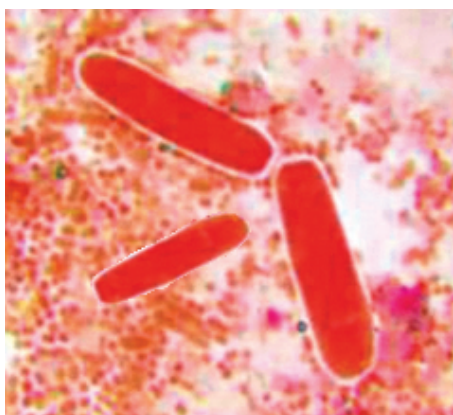


Figure 1 *Cyniclomyces guttulatus* on the mucous membrane of jejunum of rabbits (HE stain, 40X)

Slika 1. *Cyniclomyces guttulatus* na sluznici jejunuma kunića (HE bojanje, 40X)

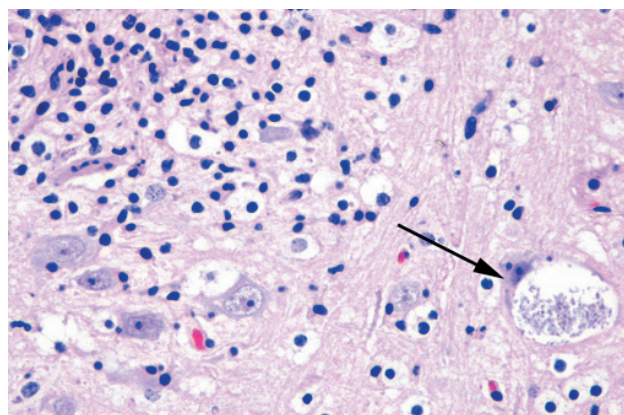


Figure 2 Intracellular cyst of *Encephalitozoon cuniculi* in brain marked with arrows (HE stain, 40X)

Slika 2. Unutarstanična cista *Encephalitozoon cuniculi* u mozgu kunića označena strelicom (HE bojanje, 40X)

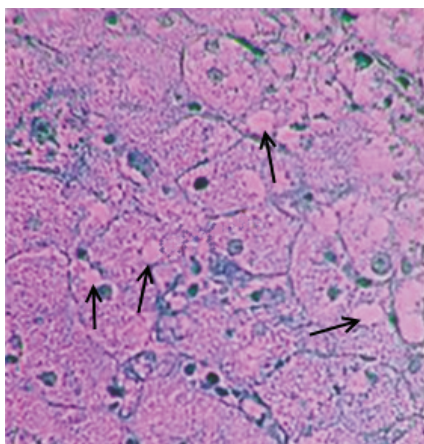


Figure 3 Fatty infiltration, degeneration and apoptosis of hepatocytes (marked with arrows) in the test (E₁ and E₂) rabbit groups fattening with olive cake in feed mixture (HE stain, 40X)

Slika 3. Infiltracija masti, degeneracija i apoptoza hepatocita (označeno strelicama) u pokusnim skupinama kunića (E₁ i E₂) hranjenih krmnom smjesom s dodatkom sušene komine masline (HE bojanje, 40X).

Histopathological changes

The observed histopathological change found in the heart is subepicardial deposition of fat in only two individual rabbits from groups E₁ and E₂. Diagnosed diffuse and centrolobular fatty hepatocytes degeneration of varying degrees, found only in the rabbits from the test groups (E₁ and E₂), was also result of feeding rabbits with feed mixtures containing 10 and 20% of olive cake (Figure 3). Moreover, in 3 animals within E₂ group we found deposition of fat in the interstitial lymph nodes as a result of feeding olive cake and increased quantities of olive oil in the diet.

By the histopathological examination, pathological changes were determined in the brain of 3 rabbits from the control group whereas in the first (E₁) test group 4 rabbits had changes and 5 had changes in the second (E₂) group. In all groups microsporidian *Encephalitozoon cuniculi* was detected (Figure 2). Pathological activity of microsporidian *Encephalitozoon cuniculi* might be responsible for histopathologic changes found in the brain, heart and kidneys in rabbits of all groups. The more so, since in the rabbit groups which were fed with the olive cake, we found increased number of animals with pathological changes compared to the control group.

In the thyroid gland of 2 rabbits from the control group (C), 3 rabbits from the first (E₁) and 5 rabbits from the second (E₂) test group histopathological changes were determined (interfollicular hyperplasia and cystic goiter). The findings in the latter group might be indicative of possible disturbance in the thyroid gland functioning. This assumption needs to be confirmed by the new research on rabbits fed with increased (20% and more) amount of olive cake and/or prolonged fattening period. This would help us to follow thyroid gland activity and determine activity of its hormones (thyroxine, triiodothyronine, also known as T3). Only in 1 rabbit from the group E₂ deposition of fat was found in the thyroid gland interstitium.

Only 1 rabbit from control (C) group was detected with histopathological changes in the pancreas while in 3 rabbits from the first (E₁) test group and 2 rabbits from second (E₂) test group we found histopathological changes in the form of hypertrophy, hyperplasia, atrophy, degeneration and parenchymal pancreolysis. These findings require additional studies to be carried out to control the exocrine pancreatic secretion in rabbits fed with different amounts of olive cake. In the rabbits from experimental group E₁ a deposition of fat was found in the interstitial connective tissue.

Histopathological changes in the adrenal gland (hyperplasia of granulomatosae zone) were found in 2 rabbits from control (C) group, in 1 animal from E₁ group and in 4 animals from E₂ group indicating the need for additional adrenal glands research and determining the activity of its hormones (glucocorticoids and mineralocorticoids) during nutrition enriched with 10 and 20% olive cake meal. Fatty infiltration of fasciculatae cells was found in the same rabbits in E₁ and E₂.

In 3 rabbits from the control (C) and in 3 rabbits from each test group (E₁ and E₂) circumscribed focal hyaline degeneration of skeletal muscle fibers was found, which was possibly due to deficiency of vitamin E and selenium in the organism. Impaired absorption of the nutrients resulted from the damaged small and large intestine membrane probably as a result of the pathological activity of *Cyniclomyces guttulatus* (Figure 1). The same applies to histopathological changes observed in all parts of the gastrointestinal tract (stomach, duodenum, jejunum, ileum and colon), in all rabbit groups. This is in agreement with our previous report (Rupić, 2009).

Shown in Table 3 is that in both test rabbit groups together (E_1+E_2), we found four times as many cases of rabbit enteritis compared to the control group. The same applies to group E_2 versus the control group. The literature mentions that the desquamative and mucinous gastroenteritis could be caused by fungus *Cyniclomyces guttulatus* (Figure 1) blastospores. Although some scientists consider that this fungus is not pathogenic for rabbits, the relevant literature and numerous researchers reported pathogenic activity of *Cyniclomyces guttulatus*, especially for young domestic and wild rabbits and other animal species (Zierdt et al., 1988; Houwers and Blankenstein, 2001; Hersey-Benner, 2008; Peters and Houwers, 2009; Saito et al., 2009; Flausino et al., 2012). On the basis of histopathological analyses carried out in this research *Cyniclomyces guttulatus* was found in all parts of the digestive tract in large number of rabbits from all three groups (C, E_1 and E_2). Therefore it might be assumed as responsible for enteritis in all parts of the digestive tract of rabbits in fattening trial of 56 days. In rabbits from first (E_1) and second (E_2) test groups fed with the olive cake in the ration, the incidence of enteritis increased; however, it was significant in duodenum only.

Histopathological changes were not found in the genitals (testicles and ovaries) of male and female rabbits of all groups in the experiment (C, E_1 and E_2) showing that olive cake used in the meals does not affect the sexual organs.

Conclusions

On the basis of the research on the possibility of using 10% and 20% of dried olive cake in Hyla rabbit nutrition during fattening period of 56 days, no detrimental nutritional impact of dry olive cake on body mass gain and feed conversion was established. Rabbits fed on 10% olive cake (E_1), and particularly those consuming 20% olive cake (E_2) in their daily feed, showed better, still not significantly, food conversion than control group rabbits.

However, histopathological examinations showed numerous pathological changes in almost all tissues, the significant ones been found in duodenum (necrotizing duodenitis in E_2) and liver (hepatocytes fatty infiltration in E_1 and E_2) only.

Since fungus *Cyniclomyces guttulatus* was found in the control and both experimental groups (Figure 1) throughout the digestive tract, starting from the stomach up to the rectum, we are inclined to believe that the olive cake did not affect the increase of *Cyniclomyces guttulatus* in E_1 and E_2 groups, but, possibly, preserved its pathological activity in the entire digestive system of rabbits.

Additional experiments are needed to shed more light on the metabolic and histopathologic implications of olive cake-enriched nutrition in Hyla rabbits, namely, to make fully clear its toxicological and safety profile.

REFERENCES

1. Abo-Omar, J. (2000): Effect of different levels of olive pulp on the digestibility of broiler chicks. Bethlehem. Univ. J., 12:34–40.
2. Abo-Omar, J. (2005): Carcass composition and visceral organ mass of broiler chicks fed different levels of olive pulp. Journal of Islamic Univ. Gaza, 13:75–84.
3. Al-Harhi, A. M. (2016): The efficacy of using olive cake as a by-product in broiler feeding with or without yeast. Italian Journal of Animal Science, 15(3):512-520.

4. Allen, R. (1993): Ingredient analysis table. *Feedstufte*, Issue 65: 24-37.
5. Amici, A., M. Verna, F. Martillotti (1991): Olive by-products in animal feeding: improvement and utilization. *Opt Méditerranéennes – Ser Seminnar*, 16:149–152.
6. AOAC (2005); Official methods of analysis of AOAC International.' 18th ed. (AOAC International: Gaithersburg, MD).
7. Belibasakis, N.G. (1984): Olive cake pulp as feed for lactating cows. *World Review of Animal Production*, 20:7-10.
8. Belibasakis, N.G., D. Kuhdis, I. Psomas, D. Zygoiannis (1991): Effect of olive cake pulp feeding on the growth performance and some characteristics of finishing bulls. *World Review of Animal Production*, 26:61-64.
9. Boucqué, Ch.V., O.L. Fiemes (1986): Vegetable by-products of agro-industrial origin. EAAP Working Group. Revised draft. Brussels, June 1986, Chapter 2.4.1, 1-51.
10. Csapó, J., Zs. Csapó-Kiss, I. Toth-Posfai (1986): Optimization of hydrolysis determination of amino acid content in food and feed products. *Acta Alimentaria (Hungary)*, 1:3-21.
11. Chaabane, K, R. Bergaoui, M. Ben Hammouda (1997): Utilisation de differents types de grignons d' olive dans l' alimentation des lapereaux. *World Rabbit Science*, 5:17-21.
12. Christaki, E., L.A. Yannakopoulos, P. Florou-Paneri, S.D. Kufidis, E. Georgopoulou (1994): Effect of olive pulp on the performance of laying hens. *Proceedings of the 9th European Poultry Conference*, August 7-12, 1994, Glasgow, Great Britain, 501-502.
13. Christaki, E., L.A. Yannakopoulos, P. Florou-Paneri, S.D. Kufidis, M. Datilo, F. Congiu (1995): Effects of olive cake on the productivity of sheep and the amino acid composition of their meat. *Protein metabolism and nutrition. Proceedings 7th International Symposium, Vale de Santarem, Portugal, May 24 – 27, 1995, EAAP Publication No. 81., 47: 119.*
14. Dal Bosco, A., C. Catellini, R. Cardineli, E. Mourvaki, L. Moscati, L. Battistacci, M. Servili, A. Taticchi (2007): Olive cake dietary supplementation in rabbit: immune and oxidative status. *Italian Journal of Animal Science*, 6(1):761-763.
15. Dal Bosco, A., E. Mourvaki, R. Cardinali, M. Servili, B. Sebastiani, S. Ruggeri, S. Mattioli, A. Taticchi, S. Esposto, C. Castellini (2012): Effect of dietary supplementation with olive pomaces on the performance and meat quality of growing rabbits. *Meat Science*, 92(4):783–788.
16. Datillo, M., F. Congiu (1995): Effects of olive cake on the productivity of sheep and the amino acid composition of their meat. *Protein metabolism and nutrition. Proceedings 7th International Symposium, Vale de Santarem, Portugal 24 – 27 May 1995, EAAP Publication No 81. FAO Yearbook (1993) Vol. 47, 119.*
17. Dorbane, Z., S.A. Kadi, D. Boudouma, M. Berchiche, C. Bannelier, T. Gidenne (2016): Nutritive value of crude olive cake (*Olea europaea* L.) for drowing rabbit. 11th World Rabbit Congress, June 15-18, 2016, Qingdao, China.
18. Dorbane, Z., S.A. Kadi, D. Boudouma, N. Gater-Belaid, C. Bannelier, M. Berchiche, T. Gidenne (2019): Nutritive value of two types of olive cake (*Olea europaea* L.) for growing rabbit. *World Rabbit Sci.*, 27, 69-75.
19. El-Samee, L.D., Hashish, S.M. (2011): Olive cake in laying hen diets for modification of yolk lipids. *Journal of Agriculture Science and Technology*, 1:415–421.
20. Estaún, J., J. Dosil, A. Al Alami, A. Gimeno, A. de Vega (2014): Effects of including olive cake in the diet on performance and rumen function of beef cattle. *Animal Production Science*, 54:1817-1821.
21. Ferrer, P., P. García-Rebollar, A. Cerisuelo, A.M. Ibáñez, A.C. Rodríguez, S. Calvet, C. Blas (2018): Nutritional value of crude and partially defatted olive cake in finishing pigs and effects on nitrogen balance and gaseous emissions. *Animal Feed Science and Technology*, 236:131-140.

22. Flausino, G., P.D.S. Leal, D. McIntosh, L.G. Amaral, F. Teixeira, W. Flausino, C.W.G. Lopez, (2012): Isolation and Characterization of *Cyniclomyces guttulatus* (Robin) Van Der Walt and Scott, 1971 in dogs in Brazil. *Current Microbiology*, 65:542-546.
23. Garcia-Casco, M.J., M. Munoz, M.J. Martinez-Torres, A. Lopez-Garcia, A.M. Fernandez-Barroso, E. Gonzales-Sanchez (2017): Alternative Feeding in Iberian Pigs during Growth Period: Incorporation of Olive Cake in a Dry or Wet (silage) Form. *Agriculturae Conspectus Scientificus* 82:147-150.
24. Georgopoulou, E. (1994): Effect of olive pulp on the performance of laying hens. *Proceedings of 9th European Poultry Conference*, Glasgow, UK, August 7-12, 1994.
25. Gül, S., M. Keskin, S. Kaya (2010): Olive cake usage as an alternative to cotton seed meal in dairy goat feeding. *African Journal of Agricultural Research*, 5:1643-1646.
26. Hersey-Benner, C. (2008): Diarrhea in a rabbit. *Cyniclomyces guttulatus* yeast. *Laboratory Animal*, 37:347-349.
27. Houwers D.J., B. Blankenstein (2001): *Cyniclomyces guttulatus* and diarrhea in dogs. *Tijdschr Diergeneeskde*, 126:14-15.
28. Joven, M., E. Pintos, M.A. Latorre, J. Suarez-Bellch, A.J. Guada, M. Fondevila (2014) : Effect of replacing barley by increasing levels of olive cake in the diet of finishing pigs: Growth performances, digestibility, carcass, meat and fat quality. *Animal Feed Science and Technology*, 197:185-193.
29. Kadi, S.A., N. Belaidi-Gater, F. Chebat (2004): Inclusion of crude olive cake in growing rabbits diet: effect on growth and slaughter yield. *Proceedings of 8th World Rabbit Congress*, September 7-10, 2004, Puebla, Mexico.
30. Kostelić, A. (2003): Influence of olive pomace on some hematological, biochemical and histopathological indicators of fattening lambs. Master's thesis, Faculty of Agriculture University of Zagreb.
31. Lebas, F. (2004): Reflections on rabbit nutrition with a special emphasis on feed ingredients utilization. *8th World Rabbit Congress*, Puebla, Mexico. Invited paper, 686-736
32. Manouakas, G., B. Mazamenos, A.M.B. Patrino (1973): Amino acids composition of 3 variations of olives. *Journal of Agriculture and Food Chemistry*, 21:215-216
33. Martilotti, F. (1983): Use of olive by-products in animal feeding in Italy. Rome, Animal Production and Health Division.
34. Mioč, B, V. Pavić, I. Vnučec, Z. Prpić, A. Kostelić, V. Sušić (2007): Effect of olive cake on daily gain, carcass characteristics and chemical composition of lamb meat. *Czech Journal of Animal Science*, 52:31-36.
35. Molina-Alcaide, E., D.R. Yanez-Ruiz (2008): Potential use of olive by-products in ruminant feeding. A review of *Animal Feed Science and Technology*, 147:247-264.
36. Nasopoulou, C., I. Zabetakis (2013): Agricultural and Aquacultural Potential of Olive Pomace (A Review). *Journal of Agricultural Science*, 7:116-127.
37. Nefzaoui, N., M. Vanbelle (1986): Effects of feeding alkali-treated olive cake on intake, digestibility and rumen liquor parameters. *Animal Feed Science and Technology*, 14:139-149
38. O'Donovan, P.B. (1984): Feeding trial results with olive pulp. *World Re. Anim. Prod.* 1984, 20:7-14.
39. Omar, J.M.A, L. Gavoret (1995): Utilization of olive cake in fattening rations of Awassi lambs. *Revue de Medicine Veterinaire*, 146 :273-276.
40. Peters, S., D.J. Houwers (2009): A cat with diarrhea associated with the massive presence of *Cyniclomyces guttulatus* in the faeces. *Tijdschr. Diergeneeskde*, 134:198-199.
41. Rabayaa, E. (2000): Utilization of olive pulp in broiler rations. MS Thesis, 2000, An-Najah National Univ. Nablus, Palestine.

42. Rayan, A., M. Ben Hamouda, C. Kayouli (1994): Olive oil cake incorporation for young rabbit feeding. *World Rabbit Science* 2, 127-134.
43. Rhone-Poulenc (1993): *Rhodimet Nutrition Guide*, 2nd ed. Rhone-Poulenc Animal Nutrition, Antony, France.
44. Rupić, V., L. Huskić, N. Vranešić, R. Božac, N. Stipić, F. Vešnik (1992): Olive cake in broiler nutrition (in Croatian). *Krmiva* 1992, 34:175-184.
45. Rupić, V., I. Jerković, R. Božac, D. Glowattzky, S. Mužic, V. Hrabak (1997): Olive by-products in pig fattening. *Acta Veterinaria Hungarica*, 45:53-66.
46. Rupić, V., V. Božikov, R. Božac, S. Mužic, N. Vranešić, M. Đikić (1999a): Effect of feeding olive by-products on certain blood parameters and serum enzyme activities of fattening rabbits. *Acta Veterinaria Hungarica*, 47:65-75.
47. Rupić, V., J. Škrln, S. Mužic, V. Šerman, N. Stipić, L. Bačar-Huskić (1999b): Proteins and fats in the serum of rabbits fed different quantities of dried olive cake. *Acta Veterinaria Brno*, 68:91-98.
48. Rupić, V. (2009): *Domestic animals health protection, Internal and Surgical Diseases and Interventions (university textbook) (in Croatian)*. Hrvatska mljekarska udruga, Zagreb, 276.
49. Sadeghi, H., A. Teimouri Ynsari, Z. Ansari-Pirsarai (2009): Effects of different olive cake by products on dry matter intake, nutrient digestibility and performance of Zel sheep. *International Journal of Agricultural Biology*, 11:39-43.
50. Saito, K., H. Saito, T. Watanabe (2009): *Cyniclomyces guttulatus*: it can now be clearly observed in canine feces. *Saito Animal Hospital, M. B. Network, Kitasato Institute*, http://www33.ocn.ne.jp/*saitoahohp/Cyniclomyces.htm, 5.5.2019.
51. Sansoucy, R. (1985): Olive by-products for animal feed. Rome, FAO, Animal Production and Health Division. Paper 43:8-15.
52. SAS Institute (1989): *SAS User Guide, Version 6, (fourth ed.) Volume 1-2*. Cary, N.C., SAS Institute Inc.
53. Tsantila, N., H.C. Karantonis, D.N. Perrea, S.E. Theocharis, D.G. Iliopoulos, C. Latrou, C.A. Demopoulos (2010): Atherosclerosis regression in rabbits upon olive pomace polar lipid extract administration. *Nutrition, Metabolism and Cardiovascular Diseases*, 20:740-747.
54. Van Soest, P.J. (1975): Physico-chemical aspects of fibre digestion. *Journal of Science Food and Agriculture*, 26:1433.
55. Vera, R., C. Aguilar, R. Lira, P. Toro, L. Barrales, I. Peña, F. Squell, P. Pérez, J. Quenaya, H. Yutronic, I. Brion (2009): Feeding dry olive cake modifies subcutaneous fat composition in lambs, noting cake resistance to degradation and peroxidation. *Chilean Journal of Agricultural research*, 4:548-559.
56. Vera, R.R., C. Aguilar, P. Toro, F.F. Squella, P. Perez (2013): Performance of lambs grazing an annual Mediterranean pasture or fed supplements based on olive oil cake or maize and its influence on system outputs. *Animal Production Science*, 53:516-522.
57. Vešnik, F., V. Rupić, T. Černy (1993): Technological value of crude olive cakes from the Croatian region of Istria (in Croatian). 9th International Symposium of Technologies for Drying and Storing. Stubičke Toplice, January 26 – 27, 1993., Proceedings, 154-162.
58. Vešnik, F., V. Rupić, T. Černy (1994): Olive cake as an animal feed component in the production of animal fodder (in Croatian). 10th International Symposium of Technologies for Drying and Storing. Stubičke Toplice, January 18 – 21, 1994., Proceedings, 200-206.
59. Zangeneh, S., M. Torki (2011): Effects of B-Mannanase supplementing of olive pulp-included diet on performance of laying hens, egg quality characteristics, humoral and cellular immune response and blood parameters. *Global Veterinaria*, 7:391-398.

60. Zierdt, C.H., C. Detlefson, J. Muller, K.S. Wagglie (1988): *Cyniclomyces guttulatus* (Saccharomycopsis guttulata) - culture, ultrastructure and physiology. *Antonie van Leeuwenhoek*, 54:357-366.
61. Ziętek, J., L. Adaszek, B. Dzięgiel, M. Kalinowski, M. Bartnicki, A. Kalinowska, L. Jarosz, S. Winiarczyk (2014): Diagnosis of the *Encephalitozoon cuniculi* infections in pet rabbits with neurological symptoms. *Polish Journal of Veterinary Sciences*, 17:361-363.

KOMINA MASLINE U HRANIDBI TOVNIH KUNIĆA: HISTOPATOLOŠKE PROMJENE

Sažetak

U radu je prikazan nutritivni utjecaj različitih količina (10% i 20%) osušenih komina maslina na tjelesnu masu, konverziju hrane i histopatološke promjene tkiva konvencionalno uzgojenih kunića Hyla hibrida u tovu. U pokusnom tovu od 56 dana bilo je ukupno 60 kunića koji su bili podijeljeni u tri skupine, kontrolnu i dvije pokusne s po 20 kunića u svakoj skupini (10 muških i 10 ženskih). Kunići kontrolne (C) skupine u obroku nisu dobivali kominu, dok su tijekom cijelog pokusa kunići prve pokusne skupine dobivali 10%, a kunići druge skupine 20% osušenih komina maslina. Nisu utvrđene statistički značajne razlike u tjelesnim masama između skupina kunića u tovu. U obje pokusne skupine utvrđena je bolja konverzija hrane u odnosu na kontrolnu skupinu. Histopatološkom pretragom 28 kunića utvrđene su histopatološke promjene u mozgu, srcu i bubrezima kunića kao posljedica patološkog djelovanja mikrosporidije *Encephalitozoon cuniculi*. U kunića obje pokusne skupine utvrđena je depozicija masti u srcu, jetri, limfnim čvorovima, štitnoj žlijezdi, nadbubrežnoj žlijezdi i gušterači iz razloga što su u hrani dobivali veću količinu maslinova ulja. Statistički značajno povećanje masti nađeno je samo u jetri, odnosno hepatocitima, ali ne i u drugim organima i žlijezdama. Histopatološkom pretragom utvrđeno je i patološko djelovanje gljivice *Cyniclomyces guttulatus* u probavnom sustavu svih skupina kunića koje su uzrokovale enteritis u cijelom probavnom sustavu, od želuca do debelog crijeva, čime je bila poremećena resorpcija hranjivih tvari, vitamina, minerala, itd.

Ključne riječi: kunići, hranidba, komina maslina, histopatološke promjene

Primljeno: 03.12.2019.
Prihvaćeno: 31.12.2019.