

Skeletal Class III Malocclusion in an Adult Patient – Orthodontics versus Orthognathic Surgery: Is there Another Alternative?

Abstract

Class III malocclusions are considered to be one of the most difficult problems to treat. Due to the significant number of patients with Class III malocclusion who cannot undergo orthognathic surgery for different reasons, we have proposed an alternative treatment that we have called surgically assisted rapid palatal expansion (SARPE) + temporary anchorage devices (TADs) which allows solving mild and moderate Class III malocclusion combined with maxillary compression, obtaining acceptable esthetic and functional results. We present a case report of an adult female with skeletal Class III malocclusion with compression in the maxillary and mandibular asymmetry, who was treated with SARPE + TADs. The result is acceptable in terms of occlusion function, esthetic of the smile, and facial esthetics.

Keywords: Case report, Class III malocclusion, maxillary compression, orthodontics, surgically assisted rapid palatal expansion + temporary anchorage devices

**Juan Carlos Pérez Varela,
Beatriz Iglesias Sánchez,
Miriam López Vila**

*Department of Orthodontics,
University of Santiago de
Compostela, Galicia, Spain*

Introduction

According to the classification of Dr. Angle, Class III is the malocclusion in which the vestibular groove of the lower first molar is located mesial to the mesiobuccal cusp of the upper first molar.^[1]

It is necessary to distinguish a dental Class III malocclusion from skeletal one because in the second, the malocclusion is due to a disproportion in the bony bases, which may be due to a retrognathism of the upper jaw, a mandibular prognathism, or a combination of both.^[2,3]

The highest prevalence of Class III malocclusions is found in Asia (12%) and Europe, values ranging between 1.5% and 5.3% and in Caucasians in North America between 1% and 4%.^[4,5]

The skeletal deformities are the result of the presence of anomalies in the position of the maxilla and mandible. In malocclusions in which a single bone is involved, maxillary retrusion is more common (19.5%) than a mandibular protrusion (19.2%), although the presence of these two features in a combined form is more common (30.2%).^[6,7]

In the treatment of skeletal Class III malocclusion in adults, there are basically

This is an open access journal, and articles are distributed under the terms of the Creative Commons Attribution-NonCommercial-ShareAlike 4.0 License, which allows others to remix, tweak, and build upon the work non-commercially, as long as appropriate credit is given and the new creations are licensed under the identical terms.

For reprints contact: reprints@medknow.com

two treatment alternatives: orthodontic treatment and surgical treatment combined with orthodontics. The choice of one or the other will depend on several factors; one of the main ones will be the degree of bone discrepancy, since orthodontic camouflage can only be done when Class III malocclusion is mild. On the other hand, not all patients are willing to undergo surgical treatment, due to its cost, invasive nature, or health conditions, despite being the ideal option from the orthodontic point of view.^[8-10]

In cases in which, in addition to the sagittal problem, there is a transversal problem due to maxillary compression, it is possible to perform a segmented Le Fort (combining Le Fort I with osteotomies that allow disjunction). Another option is the previous execution of a surgically assisted rapid palatal expansion (SARPE).^[11-13]

Federico Hernández Alfaro describes the SARPE performed on 257 patients, under local anesthesia and sedation, making a complete Le Fort I without mobilization, which achieves a total release and bipartition of the maxilla that guarantees skeletal distraction and prevents a damaging load at the dental level.^[14]

Due to the number of patients with Class III malocclusion with maxillary

How to cite this article: Pérez Varela JC, Sánchez BI, Vila ML. Skeletal class III malocclusion in an adult patient – orthodontics versus orthognathic surgery: Is there another alternative? APOS Trends Orthod 2018;8:161-7.

Address for correspondence:
Dr. Juan Carlos Pérez Varela,
C/Doutor Teixeira N 12 1,
15701, Santiago De Compostela,
A Coruña, Spain.
E-mail: jcperezvarela@yahoo.es,
clinicadelnoroeste@yahoo.es

Access this article online

Website:

www.apospublications.com

DOI: 10.4103/apos.apos_63_18

Quick Response Code:



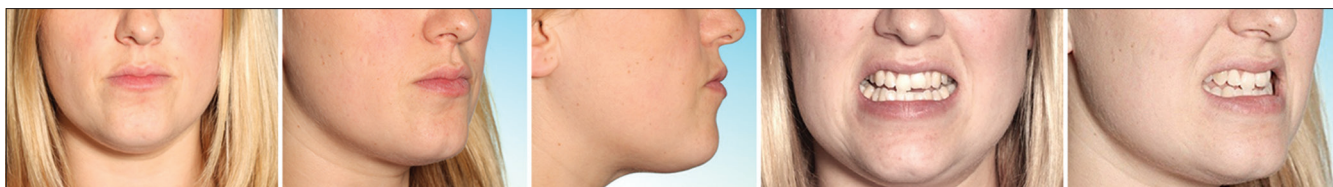

Figure 1: Initial extraoral photographs

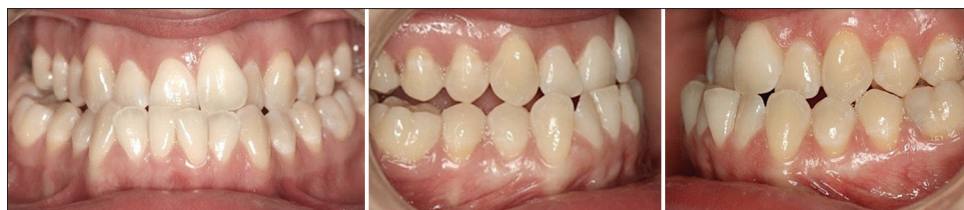

Figure 2: Initial intraoral photographs

compression who refuse treatment with orthognathic surgery, we have proposed a less invasive solution for the patient, more economically affordable, and that obtains very good results, both esthetically and functionally. This alternative consists in the performance of a SARPE under local anesthesia and sedation, and the placement of miniplates, two superiors at the level of the pterygoid and two inferiors in the symphysis, between the lateral incisors and the canines.

The case presented is a Class III malocclusion with maxillary compression, mandibular asymmetry, and deviation of the lower line to the right.

Although the ideal option to correct all the problems was orthognathic surgery, the patient decided to undergo treatment of SARPE + temporary anchorage devices (TADs), assuming that the mandibular asymmetry would not be corrected.

Diagnosis and etiology

The patient is an adult of 28 years old presenting with transversal and sagittal hypoplasia of the maxilla, skeletal asymmetry, deviation of the lower line to the right, and crowding.

Clinical frontal examination revealed an asymmetrical face. The profile assessment revealed concave profile, with anterior facial divergence, flat cheekbone contour, and pure esthetics of the smile in the frontal and lateral views [Figure 1]. When we analyzed the smile in detail, we observed crowding, poor coordination of the dental midlines, and the upper teeth are worn [Figure 1].

Intraoral examination revealed Class III molar and canine relation on both sides. The mandibular midline was deviated 4.5 mm to the right. The patient had upper and lower crowding and compression in the maxilla [Figure 2].

Temporomandibular joint (TMJ) examination revealed a little discrepancy between centric relation and centric occlusion, and the patient complained of pain in the joint.

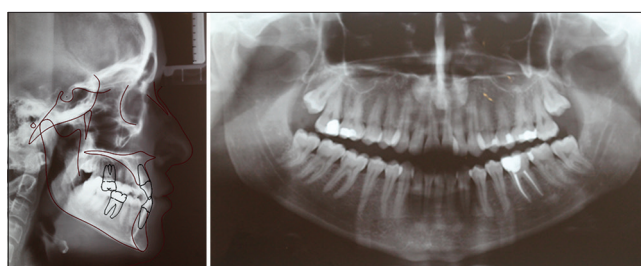


Figure 3: Initial teloradiograph and orthopantomography

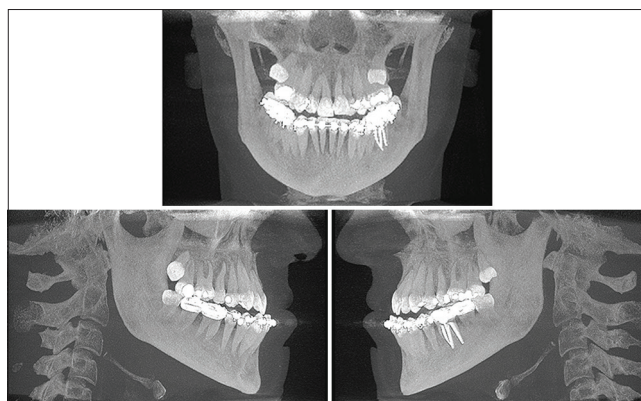


Figure 4: Cone beam computed tomography before surgically assisted rapid palatal expansion

Cephalometric examination revealed retrognathic maxilla (SNA 73°) and Class III malocclusion (Witts -10mm and ANB -4°) [Figure 3 and Table 1].

Treatment progress

Due to the large number of adult patients who present Class III malocclusion but decide not to undergo orthognathic surgery, despite being the ideal option, for different reasons explained above, we decided to devise an intermediate option between camouflage and orthognathic surgery.

When a SARPE is performed to solve maxillary compression, the palatine and pterygoid sutures are released. If we also add some miniplates at the level of the

pterygoids each side by vestibular and others between the lower lateral incisors and the lower canines by vestibular, we can pull forward the maxilla, benefiting from the release of the pterygoid sutures made in the SARPE. We have defined this technique as SARPE + TADs.

Orthodontic treatment combined with SARPE + TADs consists of three phases: presurgical orthodontic treatment, surgical treatment, and postsurgical orthodontic treatment.

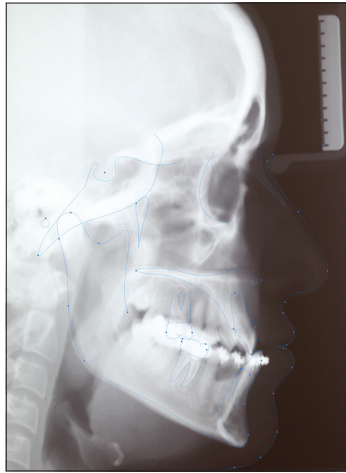

Figure 5: Teleradiograph before surgically assisted rapid palatal expansion

Table 1: Cephalometric values

Value	Mean	Initial	Treatment pre-SARPE	Final
SNA (°)	82±3.5	73	73	76.5
SNPg (°)	80±3.5	77	77	77
SNB (°)	80±2	77.5	77.5	77.5
ANPg (°)	2±1.5	-4.5	-4.5	-1
ANB (°)	2±1	-4	-4	-0.5
SN/ANS-PNS (°)	8±3.0	14.5	14.5	14.5
SN/GoGn (°)	33±2.5	38	38	38
ANS-PNS/GoGn (°)	25±6.0	20	20	20
+1/ANS-PNS (°)	110±6.0	108	108	119.5
-1/GoGn (°)	94±7.0	83	91	82
Overjet (mm)	3.5±2.5	-0.3	-2	0.3
Overbite (mm)	2±2.5	1.7	1.5	2
Interincisal (°)	132±6.0	147	142	137
Witts	0±1	-10	-10	-4

SARPE: Surgically assisted rapid palatal expansion

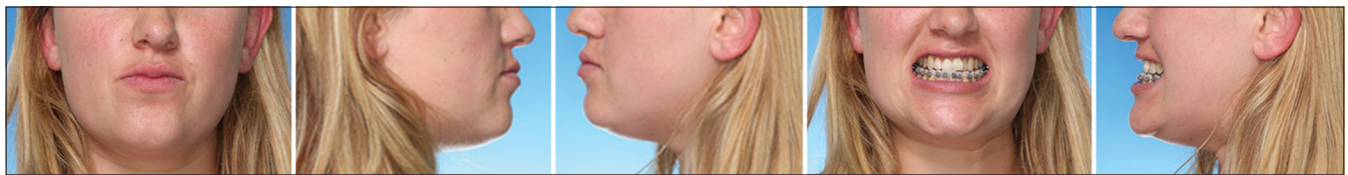

Figure 6: Extraoral photographs before surgically assisted rapid palatal expansion

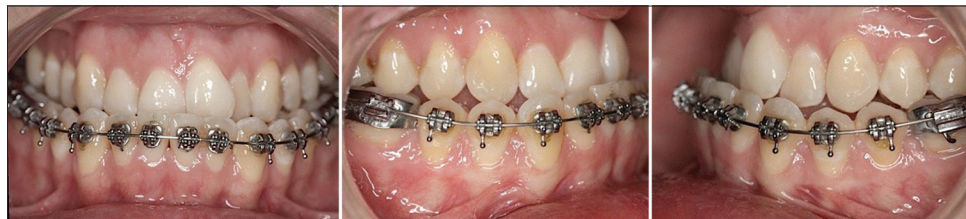

Figure 7: Intraoral photographs before surgically assisted rapid palatal expansion

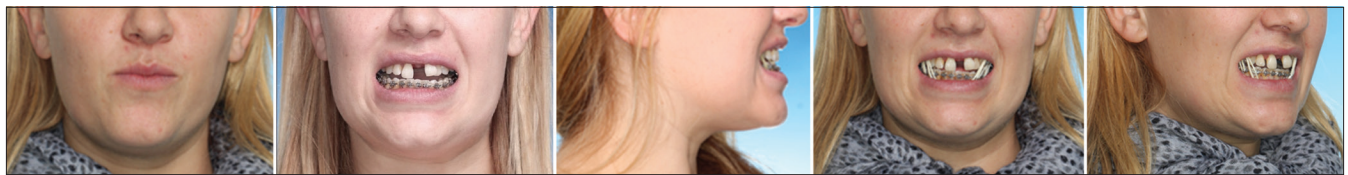


Figure 8: Extraoral photographs after surgically assisted rapid palatal expansion

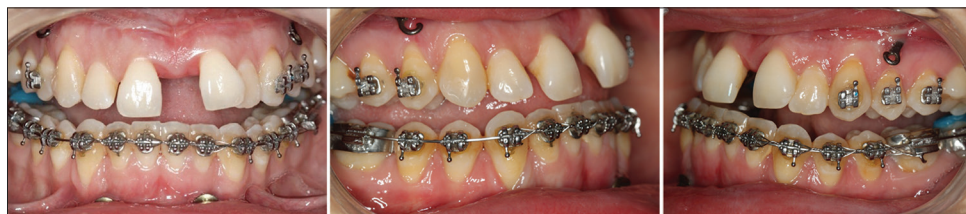

Figure 9: Intraoral photographs after surgically assisted rapid palatal expansion

In patients with skeletal problems and TMJ pain, we propose to use a split in upper arch, and we decompensate the lower arch to make sure which is the real transversal and sagittal problem for 4 months.

After this first phase, we did a teleradiograph [Figure 4 and Table 1] and a cone-beam computed tomography

(CBCT) to measure the transversal problem [Figures 4 and 5]. The patient first needed a surgery to expand the maxillary by SARPE technique before the placement of brackets in the upper arch. In our protocol, this surgery is considered ambulatory because it is performed under local anesthesia and sedation on an outpatient basis in 30 min [Figures 6-9].

Next, the patient underwent the operation of SARPE + TADs. The activation was 3 turns per day, and an intermaxillary elastic was placed from the right upper miniplate to the lower right one and another from the upper left miniplate to the lower left one, with forces of 200–400 g per side for approximately 24 h a day (the patient can only remove them to eat and brush her teeth) [Figure 8].

Once the desired expansion was obtained, we made a CBCT to confirm that the expansion was completely corrected and to measure the sagittal advance of the maxilla [Figure 10].

One month later of the last turn of the screw, we bonded the brackets in the upper arch and we closed the diastema and coordinated the dental arches to achieve an

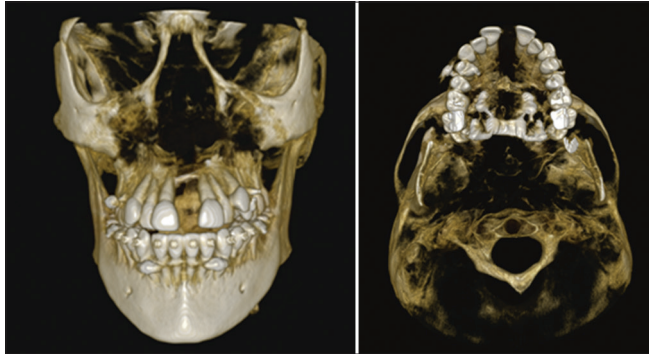


Figure 10: Cone-beam computed tomography after maxillary expansion

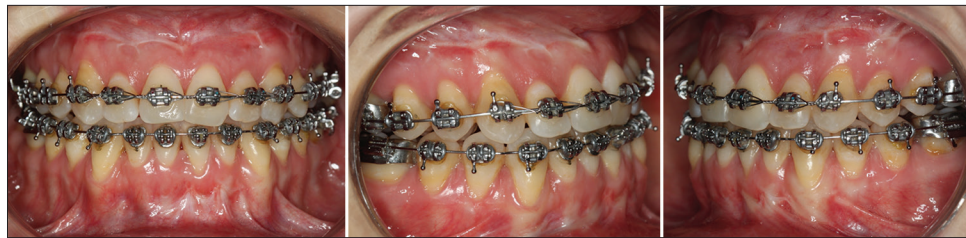

Figure 11: Intraoral photographs during the treatment

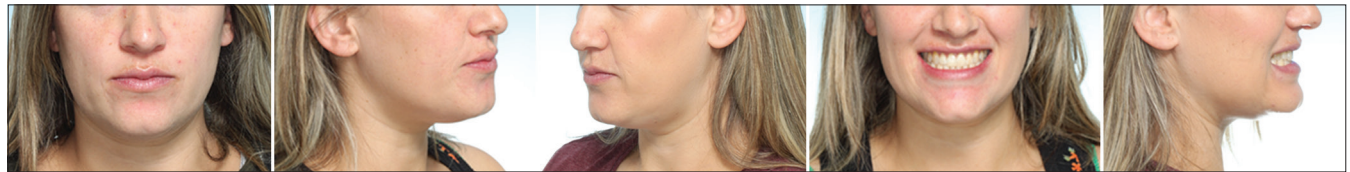

Figure 12: Final extraoral photographs

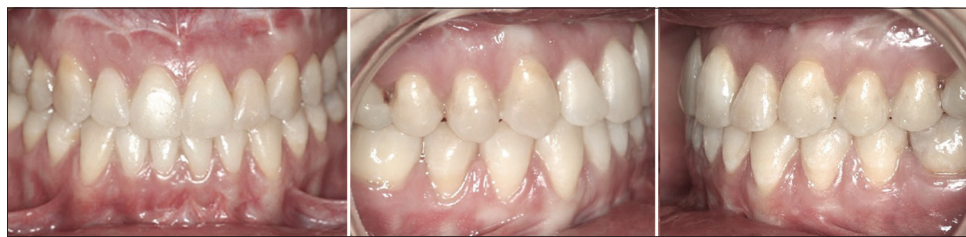

Figure 13: Final intraoral photographs

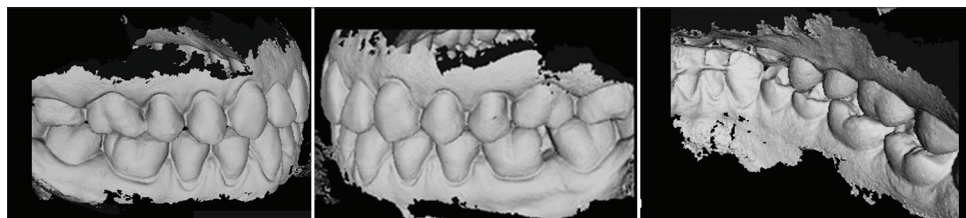


Figure 14: Final intraoral scan

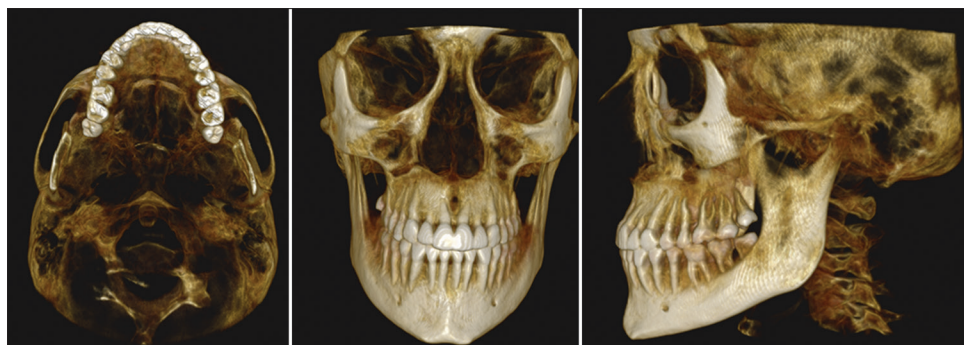


Figure 15: Final cone-beam computed tomography

adequate occlusion and esthetics of the smile (to center the midlines, obtain molar and canine in Class I, achieve overbite with intermaxillary elastics, and get a correct smile arch) [Figure 11]. The elastics of the miniplates continued to be placed until the patient's sagittal problem was resolved.

During the treatment, we used the following arches:

- Alignment: 0.014 NiTi and 0.016 NiTi
- Leveling: 0.017 × 0.025 NiTi.
- Torque and space closure: 0.019 × 0.025 steel wire
- Finishing: 0.018 steel wire with bindings.

Treatment results

After the treatment, the brackets and TADs were removed and final radiographs were taken.

The result after the treatment is acceptable. We obtained a significant improvement in alignment, occlusion function, coordination of the midlines, and esthetics of the smile in frontal and lateral views and facial esthetics. The mandibular asymmetry was not corrected since orthognathic surgery would have been necessary for this purpose [Figures 12 and 13].

The lingual occlusion is acceptable, and we can see it with the dental scan [Figure 14].

In the CBCT, we can observe that the roots are in the middle of the alveolar bone, and there is no root resorption [Figure 15].

Cephalometric examination showed an advance of the maxilla (SNA 76.5°), a Class I malocclusion (Witts -4 and ANB -0.5°) and a correct interincisal angle (137°) [Figure 16 and Table 1].

The main changes obtained in the treatment of SARPE + TADs in the patient are as follows [Table 1]:

- There have been no rotations of the maxillary or mandibular plane
- The Class III malocclusion has been completely corrected (ANB from -4° to -0.5°, Witts from -10 to -4 mm)
- Proper advancement of maxilla has been achieved (SNA from 73° to 76.5°)



Figure 16: Final telerocephalogram

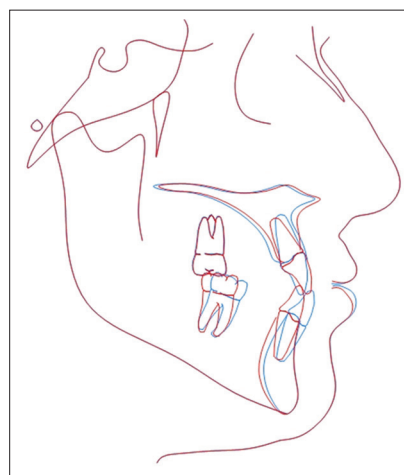


Figure 17: Superposition of the tracings before surgically assisted rapid palatal expansion (blue) and final (red) on the anterior cranial base

- The inclination of the upper incisor (119.5°) and the lower (92°) is corrected
- The interincisal angle is corrected (137°)
- The overjet decreased from -2 to 0mm.

In order to visualize the changes produced after the treatment of the patient with SARPE + TADs, the superposition of the tracings after SARPE and final, on the anterior cranial base, was made, showing all the

changes previously exposed [Figure 17], and a comparison between intraoral and extraoral photographs was made [Figures 18 and 19].

Two years later, the occlusion function is stable. The esthetic of the smile is acceptable. The patient does not have TMJ problems [Figures 20 and 21].

Conclusion

In cases where there are a maxillary compression and a mild or moderate Class III malocclusion, and/or when the patient rejects the option of orthognathic surgery due to its economic cost, health conditions, or invasive nature, the treatment of SARPE + TADs is an option that obtains very

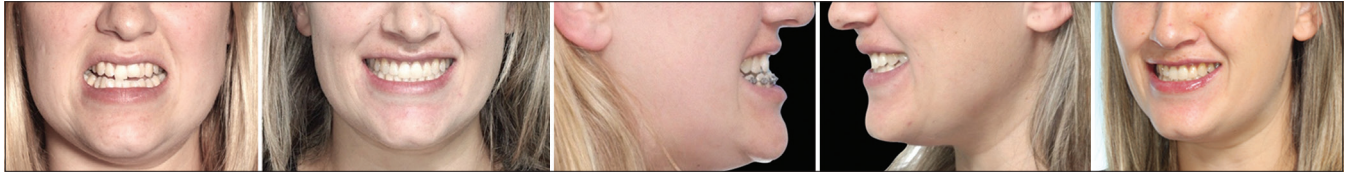

Figure 18: Comparison between initial and final extraoral photographs

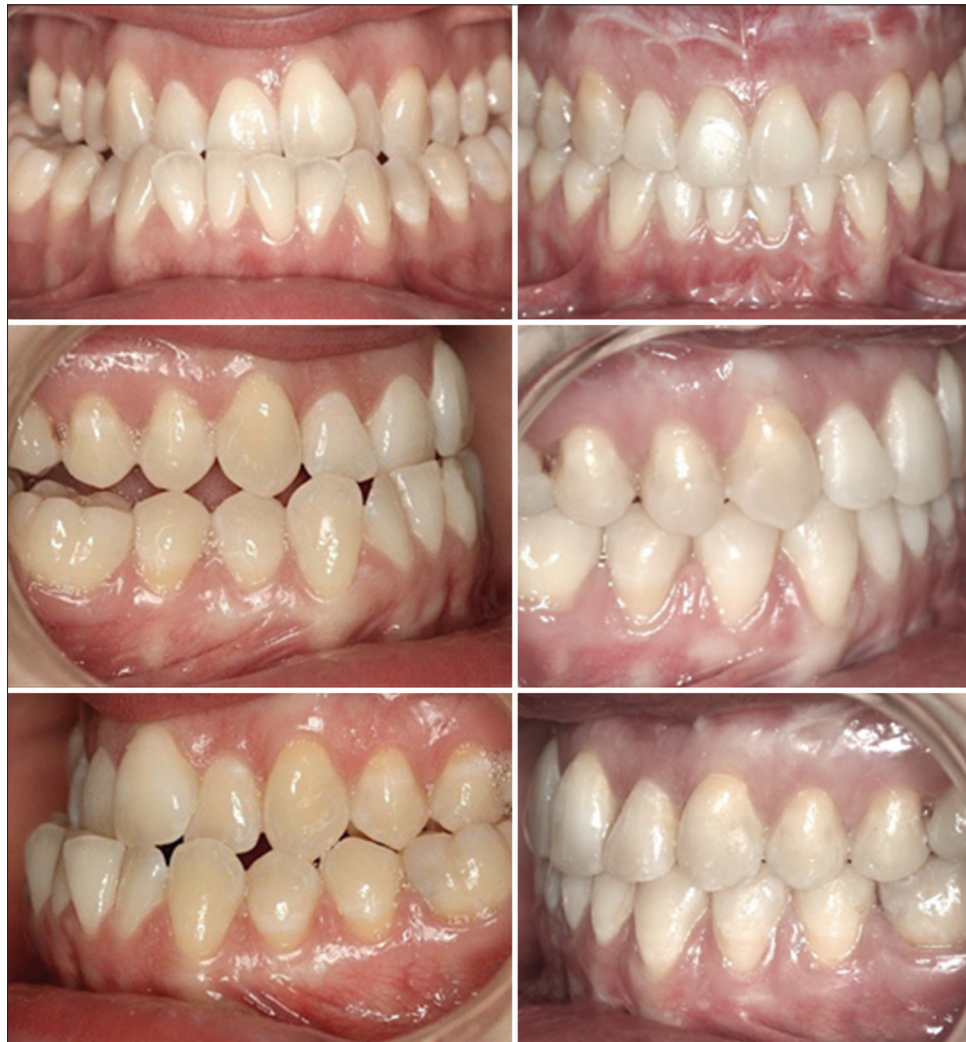

Figure 19: Comparison between initial and final intraoral photographs

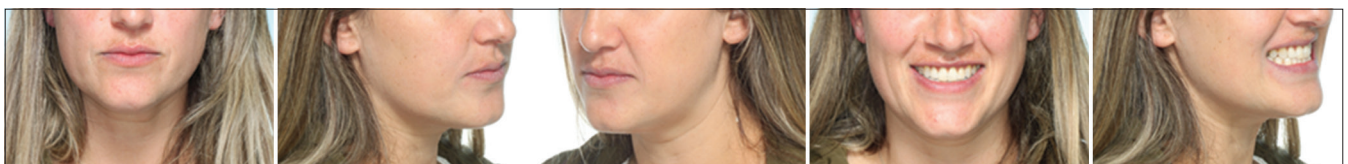

Figure 20: Retention extraoral photographs

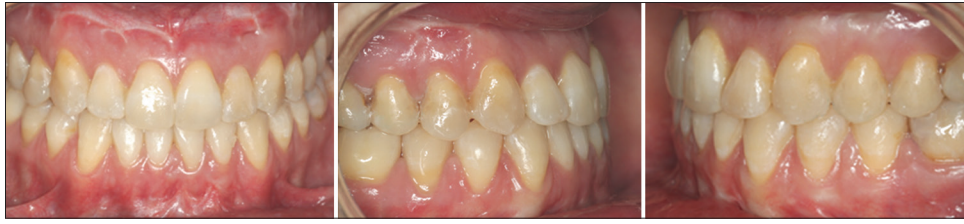

Figure 21: Retention intraoral photographs

acceptable results, both functionally and esthetically, and allows patients to solve skeletal problems that until now could only be corrected with orthognathic surgery.

Declaration of patient consent

The authors certify that they have obtained all appropriate patient consent forms. In the form, the patient has given his consent for her images and other clinical information to be reported in the journal. The patient understands that her names and initials will not be published and due efforts will be made to conceal her identity, but anonymity cannot be guaranteed.

Financial support and sponsorship

Nil.

Conflicts of interest

There are no conflicts of interest.

References

1. Profit WR. The development of dentofacial deformity: Influence and etiological factor. In: Profit WR, White RP Jr., Sarver DM. Contemporary Treatment of Dentofacial Deformity. St. Louis: CV Mosby; 2003.
2. Ngan P, Moon W. Evolution of Class III treatment in orthodontics. Am J Orthod Dentofacial Orthop 2015;148:22-36.
3. Benyahia H, Azaroual MF, Garcia C, Hamou E, Abouqal R, Zaoui F. Treatment of skeletal Class III malocclusions: Orthognathic surgery or orthodontic camouflage? How to decide. Int Orthod 2011;9:196-209.
4. Carlos Pérez Varela J, Sánchez BI. Orthodontic treatment of an asymmetric case with Class III malocclusion, crowding, and an impacted canine. APOS Trends Orthod 2016;6:306-11.
5. Varela JC, Sanchez BI. Orthosurgical management of an asymmetric case with class III malocclusion and transversal problema in the maxilla. APOS Trends Orthod 2016;6:160-5
6. Sun B, Tang J, Xiao P, Ding Y. Presurgical orthodontic decompensation alters alveolar bone condition around mandibular incisors in adults with skeletal Class III malocclusion. Int J Clin Exp Med 2015;8:12866-73. 14.
7. Zhang J, Li X. Dentoalveolar compensation in skeletal Class III patients treated with orthognathic surgery. Zhonghua Kou Qiang Yi Xue Za Zhi 2015;50:656-60.
8. Arnett GW, Bergman RT. Facial keys to orthodontic diagnosis and treatment planning –Part II. Am J orthod Dentofacial Orthop 1993;103:395-411.
9. Arnett GW, Bergman RT. Facial Keys to orthodontic diagnosis and treatment planning. Part I. Am J Orthod Dentofacial Orthop 1993;103:299-312.
10. Lee CH, Park HH, Seo BM, Lee SJ. Modern trends in Class III orthognathic treatment: A time series analysis. Angle Orthod. Available from: <https://www.ncbi.nlm.nih.gov/pubmed/27513030>. [Last accessed on 2016 Aug 11].
11. Dergin G, Aktop S, Varol A, Ugurlu F, Garip H. Complications related to surgically assisted rapid palatal expansion. Oral Surg Oral Med Oral Pathol Oral Radiol 2015;119:601-7. 11.
12. Möhlhenrich SC, Modabber A, Kamal M, Fritz U, Prescher A, HÖlzle F. Three-dimensional effects of pterigomaxillary disconnection during surgically assisted rapid palatal expansion: A cadaveric study. Oral Surg Oral Med Pathol Oral Radiol 2016;121:602-8.
13. Fernandez-Sanromán J, Donascimento MG, López AC, Ferrol MF, Berrondo IA. Transverse maxillary distraction in patients with periodontal pathology or insufficient tooth anchorage using customade devices. J Oral Maxillofac Surg 2010;68:1530-6
14. Hernandez-Alfaro F1, Mareque Bueno J, Diaz A, Pagés CM. Minimally invasive surgically assisted rapid palatal expansion with limited approach under sedation: a report of 283 consecutive cases. J Oral Maxillofac Surg. 2010;68:2154-8.