

# An anomalous bilateral muscle in Guyon's canal found during cadaver study

P. Depukat, E. Mizia, J. Walocha

Chair of Anatomy, Faculty of Medicine, Jagiellonian University, Cracow, Poland

[Received 23 November 2009; Accepted 9 December 2009]

*During anatomical dissection, an unusual bilateral muscle in the region of Guyon's canal was found in a 29-year-old human male cadaver. It originated from the pisiform bone and inserted to the flexor retinaculum. The muscle passed between the superficial and deep branch of the ulnar nerve. The ulnar artery passed anteriorly to the muscle. This work reports this finding and tries to categorise it in one of the groups following the literature. (Folia Morphol 2010; 69, 1: 65–67)*

**Key words:** accessory muscle, wrist, variations

## INTRODUCTION

The occurrence of anomalous hand muscles in the region of the wrist is a rather common event. Usually authors classify them as accessory abductor digiti minimi (ADM), flexor digiti minimi brevis (FDMB), or palmaris longus [1–12]. This work reports a rarely seen type of accessory muscle. The dissection was performed with the permission of the Ethical Committee of Jagiellonian University.

## MATERIAL AND METHODS

Both wrists of a 29-year-old male fresh cadaver with no medical history were dissected simultaneously to enable visualization of Guyon's canal. An incision was performed along the radial border of the flexor carpi ulnaris tendon, then in a zigzag fashion across the proximal wrist crease, continuing in a line to the ring finger [1]. To open the roof of the canal, the palmar carpal ligament and palmaris brevis muscle were dissected. An ulnar nerve and artery were isolated in the distal forearm and traced distally.

## RESULTS

A bilateral, hypertrophic, anomalous hand muscle was accidentally identified originating from the pisiform bone and inserting to the flexor retinacu-

lum. In both wrists it was 18.2 mm long and 5.2 mm wide. The muscle passed between the superficial and deep branch of the ulnar nerve. The ulnar nerve divided 7.2 mm proximally to the proximal end of the pisiform bone. The ulnar artery passed superficially to the muscle while the deep branch of the ulnar artery was not found (Figs. 1, 2).

## DISCUSSION

Dodds et al. [4] reported a 22% incidence rate of accessory ADM muscles during a cadaver study, with 46.2% of cases occurring bilaterally. Most of the accessory ADM muscles originated from the antebrachial fascia and inserted on the ulnar side of the base of the proximal phalanx of the little finger.

Zeiss et al. [12] showed an accessory ADM muscle incidence rate of 25% from their radiologic study, 67.0% of cases occurring bilaterally. The accessory muscles originated somewhere between the mid-forearm and the proximal part of Guyon's canal, along the antebrachial fascia, under the surface of the palmar carpal ligament, or on the radial side of the pisiform bone, eventually fusing with the ADM.

Richards et al. [11] dissected 43 wrists and found 3 anomalous muscles. Two of them arose from the flexor carpi ulnaris and inserted to the proximal as-

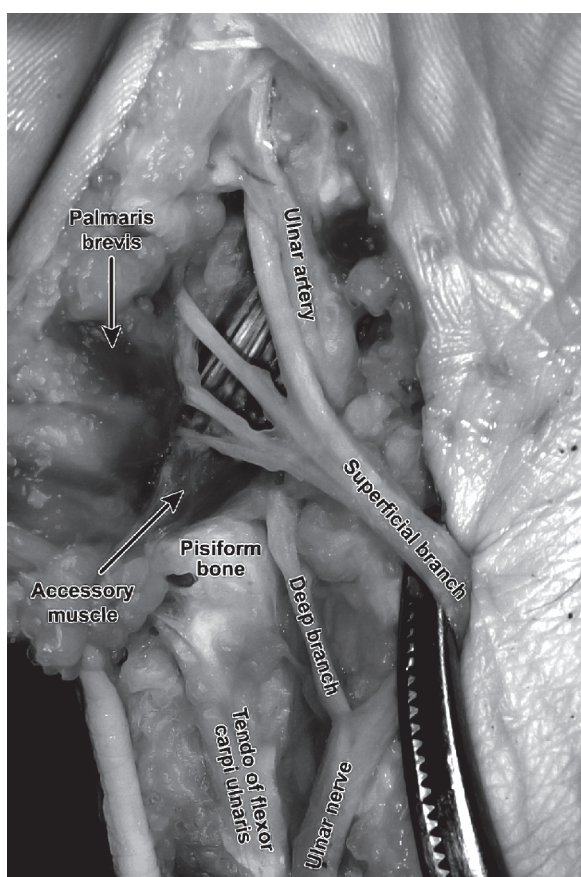


Figure 1. Right hand.

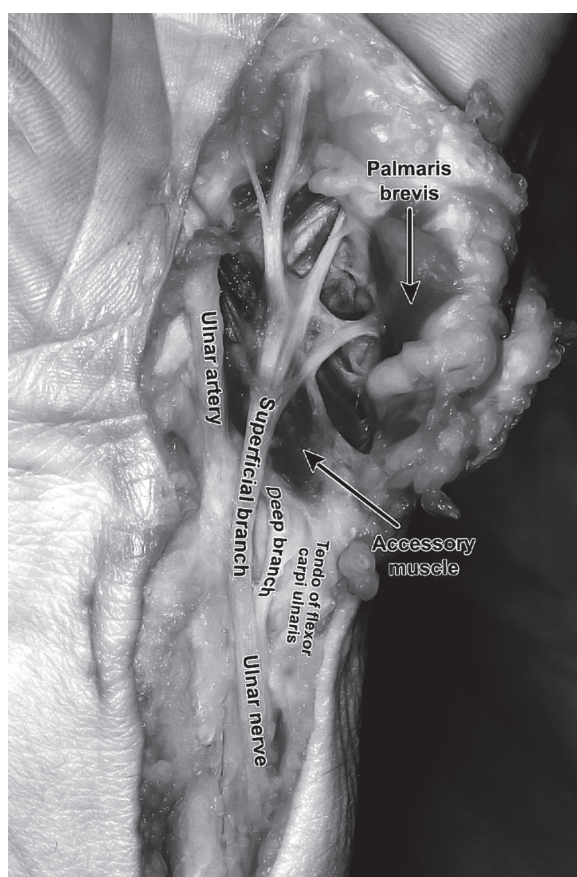


Figure 2. Left hand.

pect of the transverse carpal ligament. One originated from the palmaris longus muscle and inserted into the hypothenar eminence.

Bozkurt et al. [2] dissected 37 wrists and recorded an accessory muscle incidence rate of 16.2%. Five muscles were classified as accessory ADM and one was accessory FDMB; all of them were unilateral. The origins for the muscles were flexor retinaculum, antebrachial fascia, or tendon of palmaris longus muscle. They fused with the bellies of the hypothenar muscles ADM or FDMB and inserted into them.

Murata et al. [9] dissected 35 wrists and found 9 aberrant muscles which they classified into 4 variants. In variation 1 (5 hands), the muscle originated from the flexor retinaculum and fused with the ADM. In variation 2 (2 hands), the muscle originated from the antebrachial fascia and fused with the ADM. In variation 3 (1 hand), the muscle originated from the pisiform bone and inserted into the flexor retinaculum. This muscle passed between the ulnar nerve and artery, lying volar to the ulnar nerve. In variation 4 (1 hand), the muscle originated from the pisiform bone and

inserted to the volar side of the head of the fifth metacarpal, dorsally to the ADM.

Harvie et al. [7] performed ultrasound examinations on 116 wrists of asymptomatic volunteers, and reported an anomalous muscle incidence rate of 35%. All of them were variants of an accessory ADM. 50% of them were bilateral. Mean muscle thickness was 1.7 mm with no significant difference with sex, hand dominance, or unilateral or bilateral presence.

It seems that the muscle found in our study belongs to variation 3 of the classification given by Murata et al. [9]. The only difference in our study is that the muscle passed between the deep and superficial branch of the ulnar nerve.

## REFERENCES

1. Bozkurt MC, Tagil S M, Ersoy M, Tekdemir I (2004) Muscle variations and abnormal branching and course of the ulnar nerve in the forearm and hand. *Clin Anat*, 17: 64–66.
2. Bozkurt MC, Tagil SM, Ozcahar L, Ersoy M, Takdemir I (2005) Anatomical variations as potential risk factors for ulnar tunnel syndrome: a cadaver study. *Clin Anat*, 18: 274–280.

3. Dimitriou C, Natsis K (2007) Accessory abductor digiti minimi muscle causing ulnar nerve entrapment at the Guyon's canal. *Clin Anat*, 20: 974–975.
4. Dodds GA, Hale D, Jackson WT (1990) Incidence of anatomic variants in Guyon's canal. *J Hand Surg Am*, 15: 352–355.
5. Fong E P, Mahaffey P JL (2000) Ulnar tunnel syndrome: an unusual cause. *Hand Surg*, 5: 77–79.
6. Green DP (2005) *Operative hand surgery*. Vol. 2. 5<sup>th</sup> Ed. Churchill Livingstone, New York.
7. Harvie P, Patel N, Ostlere SJ (2004) Prevalence and epidemiological variation of anomalous muscles at Guyon's canal. *J Hand Surg*, 29B: 26–29.
8. Kelly EJ, Riaz M, O'Shaughnessy M (1998) An anomalous muscle in the hand. *J Hand Surg*, 23B: 389–390.
9. Murata K, Tamai M, Gupta A (2004) Anatomic study of variations of hypothenar muscles and arborisation patterns of the ulnar nerve in the hand. *J Hand Surg Am*, 29: 500–509.
10. Pribyl CR, Moneim MS (1994) Anomalous hand muscle found in the Guyon's canal at exploration for ulnar artery thrombosis. A case report. *Clin Ortop Relat Res*, 306: 120–123.
11. Richards RS, Dowdy P, Roth JH (1993) Ulnar artery palmar to Palmaris brevis: cadaver study and three case reports. *J Hand Surg Am*, 18: 888–892.
12. Zeiss J, Jakab E, Khimji T, Imbriglia J (1992) The ulnar tunnel at the wrist (Guyon canal): normal MR anatomy and variants. *Am J Roentgenol*, 158: 1081–1085.