

Age dependent changes of the diploe in the human skull

Janusz Skrzat¹, Paweł Brzegowy¹, Jerzy Walocha¹, Wadim Wojciechowski²

¹Department of Anatomy, Collegium Medicum, Jagiellonian University, Kraków, Poland

²Department of Radiology, Collegium Medicum, Jagiellonian University, Kraków, Poland

[Received 11 September 2003; Revised 25 November 2003; Accepted 25 November 2003]

This paper presents an approach to the investigation of age-related morphological changes in the diploe of the human skull. Comparative investigations were performed on 10 dried skulls of young and old individuals. Computer tomography was employed followed by filtering of the digital images to visualise more details of the inner structure of the calvarial bones. As a result of our analysis, we concluded that the diploe of the young individuals was homogenous cancellous bone, which tightly fills the space between the outer and inner tables of the calvarial bones. The diploe of the older individual is more porous, showing a trace of sclerosis and with lacunas. Its texture is more scattered in the images and presents a higher level of degradation. The structural differences of the diploe in the skulls of older individuals can be due to a process of involution related to a diminishing of trabecular density in the cancellous bone. These processes are usually accompanied by fluctuations in the mineral components.

Key words: diploe, ageing, skull, computed tomography

INTRODUCTION

The ageing process causes morphological changes in the bone structure. Both the bones of the cranial and postcranial skeleton undergo remodelling. In the case of the skull this is vividly observed in suture obliteration [3, 4, 8]. During ageing distinct microstructural changes occur in the bone matrix resulting from an exchange of mineral components. The process of ageing has an impact on bone mineral density and calcium concentration. The calvarium is composed of inner and outer tables that enclose a layer of cancellous bone known as the diploe. This inner layer of the calvarial bones contains an abundance of different channels which transmit diploic veins [2, 5]. Age-related changes may seriously affect the diploe and inner table, which is lined by dura matter.

Studies of morphological age-related changes of the inner structure of the cranial bones are an es-

sential background to understanding the healing process and the use of calvaria in bone grafts [7].

The aim of the study was to detect differences in the structure of the diploe in the skull of young and old individuals which were observed in computed tomography (CT) and correlated with measurements of bone mineral density of the cranial vault.

MATERIAL AND METHODS

Computed assisted study of the diploe was performed on the calvaria of 10 dry skulls of adult individuals (5 skulls at age of death 30–40 and 5 skulls at age of death 60–70). The skulls under investigation belong to the Anatomical Museum of the Collegium Medicum of the Jagiellonian University.

Investigation of the diploe of young and old individuals involved image filtering and measurements of bone mineral density performed on the CT scans. Radiographic studies were carried out by means of

a Helicat Flash scanner (Marconi) using a spiral technique. The parameters of the examination were: collimation 2.7 mm, pitch 1.5, and exposure factors 120 kV, 162 mAs. In order to pick out more details in the image, a zoom factor was applied to CT-scans ranging from 2.5 to 5.0. This facilitated analysis of the inner structure of the calvarial bone and the relation between diploe and the outer and inner table of the compact bone. Axial scans were used to analyse the morphological appearance of the diploe because such sections enabled simultaneous observations and measurements of its density on the selected level of the skull in the entire calvaria (both on the right and the left side). Densitometric measurements were performed on the axial CT scans of the calvaria 40 mm below the vertex of the cranial vault and expressed in Hounsfield units (HU). Bone mineral density was measured in different areas, bilaterally on the axial CT scans with the omission of the areas of cranial suture, as these sites are different in morphological character.

Diploe appearance was inspected visually on the basis of on original and modified digital images, which were obtained from computed tomography. Image modifications combined tonal correction and embossing of the original images. This procedure was to differentiate areas of the diploe with different morphology resulting in a different distribution of the bony tissue. This corresponds closely to the bone mineral density calculated in the software applied in the computed tomography.

The method of tonal correction employed was a non-linear transformation of greyscale images. The images analysed were composed of pixels of different shades of grey. The non-linear tonal correction enables the image to be modified, so that the effect of light intensification was not a deepening of the shadows or vice versa, which would result in loss of the visual information which could be obtained from the images. This task was achieved with the help of graphic computer software, which made it possible to select appropriate levels of greyscale ranging from 0–255 and to remap the grey levels within the image. In such a process of image conversion the excessively dark areas of the image become lighter, while those that are too light become darker. Additionally, the proportions of the changes in the half-tones were preserved [6]. The method applied allowed the demarcation of borders between clusters of pixels, which were distinct in levels of grey that correlated with the density of bony tissue and its distribution in the selected area. The range of grey

levels expressed the density of the structure, while its gradient indicated the direction of variability in its structural density. The darker zones of the image showed an increase in bone mineral density, while the light zones indicated a decrease in structural density. The grey levels of the image CT-scans corresponded with the Hounsfield scale. The mean X-ray attenuation value of each pixel was expressed by the Hounsfield unit, which depends on bone mineral density. To visualise image texture in another way we applied an embossed effect, which creates the impression of stamping the contours of the image into a flat surface. The appropriate lightning direction, its brightness, and the "depth" of the embossing effect were adjusted experimentally.

RESULTS

Computed tomographic assisted study supported by measurements of the bone mineral density of the cranial vault revealed differences in the morphological appearance of the diploe in the skulls of young and old individuals.

Axial CT scans of the skulls of young individuals that were studied presented a high degree of grey shading, indicating a tight uniform structure of the inner layer of the bone. In the case of old individuals, the images of the diploe present non-homogeneous, irregular spots, which show various degrees of intensity of grey shading (Fig. 1, 2).

In young skulls this area is filled homogeneously, the texture being smooth or slightly folded, while in the old skulls these areas are scattered, irregular and rough in texture with numerous small granular clumps, which might be counterparts of random agglomerations of bony masses. This is visible with the use of the embossing algorithm applied to the CT scans. Increased bone density was observed in the peripheral layers of the calvarial bones, especially in young individuals. The skulls of the old individuals frequently show cessation of the inner table of the compact bone, with increased porosity of the diploe. Visual inspection of the CT scans also revealed widening of the diploe accompanied by thinning of the outer table of compact bone. In certain cases the age-dependant bone remodelling observed resulted in the production of irregular clusters of bone tissue, which seemed to be scattered in the vault section.

The values for the bone mineral density measured in the skulls ranged from 699 to 871 Hounsfield units in young individuals. However, in old individuals bone mineral density ranged from 93 to 225 Hounsfield

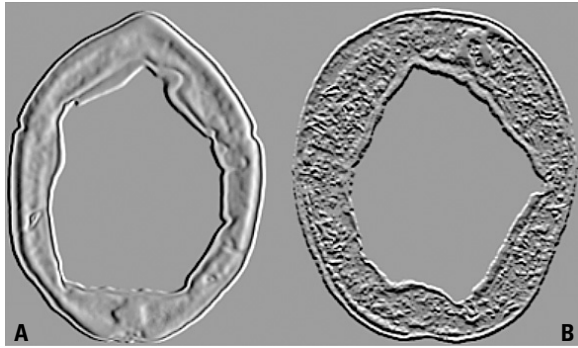


Figure 1. Comparison of the image texture of the transverse section of the calvarial bones in the young (A) and old individual (B). Reconstruction based on axial CT-scans with implementation of the embossing procedure.

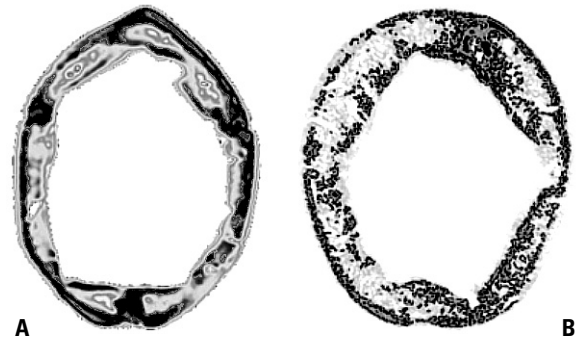


Figure 2. Comparison of the image texture of the transverse section of the calvarial bones in the young (A) and old individual (B). Reconstruction based on axial CT-scans with implementation of tonal correction of the original image.

units (Fig. 3). The local changes in bone mineral density evaluated correlated with visualised changes in the grey intensity of both age groups.

The minimum value of bone mineral density (699 HU) obtained in the skulls analysed of young individuals distinctly exceeds the maximum value of bone mineral density (225 HU) of the skulls of old individuals. The ranges of variation in bone mineral density do not overlap in their values, so that the structure of the diploe of the skull analysed should be regarded as significantly different. The differing morphological character of the diploe in the young and old individuals was also confirmed by visual inspection of the modified original CT scans (Fig. 1, 2). It is easy to make out the substantial organisation of bony matrix in the section of the cranial vault. In the skulls of young individuals the diploe is well demarcated from the outer and inner tables of the compact bone and smoothly fills the space in between them. Its image contains continuous dark spots, which indi-

cate an increase in bone mineral density, while in the old skull darker spots are smaller and more scattered in the section analysed. In the case of the old skulls, the observed diploe seemed to be irregular in structural pattern and more porous.

DISCUSSION

Spongy bone, which is typical for the diploe, is normally a porous substance that is less dense than compact bone. The different level of X-ray attenuation of each type of bone therefore results in a distinct appearance in CT scans, presenting various levels of grey intensity [9].

The intensity of greys in the structures studied was similar and the tonal range of greys had to be adequately separated to denote compact and spongy bone. Two distinct methods of image differentiation were therefore applied, that of tonal correction and that of embossing, which enabled the original digital images of the bony structure to be differentiated in such a way that the anatomical details under observation could be perceived in a different manner [6]. This technique allowed the inner structures of the calvarial bones to be compared. The images obtained provided the background against which conclusions could be drawn about the distribution of bone tissue and its concentration in the section of skull analysed. In the case of tonal correction darker spots on the image indicated a condensation of bony tissue, while lighter areas correspond to a loose organisation of the bony matrix, which was observed frequently in the diploic layer of the old individuals. It can be assumed that the diploe of the young skull and that of old individuals interact differently with X-rays. Thus the structure of the bone and diploe itself varies significantly in both cases, presumably

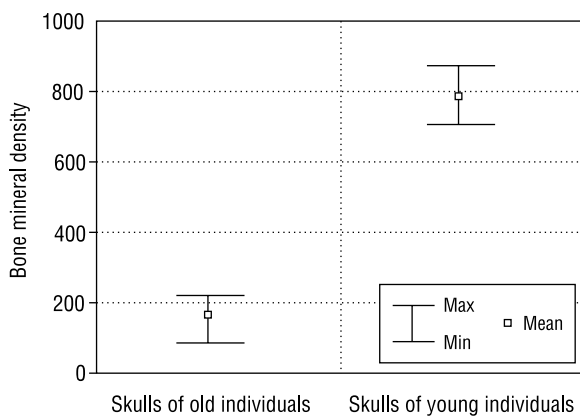


Figure 3. Range of variation in bone mineral density (HU) of the skulls studied.

as a result of age dependent changes in the bony matrix organisation in the skull.

Filtering the images of the diploe enhanced the details which indicate structural differences concerning the degree to which the space between the internal and external table of the compact bone is filled.

On the basis of the observations made and the measurements of bone mineral density taken in the skulls of young and old individuals, it may be concluded that structural changes are a result of a decrease in calcium concentration in the skull of old individuals [7]. Regarding the age-related morphological alterations in the diploe, it may be concluded that significant anatomical differences exist between young and old individuals in the inner structure of bone composition.

The tonal correction applied proved to be helpful in the visual inspection of the CT scans because it revealed significant differences in the morphological organisation of the inner structure of the calvarial bones of the young and old individuals.

We are aware of the fact that our material was made up of a rather small number in number of skulls for analysis. For this reason we were not able to perform objective comparative studies of morphological changes in the diploe between males and females. However, our evaluation of bone mineral density in the skulls of young and old individuals are coherent with the results obtained by Yamada et al. [10], who studied age-related changes in cranial bone mineral density in 495 cases. They found out that bone mineral density may decline from a value of 1164 ± 143 HU for young individuals (age of 20–30) to a value of 629 ± 119 HU for old ones (aged 70 or older). Moreover, structural differences in diploe between the skulls of young and old individuals were repeated in each pairs of skulls compared and their morphological appearance was similar. Our work was aimed at the visualisation of possible inner structural changes in the cranial bones related to the aging process and their verbal description rather than at precise densitometry. The measurements performed were to confirm or reject the hypothesis of local changes, observable in CT scans, which occur in the diploe structure during the ageing process. The re-

sult obtained allows the assumption to be made that visual methods of evaluating structural density and its variation might be effective without the need for performing measurements, if the values of bone mineral density called for do not have to be precise. Evaluation of structural density based on visual methods should take into considerations only the most typical structural attributes of the diploe, which differentiate age groups. The appearance and number of morphological changes may vary from those that occur in the post-cranial skeleton, as they are additionally stimulated by continuous impact forces derived from the external environment [1]. It should also be stressed that structural differences and the degree of age-related changes may depend on individual anatomical variation and physical reaction rate, which influence the function and organisation of the skeleton.

REFERENCES

1. Boyde A, Kingsmill VJ (1998) Age changes in bone. *Gerodontology*, 15: 25–34.
2. Cooper ER (1961) Cranial diploic channels and their communications. *Acta Anat*, 47: 345–362.
3. Creutz U (1977) Architecture of the human skullcap in the region of the parts bregmatica suturae sagittalis. I. Age dependence, *Gegenbaurs Morphol Jahrb*, 123: 666–688.
4. Furuya Y, Edwards MS, Alpers CE, Tress BM, Ousterhout DK, Norman D (1984) Computerized tomography of cranial sutures. Part 1: Comparison of suture anatomy in children and adults. *J Neurosurg*, 61: 53–58.
5. Hershkovitz I, Greenwald C, Rotschild BM, Latimer B, Dutour O, Jellema LM, Wish-Baratz S, Pap I, Lenoetti G (1999) The elusive diploic veins: anthropological and anatomical perspective. *Am J Phys Anthropol*, 108: 345–358.
6. Pastuszek W (2000) *Barwa w grafice komputerowej*, PWN, Warszawa.
7. Raulo Y, Baruch J (1990) Use of the calvarium for bone grafting in cranio-maxillo-facial surgery. *Chirurgie*, 116: 359–362.
8. Retzlaf E, Upledger J, Mitchel F, Walsh J (1979) Aging of cranial sutures in humans, *Anat Rec*, 193: 663.
9. Wegener H (1992) *Whole body computed tomography*. Blackwell Scientific Publications, Boston.
10. Yamada K, Endo S, Yoshioka S, Hatazawa J, Yamaura H, Matsuzawa T (1982) Age-related changes of the cranial bone mineral: a quantitative study with computed tomography. *J Am Geriat Soc*, 30: 756–763.