

QUIZ

CORRECT ANSWER TO THE QUIZ. CHECK YOUR DIAGNOSIS

HOBNAIL HEMANGIOMA

MARIA HEJNOLD¹, GRZEGORZ DYDUCH¹, IZABELA MOJSA², KRZYSZTOF OKOŃ¹

¹Department of Pathomorphology, *Collegium Medicum*, Jagiellonian University, Kraków, Poland

²Department of Oral Surgery, *Collegium Medicum*, Jagiellonian University, Kraków, Poland

We present a case of a 73-year-old woman who developed a small lesion on her tongue. The nodule was resected and hobnail hemangioma was diagnosed. Hobnail hemangioma is a rare vascular lesion with unusual morphology, including bland cells with hobnail appearance, biphasic grow pattern with superficial dilated vessels and slit-like vessels in the deeper portion of the lesion. The infiltrative pattern of grow may cause misdiagnosis. The differential diagnosis with hemangioendothelioma variants, low grade angiosarcomas and Kaposi sarcoma is of particular concern. The lack of recognition of this uncommon entity may result in excessive and unnecessary treatment.

Key words: hemangioma, vascular tumors, head and neck tumors, differential diagnosis.

Introduction

Hobnail hemangioma (HH) is an unusual benign vascular lesion of quite peculiar morphology. The differential diagnosis with some vascular malignant lesions is at times problematic. Below we describe a case of such lesion presenting as an oral nodule.

Clinical history

A 73-year-old woman was admitted to the Department of Oral Surgery for treatment of a nodule that appeared on her tongue. The patient did not remember when exactly the lesion appeared, but she said that it had been present 'for a long time'. The lesion was asymptomatic except for periodic bleeding, especially after irritation, such as accidental biting of the tongue. The clinical diagnosis of pyogenic granuloma was made, the lesion was completely excised and sent for histopathologic examination.

Material and methods

The material was fixed in formalin, routinely processed and paraffin embedded. Using the paraffin

blocks, 2 µm sections were prepared, stained by hematoxylin-eosin method and used for immunohistochemistry. Immunohistochemistry was performed using a standard protocol. Briefly, the slides were dewaxed, rehydrated and incubated in 3% peroxide solution for 8 min to block endogenous peroxidase activity. Antigen retrieval was carried out by water bath cooking in citrate buffer (0.2% citric acid titrated to pH 6.0 with 2N NaOH except for CD31 staining which needs EDTA in pH 8.0 instead of citric acid in pH 6.0) for 30 min. Primary antibodies are listed in Table I. The LabVision (Thermo Fisher Scientific, USA) detection system was used. 3,3'-diaminobenzidine (DAB) served as the chromogen. The slides were counterstained with Mayer's hematoxylin (Thermo Scientific, USA).

Results

Grossly, the lesion presented as reddish, soft nodule measuring 6 mm in diameter. The microscopic examination revealed dilated superficial vessels in the lamina propria, some of them containing red blood cells (Fig. 1). The endothelial cells in the superficial portion of the lesion were plump and exophytic, showing 'hobnail' cytomorphology. The cytoplasm was scant and nu-

Table I. Primary antibodies used in the study

SPECIFICITY	MANUFACTURER	CLONE/TYPE	DILUTION
CD31	DAKO	JC70A	1 : 20
CD34	DAKO	QBEnd 10	1 : 50
Ki-67	DAKO	MIB-1	1 : 100
D2-40	COVANCE	D2-40	RTU

RTU – 'ready to use'

clei were large without visible nucleoli (Fig. 2). Some of the nuclei showed random hyperchromasia, but neither true atypia nor mitotic figures were present. In the deeper portion, beside large vascular spaces, there were also smaller, non-arborizing vessels, forming slit-like spaces, some of them dissecting collagen fibers. The endothelia of these vessels were rather flat (Fig. 3). A sparse to moderately dense perivascular lymphocytic infiltration with occasional polymorphonuclears was present. Immunohistochemically, the endothelia were positive for the usual markers, such as CD31 and CD34. Some of the smaller vessels within the lesions showed positive reaction with D2-40 antibody. Single cells only were positive for Ki-67 proliferation marker (Fig. 4).

Discussion

Hobnail hemangioma (HH) is a benign vascular lesion showing peculiar endothelial cells' morphology. It was first described as *targetoid hemosiderotic hemangioma* in 1988. It may be seen both in children and the elderly, but most patients are in their 20s or 30s [5]. HH commonly affects the trunk (44%) and lower and upper extremities (40%); head and neck involvement, including mouth, is rarer (6%) [6].

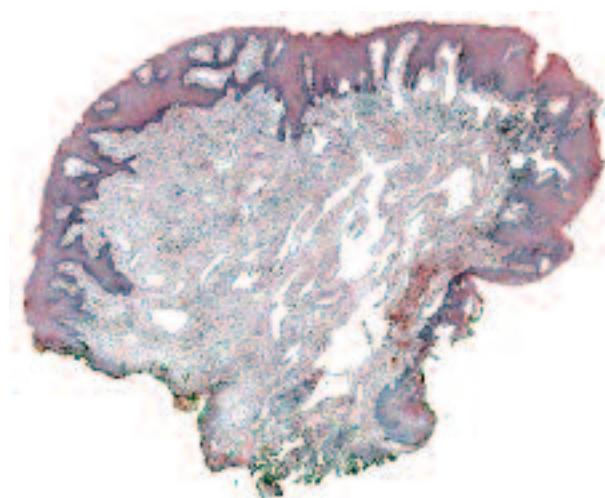


Fig. 1. On low magnification, a polypoid nodule, covered with thick squamous epithelium is seen. Larger and smaller vessels separated by fibrous stroma constitute the bulk of the lesion. HE, magnification 25×

Etiology of HH remains unclear. Physical injury, including injury of a preexisting hemangioma or ionizing radiations were proposed as causative factors, as well as increased vascular permeability and leakage of erythrocytes promoted by chronic inflammation [5, 7-9]. The gross 'targetoid' appearance is suggested to be a result of microshunts connecting lymphatic vessels and adjacent blood vessels. Due to capillary pressure, HH vessels are filled with erythrocytes, causing also

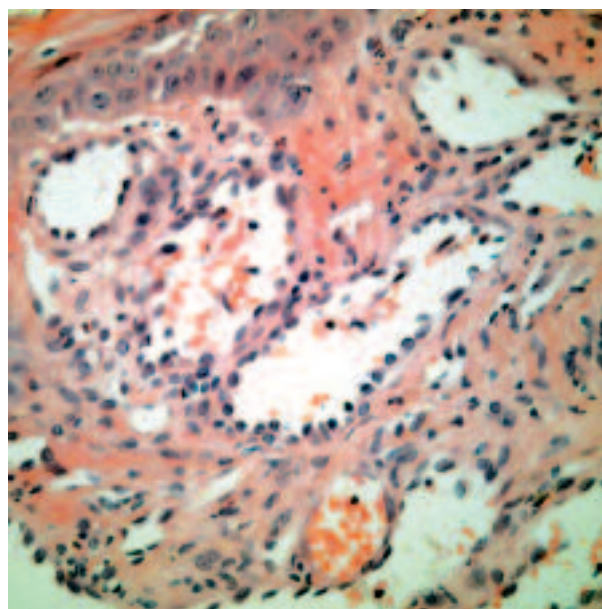


Fig. 2. Hobnail morphology of the endothelial cells. HE, magnification 400×

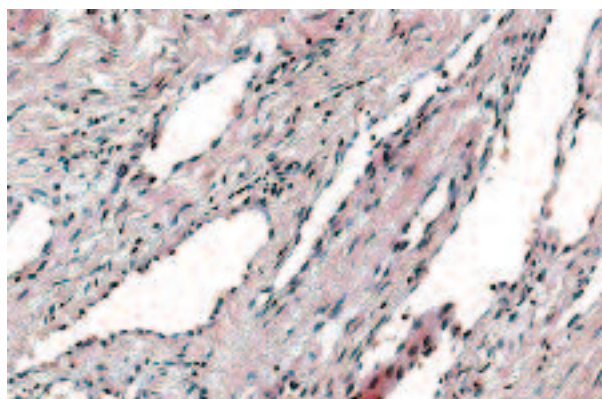


Fig. 3. Dissecting of the collagen fibers by the tumor vessels. HE, magnification 200×

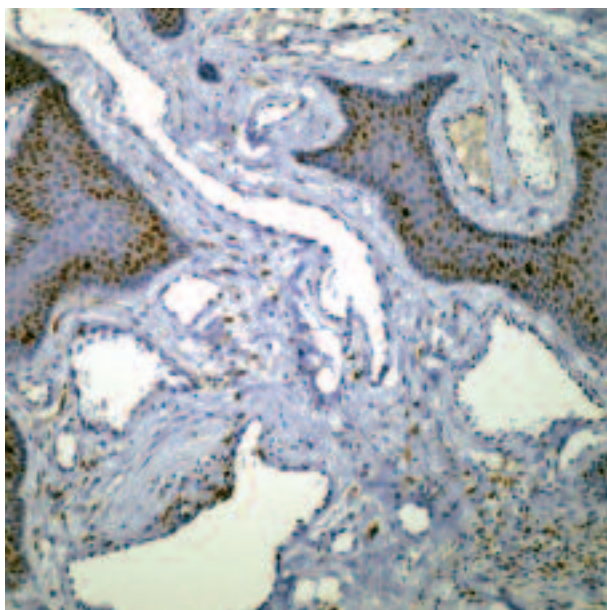


Fig. 4. Only smaller vascular spaces at the periphery are D2-40 positive. Immunohistochemistry, magnification 200×

aneurysmal dilatations, and obstruction of efferent lymphatic vessels. What is more, capillary pressure may also promote extravasation of erythrocytes and hemosiderin depositions in the interstitium, as well as inflammation and fibrosis [5].

Grossly, the typical HH is a small, targetoid lesion with a central violaceous papule and surrounding halo that can vary in color from tan to black. The discoloration is thought to be a result of red blood cells extravasation and hemosiderin depositions. The halo tends to disappear in older lesions [5].

In some female patients in the reproductive age, in the premenstrual phase, the HH may become more exophytic, violaceous and painful on palpation. After menstruation it turns to a painless, brownish plaque. There are also reports of HH enlarging during the pregnancy [5, 7]. This could be related to influence of estrogens, which are known to promote endothelial proliferation and rapid vascular dilatation. Surprisingly, in HH, stains for estrogen, progesterone and androgen receptor were reported as negative [7, 8].

The defining feature of HH is the hobnail morphology of the endothelial cells; another characteristic histological feature is a biphasic growth pattern consisting of superficial cavernous hemangioma-like dilated vascular spaces and narrow, slit-like vascular spaces in the deeper part of the lesion, growing in a quasi-infiltrative, collagen-dissecting pattern. In the superficial part of neoplasm, occasional endoluminal stromal papillary projections occur [3, 6], but endothelial cells show no multilayering or tufting [10].

Extravasated red blood cells and hemosiderin deposits are common, but not universally present [10]. Nuclei

of the endothelial cells can be hyperchromatic, but mitoses and true cytological atypia are absent and the nucleoli are small [3]. Old lesions become more fibrous and in the skin can imitate dermatofibroma [9].

On immunohistochemistry, HH endothelial cells express vascular endothelial markers as CD31, CD34, vWF, but also lymphatic endothelial markers such as podoplanin or VEGFR-3. In some cases, lack of expression of CD34 with reactivity with D2-40 only was described. In contrast to other vascular lesions, HH lacks actin-containing pericytes [2, 3, 11]. These features suggest lymphatic origin, at least in some cases [5].

Clinical differential diagnosis includes melanocytic nevus, malignant melanoma, Kaposi sarcoma, hemangioma, solitary angiokeratoma, dermatofibroma and insect bite reaction [6, 9]. Dermoscopy can help in establishing the correct diagnosis. In HH, dermoscopy shows sharply demarcated red round to oval structures and intermixed smaller, pale pink, round structures placed among a diffuse pink-white pigmentation. In some cases, a few sharply demarcated black macules representing hemorrhagic crust can be found [5]. Microscopically, a hobnail endothelial cell morphology similar to HH can be found in some non-targetoid and/or non-hemosiderotic benign hemangiomas, Dabska tumor, retiform hemangioendothelioma, and occasionally epithelioid hemangioendothelioma and conventional angiosarcoma [6]. Other lesions requiring distinction from HH include solitary angiokeratoma, retiform hemangioendothelioma, Kaposi sarcoma, benign lymphangioendothelioma, and well-differentiated angiosarcoma [6]. The main criterion lies in the cytologic features of the lesion as endothelial cells of HH show no atypia. Also the described architectural features of HH are fairly characteristic [5]. Other typical features of HH include small size, good circumscription, superficial location, prominence of dilated vessels, and a limited inflammatory infiltrate [3].

The infiltrative growth pattern of hobnail hemangioma makes the distinction from patch-stage Kaposi sarcoma difficult at times. However, HH usually shows widely dilated vascular spaces in the superficial portion of the lesion, which are not characteristic of Kaposi sarcoma. Also, vascular spaces in HH are lined by endothelial cells with a typical hobnail morphology, whereas in patch-stage Kaposi sarcoma, endothelium is flattened. Staining for HHV-8 should solve the diagnostic problem [5, 10].

In summary, we presented a rare vascular lesion, important for differential diagnosis with malignant vascular tumors.

References

1. Gutzmer R, Kaspari M, Herbst RA, et al. Absence of HHV-8 DNA in hobnail hemangiomas. *J Cutan Pathol* 2002; 29: 154-158.

2. Mentzel T, Partanen TA, Kutzner H. Hobnail hemangioma ("targetoid hemosiderotic hemangioma"): clinicopathologic and immunohistochemical analysis of 62 cases. *J Cutan Pathol* 1999; 26: 279-286.
3. Pabuccuoglu U, Ozkara E, Lebe B. Hobnail haemangioma occurring on the nasal dorsum. *Br J Dermatol* 2002; 146: 162-164.
4. Santa Cruz DJ, Aronberg J. Targetoid hemosiderotic hemangioma. *J Am Acad Dermatol* 1988; 19: 550-558.
5. Ibrahim M, Shwayder T. Hobnail hemangioma in a nine-year-old boy: a rare case presented with dermoscopy. *Dermatol Online J* 2010; 16: 7.
6. Rashmi MS, Alka KD, Seema C. Oral hobnail hemangioma – a case report. *Quintessence Int* 2008; 39: 507-510.
7. Hong W, Song H, Lee H, et al. Hobnail haemangioma associated with a secondary sexual characteristic. *J Eur Acad Dermatol Venereol* 2009; 23: 465-466.
8. Ortiz-Rey JA, González-Ruiz A, San Miguel P, et al. Hobnail haemangioma associated with the menstrual cycle. *J Eur Acad Dermatol Venereol* 2005; 19: 367-369.
9. Sahin MT, Demir MA, Gunduz K, et al. Targetoid haemosiderotic haemangioma: dermoscopic monitoring of three cases and review of the literature. *Clin Exp Dermatol* 2005; 30: 672-676.
10. Guillou L, Calonje E, Speight P, et al. Hobnail hemangioma: a pseudomalignant vascular lesion with a reappraisal of targetoid hemosiderotic hemangioma. *Am J Surg Pathol* 1999; 23: 97-105.
11. Franke FE, Steger K, Marks A, et al. Hobnail hemangiomas (targetoid hemosiderotic hemangiomas) are true lymphangiomas. *J Cutan Pathol* 2004; 31: 362-367.

Address for correspondence

Krzysztof Okoń
Department of Pathomorphology
Collegium Medicum
Jagiellonian University
ul. Grzegórzecka 16
31-531 Kraków
e-mail: mpokon@cyf-kr.edu.pl