

# The morphological appearance of the palatine torus in the Cracovian skulls (XV–XVIII century)

Janusz Skrzat, Dominika Holiat, Jerzy Walocha

Department of Anatomy, Collegium Medicum, Jagiellonian University, Kraków, Poland

[Received 16 May 2003; Accepted 27 June 2003]

*The paper presents a morphological analysis of the palatine torus of the Cracovian skull dated from XV–XVIII<sup>th</sup> century. The cranial collection analysed comprised 98 skulls with the hard palate preserved but only 27 male and 28 female skulls showed the palatine torus. The length, breadth and height of the palatine torus were measured, and a visual inspection of the position and form of the torus was performed. Our findings suggest that most typical of the skulls analysed is a medium-sized mound-shaped palatine torus in an antero-posterior position, which means that the torus occupies the palatal processes of the maxilla and the horizontal plates of the palatine bones along the mid-palatine suture. Mean parameters of the palatine torus were established as: length — 25.7 mm (male) and 28.3 mm (female), width — 10.8 mm (male) and 10.2 mm (female), height 2.7 (male) and 3.2 mm (female). There are no significant differences between mean values of the parameters of the palatine torus.*

**key words:** palatine torus, torus palatinus, hard palate

## INTRODUCTION

The palatine torus /torus palatinus/ is a slowly growing bony elevation that sometimes exists on the hard palate along the mid-palatine suture and inter-palatine suture. However, the anatomical position of the palatine torus varies according to the transverse palatine suture. It may extend forwards or backwards towards the transverse palatine suture, and sometimes the torus is located in the area of intersection of both palatine sutures, forming an oval elevation (Fig. 1). The palatine torus consists of compact bone externally and spongy bone internally [13, 14].

Anthropological and anatomical studies have reported variously concerning the frequency and morphology of this cranial feature. Existing investigations into the palatine torus are not always comparable and its morphology is studied on living individuals or in collections of dry skulls [9].

The etiology of the palatine torus has been considered by many scientists who have argued for dif-

ferent reasons for its formation and its dependence on various factors which have an impact on palatal morphogenesis [12, 14]. Apparently the palatine torus has no functional importance, unless it is extremely large, in which case it may cause discomfort in the oral cavity. The morphology of the palatine tori of the human skull is also of clinical importance in the administration of palatal surgery and in orthodontic practice [8]. The occurrence of the palatine torus is meaningful in the event of necessary prosthetic management in the oral cavity. It may then significantly interfere with the stabilisation of the denture, which has to be mounted in the oral cavity and adhere precisely to the vault of the palate. Understanding of the appearance and variation of this structure is therefore the concern of investigators of different biomedical sciences.

Because there is a lack of effective data on the morphology and occurrence of the palatine torus in the Polish population, we undertook an analysis of

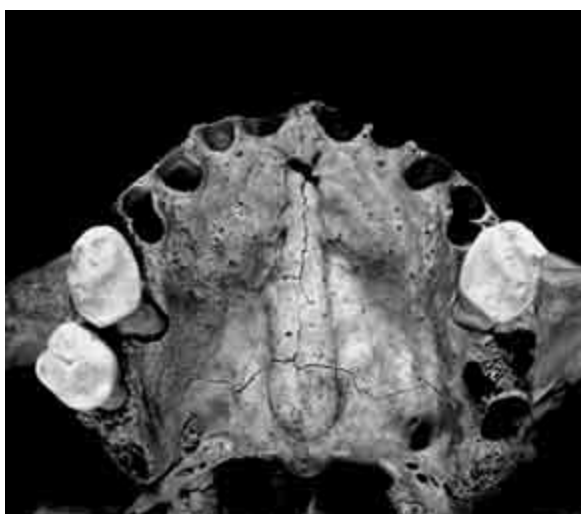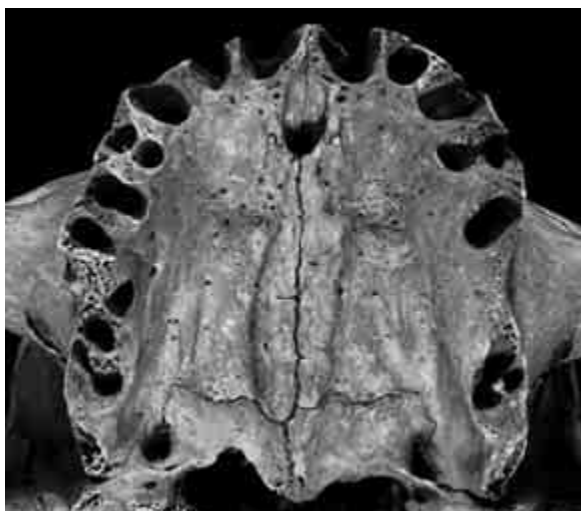


Figure 1. External forms of the palatine torus.

this feature in the Cracovian skulls, the results of which might serve as a contribution to the cross-sectional and comparative study of the past and present populations.

### MATERIAL AND METHOD

Palatine tori were analysed on dry skulls from the Anthropological Museum of the Department of Anthropology of the Jagiellonian University in Cracow. The cranial set derives from a period of XV–XVIII<sup>th</sup> century. The whole Cracovian cranial set comprises 203 skulls of known sex (99 male skulls and 104 female skulls). From the entire collection only 98 skulls have been investigated as these had preserved the hard palate and 61 of these skulls manifested the presence of the palatine torus (27 male and 28 female). That subset was subjected to morphometrical analysis.

The morphological appearance of the palatine torus was analysed by visual inspection and its position was recorded in the hard palate. Additionally, measurements of the length, breadth and height of the palatine torus were performed using a sliding and a co-ordinated caliper respectively and the results were recorded in millimeters. The length of the palatine torus was measured from the beginning to the end along the mid-sagittal line and the breadth was measured at its widest part.

The size of palatine torus was rated as small, medium or large according to the classification applied by Woo [14] (Table 1). The form of the palatine torus was evaluated as ridge, mound or lump. The ridge form is a torus that is relatively narrow and uniform in width. A torus, which is relatively wide and tapers anteriorly and posteriorly, is termed as being in mound form. The palatine tori of irregular shape are classified as being in lump form [6]. The percentage of each type of palatine torus was counted in both sexes.

We employed a two-sample analysis to detect statistical differences between the diameters of the palatine tori of male and female skulls.

### RESULTS

Statistical data for the palatine tori analysed are assembled in Table 2 and the percentage occurrence of size, form and position of the palatine torus in the skulls examined are presented in the graphs (Fig. 2, 3).

Table 1. Classification of the size of the palatine torus (in millimeters)

	Elevation	Width	Length
Small	Under 3	Under 10	Under 15
Medium	3–5	10–15	15–25
Large	Above 5	Above 15	Above 25

Table 2. Means and range of variation in the diameters of the palatine torus for 27 male and 28 female skulls

	Length		Width		Height	
	Male	Female	Male	Female	Male	Female
Mean	25.7	28.3	10.8	10.2	2.7	3.2
Std. dev.	8.6	7.4	4.6	3.8	0.7	1.9
Min	13.0	10.0	4.0	3.0	2.0	1.0
Max	39.0	38.0	22.0	21.0	4.0	10.0

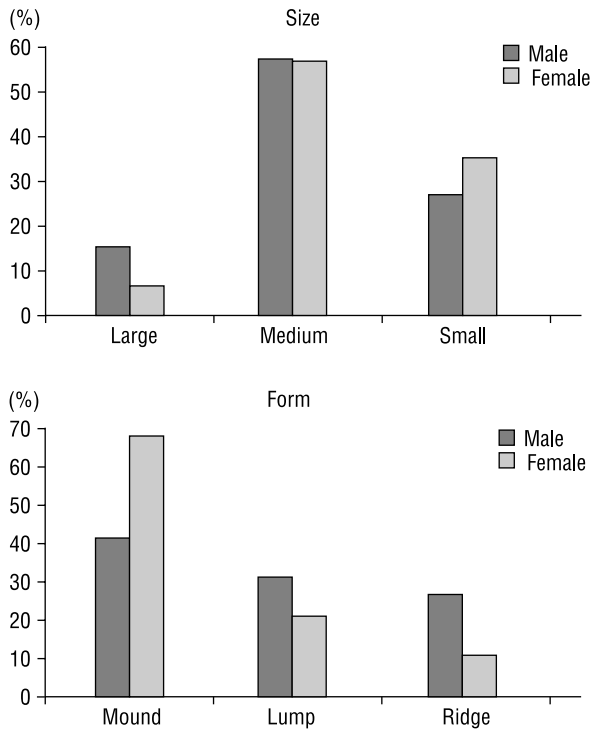


Figure 2. Distribution of size and form of the palatine torus.

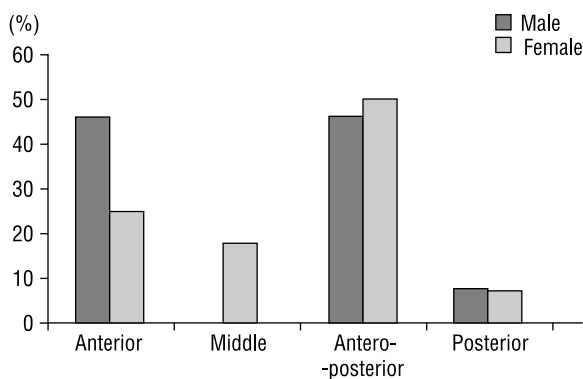


Figure 3. Position of occurrence of the palatine torus.

The statistical test did not show significant differences in means of length, width and height of the palatine torus between the male and female skulls.

The palatine tori analysed can be classified as large, medium and small but the medium size was the most frequently occurring in both sexes. Large tori were more typical for male skulls and small tori are often found in female skulls.

The mound form of the palatine torus was dominant in the analysed skulls in both sexes, but in the case of female skulls there is an overwhelming dominance of this form and it constitutes nearly 70%.

The ridge form is uncommon in the female skulls (10%), while the ridge form and lump form are similarly distributed among the male skulls.

In the skulls studied the palatine torus was located along the mid-sagittal line of the hard palate and did not deviate from this line. The anatomical position of the analysed palatine torus varies according to the transverse palatine suture. All positions were recorded, except the middle position of the torus in the female skulls. The most typical was the antero-posterior position, where the torus extends along the mid-palatinal and interpalatine sutures. The posterior position of the torus (occupying only the horizontal plates of the palatal bones) was the rarest in both sexes.

## DISCUSSION

The palatal torus varies in form and size. Woo reported that the greatest normal length reached by the torus is 50 mm, the width 23 mm and the height 8 mm and Martin mentioned a torus with an elevation of 12 mm [11, 14]. The palatal tori analysed in the Cracovian skulls correspond in their diameters to the data cited.

As presented in literature, there is a population variation in the occurrence of the palatine torus. The frequency of the palatine torus varies significantly both for male and female skulls. In our case the frequency of the palatine torus is equal in both sexes in the sample analysed and is estimated as 56%. For comparison, Zivanovic found the palatine torus present in 33.5% of males and 49% of females of the skulls in the Galloway Collection. In the medieval Slavonic series of cranial sets the palatine torus was found in 53.33% of male and 46.66% female skulls [15]. In Korean skulls the palatine torus was found in 18.8%, while in skulls from Kenya the torus was observed in 4.8% [3, 10].

As noted, the palatine torus shows a marked morphological variation and frequency. In our case the results of a frequency analysis of the torus are not very representative of the whole population, because the majority of the skulls did not preserve the facial skeleton, so that we were not able to observe their palatal morphology and to conclude whether the frequency would be different. Nevertheless, it seems that the palatine torus appeared quite often in the cranial set analysed, so that one may presume that its occurrence might be typical for the Cracovian population. This view needs verification from other cranial series from Cracow, which would be more numerous and coherent chronologically.

The palatine torus shows a hereditary tendency and is coupled with racial variation [13]. Thus this cranial trait might be helpful in identifying population groups which show a prevalence of palatine tori. We did not analyse the association between the presence or morphology of the palatine torus and the racial character of the skulls examined because this was not a goal of this study. However, on the basis of the results of a typological analysis performed by Kaczanowski on the Cracovian skulls studied, 46% of the male and 43% of the female skulls belong to the Laponoidal type [7]. This constitutes a relatively high percentage of a selected racial group (Laponoid) in the cranial set studied. We therefore hypothesise that our cranial set may confirm the view that the palatine torus is a characteristic feature of Laponoid skulls. According to the findings of Hooton, the palatine torus occurs with a higher frequency among populations in the northern world [5] and the Laponoidal race originates in these habitats.

There are current studies of the occurrence of the palatine torus but these refer in most cases to the American or other populations [1, 4]. Unfortunately, we did not make any profound discovery about the occurrence of the palatine torus in the contemporary Cracovian or Polish population. El-Nofely claims that the palatine torus was often found in both males and females living in the area of Augustov in northeast Poland, but this can be the effect of an analysis performed on an isolated ethnic group [2]. Thus we conclude that our study may give a brief insight into the morphological and comparative analysis of the palatine torus in Polish human crania.

## REFERENCES

1. Chochayeb AA, Volpe AR (2001) Occurrence of torus palatinus and mandibularis among women of different ethnic group. *Am J Dent*, 14: 278–280.
2. El-Nofely A (1976) Some observations on the dentition of an isolated group in northeast Poland. *Am J Phys Anthropol*, 44: 123–126.
3. Hassanali J, Mwaniki D (1984) Palatal analysis and osteology of the hard palate of the Kenyan African skulls. *Anat Rec*, 209: 273–280.
4. Haugen LK (1992) Palatine and mandibular tori. A morphologic study in current Norwegian population. *Acta Odontol Scand*, 50: 65–77.
5. Hooton EA (1918) On certain Eskimoid characters in Icelandic skulls. *Am J Phys Anthropol*, 1: 53–76.
6. Hooton EA (1946) *Up from the ape*. 2<sup>nd</sup> ed. Macmillan Co., New York.
7. Kaczanowski K (1965) *Czaszki przy kościele Mariackim w Krakowie (XV–XVIII w.)*. Materiały i Prace Antropologiczne, 71: 57–112.
8. Kerdpon D, Sirirungrojying S (1999) A clinical study of oral tori in southern Thailand: prevalence and relation to parafunctional activity. *Eur J Oral Sci*, 107: 9–13.
9. Kronenberger H (1981) The torus palatinus. *Anthropol Anz*, 39: 150–157.
10. Lee SP, Paik KS, Kim MK (2001) Variations of the prominences of the bony palate and their relationship to complete dentures in Korean skulls. *Clinic Anat*, 14: 324–329.
11. Martin R (1928) *Lehrbuch der Anthropologie*, Jena.
12. Sawyer DR, Allison MJ, Elzay RP, Pezzia A (1979) A study of torus palatinus and torus mandibularis in pre-Columbian Peruvians. *Am J Phys Anthropol*, 50: 525–526.
13. Suzuki M, Sakai T (1960) A familial study of torus palatinus and torus mandibularis. *Am J Phys Anthropol*, 18: 263–272.
14. Woo JK (1950) Torus Palatinus. *Am J Phys Anthropol*, 8: 81–111.
15. Zivanovic S (1980) Longitudinal grooves and canals of the human hard palate. *Anat Anz*, 147: 161–167.