

Contents lists available at [ScienceDirect](https://www.sciencedirect.com)

Visual Journal of Emergency Medicine

journal homepage: www.elsevier.com/locate/visj

Visual Case Discussion

A novel presentation of COVID-19 via community acquired infection

Jaclyn H. Jansen*, Rachel L. Day

Department of Emergency Medicine, Indiana University School of Medicine, Indianapolis, IN, USA



ARTICLE INFO

Keywords:

SARS-CoV-2
COVID-19
Coronavirus
Lung disease
Viral

1. Discussion

COVID-19 is a novel coronavirus first detected in Wuhan, China in late 2019. Shortly after, it was detected in the United States by mid-January 2020^{1,3}. The virus can cause severe respiratory tract infections in its host more often in the elderly, immunocompromised, or individuals with multiple medical comorbidities³. Current data suggests that while up to 80% of those infected are either asymptomatic or experience mild symptoms, 15% of those infected will have severe disease requiring hospitalization, and 5% will require intensive care and mechanical ventilation². Typical symptoms include fever (88.7%), dry cough (67.8%), and fatigue, with symptoms such as sputum production, sore throat, headache, and GI symptoms occurring less commonly².

2. Visual case discussion

A 76 year old male patient presented with his wife for altered mental status and lethargy. The patient's wife stated that for the last three days the patient "had not seemed himself". She described some confusion at home and decreased interaction. She reported the patient had not had fevers at home or dry cough, however she had recently experienced a dry cough. The couple spent the previous weekend at a nearby casino after taking public transit. The patient and wife had no recent long distance of international travel and no known sick contacts or known exposure to COVID-19 + patients. The patient had no known history of pulmonary disease.

When vital signs were obtained the patient was found to have an oxygen saturation of 70% on room air. The patient was tachypneic to a rate of 23 but did not appear to be in respiratory distress and was able to answer questions in full sentences. Lung sounds were clear

bilaterally. The patient was moved to an isolation room and was placed on 15 L O₂ via non-rebreather mask.

The patient was then weaned and able to maintain oxygen saturation of 93% on 5 L via nasal cannula. Cell counts and electrolytes were within normal limits. The patient was negative for Flu A/B and had a negative respiratory viral panel. Chest X-ray obtained showed non-specific bibasilar airspace disease (Fig. 1). Of note, the patient's D-dimer was elevated to 2574 and CT imaging was ordered to evaluate for pulmonary embolism. CTA of the chest with PE protocol revealed bibasilar opacities. The patient was admitted to the progressive care unit for respiratory support and COVID-19 rule out.

On follow-up, patient tested positive for COVID-19 with declining respiratory status over the next 24 h. He was upgraded to the intensive care unit for high flow nasal cannula at 25 L/min with FiO₂ of 0.6.

Questions

- What is the R⁰ for COVID-19? How does this compare to the R⁰ for typical influenza?
 - 0.5, less than typical flu
 - 1.3, the same as typical flu
 - 1.5–1.8, the same as pandemic flu
 - 2.2, higher than pandemic flu
 - 3.0, the same as pandemic SARS
- What lab abnormalities can be expected in COVID-19+ patients?
 - Lymphopenia
 - Elevated pro-calcitonin
 - Elevated D-dimer
 - A and B
 - A and C

* Corresponding author.

E-mail address: jacjans@iu.edu (J.H. Jansen).<https://doi.org/10.1016/j.visj.2020.100760>

Received 23 March 2020; Accepted 24 March 2020

2405-4690/© 2020 Elsevier Inc. All rights reserved.

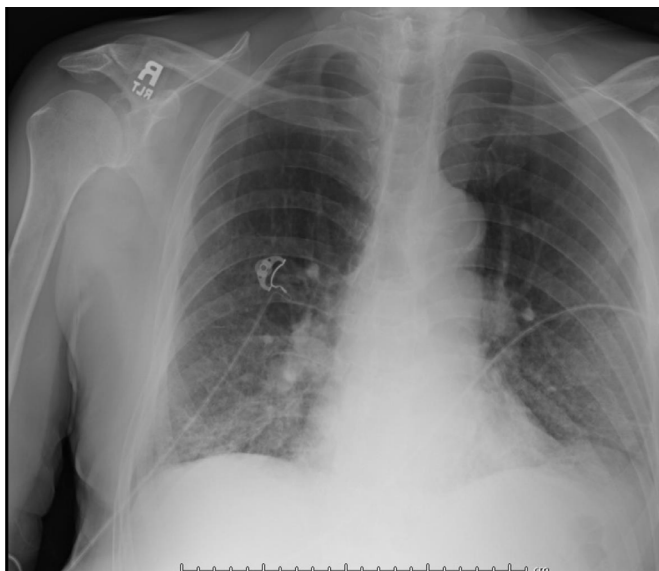


Fig. 1. Chest Radiograph (AP view): Upper lung emphysematous changes. Nonspecific bibasal airspace disease which could represent atypical infection or pulmonary edema superimposed on chronic inflammatory changes. Stable mediastinal contour and heart size. No large effusion or pneumothorax.

- f B and C
- g All of the above

Answers

- 1 **Correct Answer = D, Explanation:** The R^0 is the expected number of secondary cases produced by a single typical infection in a susceptible population. Based on the most up-to-date statistics, COVID-19 is considered highly virulent with an expected R^0 of at least 2.2 much higher than the R^0 of seasonal flu, which is typically closer to 1.3.¹
- 2 **Correct Answer = E, Explanation:** Patient typically present with lymphopenia and mildly elevated AST and ALT. Procalcitonin is normal. Patient who present with severe lymphopenia and elevated D-dimer has an associated increased risk of mortality.¹

Declaration of Competing Interest

None

References

1. Cascella, Marco, et al. "Features, evaluation and treatment coronavirus (COVID-19)." StatPearls [Internet]., U.S. National Library of Medicine, 8 Mar. 2020, www.ncbi.nlm.nih.gov/books/NBK554776/#article-52171.s3.
2. Guan Wei-Jie, et al. Clinical characteristics of coronavirus disease 2019 in china. *N Engl J Med.* 2020. <https://doi.org/10.1056/nejmoa2002032>.
3. Jernigan, Daniel B. "Update: public health response to the coronavirus disease 2019 outbreak - United States, february 24, 2020." Centers for Disease Control and Prevention, Centers for Disease Control and Prevention, 27 Feb. 2020, www.cdc.gov/mmwr/volumes/69/wr/mm6908e1.htm.



Since January 2020 Elsevier has created a COVID-19 resource centre with free information in English and Mandarin on the novel coronavirus COVID-19. The COVID-19 resource centre is hosted on Elsevier Connect, the company's public news and information website.

Elsevier hereby grants permission to make all its COVID-19-related research that is available on the COVID-19 resource centre - including this research content - immediately available in PubMed Central and other publicly funded repositories, such as the WHO COVID database with rights for unrestricted research re-use and analyses in any form or by any means with acknowledgement of the original source. These permissions are granted for free by Elsevier for as long as the COVID-19 resource centre remains active.