

Canine Impaction- A Review of the Prevalence, Etiology, Diagnosis and Treatment

Yusuke Hamada, D.D.S, M.S.D,

Clinical Assistant Professor, Associate Program Director, Department of Periodontology, Indiana University School of Dentistry. Indianapolis, IN, USA

Celine Joyce Cornelius Timothius BDS, MSc, MS

Graduate Student, Department of Periodontology, Indiana University School of Dentistry.

Indianapolis, IN, USA

Daniel Shin, D.D.S, M.S.D,

Clinical Assistant Professor, Director, Pre-Doctoral Periodontics, Department of Periodontology, Indiana University School of Dentistry. Indianapolis, IN, USA

Vanchit John, D.D.S, M.S.D,

Chairperson, Associate Professor, Department of Periodontology, Indiana University School of Dentistry. Indianapolis, IN, USA

Correspondence to Dr. Vanchit John

1121 W. Michigan St, Indianapolis, IN, 46202. U.S.A,

Email: vjohn@iu.edu Phone: 317-274-5124, Fax: 317-274-1363

Authors declare that there is no conflict of interest any products and devices discussed in this article.

This is the author's manuscript of the article published in final edited form as:

Hamada, Y., Timothius, C. J. C., Shin, D., & John, V. (2019). Canine impaction – A review of the prevalence, etiology, diagnosis and treatment. *Seminars in Orthodontics*, 25(2), 117–123. <https://doi.org/10.1053/j.sodo.2019.05.002>

Abstract:

The signs and symptoms of canine impaction can vary, with patients only noticing symptoms when they are suffering from unsightly esthetics, faulty occlusion, or poor cranio-facial development. While various surgical interventions have been proposed to expose and help erupt impacted canines, these treatment modalities have a high degree of difficulty compared to other types of dental cosmetic surgeries. This paper focuses on multi-disciplinary strategies for treating and managing canine impaction, reviews patient and clinical selection criteria, and discusses the evidence underlying existing interventions to reduce complications and improve patient-centered outcomes following treatment.

Introduction:

An impacted tooth is defined as a tooth that fails to erupt after the normal development pattern is complete. Maxillary canines are the most common impacted tooth, following the third molar teeth. Tooth impaction is often diagnosed during routine dental examination by pediatric dentists, orthodontists, or general dentists. The early detection, timely management, and appropriate surgical and orthodontic intervention can lead to esthetically and functionally acceptable outcomes. An interdisciplinary patient care approach with specialists from different disciplines- orthodontists, pediatric dentists, periodontists, oral surgeons and general dentists- cooperating and collaborating together is necessary to manage this condition successfully. Proper positioning and alignment of canines plays an extremely important role in establishing an acceptable facial contour, esthetic smile line, and occlusion especially for canine guidance or group function occlusion. If this condition is not treated properly, the outcome of orthodontic treatment might be less desirable and the treatment duration might be extended. Additionally,

under certain circumstances, the presence of an impacted canine may play a role in root resorption of adjacent teeth. Thus, the aims of this paper are to review the prevalence and the etiology of canine impaction, methods for the radiographic assessment of canine impaction, and treatment intervention based on the labio-lingual position of impacted canines. A patient case accompanies this article to highlight several key steps in treating and managing impacted canines.

Prevalence and Etiology of Canine Impaction:

The maxillary canine is the second most commonly impacted tooth following the maxillary third molar. Yet, the prevalence of the impacted maxillary canine is actually quite low, with the prevalence ranging from 0.92% to 2.2% of the population, and a predilection to affect females more often than males, at a ratio of 2:1.^{1,2} Furthermore, the unerupted impacted maxillary canine tends to be positioned more palatally than labially, at a ratio of 2:1 or 3:1.³ In comparison, the prevalence of the mandibular canine impaction is lower (0.35%) than that of the impacted maxillary canine.²

While the exact etiology of the unerupted impacted maxillary canine remains somewhat elusive, there is strong evidence to suggest that multiple broad and complex mechanisms- namely, genetic, systemic (like endocrine disorders, febrile conditions, and/or irradiation), and local factors- are involved. Several local factors- such as 1) tooth size–arch length discrepancies; 2) failure of the primary canine root to resorb; 3) prolonged retention or early loss of the primary canine; 4) ankylosis of the permanent canine; 5) cyst or neoplasm; 6) dilaceration of the root; 7) absence of the maxillary lateral incisor; 8) variation in root size of the lateral incisor (peg-shaped

lateral incisor); and 9) variation in timing of lateral incisor root formation, are believed to play critical roles in canine impaction.

Of all the local factors listed above, arch length deficiency is believed to be the most common cause of labially impacted canines. Jacoby observed that while approximately 85% of palatally impacted canines had sufficient space for eruption, only 17% of labially impacted canines had sufficient space to erupt in the arch.⁴ Therefore, it was proposed that the primary etiology of the labially impacted canines is insufficient arch length which limits the amount of space available for the unerupted canine to erupt normally. On the other hand, for palatally impacted canines, the absence of the maxillary lateral incisor is believed to be the most common cause for eruption failure. In order for a canine to erupt normally into the arch, the prevailing theory is that the root of the adjacent lateral incisor serves as a “guide” for the canine to erupt along it. However, when the adjacent lateral incisor is either missing or malformed, there is no “guide” for the canine to travel along; as a result, the canine will fail to erupt. This is known as the “guidance theory.” To further substantiate this important relationship between the erupting canine and the maxillary lateral incisor, Becker reported an increase of 2.4 times in the incidence of palatally impacted canines adjacent to missing lateral incisors compared to palatally impacted canines in the general population.⁵

Clinical and Radiographic Assessments:

Clinical examination usually involves a comprehensive periodontal examination. Clinical signs of canine impaction include the retention of primary canines and an absence of buccal and palatal bulges when compared to the contralateral side of the affected area after a patient reaches 12-15 years of age.¹ Careful palpation of the alveolar housing would be useful for clinicians to

identify the presence or absence of bulges. Other possible clinical signs include tipping or irregular positioning of adjacent teeth.

Although palpation of the alveolar ridge is one way of the most common clinical methods to identify the location of the impacted canines, sometimes impacted canines are not clinically palpable. Ericson showed that approximately 3-5% of impacted teeth are not clinically palpable based only on the clinical examinations.^{6,7} Consequently, due to the limitations of clinical examinations, many radiographic assessment methods, such as panoramic, periapical, occlusal, and lateral cephalometric radiographs have been utilized to evaluate the presence and position of impacted canines. If the tooth is not palpable, 2 or more periapical radiographs taken at different angles can confirm the position of the impacted tooth by utilizing the principle of the SLOB or Clark's rule. The SLOB rule means "Same Lingual, Opposite Buccal". If the beam angle moves mesially, then the image of the impacted canine moves mesially too. This means the impacted tooth might be located on the lingual or palatal side. On the other hand, if the beam angle moves distally and the image of the impacted canine moves mesially, the tooth is likely located on the buccal side. This principle has been useful to locate the position of the tooth. Approximately 90% of the time, clinicians can identify the position of an impacted tooth on the labial or palatal sides.⁶ However, there are many limitations including measuring the exact distance from the impacted tooth to the adjacent teeth and identifying the presence or absence of root resorption on adjacent teeth. Orthodontists and surgeons need to be aware of the precise position of the tooth in order to generate appropriate treatment plans. Three dimensional analysis with cone beam computed tomography (CBCT) has significantly improved our ability to localize the position of the tooth accurately. After obtaining a CBCT scan, a panoramic radiograph can also be

recorded. The customized arch is made on the panoramic view, and the customized slice view can be used for accurate detection of tooth position. (Figure 1. 2) In addition to those sliced views, a 3D reconstructed view can be useful in identifying the exact location of an impacted canine. (Figure 3)

Haney assessed inherent discrepancies when comparing 2D images to 3D images in the diagnosis and treatment planning of impacted canines. The results showed that all clinicians have a much higher degree of confidence of the precise position of the impacted teeth with CBCT images. Due to differences in assessing the accurate position and the relationship of the cusp tip location to adjacent tissue, 2D and 3D images generate different images on the same patients.⁸ CBCT also provides an additional benefit in identifying the prevalence of root resorption on the central and lateral incisors. Ericson revealed that the prevalence of root resorption associated with canine impaction was 12% of lateral incisors with conventional 2D images.⁷ On the other hand, when using CBCT imaging, these same authors found that 38% of lateral incisors and 9% of central incisors have some degree of root resorption with impacted canines. This study revealed that the detection of root resorption increased almost 50% with CT scanning.⁹ The presence of root resorption might affect the overall treatment plan whether extraction or retention of those affected teeth are indicated. If extraction is indicated due to the severity of root resorption, the orthodontic and restorative treatment plans need to be modified accordingly.¹⁰ Therefore the use CBCT can definitely contribute to accurate and timely diagnosis and lead to proper treatment intervention.

Treatment Interventions (Classification of Canine positions):

Canine impactions are broadly classified based on their labio-palatal positions in relation to the alveolar ridge, the axial inclination and the depth of the impacted tooth^{11,12}. Several classification systems have been formulated describing the location of the impacted canines, thus guiding the clinician in choosing the most predictable treatment option. The position of the impacted tooth is usually classified per their relation to the neighboring teeth and anatomical structures. Similarly, mandibular impacted canines were classified based on their labial and unusual anatomical positions. The presence of the ectopic maxillary canine based on the location of impaction and relation to the neighboring lateral incisor root was classified by Chapokas, as: *Class I*- palatal location, *Class II*- center of the alveolar ridge or labial to the alveolar crest, without labial superimposition to the root of the adjacent lateral incisor and *Class III*- labial to the long axis of the adjacent lateral incisor root¹¹. This classification was specifically formulated to guide the clinician in deciding the most optimal surgical interventional technique for their eruption.

Spontaneous correction of an impacted canine is highly predictable if the deciduous tooth is removed when the crown of the permanent ectopic canine was positioned over the root of the maxillary lateral incisor, not past the mesial surface of the tooth. Surgical uncovering of the impacted canine is necessary when the tooth is positioned beyond the mesial root surface of the lateral incisor.¹³

In the presence of labially impacted maxillary canines, Kokich recommends the usage of three technique for surgical eruption: *gingivectomy, apically positioned flap and closed eruption techniques*.¹³ Facially impacted canines can be uncovered by an open or a closed approach based on the adequacy of keratinized gingiva and the position of the impacted tooth within the alveolar

housing. Coronally positioned labially impacted canines with adequate amount of keratinized tissue can be uncovered by any of the three techniques. When these ectopic canines are not covered by bone, gingivectomy is the most preferred approach as it leads to spontaneous eruption without any orthodontic traction and is less traumatic to the patient. However, this is a rarely used technique due to the possible loss of keratinized gingiva and damage to the surrounding healthy periodontium.^{13, 14}

Apically positioned flaps are indicated when the impacted canine is apical to the muco-gingival junction and is labially superimposed on the adjacent root of the lateral incisor. A partial thickness flap is reflected with mesial and distal vertical releasing incisions and apically positioned. This surgical technique conserves the amounts of keratinized gingiva available, since these situations are usually accompanied by a reduced width of keratinized gingiva. Frequent occurrence of post-operative gingival recession and orthodontic relapse are commonly associated with this technique.^{11, 13}

When the ectopic maxillary canine is located significantly apically to the muco-gingival junction, a closed eruption technique is advised. This technique is implemented by the reflection of a full-thickness flap followed by the debridement of the surrounding follicle. A fixed attachment is immediately bonded to the exposed tooth surface and a wire or chain is attached. The flap is repositioned with the wire or chain emerging through the initial crestal incision and tied to orthodontic wire passively. This would allow the orthodontist to apply traction to erupt the impacted canine to the desired position.^{2, 13} Closed eruption techniques are usually accompanied by a higher frequency of post-operative complications and incomplete eruption necessitating a second surgery.¹⁴

Palatally impacted canines can also be surgically erupted using a closed or open approach, depending on the location of the ectopicity. Most palatal canine impactions can be surgically approached via a gingivectomy procedure, facilitating spontaneous eruption. A fixed attachment appliance is recommended to be connected immediately after exposure, should the spontaneous eruption fail to occur.¹⁵ Open exposure techniques for palatally impacted canines can be made with an open window eruption or a tunnel traction. When the canine is horizontally positioned near the lateral and central incisors, an open window eruption technique allows visualization of the crown and guiding the impacted tooth to the desired location. However, when the horizontally inclined impacted canines are positioned higher up in the maxillary arch, a closed flap technique is recommended followed by immediate orthodontic traction. Some of the most common complications associated with these procedures are gingival overgrowth at the surgical site and high infection rate.^{13, 14}

Tunnel traction is recommended when the primary canine is present at the time of the surgical intervention. After the reflection of a full thickness flap, a tunnel is created by extracting the deciduous canine and removing adequate bone at the seat of the deciduous canine root allowing the eruption of the ectopic canine via traction.¹⁶

Since mandibular impacted teeth are usually located at a labial or intra-alveolar position, a closed flap approach to orthodontically erupt the tooth to an ideal position is recommended. However, in cases of severe impaction or transmigration, mandibular impacted teeth are more challenging to treat orthodontically. In these situations, it would be prudent to extract the canine instead of performing any surgical intervention to preserve the available bone and avoid damaging adjacent tooth roots.¹³

Despite the technical differences in the closed and open surgical exposure of impacted canines, several studies have shown minimal statistical differences in the surgical outcomes and post-operative adverse symptoms.^{17, 18}

Case:

A 19-year old patient was referred to the Graduate Periodontology Clinic at the Indiana University School of Dentistry for surgical exposure and recovery of the impacted mandibular left canine. (Figure 4) Upon palpation, a slight prominence on the buccal keratinized gingiva in the missing tooth #22 area was noted. (Figure 5) A CBCT image was taken to confirm the buccal positioning of the impacted canine. Additionally, the CBCT showed a buccal dehiscence associated with the impacted tooth. (Figure 6) Since most of the anatomic crown of #22 was positioned apical to the mucogingival junction in a vertical dimension, a closed approach was selected as the interceptive treatment. After the muco-periosteal flap was elevated, the coronal aspect of #22 was visualized and accessed. The dental follicle was removed from the coronal aspect of the impacted tooth with a curette. To determine whether the impacted tooth was ankylosed, the authors utilized an elevator to check for movement of the tooth. Obtaining proper hemostasis and salivary control was essential to securing the gold button of the orthodontic chain to the anatomic crown of the tooth. (Figure 7) Primary closure was then obtained and the gold chain was tied to the orthodontic arch wire to reduce premature mobility of the chain and movement of the overlying soft tissue. (Figure 8) At subsequent surgical follow ups, no adverse post-surgical events were noted, and the patient was referred back to the orthodontist to activate the force on the impacted canine. (Figure 9)

Conclusions:

Tooth impaction profoundly impacts esthetics and function for patients. However, there is increasing recognition among dental health care providers that treatment intervention poses challenges and are intricate and fallible, owing largely to the complex interrelationships between normal craniofacial development, functional outcomes, and esthetic results. This review paper is timely because the number of articles related to the surgical treatment and management of impacted canines is on the rise. The case study provided in this paper suggests that early diagnosis and interception of impacted canines results in a predictable and successful esthetic and functional outcomes when there is proper coordination and collaboration between the patient, the general dentist, and the dental specialist.

1. Bishara SE, Ortho DJAJoo, Orthopedics D. Impacted maxillary canines: a review. 1992;101:159-171.
2. Cooke J, Wang H-LJJoP, Dentistry R. Canine impactions: incidence and management. 2006;26.
3. Fournier A, Turcotte JY, Bernard C. Orthodontic considerations in the treatment of maxillary impacted canines. *American journal of orthodontics* 1982;81:236-239.
4. Jacoby H. The etiology of maxillary canine impactions. *American journal of orthodontics* 1983;84:125-132.
5. Becker A. The orthodontic treatment of impacted teeth. In. New York Abingdon, Oxon : Informa Healthcare 2007:1-228.
6. Ericson S, Kurol JJAJoo, orthopedics D. Radiographic examination of ectopically erupting maxillary canines. 1987;91:483-492.
7. Ericson S, Kurol JJTAO. Incisor root resorptions due to ectopic maxillary canines imaged by computerized tomography: a comparative study in extracted teeth. 2000;70:276-283.
8. Haney E, Gansky SA, Lee JS, et al. Comparative analysis of traditional radiographs and cone-beam computed tomography volumetric images in the diagnosis and treatment planning of maxillary impacted canines. *American journal of orthodontics and dentofacial orthopedics : official publication of the American Association of Orthodontists, its constituent societies, and the American Board of Orthodontics* 2010;137:590-597.

9. Ericson S, Kurol JJTAAO. Resorption of incisors after ectopic eruption of maxillary canines: a CT study. 2000;70:415-423.
10. Alqerban A, Jacobs R, Lambrechts P, Loozen G, Willems G. Root resorption of the maxillary lateral incisor caused by impacted canine: a literature review. *Clin Oral Investig* 2009;13:247-255.
11. Chapokas AR, Almas K, Schincaglia G-PJOs, oral medicine, oral pathology, radiology o. The impacted maxillary canine: a proposed classification for surgical exposure. 2012;113:222-228.
12. Gashi A, Kamberi B, Ademi-Abdyli R, Perjuci F, Sahatciu-Gashi A. The Incidence of Impacted Maxillary Canines in a Kosovar Population. *International scholarly research notices* 2014;2014:370531.
13. Kokich VG. Surgical and orthodontic management of impacted maxillary canines. *American journal of orthodontics and dentofacial orthopedics : official publication of the American Association of Orthodontists, its constituent societies, and the American Board of Orthodontics* 2004;126:278-283.
14. Bedoya MM, Park JHJTJotADA. A review of the diagnosis and management of impacted maxillary canines. 2009;140:1485-1493.
15. Burden DJ, Mullally BH, Robinson SNJAJoO, Orthopedics D. Palatally ectopic canines: closed eruption versus open eruption. 1999;115:640-644.
16. Crescini A, Nieri M, Buti J, Baccetti T, Mauro S, Pini Prato GPJJocp. Short-and long-term periodontal evaluation of impacted canines treated with a closed surgical–orthodontic approach. 2007;34:232-242.
17. Parkin NA, Deery C, Smith AM, Tinsley D, Sandler J, Benson PE. No difference in surgical outcomes between open and closed exposure of palatally displaced maxillary canines. *J Oral Maxillofac Surg* 2012;70:2026-2034.
18. Gharaibeh TM, Al-Nimri KS. Postoperative pain after surgical exposure of palatally impacted canines: closed-eruption versus open-eruption, a prospective randomized study. *Oral surgery, oral medicine, oral pathology, oral radiology, and endodontics* 2008;106:339-342.

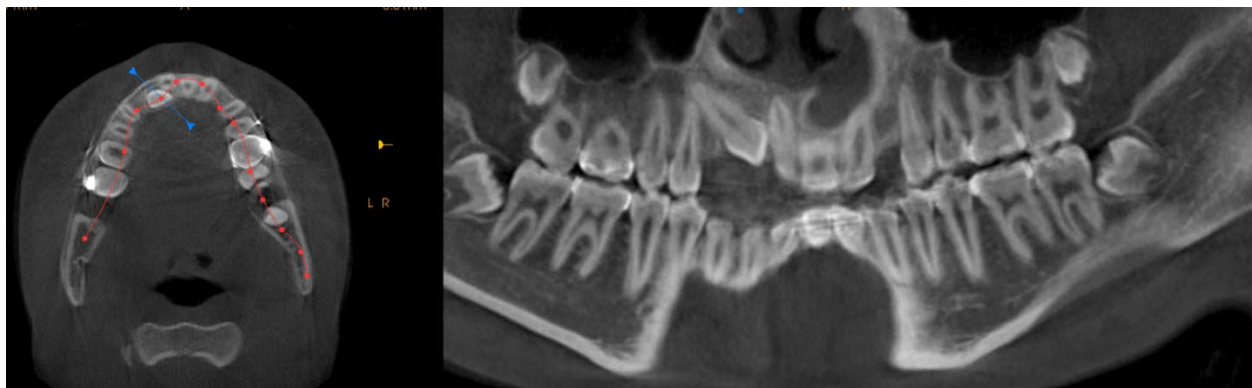

Figure 1. Customized panoramic view from CBCT image.

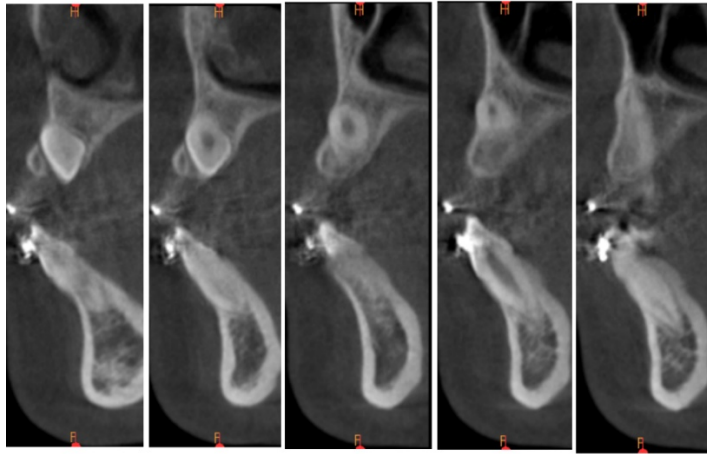


Figure 2. Customized sliced view can show the position of tooth and the presence of bony housing.

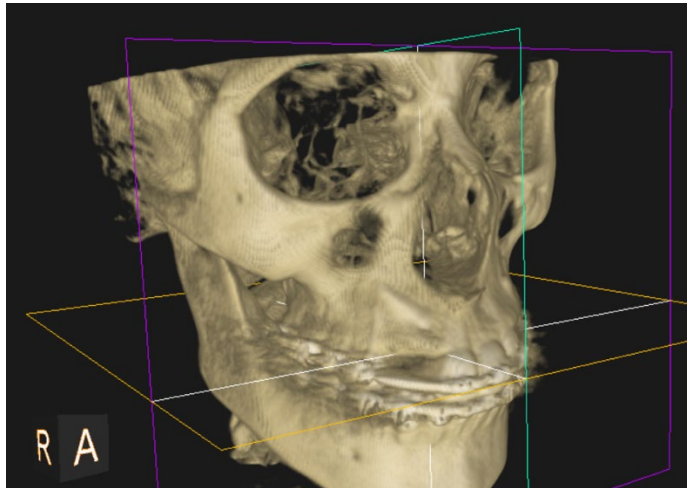


Figure 3. Three dimensional reconstructed view. This image can clearly shows the position of the maxillary right canine and the prominence of the tooth.

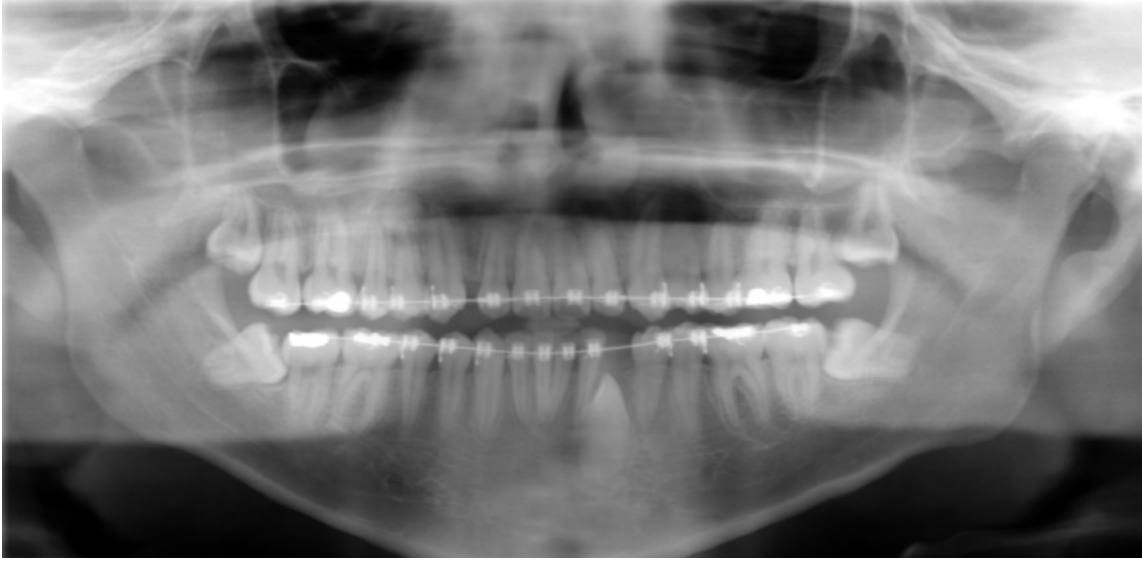

Figure 4. Mandibular left impacted canine is noted.

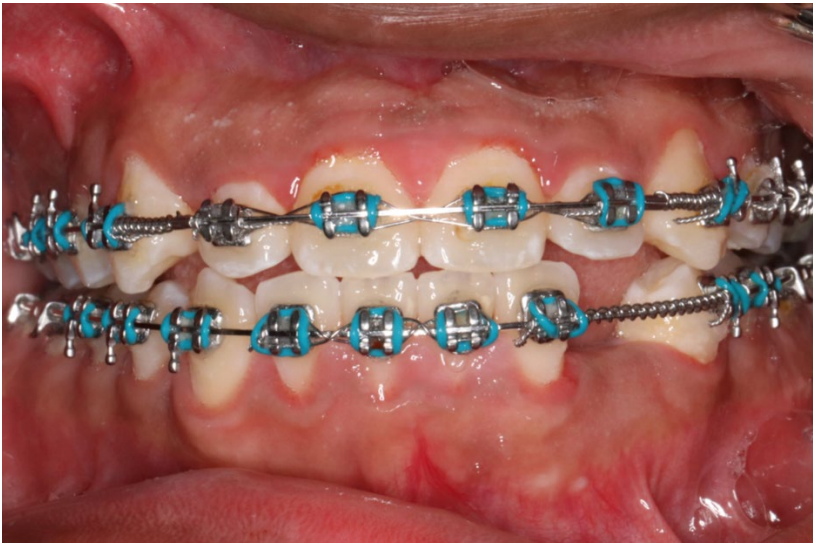


Figure 5. Slight bulge on the coronal of #22 area was noted upon palpation.

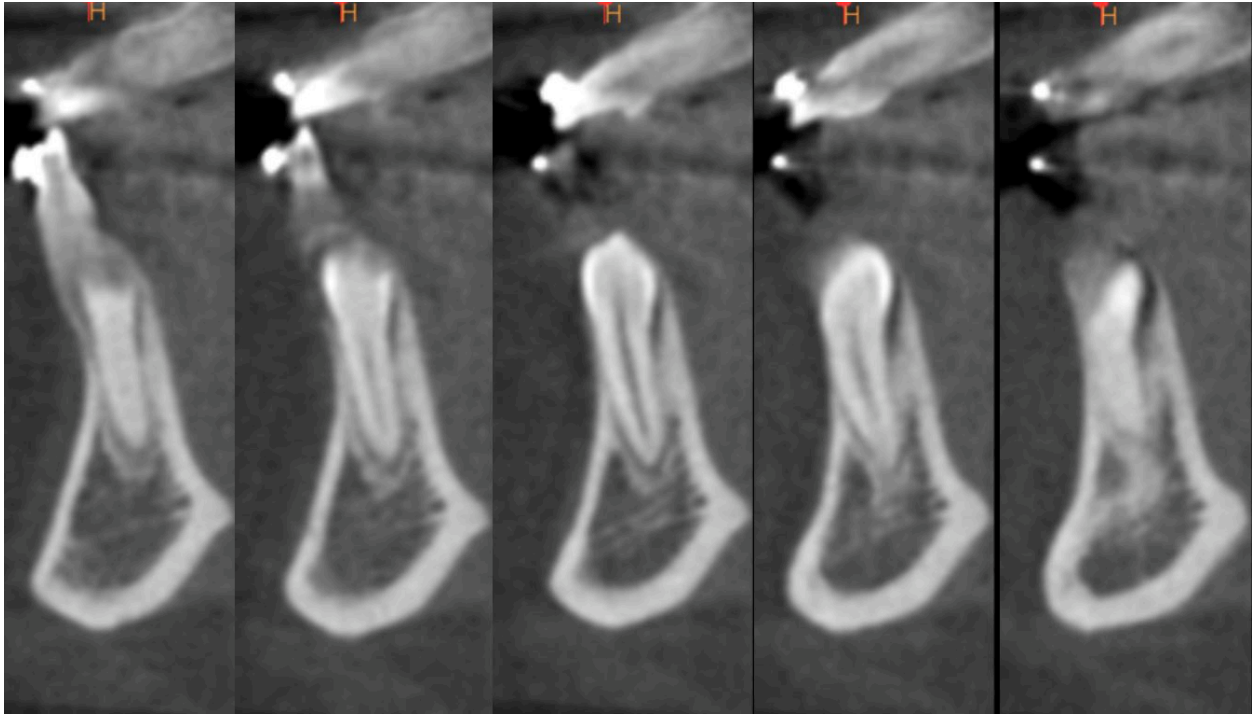


Figure 6. CBCT images showed that the impacted tooth is buccal positioned, and there is no labial plate covering tooth #22.

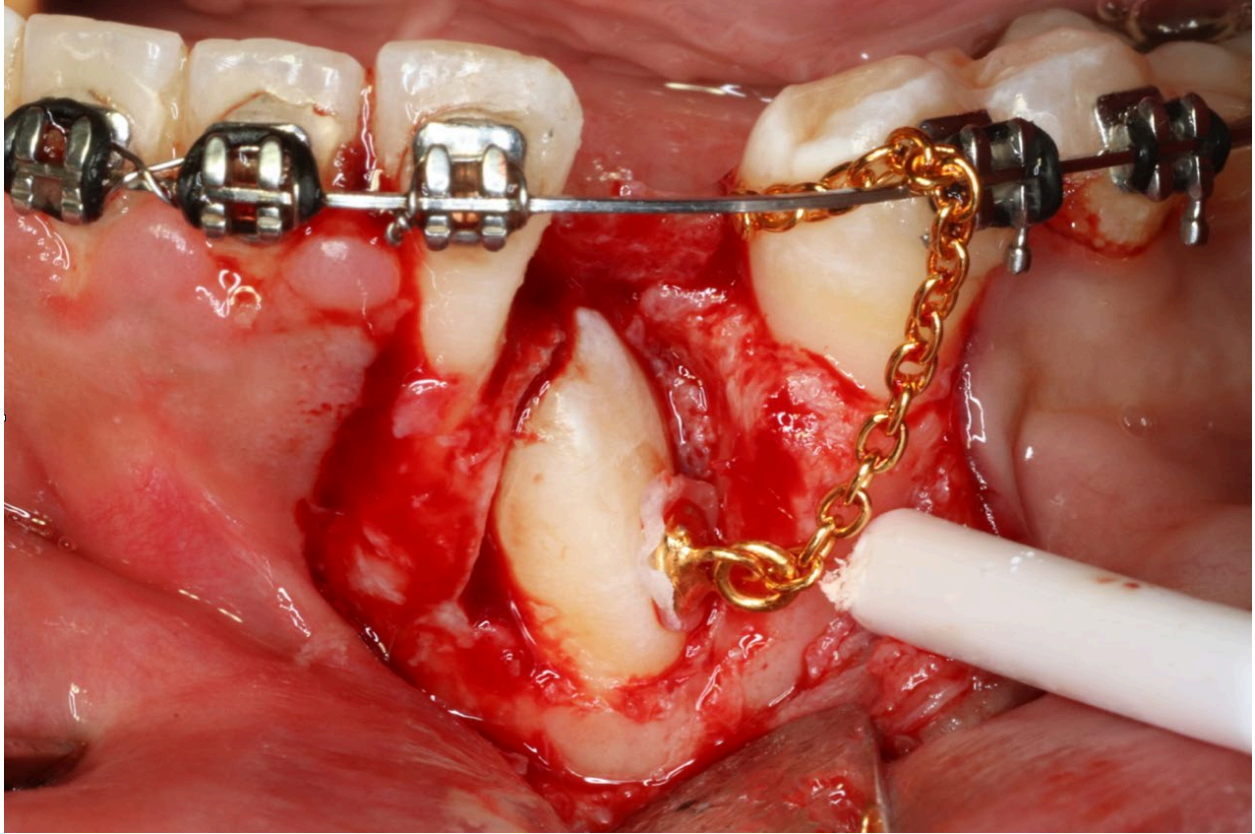


Figure 7. Resin was used to attach the gold button on the tooth surface. Control of bleeding and saliva are the key success.

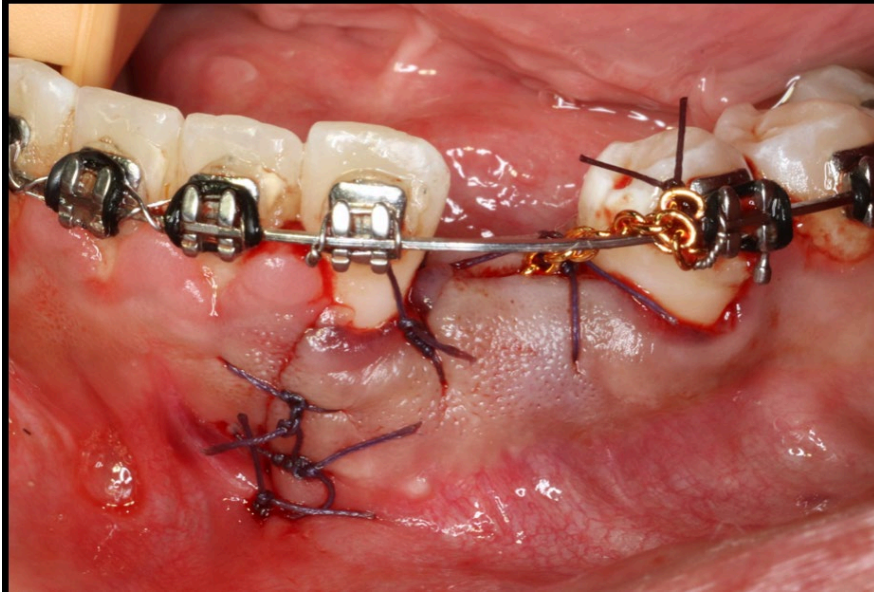


Figure 8. Primary closure was obtained. Gold chain was tied to the archwire to reduce the mobility of the wound.

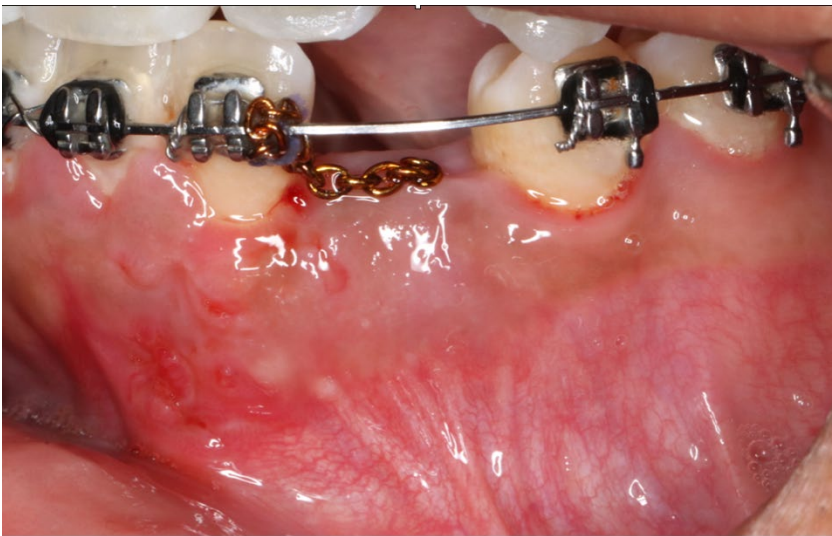

Figure 9. Two weeks post-operative. Wound healing was uneventful, and patient was referred to orthodontist to activate the movement of #22.