

International Journal of Gynecological Pathology
 00:1–8, Lippincott Williams & Wilkins, Baltimore
 Copyright © 2019 The Author(s). Published by Wolters Kluwer Health, Inc.
 on behalf of the International Society of Gynecological Pathologists

OPEN

Original Article

Practical Guidance for Measuring and Reporting Surgical Margins in Vulvar Cancer

Kim E. Kortekaas, M.D., Koen K. Van de Vijver, M.D., Mariëtte I.E. van Poelgeest, M.D., C. Blake Gilks, M.D., Vincent T.H.B.M. Smit, M.D., Saimah Arif, M.D., Deep Arora, M.D., Asma Faruqi, M.D., Raji Ganesan, M.D., Nicholas R. Griffin, M.D., Richard Hale, M.D., Yelin E. Hock, M.D., Lars-Christian Horn, M.D., W. Glenn McCluggage, M.D., Pinias Mukonoweshuro, M.D., Kay J. Park, M.D., Brian Rous, M.D., Bruce Tanchel, M.D., Anne-Sophie Van Rompuy, M.D., Gerry van Schalkwyk, M.D., Jo Vella, M.D., Marco Vergine, M.D., Naveena Singh, M.D., and Tjalling Bosse, M.D.

Summary: Surgical resection with free surgical margins is the cornerstone of successful primary treatment of vulvar squamous cell carcinoma (VSCC). In general reexcision is recommended when the minimum peripheral surgical margin (MPSM) is <8 mm microscopically. Pathologists are, therefore, required to report the minimum distance from the tumor to the surgical margin. Currently, there are no guidelines on how to make this measurement, as this is often considered straightforward. However, during the 2018 Annual Meeting of the British Association of Gynaecological Pathologists (BAGP), a discussion on this topic revealed a variety of opinions with regard to reporting and method of measuring margin clearance in VSCC specimens. Given the need for uniformity and the lack of guidance in the literature, we initiated an online survey in order to deliver a consensus-based definition of peripheral surgical margins in VSCC resections. The survey included questions and representative diagrams of peripheral margin measurements. In total, 57 pathologists participated in this survey. On the basis of consensus results, we propose to define MPSM in VSCC as the minimum distance from the peripheral edge of the invasive tumor nests toward the inked peripheral surgical margin reported in millimeters. This MPSM measurement should run through tissue and preferably

From the Departments of Obstetrics and Gynecology (K.E.K., M.I.E.V.P.); Pathology (V.T.H.B.M.S., T.B.), Leiden University Medical Centre, Leiden, The Netherlands; Department of Pathology, Ghent University Hospital, Gent (K.K.V.D.V.); Department of Pathology, University Hospitals Leuven, Leuven (A.S.V.R.), Belgium; Department of Pathology and Laboratory Medicine, University of British Columbia, Vancouver, BC, Canada (C.B.G.); Department of Cellular Pathology, Princess Alexandra Hospital, Harlow, Essex (S.A.); Department of Cellular Pathology, St. James's University Hospital, Leeds (D.A.); Department of Cellular Pathology, Barts Health NHS Trust, London (A.F., N.S.); Department of Cellular Pathology, University Hospitals Birmingham NHS Trust, Birmingham (R.G., B.T., J.V.); Department of Pathology, Airedale General Hospital, Keighley (N.R.G.); Department of Cellular Pathology, Stepping Hill Hospital, Stockport (R.H.); Department of Histopathology, Manor Hospital, Walsall Healthcare NHS Trust, Walsall (Y.L.H.); Department of Pathology, Belfast Health and Social Care Trust, Belfast (W.G.M.); Department of Cellular Pathology, Royal United Hospital, Bath (P.M.); Department of Pathology, Cambridge University Hospitals NHS Trust, Cambridge (B.R.); Department of Pathology, Royal Derby Hospital, Derby (G.V.S.); Department of Histopathology, The Royal Sussex County Hospital, Brighton (M.V.), UK; Division of Gynecologic, Breast & Perinatal Pathology, University Hospital Leipzig, Leipzig, Germany (L.C.H.); and Department of Pathology, Memorial Sloan Kettering Cancer Center, New York, New York (K.J.P.).

K.J.P. is funded by the NIH/NCI Institutional Support Grant P30 CA008748. The authors declare no conflict of interest.

Address correspondence and reprint requests to Tjalling Bosse, MD, Leiden University Medical Centre, Albinusdreef 2, Leiden 2333 ZA, The Netherlands. E-mail: t.bosse@lumc.nl

Supplemental Digital Content is available for this article. Direct URL citations appear in the printed text and are provided in the HTML and PDF versions of this article on the journal's website, www.intjgynpathology.com.

This is an open-access article distributed under the terms of the Creative Commons Attribution-Non Commercial-No Derivatives License 4.0 (CCBY-NC-ND), where it is permissible to download and share the work provided it is properly cited. The work cannot be changed in any way or used commercially without permission from the journal.

be measured in a straight line. Along with MPSM, other relevant measurements such as depth of invasion or tumor thickness and distance to deep margins should be reported. This manuscript provides guidance to the practicing pathologist in measuring MPSM in VSCC resection specimens, in order to promote uniformity in measuring and reporting. **Key Words:** Surgical margin—Vulvar cancer—Measurement.

Vulvar squamous cell carcinoma (VSCC), the most common vulvar malignancy (1), is notorious for its high recurrence rates, with a reported local recurrence frequency of up to 40% ten years after primary treatment (2). In an effort to limit these recurrence rates, most guidelines including The Royal College of Obstetricians & Gynaecologists (RCOG) in the United Kingdom, recommend surgical excision with a histological minimum tumor-free peripheral surgical margin (MPSM) of > 8 mm (3–6). Retrospective cohort studies support this approach, showing 0% recurrence rates for > 8 mm margins and 47% when the margins are ≤ 8 mm (4,7,8), although recent studies have argued that the 8 mm threshold might be too stringent (9–12). The concept of ontogenic cancer fields might explain why the width of the tumor-free resection margin is not a consistent predictor of local recurrence (13). However, when surgical treatment of VSCC in respect to the theory of cancer as inverse morphogenesis is carried out, it is still important to measure the MPSM as a pathologic quality. In order to achieve this requirement, surgeons often need to sacrifice critical structures adjacent to the VSCC (e.g. clitoris, urethra, and anus) with subsequent morbidities (14). If the 8 mm MPSM is not reached, most guidelines recommend consideration of reexcision and/or adjuvant radiotherapy to reduce the chance of local recurrence (9). Therefore, MPSM measurement is a mandatory and clinically important item in pathology reporting and clinical care.

Despite its clinical relevance, practical guidelines on how to measure the MPSM are lacking in the current literature. This is in contrast to depth of stromal invasion and/or tumor thickness, for which definitions and guidance on measurement have been published (15,16). During the British Association of Gynaecologic Pathologists (BAGP) Annual Meeting in 2018, an ad hoc pilot survey revealed considerable disagreement among pathologists on how to measure MPSM. This topic seems particularly relevant to vulvar resections, as the vulva has natural folds that form the anatomical landmarks such as the labia, and tumors are often exophytic, resulting in scenarios in which the correct measurement is not obvious. This is compounded by a lack of agreement between the naked eye measurement

made at the time of surgery and that reported histologically after formalin fixation (17). Surgical assessment of margin clearance is based on measuring skin adjacent to tumor when the skin has been pulled taut/flat. Various factors may affect the histological assessment, including variation in laboratory protocols with regard to pinning specimens before fixation, shrinkage as a result of fixation, and/or the presence of microscopic tumor deep to the surface extending closer to the margin than is apparent from assessment of the skin surface. As patient care and future research studies would clearly benefit from a uniform and standardized approach toward measuring MPSM in VSCC, we undertook an online survey among members of the BAGP in order to formulate recommendations for uniform MPSM measurement and reporting. These recommendations are likely to not only be relevant for VSCC, but also for other skin/mucosal resections for which peripheral margin measurements are required.

METHODS

Four pathologists with a specialist interest in gynecologic, including vulvar pathology (K.K.V.d.V., C.B.G., N.S., and T.B.), discussed the common problems encountered in MPSM measurement of VSCC following the 2018 BAGP meeting. This group designed a survey including questions and challenging scenarios for MPSM measurement. The questions were sent to members of the BAGP council for comments. A link to the final agreed electronic online survey was sent to all members of the BAGP in November 2018.

The survey included 5 diagrams representing potential problematic areas in MPSM measurement. In each diagram, multiple options for measuring margin distance were drawn, and the participants were asked to select their preferred MPSM (only one answer allowed). The first diagram represents a straightforward MPSM measurement (Supplemental Fig. 1, Supplemental Digital Content 1, <http://links.lww.com/IJGP/A99>) and was included to make participants familiar with the online webtool. Five multiple-choice questions were also included in the survey (Fig. 1). Participants were encouraged to submit comments related to the topic, which have been

incorporated in the discussion of this manuscript. Responses received until the end of December 2018 were analyzed, excluding any that were incomplete.

RESULTS

A total of 57 BAGP members responded, and all these participants fully completed the survey. Importantly, an overwhelming majority (96%) replied that recommendations for measuring MPSM would be useful in daily practice. This was reinforced by responses to the question on whether they experienced difficulties in measuring MPSM in daily practice, to which 14% and 68% respondents, respectively, selected “often” and “occasionally,” as opposed to 12% and 5%, respectively, stating that they rarely or never experienced difficulties when measuring MPSM (Fig. 1).

Problematic Area 1: Should the MPSM Always be Measured Toward the Peripheral Surface Edge?

Because of the irregular vulvar surface a measurement toward the peripheral inked epithelial-surface edge may not always represent the shortest distance. As illustrated in Figure 2A, the shortest measurement from the tumor to the resection edge, in this scenario, is toward the inked soft tissue edge. In keeping with measuring the shortest distance, the majority of participants (86%) chose option B, measuring from the peripheral edge of the invasive tumor to the peripheral inked soft tissue edge. Interestingly, a significant minority (14%) chose option A, in which the distance is larger, but the measurement is toward the epithelial-surface edge.

Comments

Most participants strictly applied the simple rule that the MSPM is the shortest measurement toward the peripheral inked edge even though this is a stromal and not an epithelial margin. Some participants, however, commented that it may be challenging to decide where the peripheral margin stops and “the deep surgical margin” begins. Another remark made by one of the participants, was that measurement A is more representative of what the surgeon measures during the operation. Reporting measurement B (only) could potentially result in a negative impact on surgical audit, and therefore it was suggested (in these scenarios) to report on both the MPSM (option B) and also the “surface epithelial margin” (option A). Provided both may be worthy of consideration, albeit after good communication with local surgeons. As long as it is clearly emphasized in the report that, for

decisions with regard to the patient’s adjuvant treatment plan, measurement B is the most relevant.

Problematic Area 2: How Should MPSM be Measured When the Epithelial Surface is Irregular/Curved?

Given the normal vulvar anatomy, an irregular or curved surface is frequent in VSCC resection specimens and may complicate the measurement of the MSPM (Fig. 2B). Curved skin may be neutralized in part by pulling the skin taut. However, artificial folds due to processing can still appear and are difficult to distinguish from natural irregularities. Depending on how extreme this irregularity is, pathologists may favor a curved line instead of a straight line. Curved line measurements are impractical when using a microscope, but, as the field moves toward digital pathology, this practical problem becomes obsolete. Interestingly, when faced with this scenario in our survey, 98% of the participants considered that the straight-line measurement is preferred.

Comments

The outcome of Figure 2B may have been influenced by the fact that it is likely that few or none of the participants have already moved toward digital pathology in daily routine. The participants reported that they used eyepiece reticles (50%), a ruler (either stage vernier scale or the magnifying glass fixed with a rule, 48%), or simply estimated the MPSM distance (2%) in practice (Fig. 1). With the introduction of digital pathology, more accurate margin measurements can be anticipated. This increased accuracy introduces another interesting question raised by one of the participants; how accurately do we need to measure? Most pathologists currently record measurements rounded to the nearest whole millimeter; however, digital pathology will allow for measurements of hundredths of millimeters or less. There is currently no evidence that this level of accuracy is required, and therefore we would recommend that rounded millimeters should remain the standard. Digital pathology will also simplify measuring curved lines; however, unless a curved measurement clearly represents the true shortest distance toward the periphery, for example, when a length of uninvolved skin is embedded curved/folded in order to fit into a paraffin block, this should be avoided. In addition, a pitfall is not to overstretch the skin, because this might lead to overestimation of the MPSM. It is unknown whether measuring in a straight line compared with measuring in a curved line will influence clinical

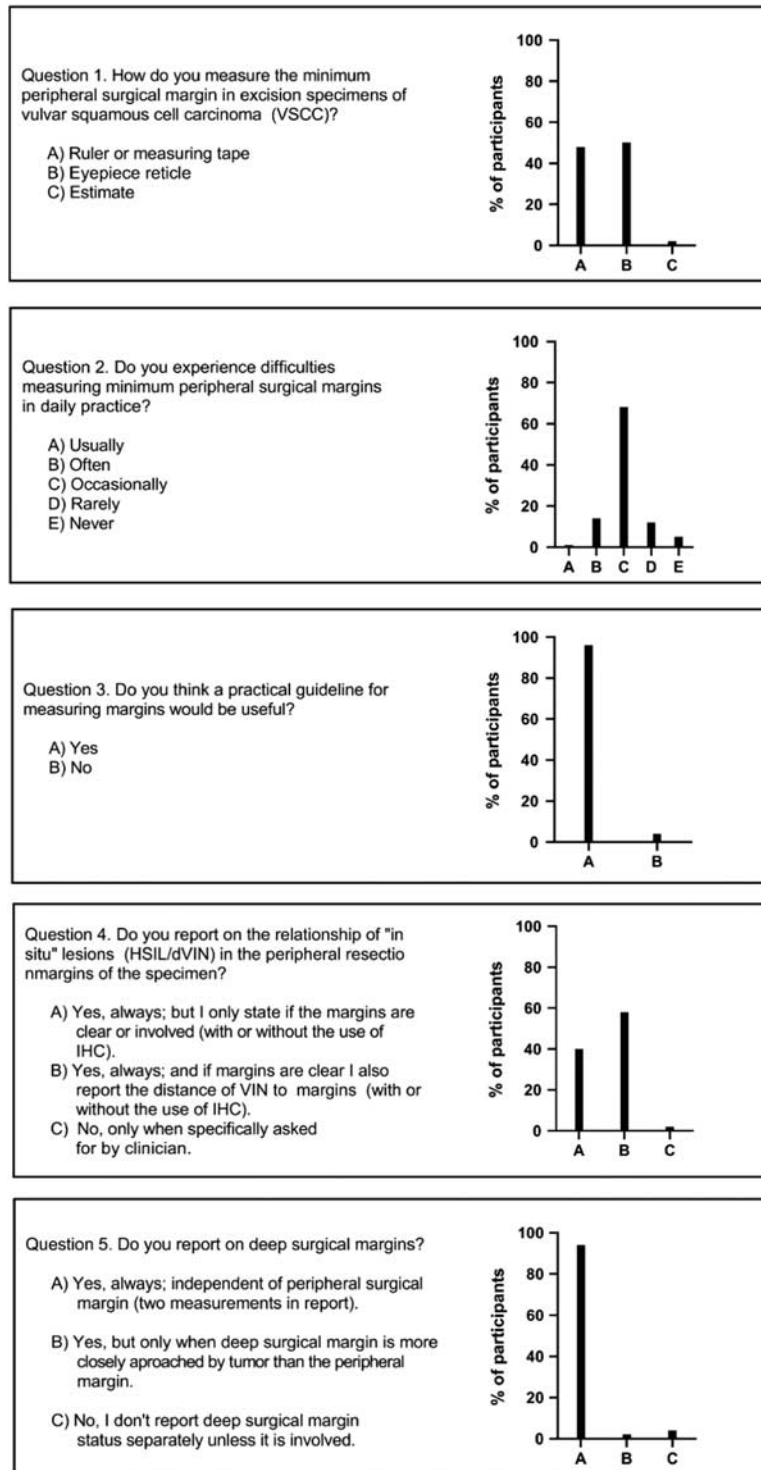


FIG. 1. Five multiple choice questions were asked to all participating pathologists on how to measure and report on minimal peripheral surgical margin.

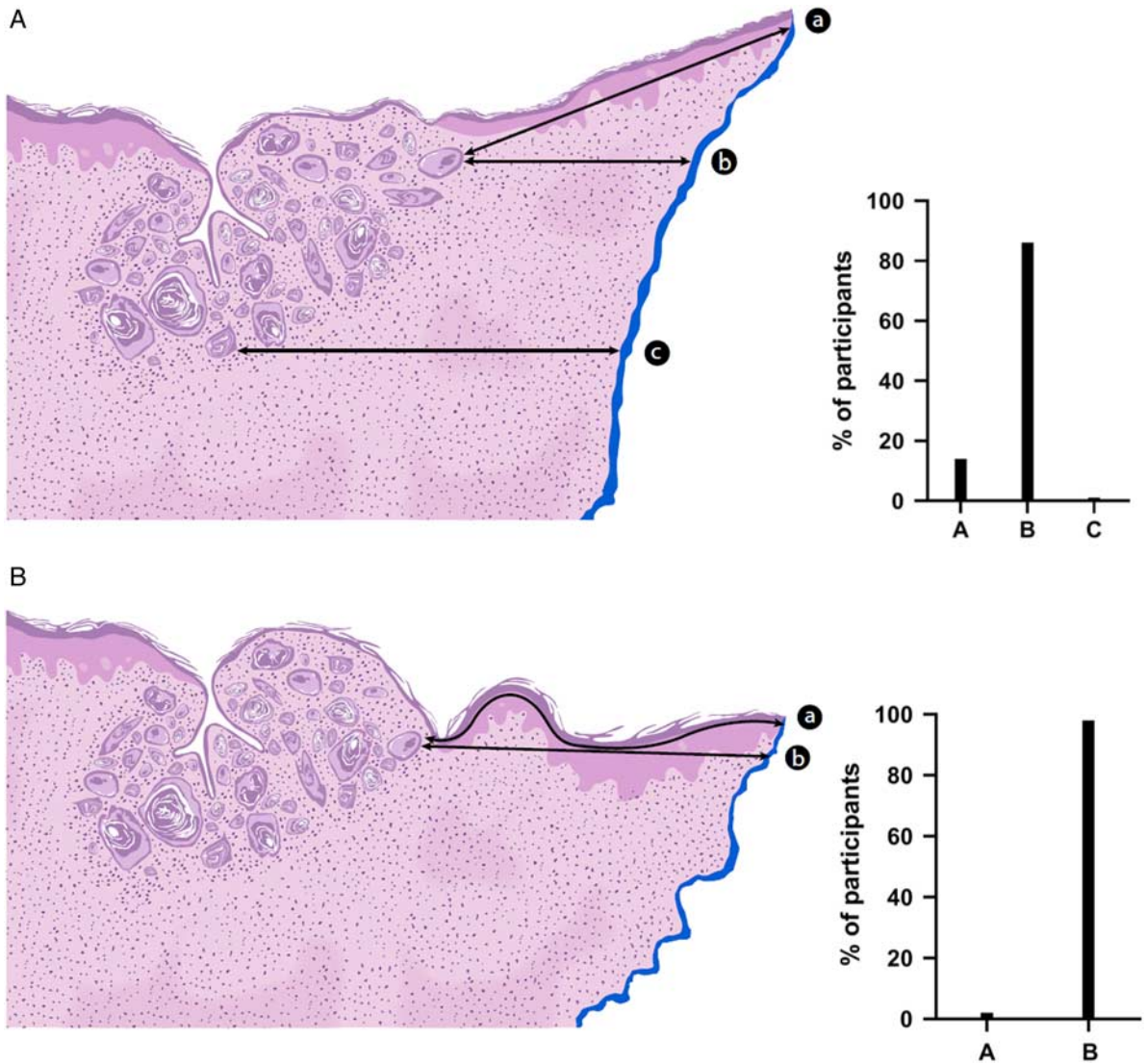


FIG. 2. These diagrams represent a problematic area in measuring minimal peripheral surgical margin (MPSM) in vulvar cancer. In each diagram, multiple options were drawn, and participants selected their preferred MPSM via an online survey. The results of this survey are shown in the corresponding bar graph. The first question was: Should the minimal peripheral surgical margin always be measured towards the peripheral surface edge? The diagram and answer to this question are depicted in (A). The next question was: how to measure minimal peripheral surgical margin when the epithelial surface is irregular/curved (B)?

outcome. Uniform use of the recommendations from this manuscript will help resolve this in the near future.

Problematic Area 3: How to Measure MPSM When an Exophytic Tumor Protrudes Above the Adjacent Surface Epithelium?

Often VSCC have an exophytic component, which protrudes above the adjacent surface epithelium (Fig. 3A). In these cases, the shortest distance from the tumor to the periphery can be measured by drawing a line outside the tissue (option A). The participants in

the survey agreed in an overwhelming majority (98%) that, in this scenario, option A does not represent the MPSM. We can deduce from this answer that the MPSM measurement should not be outside the tissue. This is informative, as this provides a useful “rule” for measuring MPSM in cases with surface irregularities.

Problematic Area 4: Should MPSM Always be Measured as a Straight Uninterrupted Line?

Figure 3B represents a case of an exophytic tumor wherein the deepest point of invasion is above a collarette

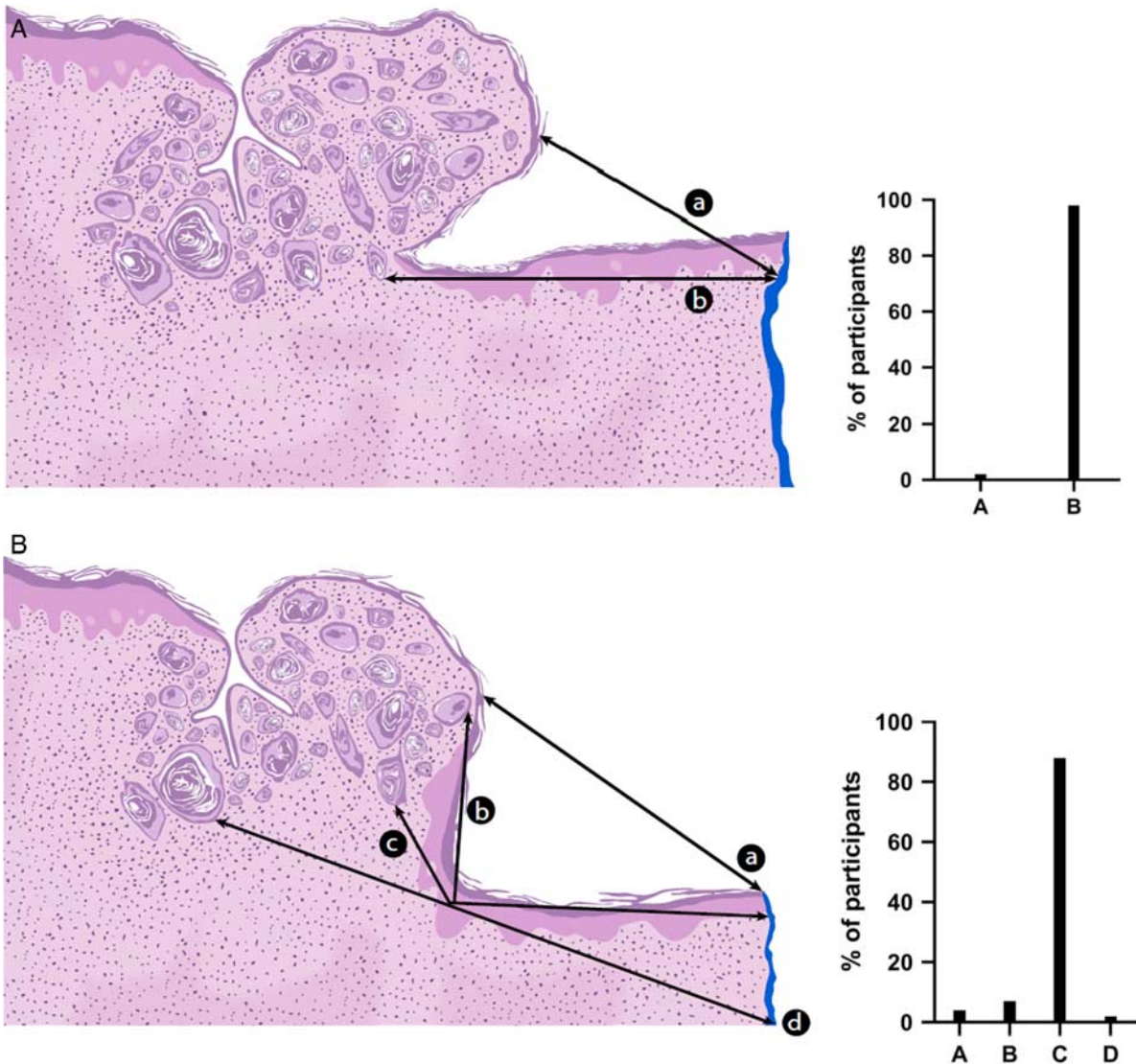


FIG. 3. These diagrams represent a problematic area in measuring minimal peripheral surgical margin (MPSM) in vulvar cancer. In each diagram, multiple options were drawn, and participants selected their preferred MPSM via an online survey. The results of this survey are shown in the corresponding bar graph. (A) Refers to the question: How to measure the minimal peripheral surgical margin when an exophytic tumor is overarching the adjacent surface epithelium? (B) Answers the question: Should the minimal peripheral surgical margin always be measured as a straight uninterrupted line?

of uninvolved skin. In this case, two ways to measure the MPSM by a straight uninterrupted line were presented (option A and option D) and two ways in which the line was interrupted at the collarette (option B and C). The shortest distance is measurement A; however, following the rule for not measuring outside the tissue (described above, Fig. 3A), this would be incorrect. The alternative straight uninterrupted line (option D) is the largest distance of all options and was not the preferred option by the participants (2%). The majority voted for option C (95%), which represents the shortest distance through tissue in a line with an angle at the collarette. From this,

we can conclude that the participants are familiar with this scenario and allow for MPSM with an angle.

Additional Questions

In addition to the questions relating to the illustrated scenarios, a few additional questions were asked, as below.

Should the Presence of a Precursor Lesion at the Lateral Epithelial MPSM be Reported?

VSCC has 2 well-defined precancerous lesions that are frequently recognized in the epithelial surface adjacent to

the tumor, high-grade squamous intraepithelial lesion of usual type (usual high-grade vulvar intraepithelial neoplasia) and differentiated vulvar intraepithelial neoplasia. It is possible that recurrent disease is not only determined by the margin status of the invasive tumor, but also by the presence and distance of the precancerous lesion to the surgical margin. Here, the measurement itself is more straightforward, as the precancer will always be measured along the epithelial surface. Interestingly, with the exception of the RCOG and College of American Pathologists (CAP) guideline (3,18), most guidelines do not consider reporting precancerous lesions in VSCC resection specimens mandatory. Despite this, most of the survey participants report upon the presence or absence of precancerous lesions (98%) adjacent to the VSCC at the peripheral margin. An overall 42% of these participants also include a measurement of the *in situ* lesion to the peripheral margin. The remaining 56% do not include a measurement and limit the comment on the *in situ* lesion to its presence/absence at the surgical margin (Fig. 1).

Should a Measurement of the Deep Soft Tissue Margin also be Included in the Report?

Most participants (95%) also report on deep soft tissue margins, in addition to the MPSM in their VSCC resection specimens (Fig. 1). This is in line with most guidelines (7), in which a minimum of three measurements are listed: (1) tumor thickness/depth of invasion, (2) the MPSM, and (3) the deep soft tissue margin (3). One participant remarked to not limit the measurement to the minimal margin, but report a clockwise margin status. Measurement of distance to multiple cutaneous margins has limited relevance; the margins are approximated and stitched together at the end of surgery (unless a skin flap has been used to fill the gap), and therefore it is the involvement of/proximity to the closest margin that is required by clinicians to plan further management. Histology reports should not be crowded with irrelevant measurements. In many practices, clockwise measurements are the standard during grossing, but these measurements should not be included in the report to avoid potential confusion.

SUMMARY

This is the first study to survey current practice in measuring the MPSM in VSCC specimens. By presenting 5 margin scenarios to 57 trained pathologists with an interest in gynecologic pathology, we can propose some broad rules that will help the community

arrive at more reproducible and accurate MPSM measurements and uniform reporting. On the basis of this, we propose the following:

- The MPSM is defined as: “the minimum distance from invasive carcinoma to the inked peripheral surgical margin reported in millimeters.”
- The peripheral margin is roughly perpendicular to the skin surface; this includes the epithelial surface and deeper soft tissue; the MPSM should, therefore, be measured toward the peripheral stromal edge or surface-epithelial edge, whichever is the shortest.
- Reporting both the MPSM and the distance to the surface-epithelial edge is not mandatory for invasive tumor, but may be considered for the purpose of surgical audit. In addition, reporting on both margins is recommended for high-grade squamous intraepithelial lesion and differentiated vulvar intraepithelial neoplasia.
- The MPSM should be measured through tissue and preferably in a straight uninterrupted line; however, in some situations (collarette) a composite measurement including separate linear measurements joined at an angle may be required.
- Measuring the MPSM by a curved line in the context of an irregular surface, which is now possible due to the increased use of digital pathology, is not recommended, unless this is felt to represent a truer measurement, for example, when a length of uninvolved skin is embedded curved/folded in order to fit into a paraffin block.
- The presence or absence of precancerous lesions at the surgical margin should be included in the report.
- Although there is no clear evidence to support the value of recording the distance of precancerous lesions from the nearest epithelial margin, it is recommended that, for uniformity, in current practice, this measurement should be included in the report; this measurement is made along the epithelial surface.
- The minimal deep surgical margin is generally understood to be measured from the deepest infiltrating tumor nest to the inked dorsal soft tissue margin.

It is hoped that these recommendations will help to uniform current clinical practice and can be used as a reference for future guidelines and clinical studies to correlate MPSM with patient outcome.

Acknowledgments: The authors thank all attendees at the BAGP Annual Meeting 2018, and those who participated in

the online surveys. The authors thank Jan Oosting for his support in creating the online survey during the BAGP Annual Meeting 2018 and Maartje Kunen for the medical illustrations in this manuscript.

REFERENCES

- Hacker NF, Eifel PJ, van der Velden J. Cancer of the vulva. *Int J Gynaecol Obstet* 2012;119(suppl 2):S90–6.
- Te Grootenhuis NC, van der Zee AG, van Doorn HC, et al. Sentinel nodes in vulvar cancer: long-term follow-up of the GROningen International Study on Sentinel nodes in Vulvar cancer (GROINSS-V) I. *Gynecol Oncol* 2016;140:8–14.
- Luesley DM, Barton DPJ, Bishop M, et al. Guidelines for the diagnosis and management of vulval carcinoma. 2014. Available at: www.rcog.org.uk/globalassets/documents/guidelines/vulvacancer guideline.pdf. Accessed April 17, 2019.
- National Dutch guideline gynaecologic tumors; vulvar carcinoma. 2015. Available at: www.oncoline.nl/vulvacarcinoom. Accessed April 17, 2019.
- Heaps JM, Fu YS, Montz FJ, et al. Surgical-pathologic variables predictive of local recurrence in squamous cell carcinoma of the vulva. *Gynecol Oncol* 1990;38:309–14.
- De Hullu JA, Hollema H, Lolkema S, et al. Vulvar carcinoma. The price of less radical surgery. *Cancer* 2002;95:2331–8.
- Faruqi A, Rous B. Standards and datasets for reporting cancers (Dataset for histopathological reporting of vulval carcinomas). The Royal College of Pathologists. 2018. Available at: www.rcpath.org/uploads/assets/uploaded/d9408b23-5dba-42b9-b9dc9b657c61f76f.pdf. Accessed April 17, 2019.
- Baiocchi G, Mantoan H, de Brot L, et al. How important is the pathological margin distance in vulvar cancer. *Eur J Surg Oncol* 2015;41:1653–8.
- Nooij LS, Brand FA, Gaarenstroom KN, et al. Risk factors and treatment for recurrent vulvar squamous cell carcinoma. *Crit Rev Oncol Hematol* 2016;106:1–13.
- Woelber L, Griebel LF, Eulenburg C, et al. Role of tumour-free margin distance for loco-regional control in vulvar cancer—a subset analysis of the Arbeitsgemeinschaft Gynakologische Onkologie CaRE-1 multicenter study. *Eur J Cancer* 2016;69:180–8.
- Pleunis N, Leermakers MEJ, van der Wurff AA, et al. Surgical margins in squamous cell carcinoma, different for the vulva. *Eur J Surg Oncol* 2018;44:1555–61.
- Nooij LS, van der Slot MA, Dekkers OM, et al. Tumour-free margins in vulvar squamous cell carcinoma: Does distance really matter. *Eur J Cancer* 2016;65:139–49.
- Hockel M, Trott S, Dornhofer N, et al. Vulvar field resection based on ontogenetic cancer field theory for surgical treatment of vulvar carcinoma: a single-centre, single-group, prospective trial. *Lancet Oncol* 2018;19:537–48.
- Gaarenstroom K, Kenter G, Trimboos J, et al. Postoperative complications after vulvectomy and inguinofemoral lymphadenectomy using separate groin incisions. *Int J Gynecol Cancer* 2003;13:522–7.
- Kurzl R, Messerer D, Baltzer J, et al. Comparative morphometric study on the depth of invasion in vulvar carcinoma. *Gynecol Oncol* 1988;29:12–25.
- Yoder BJ, Rufforny I, Massoll NA, et al. Stage IA vulvar squamous cell carcinoma: an analysis of tumor invasive characteristics and risk. *Am J Surg Pathol* 2008;32:765–72.
- Balega J, Butler J, Jeyarajah A, et al. Vulval cancer: what is an adequate surgical margin? *Eur J Gynaecol Oncol* 2008;29:455–8.
- Movahedi-Lankarani S, Krishnamurti U, Bell DA, et al. Protocol for the examination of specimens from patients with primary carcinoma of the vulva. 2018. Available at: <https://documents.cap.org/protocols/cp-femalereproductive-vulva-18protocol-4100.pdf>. Accessed April 17, 2019.