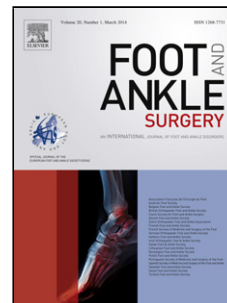

## Journal Pre-proof

Comments on the paper: « Impact of the rotational position of the hindfoot on measurements assessing the integrity of the distal tibio-fibular syndesmosis. *Foot Ankle Surg.* 2019;S1268-7731(19)30181-X. doi:10.1016/j.fas.2019.10.010 ».



Francois Lintz MD, MSc, Alexej Barg MD, Cesar de Cesar Netto MD, PhD, Arne Burssens MD, Scott Ellis MD, Martinus Richter MD, PhD, International Weight Bearing CT Society

PII: S1268-7731(20)30068-0  
DOI: <https://doi.org/10.1016/j.fas.2020.04.003>  
Reference: FAS 1442

To appear in: *Foot and Ankle Surgery*

Received Date: 30 March 2020  
Accepted Date: 2 April 2020

Please cite this article as: { doi: <https://doi.org/>

This is a PDF file of an article that has undergone enhancements after acceptance, such as the addition of a cover page and metadata, and formatting for readability, but it is not yet the definitive version of record. This version will undergo additional copyediting, typesetting and review before it is published in its final form, but we are providing this version to give early visibility of the article. Please note that, during the production process, errors may be discovered which could affect the content, and all legal disclaimers that apply to the journal pertain.

© 2020 Published by Elsevier.

**Letter to the Editor:**

**Comments on the paper: « Impact of the rotational position of the hindfoot on measurements assessing the integrity of the distal tibio-fibular syndesmosis. Foot Ankle Surg. 2019;S1268-7731(19)30181-X. doi:10.1016/j.fas.2019.10.010 ».**

**Authors**

Francois Lintz, MD, MSc<sup>1</sup>; Alexej Barg, MD<sup>4</sup>; Cesar de Cesar Netto, MD, PhD<sup>2</sup>; Arne Burssens, MD<sup>3</sup>; Scott Ellis, MD<sup>5</sup>; Martinus Richter, MD, PhD<sup>6</sup>; International Weight Bearing CT Society.

**Authors information:**

<sup>1</sup> Ankle and Foot Surgery Center, Ramsay Santé-Clinique de l'Union, 31240, Saint Jean Toulouse, France; dr.f.lintz@gmail.com

<sup>2</sup> Department of Foot and Ankle Surgery, Med Star Hospital, Baltimore, MA, USA; cesardecesarnetto@gmail.com

<sup>3</sup> Department of Foot and Ankle Surgery, University Hospital of Ghent: Ghent, Oost-Vlaanderen, Belgium; arne.burssens@gmail.com

<sup>4</sup> Department of Orthopaedics, University of Utah, 590 Wakara Way, Salt Lake City, UT 84108, USA; alexej.barg@hsc.utah.edu

<sup>5</sup> Department of Foot and Ankle Surgery, Hospital for Special Surgery, NY 10021, New York City, USA

<sup>6</sup> Department of Orthopedic Surgery, Rummelsberg Hospital, Rummelsberg, Germany; martinus.richter@sana.de

<sup>7</sup>The International Weight Bearing CT Society, 66, Blankenbergestraat, Ghent, 9000,  
Belgium

Corresponding author :

Francois Lintz: [dr.f.lintz@gmail.com](mailto:dr.f.lintz@gmail.com); Ankle and Foot Surgery Center, Ramsay Santé-  
Clinique de l'Union, 31240, Saint Jean Toulouse, France

Comments on:

Krähenbühl N, Akkaya M, Dodd AE, et al. Impact of the rotational position of the hindfoot on measurements assessing the integrity of the distal tibio-fibular syndesmosis [published online ahead of print, 2019 Nov 1]. *Foot Ankle Surg.* 2019;S1268-7731(19)30181-X. doi:10.1016/j.fas.2019.10.010

Dear authors,

We thank you for an excellent paper which sheds more light into radiographic evaluation of the distal tibio-fibular syndesmotoc joint, a long-lasting challenge in our specialty. We respectfully suggest in the present letter that a more in-depth analysis of your work is possible, which we would like to share here by detailing two major aspects: 1- principles of rotation induced bias in radiography and 2- simple geometrical background for this bias. After which, the relevant conclusions will be drawn regarding the aforementioned study and consequences for future research.

1- Rotation induced bias in conventional radiography, DRR and 3D WB cone beam CT images.

Projection of 3D structure on a plane is subject to rotation bias: measurements (angles, lengths) change, depending on rotation of the 3D structure relative to the incident radiographic beam and to the plane of projection. This problem is inherent to WB Conventional Radiography, not WB cone beam CT in which the whole volume is acquired so that the true absolute and relative dimensions are known.

In this study, a foot and ankle complex is scanned. A virtual model of the F&A is obtained through segmentation. Digitally Reconstructed Radiographs are then obtained at different degrees of rotation by rotating the virtual model and projecting it on a virtual plane. This is like virtually performing conventional radiography on a virtual foot and ankle model obtained through WB cone beam CT. In conventional

radiography in real life, once the film is shot at a certain degree of rotation, the projection is fixed with an unknown degree of rotation from the neutral position and an equivalent bias is created and fixed. The whole point of WB cone beam CT is to be able to rotate back the virtual foot model to neutral position in order to perform the measurements in neutral position with the smallest possible bias. So we do agree that in your study, it is interesting to verify that bias in DRR, which are a simulation of radiography, but in the clinical setting, such bias in axial measurements would not happen.

Therefore, it is our belief that it cannot be concluded that measurements will vary depending on rotation in WBCT because the whole point of WBCT is that whatever the position of the foot within the machine's field of view, measurements can always be made in neutral position.

## 2- The results can be demonstrated in advance using geometry.

$\alpha$  is the angle of incidence of the X rays or the angle between the neutral position and the position used for measurements.

$l_1$  is the distance between the anterior border of the fibular notch and the most medial point on the fibula. Its projection on the radiographic plane or DRR corresponds to TFCS.

$l_2$  is the distance between the posterior border of the fibular notch and the most medial point on the fibula. Its projection on the radiographic plane or DRR corresponds to TFO.

The same applies to the MCS.

Figure 1 Here

At this point, whatever the configuration, since the anatomy of the syndesmosis is not changing (no extra torque is applied and it is the whole foot and ankle complex which is rotation), the measurement ( $M$ ) (whatever it is, TFCS, TFO or MCS) is a trigonometric function of  $\alpha$  where  $M$  is equal to the Sinus of  $\alpha$  times the value of the  $M$  in the neutral position (meaning when  $\alpha=0$ ):

$$M = \sin(\alpha) \cdot l$$

Therefore, the results observed in this study cannot mathematically be anything else than a sinusoid function. Any observed variation will be due to variability between patients, intra-inter observer reliability, and the fact that depending on rotation, the most medial point of the fibula is not always the same, but this will never change the actual of the relationship and the shape of the trigonometric function.

As an example, we plotted the results in Figure 2., using 1cm as a hypothetical value for  $l$  and the same interval as the authors (-30 to +30°) for the rotation, also using an inverted scale on the horizontal axis. What can be seen is that this is exactly the same as the findings in your paper.

Figure 2 Here

Furthermore, this is only part (-30°-30°) of the sinusoid function, so it looks linear, but if the range is extended, as shown in Figure 3, the sinusoid appears.

Figure 3 Here

### 3-Conclusions

In conclusion, this is definitely a useful study, which will help raise awareness on the importance of avoiding rotational bias, however:

In order to avoid confusion by the readership, that rotational bias is the thing of conventional radiography, not CT. In this study, CT was only used to create models for repeated virtual conventional radiography for each patient (7 for each patient), which avoided 7 times extra radiation dose for the healthy volunteers. A similar study on hindfoot alignment measurements was performed and published in previous literature where the option was chosen to use a cadaver leg and conventional radiography rather than a virtual model of the latter, in order to avoid radiation on live patients/volunteers[1].

As a consequence, the conclusion could be that in order to use WB cone beam CT at its fullest, a structured reference technique has to be described in order to fix the plane of projection for axial measurements and DRR's relative to the foot and ankle referential, not the scanner's referential (or Field of View). In that respect, the sagittal, vertical plane passing through the 2nd metatarsal's long axis may be used, according to past literature, to define 0° rotation. In the future, maybe even more reliable landmarks may be investigated and defined using WB cone beam CT technology.

### Conflicts of interest statement

All the authors are members of the board of the « International Weight Bearing CT Society » (iWBCTS)

The iWBCTS is a non-profit association registered in Belgium, with the aim to raise awareness, study and validate the clinical use of Cone Beam Weight Bearing CT technology in the area of Foot and Ankle Surgery.

The WBCT ISG is, as any scientific society in orthopedics independently funded through sponsorships by companies with interests in this industry amongst which:

Curvebeam LLC

Carestream

Planmed Oy

Paragon 28

Foot Innovate

### REFERENCES

[1] Baverel L, Brillhault J, Odri G, Boissard M, Lintz F. Influence of lower limb rotation on hindfoot alignment using a conventional two-dimensional radiographic technique. *Foot Ankle Surg Off J Eur Soc Foot Ankle Surg* 2017;23:44–9. <https://doi.org/10.1016/j.fas.2016.02.003>.

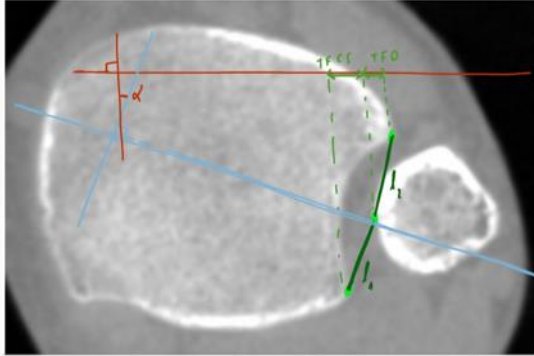


Figure 1: Trigonometric interpretation of the syndesmosis axial slab

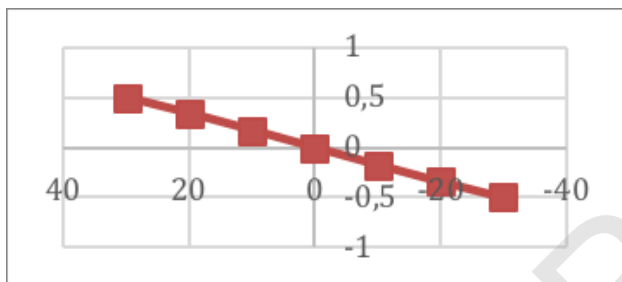


Figure 2: shape of trigonometric relationship in the study interval ( $-30^\circ$  to  $+30^\circ$ )

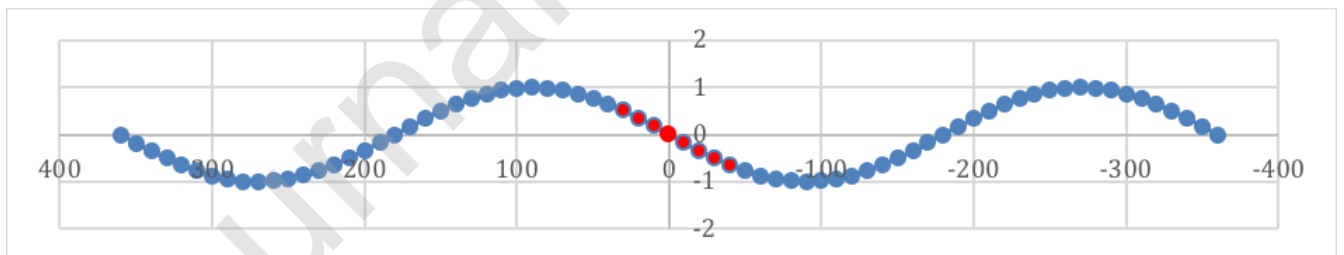


Figure 3: extended trigonometric relationship: the red part corresponds to the previous graph in Figure 2. or the study interval.