



Unusual Skin Toxicity after a Chemotherapeutic Combination

Cantisani C^{1*}, Paolino G¹, Passarelli F², Cigna E¹, Rota L², Pallotta S², Bangrazi C³, Lisi R³, Corsetti P¹, Calvieri S¹.

¹UOC of Dermatology, "Sapienza" University of Rome, Policlinico Umberto I

²IDI Rome, Italy

³Oncological Department "Sapienza" University of Rome, Policlinico Umberto I, Italy

A 66 year-old Caucasian patient presented to our attention complaining for an heliotrope rash and large diffuse erythematous itching with pustular-like lesions on his trunk, upper arms, involving the upper gluteus, with a yellowish necrotic like surface (Figure 1A,1B). Brown-to-purple lesions were also present on the right side of his back associated to muscle weakness. His personal medical history was positive for diabetes, hypertension and a 14 months history of squamous cell carcinoma of the lung. After 45 days of a sequential chemotherapeutic combination, with carboplatin/gemcitabine/taxotere/bevacizumab regimen the patient referred the onset of the skin reaction.

Laboratory investigations showed red blood cells 3.6×10^3 uL (4.52-5.10 X 10³ uL), hemoglobin 11.6 g/dL (14-18 g/dL), haematocrit 34.4% (42-50 %), MCV 16.2% femtolitre (80-96 femtolitre), white cells 10.9×10^3 uL (4-8.500/mm³) with neutrophilia, ferritin 931 ng/mL (20-300 ng/ml), LDH 480 U/L (122-222 U/L) and Potassium 5.4 g/dL (3.5-5.1 mEq/L). While the remaining laboratory investigations (including renal function, hepatic functions, autoantibody, calcium and phosphorous) were between normal ranges, as well as a chest X-Ray. The patient also showed an increased body temperature (maximum reached: 38°C), which disappeared after the administration of an intra-venous antibiotic therapy, with normalization of the laboratory tests. A cutaneous biopsy from the arm showed perivascular inflammatory cells in the dermis with increased dermal mucin, and atrophic epidermis with vacuolar basal changes and myofiber necrosis (Figure 2A,2B). According to the clinical and pathological findings, a final diagnosis of dermatomyositis with calciphylaxis aspect was made. The patient underwent to a steroidal immunosuppressive treatment (prednisolone 40 mg/day), with a fast response. However 6 weeks later, he developed a red-violaceous lesion on the lower-arms, histologically suggestive for Kaposi's sarcoma (KS) (Figure 3A,3B); for which the patient underwent to clinical and instrumental evaluations.

As known calciphylaxis (CPX) is a rare condition involving subcutaneous vascular calcification and cutaneous necrosis, mostly observed in patients with renal failure. However CPX may also appear in patients affected by polymyositis, Sjogren syndrome, Lupus

Erythematous systemicus, Sarcoidosis and rheumatoid arthritis, especially in children. Clinically CPX can present itself as subcutaneous nodules, infiltrate plaques or purpuric-like and livedo-like plaques, while in the late stages necrotic ulcers (with a bizarre shape and severe pain) may be the main cutaneous manifestations. After the diagnosis, the percentage of death is around 50% (during the first year), often due to sepsis or organ failure. The reported frequency of malignancy in DM has varied from about 20% to 25%, and probably with more aggressive forms, in this view it can be considered a paraneoplastic manifestation, more frequent in gynecologic malignancy, nasopharyngeal, but also gastrointestinal and lung cancer, especially in patient more than 50 years old. In our patient the lung cancer was in remission and no metastasis was found. Up to date, dermatomyositis (DM) has rarely been described to present as a drug-induced CPX, although a case of CPX with harbinger's myopathy was described in 1992 by Edelstein et al. [1]. In fact in a small percentage of patients the cutaneous lesions are due to or are exacerbated by drugs, but never reported with chemotherapeutic agents. Our report shows similarities with a recent published paper, where it was reported a gemcitabine-induced radiation myositis in a patient with dermatomyositis. At this point we are not able to state which drug induced skin toxicity.

To the best of our knowledge, in literature there are only 3 reports describing iatrogenic Kaposi's sarcoma (KS) in patients with DM [2-6], after treatments with prednisolone, prednisone and azathioprine [2-5]. In all these cases KS developed after an immunosuppressive treatment, with a median time of 9 months (ranging between 1/2 months and 30 months). In our patient KS appeared 6 weeks after the immunosuppressive treatment beginning. In this regard KS should be seen as a result of the immunosuppressive treatment, concluding that KS, not usually associated with DM, can appear in this group of patients after an immunosuppressive treatment, with a faster onset time. The pathogenesis of the muscle disease is becoming better understood, but the cutaneous disease mechanisms remain enigmatic. Our patient was under carboplatin/gemcitabine/taxotere/bevacizumab regimen to treat the lung cancer, however, no similar skin toxicity has never been described in literature and is not possible to state which drug can be directly connected, therefore CPX could be explained as drug induced or as a paraneoplastic sign, which revealed in advance another tumour (i.d. KS).

This observation is important for rheumatologists, dermatologists

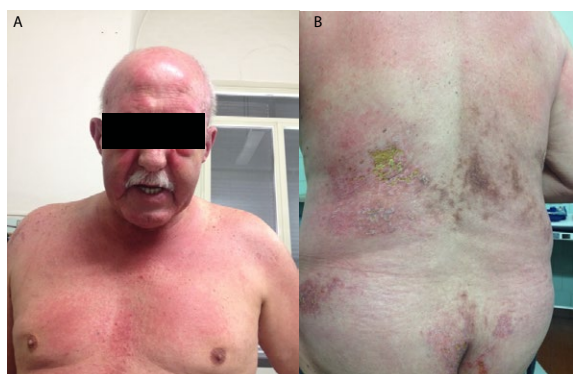

Figure 1: Clinical image Malar and facial dusky erythema associated to massive periorbital edema. Large erythematous lesions on the back, involving also the upper part of gluteus, with a pseudo-necrotic surface, sometimes with a yellowish colour

*Corresponding author: Cantisani C MD, UOC of Dermatology "Sapienza" University of Rome, Italy, Tel: +393479385719; Fax: +390649976933; E-mail: carmencantisaniater@gmail.com

Received July 15, 2015; Accepted August 06, 2015; Published August 13, 2015

Citation: Cantisani C, Paolino G, Passarelli F, Cigna E, Rota L, et al. (2015) Unusual Skin Toxicity after a Chemotherapeutic Combination. Clin Pharmacol Biopharm 4: 141. doi:[10.4172/2167-065X.1000141](https://doi.org/10.4172/2167-065X.1000141)

Copyright: © 2015 Cantisani C et al. This is an open-access article distributed under the terms of the Creative Commons Attribution License, which permits unrestricted use, distribution, and reproduction in any medium, provided the original author and source are credited.

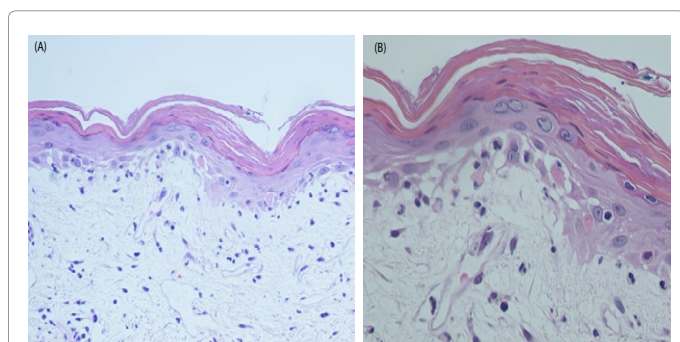


Figure 2: (a) Histologic findings [haematoxylin and Eosin 20x] Perivascular inflammatory cells in the dermis with increased dermal mucin (B) [Haematoxylin and Eosin 20x] Atrophic epidermis with vacuolar basal changes and myofiber necrosis.

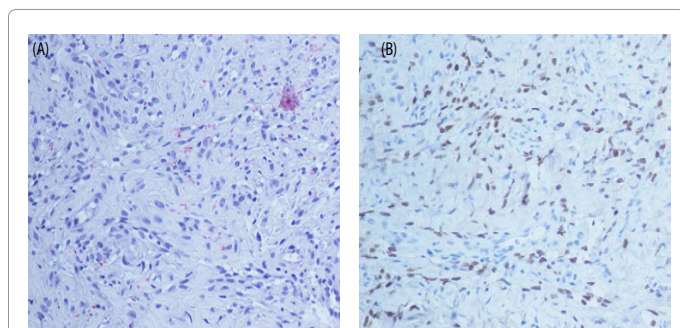


Figure 3: (A) [Haematoxylin and Eosin 10x] Fascicular spindle cells and vascular cleft filled with erythrocytes. Monomorphous endothelial cells with dense nuclei without mitoses (B) [10X] Positivity to HHV8

and oncologists, due to the association between malignancy and dermatomyositis and the common use of gemcitabine as a chemotherapeutic agent, showing also how a steroid treatment can lead to an improvement of the cutaneous and muscular symptomatology, but it can induce immune dysregulation [7]. Assuming that prognosis is poor in oncologic patients, a careful evaluation of each patient should be part of their initial and follow-up assessments.

Acknowledgments

This paper was supported by associazione Romana Ricerca Dermatologica.

References

1. Edelstein CL, Wickham MK, Kirby PA (1992) Systemic calciphylaxis presenting as a painful, proximal myopathy. *Postgrad Med J* 68: 209-211.
2. Simeoni S, Puccetti A, Moruzzi S, Tinazzi E, Peterlana D, et al (2007) Dermatomyositis complicated with Kaposi sarcoma: a case report. *Clin Rheumatol* 26: 440-442.
3. Weiss VC, Serushan M (1982) Kaposi's sarcoma in a patient with dermatomyositis receiving immunosuppressive therapy. *Arch Dermatol* 118:183-185.
4. Almong Y, Ben-Yehuda A, Ben-Chetrit E (1992). Dermatomyositis associated with the recurrence of transitional cell carcinomas and Kaposi's sarcoma. *Clin Exp Rheumatol* 92: 285-288.
5. Louthrenoo W, Kasitanon N, Mahanuphab P, Bhoopat L, Thongprasert S (2003) Kaposi's sarcoma in rheumatic diseases. *Semin Arthritis Rheum* 2003; 32:326-333.
6. Weiss VC, Serushan M (1982) Kaposi's sarcoma in a patient with dermatomyositis receiving immunosuppressive therapy. *Arch Dermatol* 118:183-185.
7. Graf SW, Limaye VS, Cleland LG (2014) Gemcitabine-induced radiation recall myositis in a patient with dermatomyositis. *Int J Rheum Dis*. 7: 696-697