



Evaluation of pharmacological correction of L-NAME-induced endothelial dysfunction, platelet aggregation and venous tone with diosmin Detralex 1000 mg

Yulia S. Lukyanova¹, Pavel D. Kolesnichenko¹, Vladimir V. Gureev¹, Lyudmila A. Zhilinkova²

¹ Belgorod State National Research University, 85 Pobedy St. Belgorod 308015, Russian Federation

² Kursk Academy of The Public and Municipal Service, 9 Stantsionnaya St. Kursk 305044, Russian Federation

Corresponding author: Yulia S. Lukyanova (1214789@bsu.edu.ru)

Academic editor: Mikhail Korokin ♦ Received 6 October 2018 ♦ Accepted 20 November 2018 ♦ Published 6 December 2018

Citation: Lukyanova YS, Kolesnichenko PD, Gureev VV, Zhilinkova LA (2018) Evaluation of pharmacological correction of L-NAME-induced endothelial dysfunction, platelet aggregation and venous tone with diosmin Detralex 1000 mg. *Research Results in Pharmacology* 4(4): 21–27. <https://doi.org/10.3897/rrpharmacology.4.31748>

Abstract

Introduction. Chronic venous diseases are one of the urgent problems of modern medicine. Recent studies have shown high significance of endothelial dysfunction (ED) and oxidative stress in their pathogenesis. For the correction of the occurring changes, drugs of the flavonoid group, particularly diosmin and hesperidin, are currently used. Numerous studies have confirmed a vast range of biological effects of diosmin; however, there are only sporadic data on its endothelium protective effects.

Materials and methods. The study was performed in 70 white mature male rats of Wistar line, weighing 180-220 g. ED simulation was performed using non-selective blocker of NO-synthase N-nitro-L-arginine methyl ester (L-NAME). Functional vascular tests and biochemical markers were used to determine a degree of correction of functional disorders. An anti-inflammatory effect of Detralex 1000 mg was estimated in 10 mature albino rabbits weighing 2800 - 3200 g by using o-xylene. The study of the venotonic property of the drug was carried out in the experiment in an isolated segment of the rats' portal vein with Ca²⁺ solutions at a concentration of 0.08-1.75 mM. The histologic specimens were prepared in accordance with the generally accepted methods.

Results and discussion. The administration of the test drug did not lead to a statistically significant decrease in blood pressure in the conditions of L-NAME-induced ED. However, there was a dose-dependent statistically significant decrease in the coefficient of ED (CED), which indicates a positive endothelium protective effect. Course administration of Detralex 1000 mg leads to a significant dose-dependent correction of platelet aggregation disorders, which is manifested in the extended aggregation time. The results of studying an anti-inflammatory activity of the drug showed a decrease in the size of spots caused by the application of o-xylene, and the extension of the time interval before their onset. Studying a Ca²⁺-mediated smooth muscle response showed that the vein contractile force reaches its maximum at a higher dosage of the drug with a lower concentration of Ca²⁺. In the morphological study of the stomach wall, small and large intestine of the intact rats and rats receiving a course of Detralex 1000 mg, there were no inflammatory changes in the mucosa of the comparison group.

Conclusions. The study found that Detralex 1000 mg significantly reduces the ED coefficient and slows platelet aggregation against the background of L-NAME-induced ED; the efficacy is dose-dependent. Detralex 1000 mg dose-dependently reduces vascular permeability disorders caused by the application of o-xylene. The test drug has a Ca²⁺-mediated mechanism of increasing the contractile activity of the venous wall. It was found that the course administration of the drug per os has no local irritative effect.

Keywords

platelet aggregation, vein-specific inflammation, Detralex, diosmin, chronic venous insufficiency, endothelial dysfunction

Introduction

Chronic venous diseases are one of the urgent problems of the modern medicine (Naess et al. 2007, Spencer et al. 2009). Recent studies have shown the high importance of endothelial dysfunction (ED) and oxidative stress in their pathogenesis (Nebylitsin et al. 2008, Castro-Ferreira et al. 2018). In the walls of the vessels involved in the pathological process, there is an increased production of proinflammatory cytokines: IL-6, IL-8, MMP-31 and proteolytic enzymes, adhesion molecules, and accumulation of lipid peroxidation products (Lattimer et al. 2016, Denisiuk 2017). In addition, there is an increase in the adhesive properties of platelets and leukocytes to the endothelium, with the latter further migrating the into the vessel wall (Khadieva et al. 2016). The resulting vein-specific inflammation leads to a violation of endothelial function and permeability of the vascular wall (Aliev et al. 2008, Kudryavtsev et al. 2017). The final of the subsequent complex of pathophysiological events is disruption of the venous wall tone and its morphological structure (Raffetto 2018).

The flavonoid group of drugs, particularly those containing diosmin and hesperidin, is actively used nowadays for the correction of venous tone and reduction of the core symptoms of chronic venous insufficiency (Belcaro et al. 2002, Boisseau 2002). Numerous studies have confirmed a wide range of biological effects of diosmin, including its anti-ulcer, antimutagenic, antioxidant, and anti-inflammatory effects (Benavente-Garcia and Castillo 2008, Gracias et al. 2018). Antioxidant effects of Detralex are connected with the inhibition of endothelin-1 synthesis and direct reduction of the production of prostaglandin E₂, F₂ and thromboxane A₂ (Manthey 2000, Feldo et al. 2018, Pietrzycka et al. 2015).

There is evidence of increased pressor effects of Ca²⁺ by diosmin (Savineau and Marthan 1994). It is also found that diosmin affects alpha- and beta-2-adrenoreceptors and, like endogenous catecholamines, increases the tone of the venous vessels (Borisova et al. 2008).

Treatment of chronic venous pathology with flavonoid preparations implies their long-term course administration per os (up to 6 months), which makes the issue of their possible local toxic effect relevant (Stoyko and Gudymovich 2006).

Objective: to evaluate experimentally the pharmacological correction of ED, vascular permeability, platelet aggregation and venous tone with diosmin Detralex 1000 mg, as well as to assess its local irritative effect in the course of treatment.

Materials and methods

The test drug is Detralex 1000 mg (France, Servier), which is a micronized purified fraction of flavonoids containing 90% of micronized diosmin (900 mg) and 10% of flavonoids in terms of hesperidin (100 mg), with a maximum fractionation of the substance to particles with a diameter of <2 microns, which makes it possible to improve the absorption of the substance (Garner et al. 2002).

The ED simulation was performed in 40 white male rats of Wistar line weighing 180–220 g. Non-selective blocker of NO-synthase N-nitro-L-arginine methyl ester (L-NAME) was administered intraperitoneally at a dose of 25 mg/kg/day for seven days. On the 7th day under anesthesia (chloral hydrate 300 mg/kg), a catheter was inserted into the left carotid artery to record hemodynamic parameters. The hemodynamic parameters: systolic blood pressure (SBP), diastolic blood pressure (DBP), and heart rate (HR) were measured continuously using a sensor and hardware for invasive measurement of hemodynamic parameters BIOPAC MP-150 (USA), with a TSD-104A module and computer software ASQKNOWLEDGE 4.2. Functional tests are the intravenous administration of acetylcholine (40 µg/kg) and sodium nitroprusside (30 µg/kg).

All the animals were divided into 4 groups: 1st group – intact rats treated with physiological solution in equivolume doses, 2nd group – rats treated with L-NAME intraperitoneally for 7 days, 3rd - rats treated with NAME intraperitoneally + Detralex 1000 mg per os at the minimum therapeutic dose of 86 mg/kg/day for 7 days, 4th group – rats treated with L-NAME intraperitoneally + Detralex 1000 mg per os at the maximum therapeutic dose of 260 mg/kg/day for 7 days. The development of ED in the experimental animals, as well as the degree of its correction by the test drug, was estimated by the calculated coefficient of ED (CED) (Pokrovskii et al. 2006).

The level of NO metabolites (i.e. the total concentration of nitrates and nitrites, NOx) was determined colorimetrically according to the stain intensity when using sulfanilamide nitrite, a component of Griess reagent, in the diazotization reaction (Metelskaya and Gumanov 2005).

Platelet aggregation was studied by visual micromethod using ADP, collagen, thrombin, ristomycin, and adrenaline as inducers.

To study the anti-inflammatory activity of the drug by Oivin's method (Suleyman et al. 2001), the experiments were conducted in 10 adult albino rabbits weighing 2800–3200 g. The rabbits were fixed, with the fur on the abdomen skin (the area of 13 cm) being cut off beforehand. During the study, the albino rabbits were administered

once Detralex 1000 mg at the maximum (100 mg/kg/day) and minimum (34 mg/kg/day) therapeutic doses 9 hours before the administration of the permeability indicator, namely Evans blue solution. The indicator of capillary permeability was the onset time of blue-colored spots on the skin and their diameter.

To estimate Ca^{2+} -dependent smooth muscle response, 30 male rats of Wistar line were divided into 3 groups. 1st group – control, 2nd group – rats receiving Detralex 1000 mg at the minimum therapeutic dose of 86 mg/kg/day, 3rd group – rats receiving Detralex 1000 mg at the maximum therapeutic dose of 260 mg/kg per day. The drug was administered per os once a day for 7 days.

After the anesthesia (chloral hydrate 300 mg/kg), a portal vein preparation 25 ± 4 mm long was taken from each animal. The preparation was placed vertically in the BIOPAC station reservoir for testing tissues (at an initial tension of 0.5 g). The lumen of the isolated vein was ligated, which excluded the contact of solutions with the endothelium. The tests were performed with solutions of Ca^{2+} at a concentration of 0.08–1.75 mM (Savineau and Marthan 1994). The solutions were added into the perfusate sequentially, from the minimum to the maximum concentration of Ca^{2+} . As the base solution, a modified Krebs–Henseleit solution was used, in which the concentration of Ca^{2+} had been changed; isotonicity was achieved by changing the content of sodium chloride (all chemicals by Reakhem, Russia). The oxygenation of the solutions was performed by using a gas mixture of 95% O_2 and 5% CO_2 . The temperature of all the solutions was 30°C. Registration and processing of the data was performed using the BIOPAC ASQKNOWLEDGE 4.2 software.

To estimate the local irritative effect of Detralex 1000 mg, a special morphological study of the stomach, small intestine and large intestine of rats treated with Detralex 1000 mg at a maximum therapeutic dose of 260 mg/kg once a day for 7 days was performed.

The recovered organs were fixed in 10% formalin solution after macroscopic examination and weighing. The samples for histological examination were cut out from the stomach wall along the lesser curvature including the cardiac part and a body area (glandular zone).

In the standard mode, the material was embedded into paraffin in a spin tissue processor “STP-120” (Microm International GmbH, Germany), using a battery of ethyl alcohol and xylene. The filling of blocks with standard

orientation of samples was carried out in paraffin in Microm EC 350 embedding station (Microm International GmbH, Germany). To ensure the standardization, paraffin embedding was carried out in multi-blocks of 5–6 samples. The sections for histological examination of 5 μm were cut on an HM 340 E semi-automatic rotary microtome with slide feed and smoothing-out systems (Microm International GmbH, Germany). Hematoxylin and eosin staining was carried out in an automatic machine for staining histological sections and smears (Microm International GmbH, Germany).

A descriptive study of histological specimens was performed using a AxioScopeA1 microscope (Carl Zeiss Microimaging GmbH, Germany). The main part of the morphological studies was performed after creating an electronic gallery of images by means of a semi-automatic Miraz Desk slide scanner (Carl Zeiss Microimaging GmbH, Germany), which made it possible to standardize the modes of morphometric studies as much as possible. The scanner lens magnification was $\times 200$. Digital magnification in microphotographs and images during the analysis ranged from $\times 20$ (without software magnification) to X800 (at 40-fold software magnification). All the studies were conducted in accordance with the principles of the Helsinki Declaration.

Statistical processing of the results of the study was carried out by checking the data for the normality of distribution. The type of distribution was determined by the Shapiro-Wilk test. In the case of the normal distribution, the mean (M) and the standard error of the mean (m) were calculated. Intergroup differences were analyzed by parametric (Student's t-test) or nonparametric (Mann-Whitney U test) methods, depending on the type of distribution. All the calculations were performed using a package of MICROSOFT EXCEL 7.0 statistical software

Results and discussion

With the administration of L-NAME, on the 7th day there was a statistically significant increase in systolic and diastolic blood pressure from 135.7 ± 4.1 and 99.9 ± 3.3 to 188.3 ± 6.1 and 143.0 ± 2.9 mm Hg, respectively (Table 1), an increase in CED from 1.2 ± 0.1 to 5.0 ± 0.6 ($p < 0.05$) and a decrease in the final NO metabolites from 45.19 ± 2.89 to 22.69 ± 1.50 .

Table 1. The Effect of Detralex 1000 mg on Blood Pressure and SED in the Correction of Experimental Endothelial Dysfunction ($M \pm m$; $n=10$).

Group	Value	SBP, mm Hg	DBP, mm Hg	CED, relative unit (RU)	NO, $\mu\text{mol/ml}$
Intact		$135.7 \pm 4.1^\#$	$9.9 \pm 3.3^\#$	$1.2 \pm 0.1^\#$	$45.19 \pm 2.89^\#$
L-NAME		$188.3 \pm 6.1^*$	$143.0 \pm 2.9^*$	5.0 ± 0.6	$22.69 \pm 1.50^{**}$
L-NAME + Detralex (86 mg/kg/day)		$185.3 \pm 4.6^*$	$134.1 \pm 3.4^*$	$2.4 \pm 0.4^{**}$	$31.34 \pm 1.64^{**}$
L-NAME + Detralex (260 mg/kg/day)		$174.0 \pm 4.0^*$	$135.3 \pm 3.2^*$	$2.0 \pm 0.1^{*y}$	$34.42 \pm 2.20^{**}$

Note. * $p < 0.05$ compared to intact rats; # – $p < 0.05$ in comparison with L-NAME.

The introduction of the test drug did not lead to a statistically significant decrease in blood pressure. However, there was a dose-dependent statistically significant decrease in CED, which indicates a positive endothelium protective effect.

The administration of non-selective blocker of NO-synthase causes a violation of platelet aggregation, which is expressed in its acceleration (Table 2). The introduction of Detralex 1000 mg leads to a dose-dependent correction of disorders, which is manifested in the extension of platelet aggregation. It was found that in the maximum therapeutic dose the greatest efficacy of Detralex 1000 mg was observed when using adrenaline as an inducer: the extension of platelet aggregation time from 79.4 ± 2.7 to 96.9 ± 3.9 sec.

The results of the studies of an anti-inflammatory activity of the drug by Oivin's method presented in Table 3 indicate a decrease in the permeability of blood vessels with the introduction of the test drug, as evidenced by a decrease in the size of spots and the extension of the time interval of their onset. It should be noted that the use of Detralex 1000 mg at a dose of 260 mg/kg/day to a greater extent reduces the disruption of vascular permeability caused by the application of 0-xylene.

In the study of the Ca^{2+} -mediated smooth muscle response, it was found that the addition of Ca^{2+} to the solution in the control group led to an increase in venous tone starting with a concentration of 0.76 mmol/l, while 7-day administration of Detralex 1000 mg caused a significant increase in venous tone with a Ca^{2+} concentration of 0.25 mmol/l. At the same time, against the background of the course treatment with Detralex 1000 mg, the sensitivity of the venous smooth muscle wall to Ca^{2+} at a concentration of 0.76 mmol/l is significantly higher than that in the control. The effect of the drug is dose-dependent, which is manifested in reaching the maximum contractile force at a higher dosage of the drug with a lower concentration of Ca^{2+} . This is most clearly demonstrated in Figure 1.

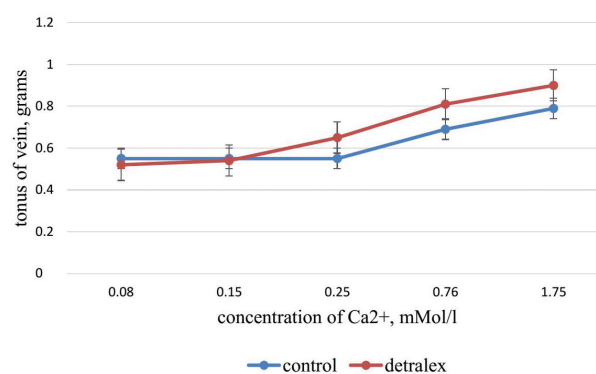


Figure 1. Effect of Detralex 1000 mg on contractility of isolated segment of rat portal vein.

The morphological study of the stomach wall of intact rats and rats against treating them with Detralex 1000 mg for 7 days at a dose of 260 mg/kg daily found no inflammatory changes in the mucosa of the comparison group. The general structure of the stomach wall is normal (Fig. 2). In the transition zone, there is a clear boundary between the non-keratinized stratified squamous epithelium of the esophagus and the fundal-type glandular mucosa. Glandular mucosa is 420-470 μm thick, and the pits are distributed evenly, with smooth contours, 90-110 μm deep, lined with a monomorphic single layer of columnar epithelium. On the surface, there is a moderate amount of mucus. The fundal glands evenly fill the thickness of the mucous membrane, with clearly differentiated areas: the surface part of 150-180 microns long, formed mainly with mucous and parietal cells, the bottom part of the same length, formed mainly with adeloniorphous cells. Parietal cells are with homogeneous oxyphilic cytoplasm, the main ones are with basophilic moderately granulated cytoplasm. No nuclear change is defined. The layers of lamina propria between the glands are thin; no significant leukocyte infiltration is determined. No changes were detected on the part of

Table 2. Effect of Detralex 1000 mg on Platelet Aggregation Rate in the Correction of Experimental Endothelial Dysfunction ($M \pm m$; $n=10$).

Group	Inductor	ADP, sec	collagen, sec	ristomycin, sec	adrenaline, sec
Intact		$43.6 \pm 1.5^{\#}$	$33.0 \pm 0.6^{\#}$	$41.5 \pm 1.9^{\#}$	$102.4 \pm 3.8^{\#}$
L-NAME		$30.2 \pm 1.3^*$	$27.1 \pm 1.1^*$	$31.6 \pm 1.2^*$	$79.4 \pm 2.7^*$
L-NAME + Detralex (86 mg/kg/day)		$34.6 \pm 1.5^*$	$31.5 \pm 1.0^{\#}$	$36.2 \pm 1.5^{\#}$	$92.3 \pm 3.9^{\#}$
L-NAME + Detralex (260 mg/kg/day)		$35.2 \pm 1.4^{\#}$	$32.1 \pm 1.0^{\#}$	$37.2 \pm 1.36^{\#}$	$96.9 \pm 3.9^{\#}$

Note. * – $p < 0.05$ compared to intact rats; # – $p < 0.05$ in comparison with L-NAME.

Table 3. Effect of Detralex 1000 mg on Vascular Permeability ($M \pm m$; $n=10$).

Group	Average area of the spots, cm^2	Time of spot onset, sec
Control	6.58 ± 0.08	202 ± 6.11
Detralex 1000 mg (86 mg/kg/day)	$5.20 \pm 0.06^*$	$243 \pm 7.30^*$
Detralex 1000 mg (260 mg/kg/day)	$4.38 \pm 0.05^*$	$290 \pm 6.15^*$

Note. * – $p < 0.05$ in relation to the control group.

other membranes of the wall. Blood content of all the membranes is moderately equal.

Histological examination of the small intestine of rats after the course treatment with Detralex 1000 mg at a dose of 260 mg/kg daily, neither inflammatory nor atrophic changes of the small intestine mucosa were identified (Fig.3). The villi of the mucous membrane are covered with columnar epithelium. In the bottom parts of the crypts, there are numerous mitotically dividing epithelial cells. In the stroma of the villi, there are many plasma cells, sometimes with an admixture of eosinophils.

Estimating the condition of the mucous membrane of the large intestine of rats treated with Detralex 1000 mg for 7 days at a dose of 260 mg/kg daily, neither inflammatory nor dystrophic changes were recorded (Fig. 4). The intestinal mucosa is covered with columnar

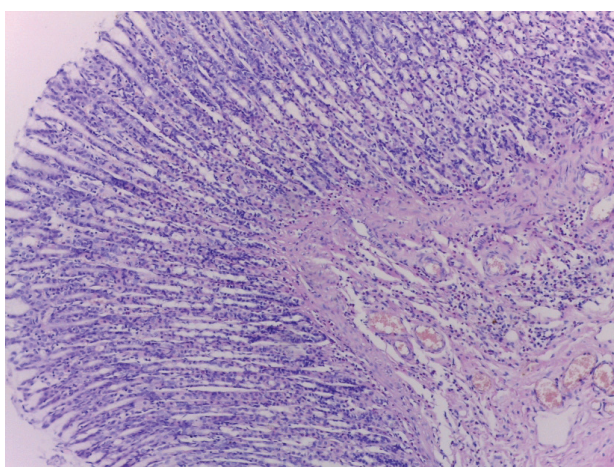


Figure 2. Histological structure of gastric mucosa after 7-day administration of Detralex 1000 mg at a dosage of 260 mg/kg/day. Glandular zone of the mucous membrane is without visible morphological changes, no inflammatory changes. Staining with hematoxylin and eosin. Microphoto. $\times 200$ (digital).

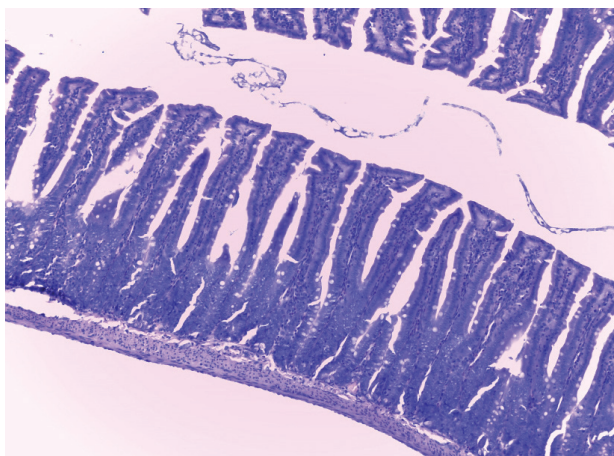


Figure 3. The structure of the wall of the jejunum after 7-day administration of Detralex 1000 mg at a dosage of 260 mg/kg/day: the mucous membrane is of the usual structure, no visible morphological changes, no inflammatory changes. Staining with hematoxylin and eosin. Microphoto. $\times 200$ (digital).

epithelium. There are numerous mitotically dividing epithelial cells.

The results of microscopic examination of the internals of rats receiving the test drug showed that Detralex 1000 mg does not cause either dystrophic, inflammatory or other pathological changes of the internals in the test dosage.

According to a number of studies, besides the restoration of NO synthesis, an endothelium-protective effect of diosmin is mediated by an increase in the activity of antioxidant enzymes, in particular superoxide dismutase (Cotelle 2001, Wang et al. 2006). This creates the conditions for the restoration of antioxidant balance in the endothelium and prevents its further damage.

Other studies have also shown that diosmin reduces the synthesis of endothelin-1, which causes the proliferation of smooth myocytes and has a pronounced pro-inflammatory effect (Pietrzycka et al. 2015). In particular, it induces the synthesis of integrins that enhance the migration and adhesion of fibroblasts and platelets, increases vascular permeability, activates neutrophils, mast cells and T-lymphocytes, which leads to the release of pro-inflammatory cytokines, mediators and the launch of the leukocyte-endothelial cascade. Mediators of inflammation – prostaglandin E2 and thromboxane A2, in their turn, increase platelet aggregation and have a powerful pro-coagulant effect (Tyurenkov et al. 2012). In addition to inhibiting the synthesis of endothelin-1, there is evidence of a direct influence of diosmin on a decrease in the production of prostaglandin E2, F2 and thromboxane A2, which also causes its anti-inflammatory effect (Manthey 2000, Feldo et al. 2018).

The extension of platelet aggregation rate in the experiment in a group of animals receiving Detralex 1000 mg against the background of simulated ED is due to the restoration of NO synthesis, which is a natural disaggregation (Tyurenkov et al. 2012).

The results of the experiment to study the venotonic effect of diosmin suggest a dose-dependent increase in

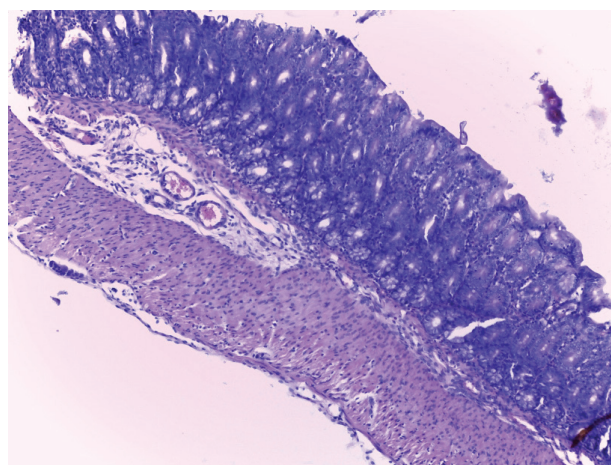


Figure 4. Colon after 7-day administration of Detralex 1000 mg at a dosage of 260 mg/kg/day with the structure of all membranes corresponding to that of the intact. There were no inflammatory changes in the lamina propria. Staining with hematoxylin and eosin. Microphoto. $\times 200$ (digital).

sensitivity of the segment of the portal vein with isolated endothelium to Ca^{2+} in the course treatment with Detralex 1000 mg. A number of studies have shown that such an increase in sensitivity of smooth myocytes to Ca^{2+} is also influenced by phosphatase inhibitors (Gong et al. 1992) or agonists of alpha-adrenergic receptors (Kitazawa et al. 1991). In the case of alpha-adrenergic receptors, increased sensitivity is most likely associated with G-proteins, which implies accelerated phosphorylation of the myosin component of the chains (Nishimura et al. 1990).

Conclusion

According to the results of studying an endothelium-protective activity of Detralex, 1000 mg, it was established

that the test drug significantly reduces CED and slows the aggregation of platelets against the background of ED simulation. It should be noted that the efficacy of endothelium-protective action of the drug is dose-dependent. The results of studying the data on the effect of Detralex 1000 mg on vascular permeability suggest that the drug can dose-dependently reduce vascular permeability disorders caused by the application of o-xylene.

Detralex 1000 mg has a Ca^{2+} -mediated mechanism of increasing the contractile activity of the venous wall.

Detralex 1000 mg, when intragastrically administered to rats at a maximum therapeutic dose of 260 mg/kg/day, does not lead to either macroscopic or histological changes in the stomach, small intestine and large intestine, therefore does not have a local irritative effect.

References

- Aliev SA, Ibishov KG, Aliev ES (2008) Certain aspects of pathogenesis of hemorheological and trophic disturbances and their pharmacological correction in patients with chronic venous insufficiency. *Vestnik Khirurgii Imeni I. I. Grekova* 167(2): 39–43. [PubMed]
- Belcaro G, Cesarone MR, Bavera P, Ricci A, Renton S, Leon M, Ippolito E, Dugall M, Acerbi G (2002) Venoruton1000, Paroven, 0-[beta-hydroxyethyl]-rutosides vs. Daflon 500 in chronic venous disease and microangiopathy: an independent prospective, controlled, randomized trial. *Journal of Cardiovascular Pharmacology and Therapeutics* 7(3): 139–45. <https://doi.org/10.1177/107424840200700303> [PubMed]
- Benavente-Garcia O, Castillo J (2008) Update on uses and properties of citrus flavonoids: new findings in anticancer, cardiovascular, and anti-inflammatory activity. *Journal of Agricultural and Food Chemistry* 56(15): 6185–205. <https://doi.org/10.1021/jf8006568> [PubMed]
- Boisseau MR (2002) Pharmacological targets of drugs employed in chronic venous and lymphatic insufficiency. *International Angiology: a Journal of the International Union of Angiology* 21(2 Suppl 1): 33–39. [PubMed]
- Borisova RP, Bubnov NA, Fionik OV (2008) The effect of diosmin on contractile function of rat venous and lymphatic vessels. *Bulletin of Lymphology [Vestnik limfologii]* 2: 50. [in Russian]
- Castro-Ferreira R, Cardoso R, Leite-Moreira A, Mansilha A (2018) The role of endothelial dysfunction and inflammation in chronic venous disease. *Annals of Vascular Surgery* 46: 380–393. <https://doi.org/10.1016/j.avsg.2017.06.131> [PubMed]
- Cotellet N (2001) Role of flavonoids in oxidative stress. *Current Topics in Medicinal Chemistry* 1(6): 569–590. <https://doi.org/10.2174/1568026013394750> [PubMed]
- Denisiuk TA (2017) Pharmacotherapeutic strategies for endothelial dysfunction correction with use of statins in syndrome of systemic inflammatory response. *Research Result: Pharmacology and Clinical Pharmacology* 3(4): 35–77.
- Feldo M, Wozniak M, Wojciak-Kosior M, Sowa I, Kot-Wasik A, Aszyk J, Bogucki J, Zubilewicz T, Bogucka-Kocka A (2018) Influence of diosmin treatment on the level of oxidative stress markers in patients with chronic venous insufficiency. *Oxidative Medicine and Cellular Longevity* 2018: e2561705. <https://doi.org/10.1155/2018/2561705> [PubMed] [PMC]
- Garner RC, Garner JV, Gregory S, Whattam M, Calam A, Leong D (2002) Comparison of the absorption of micronized (Daflon 500 mg) and nonmicronized 14C-diosmin tablets after oral administration to healthy volunteers by accelerator mass spectrometry and liquid scintillation counting. *Journal of Pharmaceutical Sciences* 91(1): 32–40. <https://doi.org/10.1002/jps.1168> [PubMed]
- Gong MC, Cohen P, Kitazawa T, Ikebe M, Masuo M, Somlyo AP, Somlyo AV (1992) Myosin light chain phosphatase activities and the effects of phosphatase inhibitors in tonic and phasic smooth muscle. *Journal of Biological Chemistry* 267(21): 14662–14668. [PubMed] [JBC]
- Gracias C, de Souza M, Cyrino FZ, de Carvalho JJ, Blanc-Guillemaud V, Bouskela E (2018) Protective effects of micronized purified flavonoid fraction (MPFF) on a novel experimental model of chronic venous hypertension. *European Journal of Vascular and Endovascular Surgery* 55(5): 694–702. <https://doi.org/10.1016/j.ejvs.2018.02.009> [PubMed]
- Khadieva TA, Dovgan AP, Pokroskaya TG (2016) Method of correction of endothelial dysfunction with combination of ademetonine and taurine. *Research Result: Pharmacology and Clinical Pharmacology* 2(2): 36–40. <https://doi.org/10.18413/2313-8971-2016-2-2-36-40>
- Kitazawa T, Gaylinn BD, Denney GH, Somlyo AP (1991) G-protein-mediated Ca^{2+} sensitization of smooth muscle contraction through myosin light chain phosphorylation. *Journal of Biological Chemistry* 266(3): 1708–1715. [PubMed] [JBC]
- Kudryavtsev KV, Korokin MV, Gudyrev OS (2017) Pharmacological efficacy of an inhibitor of arginase-2 KUD975 with L-NAME-induced endothelial dysfunction. *Research Result: Pharmacology and Clinical Pharmacology* 3(1): 10–17. <https://doi.org/10.18413/2500-235X-2017-3-1-10-17>
- Lattimer CR, Kalodiki E, Geroulakos G, Hoppensteadt D, Fareed J (2016) Are inflammatory biomarkers increased in varicose vein blood? *Clinical and Applied Thrombosis/Hemostasis* 22(7): 656–64. <https://doi.org/10.1177/1076029616645330> [PubMed]
- Manthey JA (2000) Biological properties of flavonoids pertaining to inflammation. *Microcirculation* 7(6 Pt 2): 29–34. <https://doi.org/10.1080/713774006> [PubMed]
- Metelskaya VA, Gumanov NG (2005) Nitric oxide: role in regulation of the biological functions, methods of determination in the human

- blood. *Laboratory Medicine [Laboratornaya meditsina]* 7: 19–24. [in Russian]
- Naess IA, Christiansen SC, Romundstad P, Cannegieter SC, Rosendaal FR, Hammerstrom J (2007) Incidence and mortality of venous thrombosis: a population-based study. *Journal of Thrombosis and Haemostasis* 5(4): 692–9. <https://doi.org/10.1111/j.1538-7836.2007.02450.x> [PubMed]
 - Nebylitsin YS, Sushkov SA, Solodkov AP, Doroshenko AS (2008) Endothelial dysfunction in acute and chronic venous insufficiency. *News of Surgery [Novosti Khirurgii]* 4: 141–153. [in Russian]
 - Nishimura J, Khalil RA, Drenth JP, van Breemen C (1990) Evidence for increased myofilament Ca²⁺ sensitivity in norepinephrine-activated vascular smooth muscle. *American Journal of Physiology* 259(2): 2–8. <https://doi.org/10.1152/ajpheart.1990.259.1.H2> [PubMed]
 - Pietrzycka A, Kozka M, Urbanek T, Stpniewski M, Kucharzewski M (2015) Effect of micronized purified flavonoid fraction therapy on endothelin-1 and tnf- α levels in relation to antioxidant enzyme balance in the peripheral blood of women with varicose veins. *Current Vascular Pharmacology* 13(6): 801–808. <https://doi.org/10.2174/1570161113666150827124714> [PubMed]
 - Pokrovskii MV, Kochkarov VI, Pokrovskaja TG, Gladchenko MP, Artjushkova EB, Pashin EN, Brusnik MV, Chulukova TN, Kljavs JP, Korneev MM, Zelenkova TI, Malyhin VA, Belous AS, Zaloznyh JI, Majakov AI (2006) Methodological approaches for quantitative evaluation of ED development in L-NAME-induced model of nitrogen oxide deficiency in experiment. *Kuban Scientific Medical Bulletin [Kubanskii nauchnyy meditsinskii vestnik]* 10: 72–77. [in Russian]
 - Raffetto JD (2018) Pathophysiology of chronic venous disease and venous ulcers. *Surgical Clinics of North America* 98(2): 337–347. <https://doi.org/10.1016/j.suc.2017.11.002> [PubMed]
 - Savineau JP, Marthan R (1994) Diosmin-induced increase in sensitivity to Ca²⁺ of the smooth muscle contractile apparatus in the rat isolated femoral vein. *British Journal of Pharmacology* 111(4): 978–980. [PubMed]
 - Spencer FA, Gore JM, Reed G, Lessard D, Pacifico L, Emery C, Crowther MA, Goldberg RJ (2009) Venous thromboembolism and bleeding in a community setting. The Worcester venous thromboembolism study. *Thrombosis and Haemostasis* 101(5): 878–885. <https://doi.org/10.1160/TH08-06-0352> [PubMed][PMC]
 - Stoyko Yu, Gudymovich V (2006) Phlebotropic therapy in a complex treatment of chronic venous insufficiency of the lower extremities. *Doctor [Vrach]* 7: 26–29. [in Russian]
 - Suleyman H, Demirezer LO, Kuruuzum A (2001) Effect of the aqueous extract of *Rumexpatientia* on xylool andhyaluronidase induced capillary permeability compared to indomethacin. *Die Pharmazie* 56(1): 92–93. [PubMed]
 - Tyurenkov IN, Voronkov AV, Slietsans AA, Volotova EV (2012) Endothelial protection drugs — a new class of pharmacological agents. *Annals of the Russian Academy of Medical Sciences [Vestnik Rossiiskoi Akademii Meditsinskikh Nauk]* 67(7): 50–57. [in Russian]
 - Wang L, Tu YC, Lian TW, Hung JT, Yen JH, Wu MJ (2006) Distinctive antioxidant and antiinflammatory effects of flavonols. *Journal of Agricultural and Food Chemistry* 54(26): 9798–9804. <https://doi.org/10.1021/jf0620719> [PubMed]

Author contributions

- **Yulia S. Lukyanova**, postgraduate student, Department of Pharmacology and Clinical Pharmacology, Belgorod State National Research University, 85 Pobedy St. Belgorod 308015 Russia; e-mail: 1214789@bsu.edu.ru. **ORCID 0000-0002-9087-5972**. The author performed the experimental work, statistical processing and evaluation of endothelium-protective, antiplatelet, venotonic and irritant effects of diosmin Detralex 1000 mg, as well as conducted the analysis and interpretation the results.
- **Mikhail V. Pokrovskii**, Doctor of Medicine, Full PhD, Head of the Department of Pharmacology and Clinical Pharmacology, Belgorod State National Research University, 85 Pobedy St. Belgorod 308015 Russia; e-mail: pokrovskii@bsu.edu.ru **ORCID 0000-0002-1493-3376**. The author suggested the idea of the study, was engaged in analyzing the results and making the conclusions.
- **Pavel D. Kolesnichenko**, junior research associate, Department of Pharmacology and Clinical Pharmacology, Belgorod State National Research University, 85 Pobedy St. Belgorod 308015 Russia; e-mail: kolesnichenko_p@bsu.edu.ru. The author took part in in vitro experiments, analyzed their results and made conclusions.
- **Vladimir V. Gureev**, Associate Professor, Department of Pharmacology and Clinical Pharmacology, Belgorod State National Research University, 85 Pobedy St. Belgorod 308015 Russia; e-mail: gureev@bsu.edu.ru. The author took part in the development of the article design and in the statistical processing of the research results.
- **Lyudmila A. Zhilinkova**, PhD in Technical Sciences, Associate Professor, Department of Philosophy, Social, Legal and Natural Sciences, Kursk Academy of The Public and Municipal Service, 9 Stantsionnaya St. Kursk 305044 Russia; e-mail: l_zhilinkova@mail.ru. The author took part in the development of the article design and in the statistical processing of the research results.