

Porcine Model for Deep Superior Epigastric Artery Perforator Flap Harvesting: Anatomy and Technique

Tiziana Roggio, MD*
Marco Pignatti, MD†
Marta Cajozzo, MD*
Pierluigi Tos, MD PhD‡
Giorgio De Santis, MD†
Cristina Garusi, MD§
Fabrizio Schonauer, MD¶
Francesco Moschella, MD*
Adriana Cordova, MD*
Salvatore D'Arpa, MD PhD*||

BACKGROUND

Microsurgical training on rats before starting with clinical practice is a well-established routine. Animal model training is less widespread for perforator flaps, although these flaps represent a technical challenge. Unlike other flaps, they require specific technical skills that need to be adequately trained on a living model¹: a cadaver is not enough because no bleeding, vessel damage, or vasospasm can be simulated.²

The purpose of this study was to assess the suitability of the porcine abdomen as a training model for the deep inferior epigastric artery perforator (DIEAP) flap, commonly used in human breast reconstruction.

METHODS

A female swine (*Sus scrofa domestica*, ssp; weight 25 kg) was used. The procedure was performed with the

*From the *Chirurgia Plastica e Ricostruttiva, Dipartimento di Discipline Chirurgiche, Oncologiche e Stomatologiche, Università degli Studi di Palermo, Palermo, Italy; †Dipartimento di Chirurgia Plastica e Ricostruttiva, Azienda Ospedaliero-Universitaria, Policlinico di Modena, Modena, Italy; ‡UOC di Microchirurgia e Chirurgia della Mano – ASST Gaetano Pini – CTO Milano, Milano, Italy; §Dipartimento di Chirurgia Plastica e Ricostruttiva, Istituto Europeo di Oncologia, Milano, Italy; ¶Chirurgia Plastica e Ricostruttiva, Università Federico II, Napoli, Italy; and ||Department of Plastic and Reconstructive Surgery, Gent University Hospital, Ghent, Belgium.*

Copyright © 2018 The Authors. Published by Wolters Kluwer Health, Inc. on behalf of The American Society of Plastic Surgeons. This is an open-access article distributed under the terms of the Creative Commons Attribution-Non Commercial-No Derivatives License 4.0 (CCBY-NC-ND), where it is permissible to download and share the work provided it is properly cited. The work cannot be changed in any way or used commercially without permission from the journal. *Plast Reconstr Surg Glob Open* 2018;6:e1659; doi: 10.1097/GOX.0000000000001659; Published online 20 February 2018.

pig under general anesthesia and in the supine position. A deep superior epigastric artery perforator (DSEAP) flap was harvested on the left side of the abdomen, including the 3 cranial nipples and stopping in the midline to spare the contralateral flap for another dissection (as in bilateral breast reconstructions in humans; Fig. 1).

All steps of a DIEAP harvest were simulated: superficial vein harvest, suprafascial perforator dissection, intramuscular perforator harvest with preservation of the nerves, and flap isolation. Observation of capillary refill was used to confirm flap viability at the end of the dissection.

The procedure was recorded by means of a GoPro camera and simultaneously with a head mounted (4× magnification) Loupecam system. Photographs were taken using 2 cameras during surgery at relevant time points.

RESULTS

At the end of the dissection, the flap was viable. The subcutaneous adipose tissue of the pig is less represented than in human and pigs have an additional muscular layer, the panniculus carnosus, which is the analogue

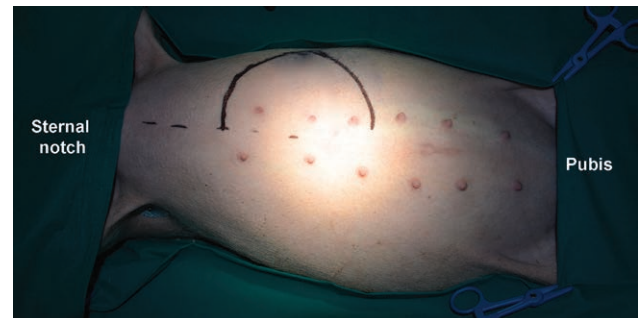

Fig. 1. Preoperative marking: a semi-circular skin paddle is drawn on the upper left side of the abdomen, including the 3 cranial nipples, without crossing the midline to spare the contralateral flap for a second dissection.

Disclosure: The authors have no financial interest to declare in relation to the content of this article. The Article Processing Charge was paid for by the authors.

SICPRE: SICPRE, Società Italiana di Chirurgia Plastica Ricostruttiva ed Estetica, national meeting, in Turin on September 21-24, 2016.

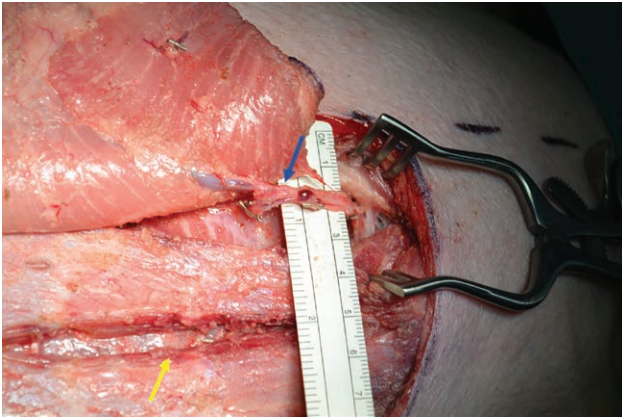


Fig. 2. DSEAP flap at the end of the dissection. Left lateral view. Head on the right hand side, midline above. The flap has been raised from lateral to medial and is visible on the upper left corner from its undersurface. Please note the muscle fibers of the panniculus carnosus on the undersurface of the flap. This is a difference with humans, who only have fat. The blue arrow shows the chosen perforator, located in the medial row. The Weitlaner retractor is placed at the cranial edge, to hold the muscle fibers spread and expose the main pedicle. The ruler gives an idea of the pedicle size. Close to the lower edge of the surgical wound, another split in the muscle can be seen, pointed at by the yellow arrow. This is the residual defect after isolation of the lateral row perforators. Each side allows the learner to practice perforator dissection twice: once with lateral and once with medial perforators.

of the human Scarpa's fascia. The rectus fascia is thinner. The perforators are lined in 2 rows: 1 lateral and 1 medial, as in the DIEAP, and the intercostal nerves cross the vessels, as happens in humans. The porcine rectus abdominis muscle is thinner than the human one, but vessels' branching faithfully reproduces the human model.¹

We identified 5 perforating vessels of more than 1 mm in diameter (2 lateral and 3 medial). We isolated a lateral

perforator first and a medial one last: the latter was eventually used to nourish the flap (Fig. 2).

CONCLUSIONS

The DSEAP flap allows one to closely reproduce all the steps of DIEAP flap harvesting and also to carry out the intramuscular dissection of 2 perforators for each side (up to 4 for each animal), confirming the adequacy of this pig model for microsurgical training. The deep superior epigastric artery is dominant in pigs.³ Despite this anatomical difference, the DSEAP allows one to reproduce the main steps of DIEAP flap harvesting, providing an excellent training model.

Moreover, the presence of double perforating rows allows simulating the dissection twice on each side.

Tiziana Roggio, MD

Chirurgia Plastica e Ricostruttiva
Dipartimento di Discipline Chirurgiche
Oncologiche e Stomatologiche
Università degli Studi di Palermo
Via del Vespro, 129
90127 Palermo, Italy
E-mail: tizianaroggio87@gmail.com

ACKNOWLEDGMENT

The donation was paid for by Egle Muti for Aldo Fontana.

REFERENCES

1. Bodin F, Diana M, Koutsomanis A, et al. Porcine model for free-flap breast reconstruction training. *J Plast Reconstr Aesthet Surg.* 2015;68:1402–1409.
2. Stefanidis D, Yonce TC, Green JM, et al. Cadavers versus pigs: which are better for procedural training of surgery residents outside the OR? *Surgery.* 2013;154:34–37.
3. Minqiang X, Jie L, Dali M, et al. Transmidline abdominal skin flap model in pig: refinements and advancements. *J Reconstr Microsurg.* 2012;28:111–118.