

Scientific Foundation SPIROSKI, Skopje, Republic of Macedonia
 Open Access Macedonian Journal of Medical Sciences. 2020 Apr 15; 8(A):113-118.
<https://doi.org/10.3889/oamjms.2020.4633>
 eISSN: 1857-9655
Category: A - Basic Sciences
Section: Pathology



Immunohistochemical Expression of “L1 cell Adhesion Molecule” in Endometrial Carcinomas

Aya Magdy Elyamany*, Solafa Amin Abd-ELaziz, Samar A. Elsheikh, Somia A. M. Soliman

Department of Pathology, Faculty of Medicine, Cairo University, Giza, Egypt

Abstract

Edited by: Sinisa Stojanoski
Citation: Elyamany AM, Abd-ELaziz SA, Elsheikh SA, Soliman SAM. Immunohistochemical Expression of “L1 cell Adhesion Molecule” in Endometrial Carcinomas. Open Access Maced J Med Sci. 2020 Apr 15; 8(A):113-118. <https://doi.org/10.3889/oamjms.2020.4633>
Keywords: Endometrial carcinoma; L1 cell adhesion molecule; Immunohistochemistry
***Correspondence:** Aya Magdy Elyamany, Department of Pathology, Faculty of Medicine, Cairo University, Giza, Egypt. Phone: +201226222858. E-mail: ayamagdy277@gmail.com
Received: 14-Mar-2020
Revised: 20-Mar-2020
Accepted: 27-Mar-2020
Copyright: © 2020 Aya Magdy Elyamany, Solafa Amin Abd-ELaziz, Samar A. Elsheikh, Somia A. M. Soliman
Funding: This research did not receive any financial support
Competing Interests: The authors have declared that no competing interest exists
Open Access: This is an open-access article distributed under the terms of the Creative Commons Attribution-NonCommercial 4.0 International License (CC BY-NC 4.0)

BACKGROUND: Endometrial cancer is the most common cancer of the female genital tract. No effective biomarkers currently exist to allow for an efficient risk classification of endometrial carcinoma or to direct treatment (adjuvant radiation and/or chemotherapy) or to triage pelvic and para-aortic lymphadenectomy. L1 cell adhesion molecule (L1CAM) a transmembrane protein of the immunoglobulin family that has been implicated in promoting tumor cell proliferation, migration, invasion, and metastasis became an attractive candidate as a potential biomarker in endometrial carcinoma and potential therapeutic target in high-risk groups.

OBJECTIVES: Evaluation of L1CAM expression in endometrial carcinoma and correlation of this expression with various pathological parameters.

MATERIALS AND METHODS: Immunohistochemical staining for L1CAM was performed on paraffin-embedded sections of 80 cases of endometrial carcinomas that underwent total hysterectomy with bilateral salpingo-oophorectomy. Expression of L1CAM in >10% of tumor cells was interpreted as positive.

RESULTS: L1CAM expression was detected in 22.5% of cases and showed statistically significant correlation with non-endometrioid histological type, high grade, high FIGO stage, high pathological (T) stage, cervical involvement, nodal metastasis, lymphovascular space invasion, and high-risk tumor according to the European Society for Medical Oncology system for risk stratification ($p < 0.05$).

CONCLUSION: The high rate of L1CAM expression in high-risk endometrial carcinomas suggests that L1CAM represents a potential marker for the identification of patients needing closer follow-up and aggressive treatment. In addition, its potential role as a therapeutic target for high-risk endometrial cancer seems promising.

Introduction

Endometrial cancer is the most common cancer of the female genital tract and the fourth most commonly diagnosed cancer among women in the United States with 61,880 new cases and 12,160 deaths estimated in 2019 [1].

In Egypt, endometrial carcinoma accounted for 31.4% of all malignant female genital system tumors and 4% of all primary malignant tumors according to Pathology-based Cancer Registry, Ain-Shams Faculty of Medicine [2]. Endometrial carcinoma represented 22.83% of all malignant female genital system tumors as reported by Cancer Pathology Registry, Cairo University, National Cancer Institute [3].

Although endometrial cancer is conventionally thought to be a cancer of the postmenopausal period, 14% of cases are diagnosed in premenopausal women; 5% of whom are younger than 40 years. The main risk factor of endometrial carcinoma is exposure to endogenous and exogenous estrogen associated with obesity, diabetes, early age at menarche, nulliparity, late-onset menopause, old age, and use of tamoxifen [4].

Conventionally, endometrial carcinomas have been classified as type I and type II; type I tumors were estrogen dependent and associated with endometrial hyperplasia, whereas type II tumors were estrogen independent and associated with endometrial atrophy. Endometrial carcinoma is also classified according to histopathological characteristics, with the most common subtypes being endometrioid carcinoma, serous carcinoma, carcinosarcoma, and clear cell carcinoma [5].

Correlations have been noted between the subtypes in these two classification systems; type I cancers generally have endometrioid histology with good prognosis and most type II cancers are serous carcinomas with poor prognosis. The prognostic value of this dualistic classification remains limited because 20% of endometrioid (i.e., type I) endometrial cancers relapse, whereas 50% of non-endometrioid (i.e., type II) endometrial cancers do not [6].

No effective biomarkers currently exist to allow for an efficient risk classification of endometrial carcinoma or to direct treatment (adjuvant radiation and/or chemotherapy) or to triage pelvic and para-aortic lymphadenectomy [7].

L1 cell adhesion molecule (L1CAM) – a transmembrane protein of the immunoglobulin family – has been implicated in promoting tumor cell proliferation, migration, invasion, and metastasis. L1CAM expression in tumor cells promotes disease progression by augmentation of cell motility, invasion, and metastasis in part through the activation of the extracellular signal-regulated kinase and also through epithelial-to-mesenchymal transition and Wnt signaling [8].

L1CAM expression in endometrial carcinoma appears to be an independent predictor for poor survival, with overexpression in advanced stage and high-grade endometrial carcinoma, serous histology, positive peritoneal cytology, deep myometrial invasion, and positive pelvic and para-aortic lymph nodes. L1CAM became an attractive candidate as a potential biomarker in endometrial carcinoma and potential therapeutic target in high-risk groups [9].

Materials and Methods

Retrieval of cases

The material of this cross-sectional study was collected as 80 formalin-fixed, paraffin-embedded endometrial carcinoma tissue sections from archives of Pathology Department, Kasr AL-Ainy (Cairo University Hospital) in the period from March 2013 to September 2016. The authors obtained the approval of Ethical Committee in the Faculty of Medicine, Cairo University.

Inclusion criteria included cases of endometrial carcinoma that underwent total hysterectomy with bilateral salpingo-oophorectomy. Exclusion criteria included cases received neoadjuvant therapy or cases with missed data.

The data collected from the pathology reports of these cases included age at time of diagnosis and lymph node status; nodal status was only documented for cases where pelvic lymphadenectomy was performed.

Histopathological examination

Each paraffin block was cut by rotatory microtome at 4 μ m thickness then mounted on glass slides and stained by hematoxylin and eosin for routine histopathological examination and on charged slides for immunostaining.

The tumors were histologically classified according to the latest World Health Organization recommendations [10]. Histological grading was performed according to the FIGO grading system [11]. Pathological staging was accomplished according to the FIGO staging system [12] and the eighth edition

(2017) of the American Joint Committee on Cancer's AJCC Cancer Staging Manual [13].

Lymphovascular space invasion (LVSI) was defined as the presence of tumor cells in a space lined by endothelial cells outside the immediate invasive border; intratumoral LVSI foci were not considered. Risk stratification was performed according to modified European Society for Medical Oncology (ESMO) system [14].

L1CAM immunohistochemical staining and evaluation

Immunostaining was done using fully automated immunohistochemical system, BenchMark XT (Ventana) autostainer, pH 6 for mouse monoclonal antibody L1CAM Ab-1, clone UJ127, Cat. #MS-770-R7, and 7.0 ml obtained from Thermo Fisher Scientific Anatomical Pathology (Fremont, CA, USA).

A section of schwannoma was used as positive control according to the manufacturer recommendations. Furthermore, nerves running through the deeper myometrium served as internal positive controls.

L1CAM membranous expression level was classified into two categories depending on the percentage of cells stained. Cases with more than 10% positively stained tumor cells were considered positive and those with <10% positively stained tumor cell were considered negative [15].

Statistical analysis

The histopathological and immunohistochemical data were then transferred to the SPSS software program, version 25 to be statistically analyzed. Simple descriptive statistics (arithmetic mean and standard deviation) were used for summary of quantitative data and frequencies were used for qualitative data. Estimation of the association between categorical variables was performed using the Chi-square test. $p < 0.05$ is considered as statistically significant.

Results

This study included 80 cases of endometrial carcinoma. The age of them ranged from 38 to 77 years with a mean of 60 ± 8.75 years. Among the studied cases, 83.8% of the cases were endometrioid carcinoma while 6.3% were serous carcinoma and 10% were malignant mixed Müllerian tumor (MMMT). Concerning FIGO grade, 20% of the cases were Grade 1, 45% were Grade 2, and 35% were Grade 3. Regarding FIGO stage, 68.8% of the cases were classified as FIGO Stage I, 13.8% were FIGO Stage II, and 17.5% were

FIGO Stage III. Out of all cases, 71.25% were classified as T1, 15% were T2, and 13.75% were T3.

Less than half of myometrial invasion was documented in 57.5% of the cases. Cervical, serosal, and/or adnexal and parametrial involvement by the tumor were detected in 17.5%, 11.25%, and 11.25% of the cases, respectively. Nodal metastasis and LVSI were present in 6.25% and 26.25% of the cases, respectively. According to ESMO system of endometrial carcinoma risk stratification, 43.75% of the cases were considered as high risk. The pathological characteristics of the studied cases are summarized in Table 1.

Table 1: Pathological characteristics of the studied cases

Pathological characteristics	n (%)
Histopathological type	
Endometrioid carcinoma	67 (83.75)
Serous carcinoma	5 (6.25)
MMMT	8 (10)
Histopathological grade	
Grade 1	16 (20)
Grade 2	36 (45)
Grade 3	28 (35)
FIGO stage	
I	55 (68.75)
II	11 (13.75)
III	14 (17.5)
Tumor (T) pathological stage	
T1	57 (71.25)
T2	12 (15)
T3	11 (13.75)
Myometrial invasion	
Less than half	46 (57.5)
More than half	34 (42.5)
Cervical involvement	
Present	14 (17.5)
Absent	66 (82.5)
Serosal and/or adnexal involvement	
Present	9 (11.25)
Absent	71 (88.75)
Parametrial involvement	
Present	6 (7.5)
Absent	74 (92.5)
Lymph nodal metastasis	
Present	5 (6.25)
Absent	16 (20)
Could not be assessed	59 (73.75)
LVSI	
Present	21 (26.25)
Absent	59 (73.75)
ESMO system of endometrial carcinoma risk stratification	
Low	27 (33.75)
Intermediate	10 (12.5)
Intermediate-high	8 (10)
High	35 (43.75)

MMMT: Malignant mixed Müllerian tumor, LVSI: Lymphovascular space invasion, ESMO: European Society for Medical Oncology.

L1CAM showed positive membranous expression in 22.5% of the cases while 77.5% of the cases were negative for it. Serous carcinoma cases showed the highest rate of L1CAM expression followed by MMTT then endometrioid histology with statistically significant difference ($p = 0.000$), Figure 1.

Grade 3 cases showed the highest rate of L1CAM expression followed by Grade 2 and then Grade 1 with statistically significant difference ($p = 0.002$). There were statistically significant direct correlations between L1CAM expression and both FIGO stage ($p = 0.006$) and tumor (T) pathological stage ($p = 0.017$).

Statistically significant direct correlations were found between positive L1CAM expression and cervical involvement ($p = 0.007$), nodal metastasis ($p = 0.027$),

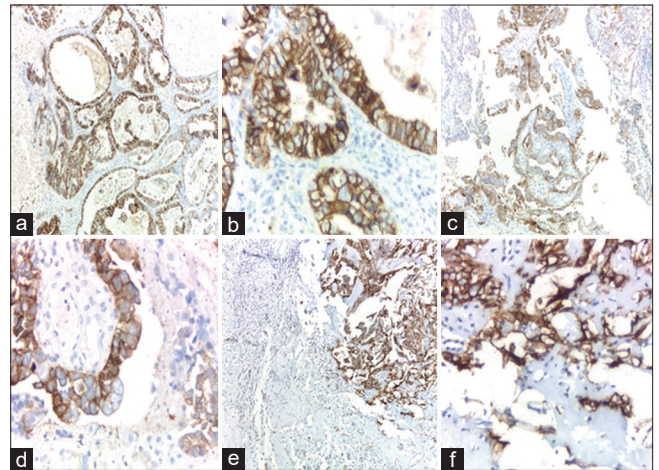


Figure 1: Positive L1CAM expression in various histological subtypes of endometrial carcinoma among the studied cases (a) endometrioid carcinoma ($\times 100$ original magnification), (b) endometrioid carcinoma ($\times 400$ original magnification), (c) serous carcinoma ($\times 100$ original magnification), (d) serous carcinoma ($\times 400$ original magnification), (e) malignant mixed Müllerian tumor ($\times 100$ original magnification), (f) malignant mixed Müllerian tumor ($\times 400$ original magnification)

and LVSI ($p = 0.046$). There were direct correlations between L1CAM expression and extent of myometrial invasion, serosal and/or adnexal involvement, and parametrial involvement. However, there were no significant differences in any of these correlations. Concerning ESMO risk stratification system, cases considered as high risk showed the highest rate of L1CAM expression with statistically significant difference ($p = 0.000$). Correlation of L1CAM expression with various pathological characteristics among studied cases is summarized in Table 2.

Discussion

Endometrial cancer is the most common gynecological malignancy. Currently available clinical and histopathological data do not allow for an efficient and well reproducible risk classification. This is especially true for early-stage disease where few patients suffer fatal relapse in spite of the absence of the established high-risk criteria [7].

L1CAM, a transmembrane protein of the immunoglobulin family that implicated in promoting tumor cell proliferation, migration, invasion, and metastasis, has been investigated in endometrial carcinoma. L1CAM immunohistochemistry could be an additional tool of considerable value for risk stratification in endometrial carcinomas, particularly recurrence potential and pelvic lymph node involvement [16].

L1CAM expression in this study was positive in 22.5% of cases. This figure was close to studies reported by van der Putten *et al.*, 2018; Kommos *et al.*,

Table 2: Correlation of L1CAM expression with various pathological characteristics among the studied cases

Pathological characteristics	L1CAM positive	L1CAM negative	p value
Histopathological type			
Endometrioid carcinoma	9 (13.4)	58 (86.6)	0.000*
Serous carcinoma	4 (80)	1 (20)	
MMMT	5 (62.5)	3 (37.5)	
Histopathological grade			
Grade 1	0 (0)	16 (100)	0.002*
Grade 2	6 (16.7)	30 (83.3)	
Grade 3	12 (42.9)	16 (57.1)	
FIGO stage			
I	7 (12.7)	48 (87.3)	0.006*
II	4 (36.4)	7 (63.6)	
III	7 (50)	7 (50)	
Tumor (T) pathological stage			
T1	8 (14)	49 (86)	0.017*
T2	5 (41.7)	7 (58.3)	
T3	5 (45.5)	6 (54.5)	
Myometrial invasion			
Less than half	10 (21.7)	36 (78.3)	0.850
More than half	8 (23.5)	26 (76.5)	
Cervical involvement			
Present	7 (50)	7 (50)	0.007*
Absent	11 (16.7)	55 (83.3)	
Serosal and/or adnexal involvement			
Present	3 (33.3)	6 (66.7)	0.409
Absent	15 (21.1)	56 (78.9)	
Parametrial involvement			
Present	3 (50)	3 (50)	0.093
Absent	15 (20.3)	59 (79.7)	
Lymph nodal metastasis			
Present	4 (80)	1 (20)	0.027*
Absent	4 (25)	12 (75)	
LVSI			
Present	8 (38.1)	13 (61.9)	0.046*
Absent	10 (16.9)	49 (83.1)	
ESMO system of endometrial carcinoma risk stratification			
Low	1 (3.7)	26 (96.3)	0.000*
Intermediate	0 (0)	10 (100)	
Intermediate-high	1 (12.5)	7 (87.5)	
High	16 (45.7)	19 (54.3)	

*Statistically significant. ESMO: European Society for Medical Oncology, MMT: Malignant mixed Müllerian tumor.

2018; Pasanen *et al.*, 2017; van der Putten *et al.*, 2016; and Geels *et al.*, 2016, where L1CAM positivity was found in 18%, 21.5%, 26.6%, 17%, and 17% of cases, respectively [17], [18], [19], [20], [21].

On the contrary, a lower rate of positive expression (8.4%) was reported by Kommos *et al.*, 2017, and a higher rate of positivity expression (51%) was reported by Van Gool *et al.*, 2016 [7], [8]. It is worthy to mention that the former concerned with low risk cases and the later concerned with high-risk cases.

Regarding the histological subtypes, serous carcinoma showed the highest rate of L1CAM expression followed by MMT and finally endometrioid carcinoma with statistically significant difference. This was compatible with results of Kommos *et al.*, 2018; Geels *et al.*, 2016; and Bosse *et al.*, 2014, who reported higher rate of L1CAM expression in non-endometrioid types, particularly serous carcinoma as reported by Tangen *et al.*, 2017 [18], [21], [22], [23].

In this study, the rate of L1CAM expression increased with the increase in the histological grade; Grade 1 (0%), Grade 2 (16.7%), and Grade 3 (42.9%) with statistically significant difference. This was compatible with the results of Kommos *et al.*, 2018, yet, with quite higher rates; 15.5%, 17.5%, and 67%, respectively [18]. Similarly, Van Gool *et al.*, 2016, reported significant association between L1CAM expression and higher tumor grade [8].

Concerning FIGO stage, the rate of L1CAM positivity increased with the increase in the FIGO stage; I (12.7%), II (36.4.7%), and III (50%) with statistically significant difference. This agreed with most of reported studies where L1CAM expression was correlated with higher FIGO stages [9], [18], [20]. Dissimilarly, no significant difference was reported by Van Gool *et al.*, 2016 [8].

Regarding (T) pathological staging, cases classified as T3 showed the highest rate of L1CAM expression (45.5%) followed by those classified as T2 (41.7%) and finally T1 cases (14%) with statistically significant difference. This correlation was not evaluated by other comparative studies. However, it is worthy to mention that the definitions of the T categories of endometrial carcinoma correspond to the stages accepted by FIGO.

Concerning the extent of myometrial invasion, cases showed more than half of myometrial invasion showed higher rate of L1CAM positivity, but these results were statistically insignificant similar to a study performed by Geels *et al.*, 2016 [21]. The same findings yet with statistically significant difference were reported by many studies [20], [23], [24].

Cases with cervical involvement by the tumor showed higher rate of L1CAM expression than cases with free cervix with statistically significant difference. This agreed with the results of Weinberger *et al.*, 2019 [25].

In this study, cases with serosal/adnexal and parametrial involvement by the tumor showed higher rates of L1CAM expression. However, no statistically significant difference could be documented. These correlations were not evaluated by other comparative studies.

In this study, cases with positive nodal metastasis showed higher rate of L1CAM positivity with statistically significant difference. Similar findings were reported by Weinberger *et al.*, 2019, and Tangen *et al.*, 2017 [23], [25].

On the contrary, Geels *et al.*, 2016, reported discordant results as they included only one case with positive nodal metastasis, in which the tumor was L1CAM negative. In addition, their result was statistically insignificant [21].

L1CAM expression rate in this study was higher in cases showed LVSI than in those with absent LVSI with statistically significant difference. This was consistent with the results of most reported studies [21], [25].

Concerning ESMO risk stratification system, high-risk cases in this study showed the highest rate of L1CAM expression with statistically significant difference. Similar results were reported by Kommos *et al.*, 2018 [18].

Conclusion

Our study documented that L1CAM expression was significantly correlated with non-endometrioid histology, high FIGO grade, high FIGO stage, high (T) stage, cervical involvement, LVSI, and high-risk tumor according to modified ESMO system.

These findings were consistent with most of reported studies making L1CAM a possible useful biomarker in identification of endometrial cancers with aggressive behavior for better risk classification, identification of patients needing closer follow-up, and management direction. In addition, its potential role as a therapeutic target for high-risk endometrial cancer seems promising.

Furthermore, significant correlation between L1CAM expression and positive nodal metastasis suggests the possible role of this marker as a predictor of lymph node metastasis helping to improve selection of patients requiring lymphadenectomy.

Further studies with larger samples, comparing L1CAM expression in pre-operative and post-operative biopsies, correlation of L1CAM expression with the molecular classification of Tumor Cancer Genome Atlas, and long-term follow-up are required to establish the prognostic significance of L1CAM expression in endometrial carcinoma, particularly occurrence of recurrence and survival. Prospective trials are needed to evaluate the clinical significance of L1CAM for risk assessment and to guide potential alterations of surgical and adjuvant treatment strategies.

References

- Siegel RL, Miller KD, Jemal A. Cancer statistics, 2019. *CA Cancer J Clin.* 2019;69(1):7-34. PMID:30620402
- Helal EA, Salman MI, Ezz-Elarab SS, editors. Malignant tumors of the body of uterus. In: Pathology Based Cancer Registry 2002-2010. Cairo, Egypt: Ain-Shams Faculty of Medicine; 2015. p. 54-6.
- Mokhtar N, Salama A, Badawy O, Khorshed E, Mohamed G, Ibrahim M, *et al.*, editors. Malignant tumors of female genital system. In: Pathology Cancer Registry 2000-2011. Cairo, Egypt: National Cancer Institute; 2016. p. 85-99.
- Morice P, Leary A, Creutzberg C, Abu-Rustum N, Darai E. Endometrial cancer. *Lancet.* 2016;387(10023):1094-108. [https://doi.org/10.1016/s0140-6736\(15\)00130-0](https://doi.org/10.1016/s0140-6736(15)00130-0)
- Sanderson PA, Moulla A, Fegan KS. Endometrial cancer-an update. *Obstet Gynaecol Reprod Med.* 2019;29(8):225-32. <https://doi.org/10.1016/j.ogrm.2019.05.001>
- Murali R, Soslow RA, Weigelt B. Classification of endometrial carcinoma: More than two types. *Lancet Oncol.* 2014;15(7):e268-78. [https://doi.org/10.1016/s1470-2045\(13\)70591-6](https://doi.org/10.1016/s1470-2045(13)70591-6)
- Kommos F, Kommos F, Grevenkamp F, Bunz AK, Taran FA, Fend F, *et al.* L1CAM: Amending the "low-risk" category in endometrial carcinoma. *J Cancer Res Clin Oncol.* 2017;143(2):255-62. <https://doi.org/10.1007/s00432-016-2276-3> PMID:27695947
- Van Gool IC, Stelloo E, Nout RA, Nijman HW, Edmondson RJ, Church DN, *et al.* Prognostic significance of L1CAM expression and its association with mutant p53 expression in high-risk endometrial cancer. *Modern Pathol.* 2016;29(2):174-81. <https://doi.org/10.1038/modpathol.2015.147> PMID:26743472
- Dellinger TH, Smith DD, Ouyang C, Warden CD, Williams JC, Han ES. L1CAM is an independent predictor of poor survival in endometrial cancer-an analysis of the cancer genome atlas (TCGA). *Gynecol Oncol.* 2016;141(2):336-40. <https://doi.org/10.1016/j.ygyno.2016.02.003> PMID:26861585
- Zaino R, Carinelli SG, Ellenson LH. Tumors of the uterine corpus. In: Kurman RJ, Carcagiu ML, Herrington CS, Young RH, editors. WHO Classification of Tumours of Female Reproductive Organs. Lyon, France: World Health Organization; 2014. p. 121-54.
- Zhou Q, Singh SR, Yunzhe L, Mo Z, Huang J. Preoperative histopathological grading and clinical staging versus surgicopathological grading and surgical staging in endometrial carcinoma patients: A single centre retrospective study. *Glob J Med Res.* 2018;18:18-28.
- FIGO Committee on Gynecologic Oncology. FIGO staging for carcinoma of the vulva, cervix, and corpus uteri. *Int J Gynecol Obstet.* 2014;125(2):97-8. <https://doi.org/10.1016/j.ijgo.2014.02.003> PMID:24630859
- Powell MA, Olawaiye AB, Bermudez A. Corpus uteri-carcinoma and carcinosarcoma. In: Amin MB, Edge SB, Greene FL, editors. *AJCC Cancer Staging Manual.* 8th ed. New York: Springer; 2017. p. 639-57.
- Colombo N, Creutzberg C, Amant F, Bosse T, González-Martín A, Ledermann J, *et al.* ESMO-ESGO-ESTRO consensus conference on endometrial cancer: Diagnosis, treatment and follow-up. *Int J Gynecol Cancer.* 2016;26(1):2-30. <https://doi.org/10.1097/igc.0000000000000609> PMID:26645990
- Klat J, Mladenka A, Dvorackova J, Bajsova S, Simetka O. L1CAM as a negative prognostic factor in endometrioid endometrial adenocarcinoma FIGO stage IA-IB. *Anticancer Res.* 2019;39(1):421-4. <https://doi.org/10.21873/anticancer.13128> PMID:30591489
- Corrado G, Laquintana V, Loria R, Carosi M, De Salvo L, Sperduti I, *et al.* Endometrial cancer prognosis correlates with the expression of L1CAM and miR34a biomarkers. *J Exp Clin Cancer Res.* 2018;37(1):139. <https://doi.org/10.1186/s13046-018-0816-1> PMID:29980240
- van der Putten LJ, Visser NC, Van de Vijver K, Santacana M, Bronsert P, Bulten J, *et al.* Added value of estrogen receptor, progesterone receptor, and L1 cell adhesion molecule expression to histology-based endometrial carcinoma recurrence prediction models: An ENITEC collaboration study. *Int J Gynecol Cancer.* 2018;28(3):514-23. <https://doi.org/10.1097/igc.0000000000001187> PMID:29324536
- Kommos FK, Karnezis AN, Kommos F, Talhouk A, Taran FA, Staebler A, *et al.* L1CAM further stratifies endometrial carcinoma patients with no specific molecular risk profile. *Br J Cancer.* 2018;119(4):480-6. <https://doi.org/10.1038/s41416-018-0187-6> PMID:30050154
- Pasanen A, Loukovaara M, Tuomi T, Bützow R. Preoperative

- risk stratification of endometrial carcinoma: L1CAM as a biomarker. *Int J Gynecol Cancer*. 2017;27(7):1318-24. <https://doi.org/10.1097/igc.0000000000001043>
PMid:29059097
20. van der Putten LJ, Visser NC, Van de Vijver K, Santacana M, Bronsert P, Bulten J, *et al*. L1CAM expression in endometrial carcinomas: An ENITEC collaboration study. *Br J Cancer*. 2016;115(6):716-24. <https://doi.org/10.1038/bjc.2016.235>
PMid:27505134
21. Geels YP, Pijnenborg JM, Gordon BB, Fogel M, Altevogt P, Masadah R, *et al*. L1CAM expression is related to non-endometrioid histology, and prognostic for poor outcome in endometrioid endometrial carcinoma. *Pathol Oncol Res*. 2016;22(4):863-8. <https://doi.org/10.1007/s12253-016-0047-8>
PMid:26891628
22. Bosse T, Nout RA, Stelloo E, Dreef E, Nijman HW, Jürgenliemk-Schulz IM, *et al*. L1 cell adhesion molecule is a strong predictor for distant recurrence and overall survival in early stage endometrial cancer: Pooled PORTEC trial results. *Eur J Cancer*. 2014;50(15):2602-10. <https://doi.org/10.1016/j.ejca.2014.07.014>
PMid:25126672
23. Tangen IL, Kopperud RK, Visser NC, Staff AC, Tingulstad S, Marcickiewicz J, *et al*. Expression of L1CAM in curettage or high L1CAM level in preoperative blood samples predicts lymph node metastases and poor outcome in endometrial cancer patients. *Br J Cancer*. 2017;117(6):840-7. <https://doi.org/10.1038/bjc.2017.235>
PMid:28751757
24. Visser NC, van der Putten LJ, van Egerschot A, Van de Vijver KK, Santacana M, Bronsert P, *et al*. Addition of IMP3 to L1CAM for discrimination between low-and high-grade endometrial carcinomas: A European network for individualised treatment of endometrial cancer collaboration study. *Hum Pathol*. 2019;89:90-8. <https://doi.org/10.1016/j.humpath.2019.04.014>
PMid:31054899
25. Weinberger V, Bednarikova M, Hausnerova J, Ovesna P, Vinklerova P, Minar L, *et al*. A novel approach to preoperative risk stratification in endometrial cancer: The added value of immunohistochemical markers. *Front Oncol*. 2019;9:265. <https://doi.org/10.3389/fonc.2019.00265>
PMid:31032226