

Scientific Foundation SPIROSKI, Skopje, Republic of Macedonia  
 Open Access Macedonian Journal of Medical Sciences. 2020 Feb 25; 8(B):62-65.  
<https://doi.org/10.3889/oamjms.2020.3272>  
 eISSN: 1857-9655  
 Category: B - Clinical Sciences  
 Section: Neurology



# Optic Nerve Sheath Diameter Cutoff Point for Detection of Increased Intracranial Pressure in the Emergency Department

Wanatchaporn Ussahgij<sup>1</sup>, Wipada Toonpirom<sup>1</sup>, Waranon Munkong<sup>2</sup>, Kamonwon Ienghong<sup>1</sup>, Wutchara Rattanaseeha<sup>1</sup>, Korakot Apiratwarakul<sup>1\*</sup>

<sup>1</sup>Department of Emergency Medicine, Faculty of Medicine, Khon Kaen University, Khon Kaen, Thailand; <sup>2</sup>Department of Radiology, Faculty of Medicine, Khon Kaen University, Khon Kaen, Thailand

## Abstract

**Edited by:** Sasho Stoleski  
**Citation:** Ussahgij W, Toonpirom W, Munkong W, Ienghong K, Rattanaseeha W, Apiratwarakul K. Optic Nerve Sheath Diameter Cutoff Point for Detection of Increased Intracranial Pressure in the Emergency Department. Open Access Maced J Med Sci. 2020 Feb 25; 8(B):62-65.  
<https://doi.org/10.3889/oamjms.2020.3272>  
**Keywords:** Optic nerve sheath diameter; Increased intracranial pressure; Ultrasound; Emergency department; Emergency medicine  
**\*Correspondence:** Korakot Apiratwarakul, Department of Emergency Medicine, Faculty of Medicine, Khon Kaen University, Khon Kaen, Thailand. E-mail: korakot@kku.ac.th  
**Received:** 23-Jun-2019  
**Revised:** 06-Feb-2020  
**Accepted:** 07-Feb-2020  
**Copyright:** © 2020 Wanatchaporn Ussahgij, Wipada Toonpirom, Waranon Munkong, Kamonwon Ienghong, Wutchara Rattanaseeha, Korakot Apiratwarakul  
**Funding:** Khon Kaen University, Faculty of Medicine (IN61113), Thailand  
**Competing Interests:** The authors have declared that no competing interests exist  
**Open Access:** This is an open-access article distributed under the terms of the Creative Commons Attribution-NonCommercial 4.0 International License (CC BY-NC 4.0)

**BACKGROUND:** Ultrasound of the optic nerve sheath diameter (ONSD) is one of the most widely used noninvasive methods of screening for high intracranial pressure.

**AIM:** This study aimed to measure the ONSD and to find the appropriate cutoff point to indicate increased intracranial pressure.

**METHODS:** We examined 93 participants over 18 years of age with abnormal neurologic signs or symptoms and took computerized tomography (CT) scans of their brains. We measured the ONSD through ultrasound with the head positioned at 30°. We also used a linear array probe to measure the ONSD in the position after connecting the eyeball 3 mm.

**RESULTS:** The average of the ONSD at each side was 4.76 mm (95% confidence interval [CI]: 4.65–4.87) in the normal CT scan group and 5.33 mm (95% CI: 5.13–5.33) in the abnormal CT scan (indicating high intracranial pressure) group. An ONSD cutoff point of 5.0 mm yielded 74.14% sensitivity and 49.22% specificity. The positive predictive value was 0.38 and negative predictive value was 0.82.

**CONCLUSION:** The ONSD in the abnormal CT scan group was greater than in the normal CT scan group, and an ONSD of 5.0 mm can be used as a cutoff point for detecting increased intracranial pressure.

## Introduction

Increased intracranial pressure in patients with head injury or other conditions resulting in reduced consciousness can worsen neurological symptoms and increase the risk of disability or death [1]. Detection of this condition must be quick and accurate to allow for adequate treatment. The gold standard is the measurement through complicated invasive procedures [2], [3], which can only be performed by specialized neurosurgeons and require special tools. The measurement of intracranial pressure using noninvasive technique is, therefore, a better choice for patients in the emergency department [4].

Greater optic nerve sheath diameter (ONSD) has been shown to correlate with higher intracranial pressure [5], [6]. Ultrasound of the ONSD is thus one of the most widely used noninvasive methods of screening for high intracranial pressure. This method is convenient, fast, and inexpensive, making it suitable for screening patients in the emergency room. There have been many studies conducted to measure

normal ONSD values in various populations. However, the cutoff points found to indicate a high intracranial pressure have varied from 3.19 to 6.30 mm.

This study aimed to determine normal ONSD in the Thai population and to find the appropriate cutoff point to indicate increased intracranial pressure.

## Methods

This was a prospective diagnostic study that included 93 participants over 18 years of age who visited the Srinagarind Hospital emergency room between April 2018 and November 2018 with abnormal neurologic signs or symptoms and who underwent computerized tomography (CT) scan of the brain. The exclusion criteria were a history of high intraocular pressure, eye injury, intracavernous sinus arachnoid cysts, and pregnancy. Ethical approval was provided by the Khon Kaen University Ethics Committee for Human Research (HE601188).

The sample size was calculated based on the prevalence of increased intracranial pressure reported in a study by Lee *et al.* [7]. To achieve a margin of error of 0.03, we determined that a sample size of 93 would be required. Statistical analysis was performed using SPSS for Windows version 16.0 (SPSS Inc., Chicago, IL, USA). Categorical data were presented as percentages, and continuous data were presented using mean and standard deviation. Univariate analysis was performed using a two-sample t-test for numerical data and a Chi-squared test or Fisher's exact test for data comparison between the two groups.

Each participant's ONSD was measured through the SonoSite M-Turbo ultrasound machine (1-year probe used) with the head positioned at 30°. We also used a linear array probe to measure the OSND in the position after connecting the eyeball 3 mm [8], [9]. These procedures were conducted by doctors in the department of emergency medicine who had been trained by an eye specialist to record the size of the optic nerve sheath through ultrasound [Figure 1]. The ONSD data were compared to brain CT results, which were interpreted by a specialist radiologist. Abnormal CT scan group was detecting abnormality on CT scan by specialist radiologist.

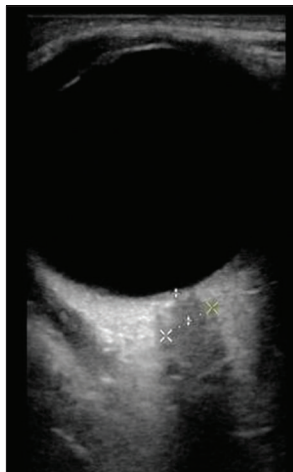


Figure 1: The position at which optic nerve sheath diameter was measured

**Results**

Ninety-three subjects were examined, the characteristics of whom are shown in Table 1. In the normal CT scan group, 51.56% (n = 33) of the patients were male. The mean age was 65 ± 14.59 years. Hypertension was the most common preexisting condition (32.55% and 13.95%) and motor weakness was the most common clinical presentation in both groups.

**Table 1: Characteristics of the subjects**

Characteristics	Normal CT scan (n=64), n (%)	Abnormal CT scan (n=29), n (%)
Sex: Male	33 (51.56)	18 (62.07)
Age±SD (years)	65±14.59	57±19.83
Preexisting condition		
Hypertension	35 (32.55)	15 (13.95)
Diabetes mellitus	20 (18.6)	8 (7.44)
Alcohol dependence	2 (1.86)	3 (2.9)
Chronic kidney disease stage 3–5	4 (3.72)	1 (0.93)
Clinical presentation		
Motor weakness	26 (24.18)	12 (11.16)
Alteration in mental status	9 (8.37)	7 (6.51)
Traumatic brain injury	11 (10.23)	1 (0.93)
Headache	6 (5.58)	4 (3.72)
Seizure	4 (3.72)	5 (4.65)
Dizziness	8 (7.44)	0 (0)

CT: Computerized tomography, SD: Standard deviation.

The average of the ONSD each side in the normal CT scan group was 4.76 mm (95% confidence interval [CI]: 4.65–4.87) and 5.33 mm (95% CI: 5.13–5.33) in the abnormal CT scan (indicating high intracranial pressure) group (p < 0.0001) (Table 2 and Figure 2).

**Table 2: ONSD in patients with normal and abnormal CT scans**

ONSD	Normal CT scan (mm)	Abnormal CT scan (mm)
Right side	4.74 (95% CI: 4.56–4.89)	5.23 (95% CI: 4.97–5.45)
Left side	4.79 (95% CI: 4.63–4.95)	5.43 (95% CI: 5.43–5.76)
Both sides	4.76 (95% CI: 4.65–4.87)	5.33 (95% CI: 5.13–5.33)
average		

CT: Computerized tomography, ONSD: Optic nerve sheath diameter, CI: Confidence interval.

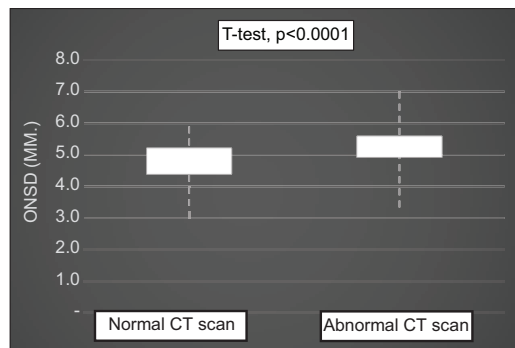


Figure 2: 25<sup>th</sup> and 75<sup>th</sup> percentile of optic nerve sheath diameter in patients with normal and abnormal computerized tomography scan

The ONSD of 5.0 mm, with 74.14 % sensitivity and 49.22% specificity, positive predictive value 0.38 and negative predictive value of 0.82 used for cut off point for detection of increased intracranial pressure [Figure 3].

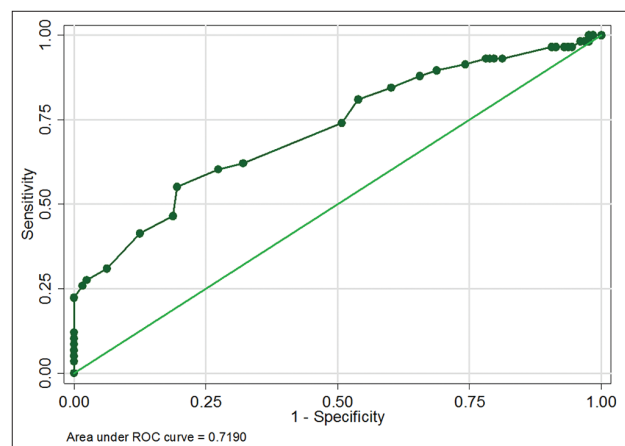


Figure 3: Sensitivity and specificity of optic nerve sheath diameter

## Discussion

This study aimed to measure ONSD, which has been anatomically and pathophysiologically proven to be associated with a higher intracranial pressure [5,6].

A previous study in a Thai population found the normal ONSD in those patients to be  $5.6 \pm 1.8$  mm at the posterior position of the eyeball and  $3.7 \pm 0.8$  mm at the center of the optic nerve in the eyeball [10]. The results of that study differed from those of ours due to the fact that the previous study measured ONSD directly with a CT scan, but the measurements in this study were attained using ultrasound, the position may be different from the position used.

A previous study of ONSD in a Chinese population found larger measurements than in this study ( $5.1 \pm 0.5$  mm) [9], but those found in studies in Bangladesh and Nepal were smaller (4.41 mm and 3.1–4.6 mm, respectively) [11], [12]. The cutoff number was different which depends on basic science knowledge about that the previous study was conducted in Asian patients, who tend to have higher ONSD cutoff point than those of Arabic patients.

In this study, an ONSD of 5.0 mm was used as a cutoff point to detect increased intracranial pressure in the emergency department using ultrasound, which is similar to those used in previous studies [13], [14], [15]. However, studies conducted in Korea and Turkey used cutoff points of 5.5 mm (sensitivity 98.77% and specificity 85.19%) [7] and 5.3 mm (sensitivity 70% and specificity 74%) [2], respectively. Ultrasound technique in emergent patients was limited due to the patient's condition and movement of head position, but we try to set head positioned at 30°. This study had some limitations. The accuracy of ultrasound ONSD measurements can depend on the inspector. Although the doctors in this study were trained and practiced in this technique, they were not experts in ocular ultrasonography.

## Conclusion

The ONSD in the abnormal CT scan group was larger than in the normal CT scan group, and an ONSD of 5.0 mm was used as a cutoff point to detect increased intracranial pressure.

## Acknowledgments

The present study received funding from the Khon Kaen University Faculty of Medicine (IN61113). The

authors would like to thank Kaewjai Thepsuthammarat for her data analysis and statistical review and Dylan Southard for acting as English consultant.

## References

- Haddad SH, Arabi YM. Critical care management of severe traumatic brain injury in adults. *Scand J Trauma Resusc Emerg Med.* 2012;20:12. <https://doi.org/10.1186/1757-7241-20-12> PMID:22304785
- Komut E, Kozacı N, Sönmez BM, Yılmaz F, Komut S, Yıldırım ZN, *et al.* Bedside sonographic measurement of optic nerve sheath diameter as a predictor of intracranial pressure in ED. *Am J Emerg Med.* 2016;34(6):963-7. <https://doi.org/10.1016/j.ajem.2016.02.012> PMID:26944107
- Czosnyka M, Pickard JD. Monitoring and interpretation of intracranial pressure. *J Neurol Neurosurg Psychiatry.* 2004;75(6):813-21. PMID:15145991
- Robba C, Bacigaluppi S, Cardim D, Donnelly J, Bertuccio A, Czosnyka M. Non-invasive assessment of intracranial pressure. *Acta Neurol Scand.* 2016;134(1):4-21. <https://doi.org/10.1111/ane.12527> PMID:26515159
- Shevlin C. Optic nerve sheath ultrasound for the bedside diagnosis of intracranial hypertension: Pitfalls and potential. *Crit Care Horiz.* 2015;1:22-30.
- Sahu S, Swain A. Optic nerve sheath diameter: A novel way to monitor the brain. *J Neuroanaesth Crit Care.* 2017;4:6. <https://doi.org/10.4103/jnacc-jnacc-73.16>
- Lee SU, Jeon JP, Lee H, Han JH, Seo M, Byoun HS, *et al.* Optic nerve sheath diameter threshold by ocular ultrasonography for detection of increased intracranial pressure in Korean adult patients with brain lesions. *Medicine (Baltimore).* 2016;95(41):e5061. <https://doi.org/10.1097/md.0000000000005061> PMID:27741121
- Blaivas M, Theodoro D, Sierzenski PR. Elevated intracranial pressure detected by bedside emergency ultrasonography of the optic nerve sheath. *Acad Emerg Med.* 2003;10:376-81. <https://doi.org/10.1197/aemj.10.4.376> PMID:12670853
- Chen H, Ding GS, Zhao YC, Yu RG, Zhou JX. Ultrasound measurement of optic nerve diameter and optic nerve sheath diameter in healthy Chinese adults. *BMC Neurol.* 2015;15:106. <https://doi.org/10.1186/s12883-015-0361-x> PMID:26148482
- Watcharakorn A, Ngamsirisuk S. Normal measurements of size of optic nerve sheath complex using computed tomography. *J Med Assoc Thai.* 2014;97(Suppl 8):S22-6. PMID:25518289
- Maude RR, Hossain MA, Hassan MU, Osbourne S, Sayeed KL, Karim MR, *et al.* Transorbital sonographic evaluation of normal optic nerve sheath diameter in healthy volunteers in Bangladesh. *PLoS One.* 2013;8(12):e81013. <https://doi.org/10.1371/journal.pone.0081013> PMID:24312515
- Shrestha G. Transorbital sonographic evaluation of normal optic nerve sheath diameter in healthy Nepalese adults. *J Neuroanaesth Crit Care.* 2016;3:115-8. <https://doi.org/10.4103/2348-0548.182343>

13. Tayal VS, Neulander M, Norton HJ, Foster T, Saunders T, Blaivas M. Emergency department sonographic measurement of optic nerve sheath diameter to detect findings of increased intracranial pressure in adult head injury patients. *Ann Emerg Med.* 2007;49(4):508-14. <https://doi.org/10.1016/j.annemergmed.2006.06.040> PMID:16997419
14. Goel RS, Goyal NK, Dharap SB, Kumar M, Gore MA. Utility of optic nerve ultrasonography in head injury. *Injury.* 2008;39(5):519-24. <https://doi.org/10.1016/j.injury.2007.09.029> PMID:18325519
15. Qayyum H, Ramlakhan S. Can ocular ultrasound predict intracranial hypertension? A pilot diagnostic accuracy evaluation in a UK emergency department. *Eur J Emerg Med.* 2013;20(2):91-7. <https://doi.org/10.1097/mej.0b013e32835105c8> PMID:22327166