

Reduction of liver abscesses in feedlot cattle by the addition of tannins on diet

CABRAL, C.¹, REDONDO, E.A.^{2,3}, DELGADO, F.^{2,4}

ABSTRACT

Liver abscess is a common disorder of feedlot cattle developed usually after ruminal acidosis. Despite of this condition is generally asymptomatic, it causes economic losses due to the reduction of feed efficiency. Routinely, antibiotics have been used as growth promoters, which can control ruminal acidosis. However, these have not direct effect on liver abscess and their use in the food chain has been under revision because of the concern about the development of antibiotic resistance. Thus, the need of alternatives increases. Tannins have been used for growth promotion in fattening of cattle, but they have not been evaluated for controlling liver disease. The aim of this study was to evaluate the effect of plant-based tannins on the prevalence of liver abscess in feedlot cattle. Two groups of Angus heifers were fattened under regular feedlot conditions; one received the regular feed (control group (CG), n=237 cows) with monensin (40 g/tn of Dry Matter (DM)) as growth promoter. Feed of the other group (tannin's group (TG), n=258 animals) was added with a commercial blend of tannins (2500 g/tn DM). Animals stayed in the feedlot until fattening was finished, and were sacrificed in the slaughterhouse. Presence of liver abscess was evaluated at the postmortem inspection. Additionally, one sample of the right lobe of healthy liver was collected for histopathologic examination of in approximately 20% of cows from both groups (69 from TG and 66 from CG). Macro and microscopic abscess development were compared by Fischer's Exact Test. A numeric score of microscopic changes was used and differences in microscopic liver affection between groups were evaluated with the Mann-Whitney test. Differences for all statistics were considered significant when $p < 0.05$. Three animals from TG and 14 from CG showed abscesses, being this difference significant ($p = 0.0051$). Microscopically, there was no difference since 35 animals from TG and 33 from CG showed microscopic abscess ($p = 1$). Finally, there were no differences in microscopic scores from both groups ($p = 0.7452$). The obtained results suggested that the tannin treatment is effective in controlling the development of liver abscess. However, presence of microscopic lesions in cows from TG suggested that the treatment regulated their progression but not the colonization of liver by the infectious agents. Nevertheless, the mechanisms involved are unknown and should be determined in further studies.

Keywords: feedlot cattle, liver abscess, tannins.

¹Silvateam, Indunor S. A. Cerrito 1136, C1010AAX, Buenos Aires, Argentina.

²Instituto Nacional de Tecnología Agropecuaria (INTA), Instituto de Patobiología. De los Reseros y Nicolás Repetto, 1686, Hurlingham, Buenos Aires, Argentina.

³Consejo Nacional de Investigaciones Científicas y Técnicas. Godoy Cruz 2290, C1425FQB, Ciudad de Buenos Aires, Argentina.

⁴Universidad del Salvador, Escuela de Veterinaria, Catedra de Patología Animal, Champagnat 1599, B1630AHU, Pilar, provincia de Buenos Aires, Argentina. Correo electrónico: delgado.fernando@inta.gob.ar

RESUMEN

El desarrollo de abscesos hepáticos es frecuente en bovinos en engorde intensivo como consecuencia de acidosis ruminal. Tal condición suele ser asintomática, pero genera pérdidas económicas. Ciertos antibióticos se utilizan frecuentemente como promotores del crecimiento, colaborando en el control de la acidosis. Sin embargo, su uso en producción animal es cuestionado debido al riesgo de generar resistencia en microorganismos, requiriéndose por lo tanto de productos alternativos. Además, estos no tienen efecto sobre los abscesos hepáticos. Los taninos son productos vegetales utilizados como promotores de crecimiento en engorde de bovinos y no han sido evaluados como herramienta para prevenir la aparición de abscesos. El objetivo del presente trabajo fue evaluar el efecto de taninos vegetales sobre el desarrollo de abscesos hepáticos en bovinos de feedlot. Dos grupos de vaquillonas cruza Angus fueron alimentadas con una dieta habitualmente empleada en engorde a corral; un grupo (grupo control (CG), $n=237$ animales) recibió monensina como promotor de crecimiento (40 g/t materia seca (MS)). El otro grupo (Grupo Taninos (TG), $n=258$ animales) recibió una mezcla comercial de taninos (2500 g/t MS). Una vez finalizada la terminación los animales fueron sacrificados en frigorífico, en donde se determinó la presencia de abscesos hepáticos. Una muestra del lóbulo derecho fue recolectada para estudio histopatológico en aproximadamente el 20% de los animales sin cambios macroscópicos de cada grupo (69 de TG y 66 de CG). La presencia de abscesos macro y microscópicos en ambos grupos fue comparada mediante el Test Exacto de Fischer. El grado de afección microscópica entre grupos fue evaluado mediante la prueba de Mann Whitney. Las diferencias fueron consideradas estadísticamente significativas cuando se obtuviera un valor de $p < 0,05$. Tres bovinos de TG y 14 de CG mostraron abscesos a la inspección macroscópica, esta diferencia fue significativa ($p=0,0051$). Microscópicamente no hubo diferencias ya que 35 animales de TG y 33 de CG mostraron lesiones ($p=1$). No se encontraron diferencias en la gravedad de las lesiones entre ambos grupos ($p=0,7452$). Los resultados obtenidos indicaron que el tratamiento con taninos fue efectivo en el control de abscesos hepáticos. La presencia de lesiones microscópicas en bovinos del TG sugirió que el tratamiento controla la progresión del cuadro, pero no la colonización del agente causal. Los mecanismos implicados permanecen desconocidos y deberán analizarse en futuros estudios.

Palabras clave: engorde a corral, absceso hepático, taninos.

INTRODUCTION

Liver abscess is a common disorder of feedlot cattle, usually related with ruminal acidosis. They are frequently caused by *Fusobacterium necrophorum*, but other agents can be involved. Frequently, microorganism accesses the liver via portal system vessels when the ruminal mucosa is damaged by the low pH caused by diets with high level of energy and low fiber. Usually asymptomatic, liver abscess causes economic losses due to the reduction of the productive performance, the affection of the carcasses' condition and the seizure of the viscera (Brink *et al.*, 1990; Nagaraja *et al.*, 1999; Tadepali *et al.*, 2009).

In order to control liver abscesses in feedlot systems, antibiotics have been used for long time (Matsushima *et al.*, 1954, Potter *et al.*, 1985). However, their use is under revision since their role in the selection of antibiotic resistant bacteria arose as a worldwide concern. Moreover, when used for metaphylaxis or as growth promoters they are applied in low doses for long period of time, ideal conditions for the development of antibiotic resistance (Redondo *et al.*, 2014). Because of it, alternatives for prevention of liver abscess in feedlot cattle should be tested.

Tannins extracted from several plants were successfully tested as alternatives for the antibiotics growth promoters

(AGP). Their addition on animal diet improves the productive performance of many species (Frutos *et al.*, 2004; Redondo *et al.*, 2014). Moreover, the effect of tannins was tested against some specific pathogenic agents (Akiyama *et al.*, 2001; Elizondo *et al.*, 2010). However, their ability for controlling liver abscess was not estimated. The aim of this study was to evaluate the effect of plant-based tannins on reducing the prevalence of liver abscess in animals fattened under feedlot conditions.

MATERIALS AND METHODS

Animals and facilities

A total of 495 Angus heifers were raised in regular feedlot facilities and fattened under intensive managing. Features of the diet supplied are resumed in Table 1. Animals were divided in 2 groups of 258 and 237 cows. In order to compare the effect of tannins over the presence of liver abscess, AGP were not used in the experimental group. Thus, ration of the first group (tannin group or TG) was added with 2500 g/tn of dry matter (DM) of a commercial blend of tannins (Silvafeed Bypro, Silvateam Argentina, Buenos Aires, Argentina), and the second group (Control group or CG) received the standard dose of monensin (Manufactured by an

Item	Tannin Group (TG)	Control Group (CG)
Animals under study	258	237
Dry matter (%)	70	70
Crude Protein (%)	13.7	13.7
Energy (Mcal/Kg DM)	2.96	2.96
Antibiotic Growth Promoting Monensin (Manufactured by an international pharmaceutical company for addition to cattle feed)	-----	40 mg/kg DM
Tannins Treatment (Silvafeed Bypro, Silvateam Argentina, Buenos Aires, Argentina)	0,25%	-----
Days in fattening (average)	90.09	92.88

Table 1. Description of experimental groups, diet and treatment applied.

international pharmaceutical company for addition to cattle feed) for feedlot fattening (40 g/tn DM) as growth promoter.

Animals from both groups stayed in the feedlot system 50 to 120 days and were sent to the abattoir when fattening was finished.

Pathologic study

Gross inspection was performed in the abattoir. Presence of abscesses was evaluated by inspection, palpation and the serial cut of the organ. It was considered abscess any focal structure composed by a semiliquid clear yellow-to-green mass of necrotic tissue surrounded by a capsule of connective tissue (figure 1).

Presence of microscopic changes in grossly healthy livers was evaluated in both groups. For that, one tissue sample of the right lobe was collected (2 cm³ in size approximately) from at least 20% of cows without abscesses from each group. Samples were immersed in 10% buffered formalin solution and then embedded in paraffin following the standard histological technique. Hematoxilin/ eosin staining was performed on liver slides (2 µm in size), according to routine procedures.

Corresponding score	Pathologic features of focus
1	Size: Less than one hepatic lobule necrotic. Exudate: scanty peripheral neutrophils
2	Size: Necrosis involved the full lobule Exudate: scanty or several neutrophils
3	Size: Necrosis involved more than one lobule Exudate: Numerous neutrophils surrounding and filling the focus

Table 2. Criteria for scoring the micro abscess detected. Final score was calculated by the sum of each foci detected in each animal.

Microscopic changes in livers were quantitatively scored. For this, all foci of hepatic necrosis filled and surrounded by neutrophils present in the slides were considered. One to 3 points were assigned to each focus, depending on its size (table 2). The final score was calculated by the sum of all micro abscesses detected in each slide.

Statistical analysis

The number of grossly and microscopically affected animals in each group was compared through the Fischer exact Test. Microscopic scores were evaluated by the non-parametrical Mann-Whitney test. Differences were considered statistically significant when the p-value was <0.05 (Confidence level: 95%).

RESULTS

Gross inspection

Results are resumed in table 3 and figure 1. Three animals from TG and 14 from CG presented abscesses. Prevalence for each group were 1.162% (3/258) and 5.9% (14/237) respectively. Differences between groups were statistically significant (p=0.0051). Most animals showed 1 focus (2 from TG and 8 from CG), being the maximum 3 foci/liver (1 from TG and 2 from CG).

Presence of abscess was detected in animals which stayed at least 80 days in the feedlot for both treatments. In TG, one cow showed abscess at day 80, and 2 at day 120. On the other hand, 7 animals had abscess at day 80, 2 at day 107 and 5 at day 120 in CG.

Histopathology

Samples of liver were collected in 69 and 66 animals from TG and CG, respectively. Thirty five animals from TG and 33 from CG showed micro abscesses, being their prevalence 50.72% and 50% respectively (table 4). Scores for

	Tannin Group	Control group
Abscess (Prevalence %)	3* (1.162%)	14 (5.9%)
No abscess	255	223
Total	258	237

Table 3. Gross inspection. Animals with liver abscess and healthy in each group.

*Difference statistically significant (Fischer exact test, $p=0.0051$)

	Tannins	Control	Total
Micro abscess	35 ^l	33	68
No changes	34	33	67
Total	69	66	135

Table 4. Microscopic inspection. Animals with micro abscesses and healthy in each group.

^lDifference not significant

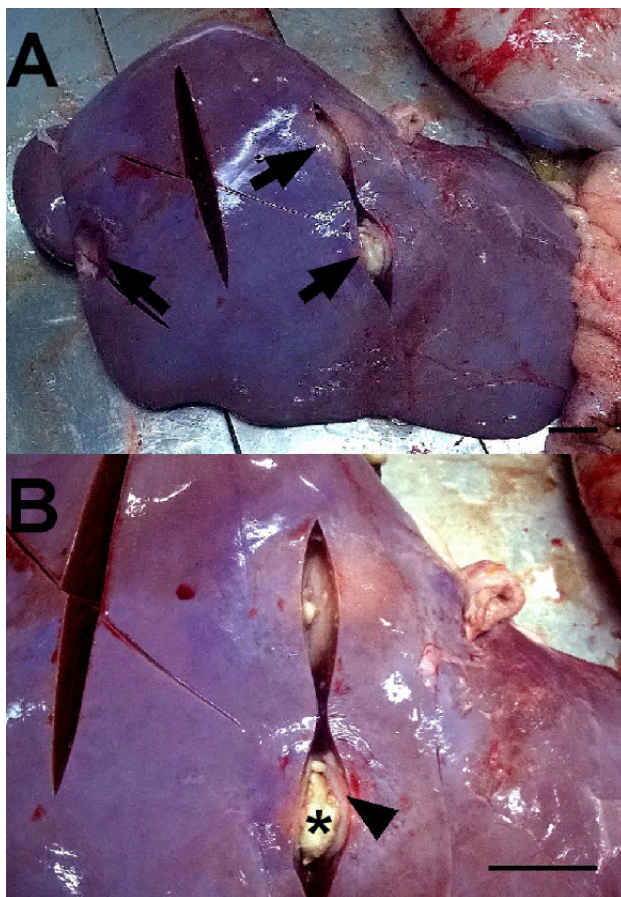


Figure 1. Cow from control group. Liver: Arrows shows 3 abscesses in the parenchyma (arrows). Bar: 5 cm. B: Magnification of A. Note the necrotic material (*) surrounded by a capsule of connective tissue. Bar: 5 cm.

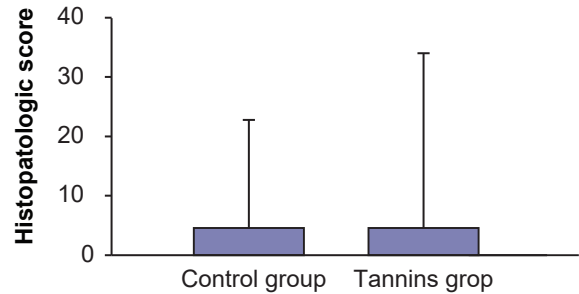


Figure 2. Scores of microscopic inspection of healthy liver of cows from both groups. Bars indicate arithmetic media with the standard drift. Circles and squares indicated the individual scores for each group.

microscopic changes are resumed in Figure 2. Maximum score was 30 for TG and 22 for CG. Differences between groups for both microscopic analysis were not significant ($p=1$ for microscopic changes development and $p=0.7452$ for histopathologic score).

DISCUSSION

Tannins used at low or moderate doses improve the performance of animal productive systems (Frutos *et al.*, 2004; Redondo *et al.*, 2014), but their effect on pathologic conditions has not been proved. In the present report we evaluated their usefulness for prevention of liver abscess in feedlot fattening cattle, and the obtained results indicated that the commercial blend of tannins administrated reduced their prevalence in comparison with a regular diet which included an antibiotic (monensin) for growth promoting.

The mechanisms by which tannins controlled liver abscess were not studied. The differences detected could be related with the proved antibacterial property of tannins (Akiyama *et al.*, 2001), which could control some specific pathogens in rumen. The antibacterial effect of certain tannins has been proved against some microorganisms, but not for controlling *F. necrophorum*, the most important agent related with liver abscess. However, growth of *Staphylococcus aureus* (another causative agent of liver abscess) is reduced by tannins and the effect of these compounds on other anaerobe microorganism such as *Clostridium perfringens* was proved *in vitro* (Akiyama *et al.*, 2001, Elizondo *et al.*, 2010). Thus, it could be possible that the growth of the etiologic agent (whatever it was) was limited in the ruminal lumen and this reduced the risk of liver abscess in the TG.

Other explanation for differences could be related with the development of ruminal acidosis. Animals from TG could control this condition while those from the CG might develop it, and thus the liver affection would be predisposed. Unfortunately ruminal pH and ruminal integrity could not be evaluated, but the presence of microscopic abscess in liver of animals from both groups indicated that microbial infection occurred. This suggested that affection of rumen would not be different between both groups.

Reduced prevalence of gross changes in cows from TG (which had micro abscesses) suggested that cows from this group controlled the disease more efficiently after the infection occurred. Although it would be rare that tannins acted against microorganism in the liver since their absorption is scanty or null, it cannot be discarded that an unknown metabolite of tannins with antibacterial effect was capable to access the liver. Other explanation would be related with an enhanced performance of immune response associated to the better absorption of amino acids in gut, caused by the protein protection by tannins in the rumen (Frutos *et al.*, 2004). Considering the effects of tannins over the ruminal microbiota and the immune system, control of liver abscess probably became from a synergistic effect. Thus, the etiologic agent might be partially controlled in the ruminal environment and the immune system might control more efficiently the infection in the TG group. However, further studies should be performed in order to determine the mechanisms by which tannins reduce the prevalence of liver abscesses in feedlot cattle.

Prevalence of liver abscesses in Argentina, where feedlot activity has increased considerably in the last decades, has not been deeply studied. An old report indicated that 4.4% of feedlot cattle were affected. In contrast, between 12 to 32% of feedlot cattle showed the disease in the United States (Brink *et al.*, 1990; Nagaraja and Chengappa, 1998; Giuliadori *et al.*, 2000; Nagaraja and Lechtenberg, 2007). In the present report, the prevalence obtained for the control group was slightly higher than the previously described for feedlots in Argentina. However, this was remarkably lower than the one reported for United States (Giuliadori *et al.*, 2000; Nagaraja *et al.*, 2007). This fact could be explained by the differences in the raising systems, but more probably by the time that the animals tested in the present study spent on fattening. It was reported that time in fattening is a risk factor for the presence of liver abscesses (Amachawadi and Nagaraja, 2016), and the obtained results in this work support this. Thus, it should be interesting to test the performance of tannins for prevention of liver abscesses in prolonged periods of time.

Tannins have been successfully tested for replacing of antibiotics growth promoters in cattle and other species bred under intensive conditions. The present report describes the reduction of prevalence of liver abscesses associated with their use as an additional effect. Although the mechanisms of action for this property were not explained and further studies should be performed, this non-reported effect of tannins would help for the rational use of antibiotics, and to improve the economic gains of feedlot farms.

ACKNOWLEDGEMENTS

The authors thank Claudia Moreno and Daniel Funes for the histological support and Dr Sol Pérez Aguir-

reburualde and Gimena Rodriguez for the manuscript review.

REFERENCES

- AKIYAMA, H.; FUJII, K.; YAMASAKI, O.; OONO, T.; IWATSUKI, K. 2001. Antibacterial action of several tannins against *Staphylococcus aureus*. J Antimicrob Chemother, 48:487-491.
- AMACHAWADI, R.G.; NAGARAJA, T.G. 2016. Liver abscesses in cattle: A review of incidence in Holsteins and of bacteriology and vaccine approaches to control in feedlot cattle. J. Anim. Sci. 94:1620-1632. doi: 10.2527/jas.2015-0261
- BRINK, D.R.; LOWRY, S.R.; STOCK, R.A.; PARROT, J.C. 1990. Severity of Liver Abscesses and Efficiency of Feed Utilization of Feedlot cattle. J. Anim. Sci. 68:1201-1207
- ELIZONDO, A.M.; MERCADO, E.C.; RABINOVITZ, B.C.; FERNANDEZ-MIYAKAWA M.E. 2010. Effect of tannins on the in vitro growth of *Clostridium perfringens*. Vet Microbiol 145:308-314. doi: 10.1016/j.vetmic.2010.04.003
- FRUTOS, P.; HERVÁS, G.; GIRÁLDEZ, F.J.; MANTECÓN, A.R. 2004. Review. Tannins and ruminant nutrition. Span J Agric Res, 2: 191-202.
- GIULIODORI, M.J.; LASTA, G.; COSTA, E.F.; CORVA, S.G.; BALDO, A. 2000. Liver Abscess Prevalence in Feedlot Cattle from Argentina. Analecta Veterinaria, 20: 29-31.
- MATSUSHIMA, J.; DOWE, T.W.; ADAMS, C.H. 1954. Effect of aureomycin in preventing liver abscess in cattle. Proc Soc Exp Biol Med; 85:18-20.
- NAGARAJA, T.G.; BEHARKA, A.B.; CHENGAPPA, M.M.; CARROLL, L.H.; RAUN, A.P.; LAUDERT, S.B.; PARROTT, J.C. 1999. Bacterial flora of liver abscesses in feedlot cattle fed tylosin or no tylosin. J Anim Sci. 77: 973-978.
- NAGARAJA, T.G.; CHENGAPPA, M.M. 1998. Liver abscesses in feedlot cattle: a review. J Anim Sci. 76: 287-298.
- NAGARAJA, T.G.; LECHTENBERG, K.F. 2007. Liver Abscesses in Feedlot Cattle. Vet Clin Food Anim 23: 351-369.
- POTTER, E.L.; WRAY, M.; MULLER, R.D.; GRUETER, H.P.; MC ASKILL, J.; YOUNG, D. 1985. Effect of monensin and tylosin average daily gain, feed efficiency and liver abscess incidence in feedlot cattle. J Anim Sci, 61: 1058-1065.
- REDONDO, L.M.; CHACANA, P.A.; DOMINGUEZ, J.E.; FERNANDEZ MIYAKAWA, M.E. 2014. Perspectives in the use of tannins as alternative to antimicrobial growth promoter factors in poultry. Front Microbiol. 27; 5:118. doi: 10.3389/fmicb.2014.00118
- TADEPALLI, S.; NARAYANAN, S.K.; STEWART, G.C.; CHENGAPPA, M.M.; NAGARAJA, T.G. 2009. *Fusobacterium necrophorum*: A ruminal bacterium that invades liver to cause abscesses in cattle. Anaerobe 15: 36-43. doi: 10.1016/j.anaerobe.2008.05.005.