

A Síndrome de CANDLE

Katarína Kieselová¹, Felicidade Santiago², Martinha Henrique³ 

¹Interna de Dermatologia e Venereologia/Resident of Dermatology and Venereology, Centro Hospitalar de Leiria, Leiria, Portugal

²Assistente Hospitalar de Dermatologia e Venereologia/Consultant of Dermatology and Venereology, Centro Hospitalar de Leiria, Leiria, Portugal

³Chefe de Serviço de Dermatologia, Centro Hospitalar de Leiria, Leiria, Portugal

RESUMO – A síndrome de CANDLE, *chronic atypical neutrophilic dermatosis with lipodystrophy and elevated temperature*, é uma doença auto-inflamatória crónica, fisiopatologicamente condicionada pela disfunção intracelular do proteasoma/imunoproteasoma.

Esta revisão descreve o reconhecimento da síndrome de CANDLE, os desenvolvimentos na compreensão do seu mecanismo patológico, os antecedentes genéticos e as estratégias terapêuticas emergentes para esta condição.

PALAVRAS-CHAVE – Complexo de Endopeptidases do Proteasoma/genética; Doenças Hereditárias Autoinflamatórias; Doenças da Pele/genética; Lipodistrofia; Síndrome.

Insights into CANDLE Syndrome

ABSTRACT – *Chronic atypical neutrophilic dermatosis with lipodystrophy and elevated temperature (CANDLE) syndrome is a recently described chronic autoinflammatory disease, pathophysiologically related to intracellular proteasome/immunoproteasome dysfunction. This review chronicles the recognition of CANDLE syndrome, the developments in the understanding of the pathomechanism, genetic background, and the emerging therapeutic strategies of this condition.*

KEYWORDS – *Hereditary Autoinflammatory Diseases; Lipodystrophy; Proteasome Endopeptidase Complex/genetics; Skin Diseases/genetics; Syndrome.*

INTRODUCTION

In 2010, António Torrelo and colleagues published a paper, thoroughly describing four patients with an early onset of recurrent fevers, annular violaceous skin lesions composed of infiltrates of atypical mononuclear cells and mature neutrophils, lipodystrophy and multisystemic inflammatory manifestations. These distinct clinical features led to an acronym for CANDLE syndrome (chronic atypical neutrophilic dermatosis with lipodystrophy and elevated temperature).¹ Subsequent studies provided evidence for the genetic nature of the syndrome, identifying a mutation in the genes encoding for a human immunoproteasome, and included this condition into a group of proteasome associated autoinflammatory syndromes (PRAAS).²

To this date, 20 patients with CANDLE syndrome have

been described in the literature. Apparently, the syndrome is not restricted to any ethnic group, with reported cases from Caucasian, Jewish, Spanish and Hispanic population.

Apart from CANDLE syndrome, PRAAS include three more entities: Japanese autoinflammatory syndrome with lipodystrophy (JASL); Nakajo-Nishimura syndrome (NNS); Joint contractures, muscular atrophy, microcytic anemia, panniculitis-associated lipodystrophy (JMP) syndrome. All these syndromes share similar clinical features and genetic background, most probably representing one disease spectrum.³

In the current review, we discuss the clinical and laboratory features of the published cases of CANDLE syndrome, the latest clinical research in its pathophysiology and the promising new treatment strategies.

Correspondência: Katarína Kieselová

Department of Dermatology
Centro Hospitalar de Leiria – CHL
Rua das Olhalvas
2410-197, Leiria, Portugal

E-mail: katarinakieselova@gmail.com

DOI: <https://dx.doi.org/10.29021/spdv.78.1.1132>

Recebido/Received
2020/10/23

Aceite/Accepted
2020/01/25

Publicado/Published
2020/04/--

© Autor (es) (ou seu (s) empregador (es)) 2019. Reutilização permitida de acordo com CC BY-NC. Nenhuma reutilização comercial.

© Author(s) (or their employer(s)) 2019. Re-use permitted under CC BY-NC. No commercial re-use.

Educação Médica Contínua

GENETIC BACKGROUND AND PATHOPHYSIOLOGY

With the recognition of CANDLE syndrome, abnormal inflammatory response was postulated, later attributed to proteasome-immunoproteasome dysfunction.^{1,2} The first identified mutations linked to CANDLE syndrome were limited to proteasome subunit β type 8 gene (*PSMB8*), which encodes the inducible $\beta 5i$ subunit of the proteasome. Most of patients reported, presented with homozygous or compound heterozygous mutation in *PSMB8*. However, one patient did not show a mutation in *PSMB8* gene, suggesting that other genes may be involved in the aetiology of CANDLE syndrome.² More recently, Brehm A *et al*, analysed eight patients with a clinical phenotype of CANDLE syndrome and recognized 8 different mutations in further 4 genes that encode other proteasome subunits: proteasome subunit alpha-type 3 (*PSMB3*); proteasome subunit beta-type 4 (*PSMB4*); proteasome subunit beta-type 9 (*PSMB9*); and proteasome maturation protein (*POMP*).⁴ Proteasome gene mutation variably affects transcription, protein expression, protein folding, proteasome assembly and proteasome activity.⁴ These findings further confirmed considerable genetic heterogeneity underlying CANDLE syndrome, with recessive inheritance pattern in one proteasome subunit (monogenic, homozygous or compound heterozygous) or two different subunits digenic, or, rarely, in an autosomal dominant fashion.^{4,5}

Proteasomes are large protease complexes located in cytoplasm, endoplasmic reticulum and nucleus, consisting of two components: the 19S regulatory particle and the 20S core particle. The eukaryotic proteasome degrades the majority of damaged or waste proteins in the cell under normal conditions. Most substrates designated to degradation are first flagged by ubiquitin conjugation system, which then directs them to the proteasome.

Immunoproteasomes are special isoform of proteasomes, induced in most cells by oxidative stress and proinflammatory cytokines, mainly by type I interferons (IFNs). The type I IFNs bind to IFN- α membrane receptors, triggering a signal in the JAK/STAT pathway. Immunoproteasome complexes serve as processors of antigen for presentation by major histocompatibility complex molecules and are involved in degradation of oxidised proteins in order to maintain cellular homeostasis. When the cell is exposed to certain triggers, such as viral infection, the production of IFNs increases, leading to increased immunoproteasome formation and pathogen-derived protein degradation.^{6,7}

In cells with a dysfunctional proteasome-immunoproteasome the catalytic activity is insufficient leading to intracellular accumulation of damaged proteins, particularly during cellular stress. These unprocessed proteins are further marked with more ubiquitin, increasing interferon signalling that leads to elevated production of proteasomes incapable of protein degradation, creating a vicious cycle of inflammation.^{5,7}

As a result, in CANDLE syndrome, proteasome defects lead to a continuous state of inflammation with exacerbations under situations of stress, when higher requirements of removing waste proteins are not met.⁵

CLINICAL PRESENTATION

CANDLE syndrome is an auto-inflammatory multisystem disease. The first symptoms begin in early childhood (often in the first weeks of life) with skin eruptions and recurrent episodes of fever, which may occur daily, even with no apparent trigger.

The most prominent skin manifestations, invariably present in all patients, are annular erythematous or violaceous plaques with an elevated border and a flat centre (Fig. 1), lasting for a few days or weeks and progressing to a residual purpuric macule. Whereas they are almost always present during childhood, they may be less conspicuous after puberty.^{2,5} Additionally, during early infancy CANDLE patients present with periorcular erythematous and/or perioral edema and pernio-like lesions on acral sites, which also tend to fade with increasing age.^{1,2,5}

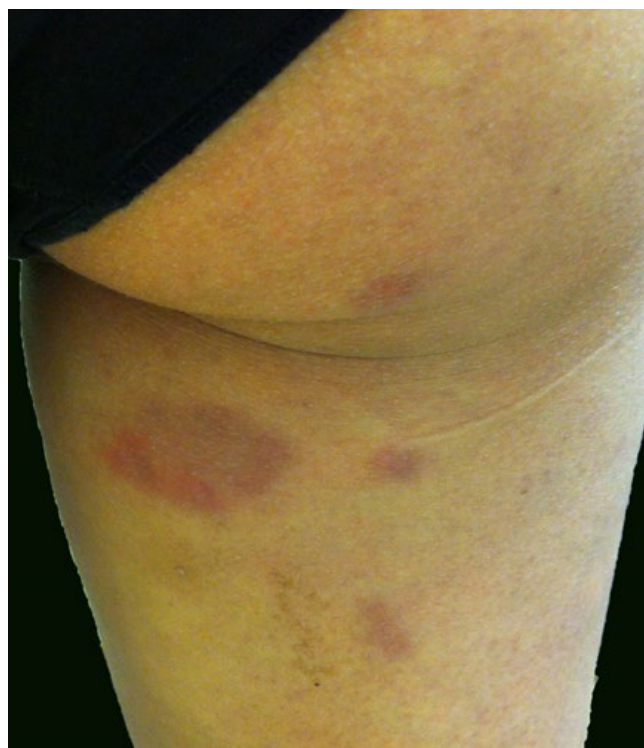

Figure 1 - Erythematous-violaceous plaques on the thighs in a patient with CANDLE syndrome (author's archive).

Lipodystrophy, a key manifestation of all PRAAS present in all published cases, starts in early childhood and has a progressive course. The loss of subcutaneous fat tissue is first noted on the face, with flattening or indentation of convex contours of the face, with subsequent involvement of trunk and upper limbs. The cause is not yet fully understood, but it has been suggested that downregulation of *PSMB8* with increased IFN signalling, together with chronic inflammation may play a role in its pathogenesis.^{5,8} Swollen eyelids with periorbital erythema together with facial lipodystrophy confer typical phenotype of CANDLE syndrome patients (Fig. 2).

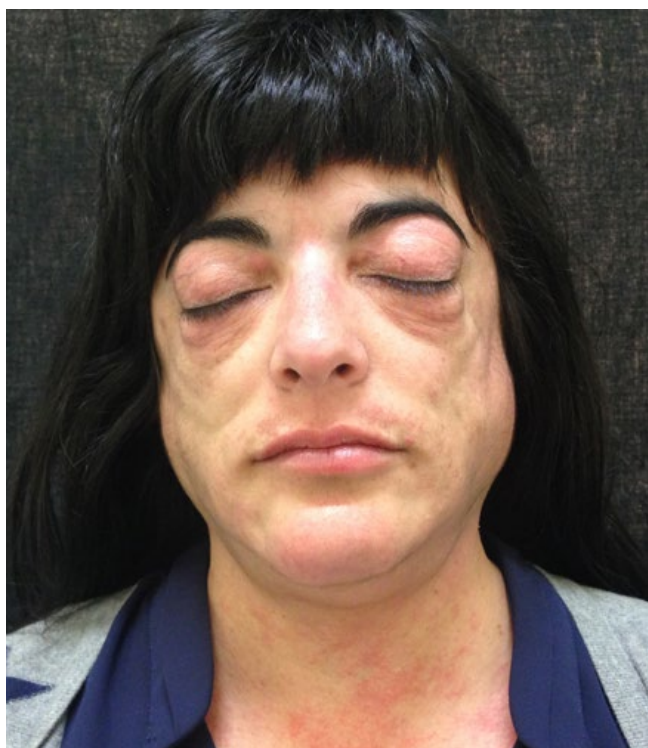


Figure 2 - Facial lipodystrophy, erythematous periorbital plaques, and parotid gland enlargement (author's archive).

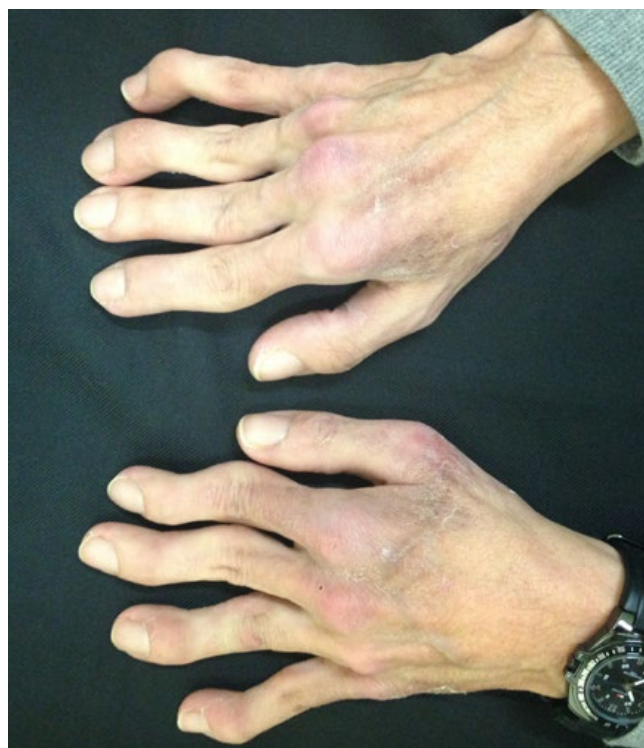

Figure 3 - Joint contractures and muscle atrophy on the hands (author's archive).

The abdominal fat tissue, on the contrary, tends to be increased, which leads to metabolic disturbances, such as acanthosis nigricans and hirsutism. Hepatosplenomegaly, described in about 65% of CANDLE syndrome patients, further contributes to a protuberant abdomen.^{2,5,9}

Some degree of arthralgia has been described in 80% cases. Patients experience pain that predominantly affects small joints of the hands and feet. Interestingly, most patients complain of joint pain without overt signs of arthritis. With disease progression patients develop joint contractures, which can lead to patients' limited mobility when associated with myositis and muscle wasting (Fig. 3).^{1,2,5,10}

Other typical features observed in two thirds of published cases include delayed physical development with growth retardation and failure to thrive. However, most patients with CANDLE do not show intellectual disability.⁵

With increasing number of published cases, several other clinical features were reported that may be variably linked to CANDLE syndrome: aseptic lymphocytic meningitis (15%), basal ganglia calcifications (20%), diabetes mellitus, ear and nose chondritis, otitis, episcleritis, conjunctivitis, lymphadenopathy, parotiditis, carditis, pneumonitis, nephritis, epididymitis.^{1,2,5,9-16}

As shown, virtually every organ may be affected with ongoing and longstanding inflammation. The clinical and laboratory features of published cases are summarized in Table 1.

The course of the disease is variable, including some cases with fatal outcome.^{2,16}

LABORATORY AND HISTOPATHOLOGIC FINDINGS

Abnormal laboratory values reflect the continuous chronic inflammation in patients with CANDLE syndrome. All affected individuals present with hypochromic anaemia and persistent elevation of acute phase reactants. In addition, elevation of liver transaminases and hypertriglyceridemia are present in 65% and 45% of cases, respectively. Transient thrombocytosis or thrombocytopenia, neutropenia, lymphopenia can be variably observed. Autoimmunity markers are usually negative, although antinuclear antibodies titres may be increased in some patients.^{1,2,5}

Skin biopsy is an essential diagnostic tool as the histological features of cutaneous lesions in CANDLE syndrome are very characteristic and may permit an early diagnosis. The histological hallmark of skin lesions is the presence of atypical or immature myeloid cells that may mimic leukaemia cutis. This infiltrate localized at the perivascular and interstitial dermis extends into the subcutis and is further composed of mononuclear cells, neutrophils and eosinophils and some mature lymphocytes.¹⁹ Immunohistochemistry stains show strong positivity for myeloperoxidase and chloroacetate esterase, confirming presence of myeloid cells, and positivity for CD68 and CD163 indicating the presence of histiocytes and macrophages (Fig. 4). Additionally, CD123 positive staining shows admixture of plasmacytoid dendritic cells.^{19,20}

Educação Médica Contínua

Table 1 - Demographics, clinical and genetic features of the patients with CANDLE syndrome published in the literature

	8y, M ^{1,2}	10y, F ^{1,2}	14y, F ^{1,2}	2y, F ^{1,2}	12,5y, M ¹⁰	5,5y M ²	3,5y, M ²	6y, F ²	2,5y, F ^{1,2}	22y, M ²	5M, F ¹⁶	24y M ¹⁵	12y, F ¹⁷	3y, M ¹²	36y, F ¹⁸	15y, F ¹³	2y, M ¹³	11y F ¹⁵	5y M ¹⁴	6y M ⁹	
Mutation	PSMB8	PSMB8	NA	PSMB8	PSMB8	No PSMB8, PSMB9, PSMB10	PSMB8	PSMB8	PSMB8	SMB8	PSMB8	No PSMB8	Not tested	PSMB8	PSMB8	No PSMB8	PSMB8	No PSMB8	PSMB8	PSMB8	
Age of presentation	1M	6M	During first 6M	1W	1M	2W	2M	2W	1M	Infancy	5M	4M	Infancy	11M	3M	3M	9D	4M	After birth	After birth	
Fever	+	+	+	+	+	+	+	+	+	+	+	+	+	+	+	+	+	+	+	+	+
Annular plaques	+	+	+	+	+	+	+	+	+	+	+	+	+	+	+	+	+	+	+	+	+
Eyelid violaceous swelling	+	+	+	+	+	+	+	+	+	+	ND	+	ND	+	+	+	+	+	+	+	+
Perioral swelling	+	+	ND	ND	+	ND	ND	ND	+	+	ND	ND	ND	ND	ND	ND	ND	ND	ND	ND	ND
Ear and nose chondritis	+	+	ND	ND	+	ND	ND	ND	+/-	ND	ND	ND	+	ND	ND	ND	ND	ND	ND	ND	ND
Low weight and height	+	+	+	+	+	+	ND	ND	ND	+	ND	+	ND	+	+	+	ND	ND	ND	+	+
Lipodystrophy	+	+	+	+	+	+	+	+	+	+	+	+	+	+	+	+	+	+	+	+	+
Alopecia areata	ND	ND	ND	ND	+	ND	ND	ND	ND	ND	ND	ND	ND	ND	ND	ND	ND	ND	ND	ND	ND
Prominent abdomen	+	+/-	+	+	+	+	ND	ND	+	ND	ND	+	ND	+	+	ND	ND	ND	ND	+	+
Hirsutism/Hypertrichosis	ND	ND	+	+	+	ND	+	+	ND	+	ND	ND	ND	ND	ND	ND	ND	ND	ND	ND	+
Lymphadenopathy	+	+	ND	+	ND	+	+	+	+	ND	ND	+	+	ND	ND	+	ND	ND	ND	+	ND
Hepatomegaly	+	+	+	+	+	+	+	ND	ND	ND	ND	+	+	+	ND	+	ND	ND	ND	+	+
Splenomegaly	+	ND	+	ND	ND	+	+	ND	ND	ND	ND	+	+	+	ND	+	ND	ND	ND	+	ND
Arthralgia/joint contracture	+	+	+	+	+	+	+	+	+	+	+	+	+	ND	+	+	ND	+	ND	ND	ND
Conjunctivitis/nodular episcleritis	+	+	ND	+	ND	ND	ND	ND	+	ND	ND	ND	ND	ND	ND	ND	ND	ND	ND	ND	ND
Epididymitis	+	ND	ND	ND	ND	ND	+	ND	ND	ND	ND	ND	ND	ND	ND	ND	ND	ND	ND	ND	ND
Aseptic meningitis	+	ND	+	ND	ND	ND	ND	ND	ND	ND	ND	ND	ND	ND	ND	ND	ND	ND	+	ND	ND
Parotitis	ND	ND	+	+	ND	ND	ND	ND	ND	ND	ND	ND	ND	ND	+	ND	ND	ND	ND	ND	ND
Interstitial lung disease	ND	ND	+	ND	ND	ND	ND	ND	ND	ND	ND	ND	ND	ND	ND	ND	ND	ND	ND	ND	ND
Nephritis	ND	ND	+	ND	ND	ND	ND	ND	ND	ND	ND	ND	ND	ND	ND	ND	ND	ND	ND	ND	ND
Otitis	ND	ND	+	+		+	+	ND	ND	ND	ND	ND	ND	ND	ND	ND	ND	ND	ND	ND	ND
Increased erythrocyte sedimentation rate and C-reactive protein	+	+	+	+	+	+	+	+	+	+	+	+	+	+	+	+	+	+	+	+	+
Anemia	+	+	+	+	+	+		+	+	+	+	+	+	+	+	+	+	+	+	+	+
Increased platelet count	+	ND	ND	+	ND	ND	ND	ND	ND	ND	ND	ND	+	+	ND	ND	ND	+	ND	ND	ND
Elevated alanine aminotransferase and aspartate aminotransferase	+	+	+	+	+	+	+	ND	+	ND	ND	+	+	+	ND	ND	+	ND	+	ND	ND
Increased triglyceride levels	ND	ND	+	+	ND	+	ND	+	ND	ND	ND	+	+	+	+	ND	ND	ND	+	ND	ND
Basal ganglia calcifications	+	ND	+	ND	ND	ND	ND	ND	ND	ND	+	ND	+	ND	ND	ND	ND	ND	ND	ND	ND

PSMB – Proteasome subunit beta type-8; ND – negative or not determined

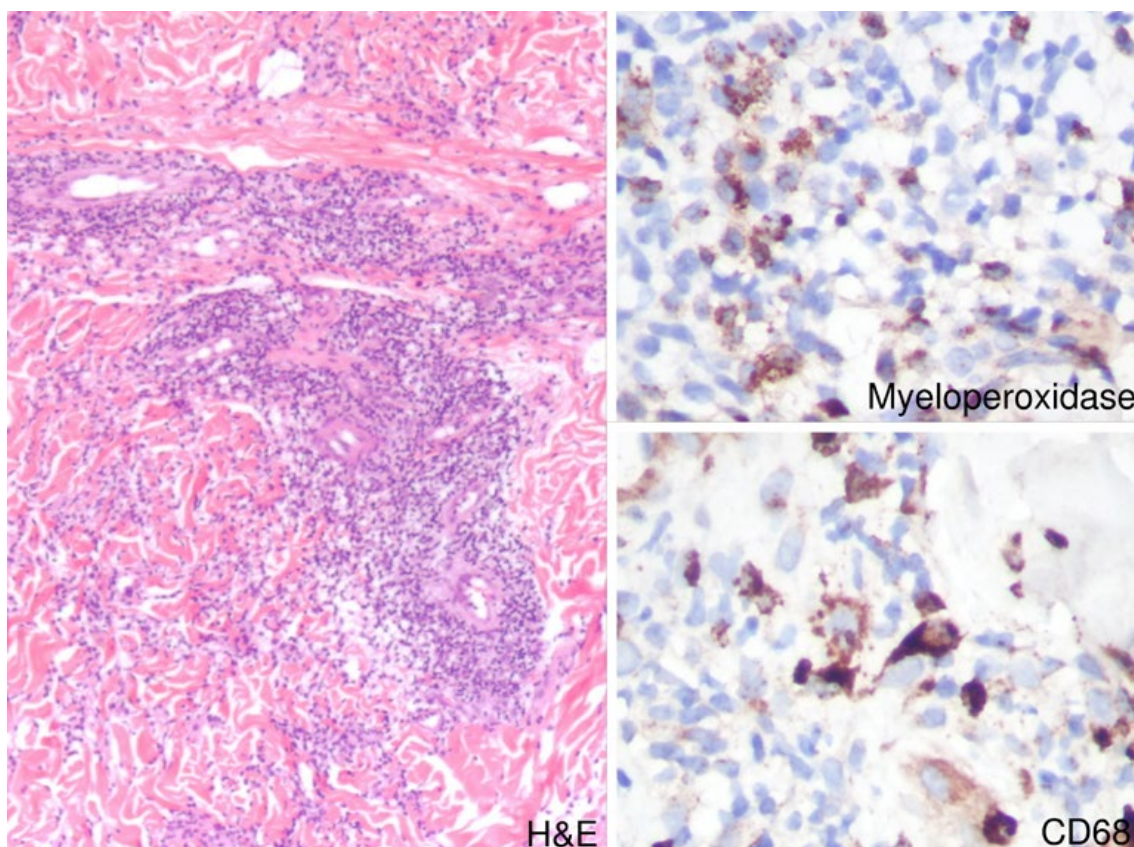


Figure 4 - Histological findings include perivascular and interstitial infiltrate composed of atypical myeloid cells, eosinophils, neutrophils and mature lymphocytes, with positive myeloperoxidase and CD68 staining.

DIFFERENTIAL DIAGNOSIS

Many of the clinical features seen in CANDLE syndrome resemble other inflammatory syndromes, such as chronic infantile, neurological, cutaneous and articular (CINCA) syndrome, cryopyrin-associated periodic syndromes (CAPS) in particular neonatal-onset multisystem inflammatory disease (NOMID) and other type 1 interferonopathies.^{21,22}

An important histologic differential diagnosis includes lymphoproliferation with cutaneous involvement as in acute myeloid leukaemia.¹⁹

TREATMENT

Patients with CANDLE syndrome respond partially to high doses of steroids, with reduction of febrile episodes, cutaneous lesions and arthralgia as well as partial or complete normalization of laboratory values. With tapering, however, rebound occurs.² Methotrexate can provide some improvement and can be considered the first line therapy.⁵

Corticoid-sparing agents, such as azathioprine and cyclosporine, together with non-steroidal anti-inflammatory drugs (NSAIDs), colchicine and dapsone, have not shown consistent efficacy. Some patients experienced temporary improvement with TNF- α inhibitors, in others exacerbation was triggered.^{2,5}

In addition, lipodystrophy has progressed in all patients despite immunosuppressive and cytokine targeted therapy.²

The identification of type I INF as the key-molecule in CANDLE syndrome, permits introduction of new and more specific therapies. Accordingly, it has been proposed that blockage of IFN receptor signalling through inhibition of the Janus kinases, JAK1/JAK2, may decrease interferon production and allow corticosteroid dose reduction. Baricitinib, a JAK inhibitor, has showed promising results and there is an ongoing trial for CANDLE (ClinicalTrials.gov: NCT01724580).²³⁻²⁵

CONCLUSION

Recent recognition of CANDLE syndrome followed by intense study of published cases, allowed to gain new insights into the genetics and the pathogenesis of this syndrome. However, the clinical course and range of organ involvement vary significantly between patients and the genotype-phenotype associations of CANDLE syndrome remain unknown. Recognizing the cutaneous features with characteristic histological findings may aid for prompt diagnosis and early treatment that is key for the quality of life and survival of the affected patients. Baricitinib represents a new promising therapy along with other targeted interventional strategies that may arise with the aim of facilitating clinical management.

Educação Médica Contínua

Apresentações

O trabalho incluído neste manuscrito foi apresentado sob forma de caso clínico na Reunião da Primavera de SPDV, 2016.

Presentations

Part of the manuscript was presented as a clinical case at the Spring Symposium of the Portuguese Society of Dermatology and Venereology, 2016.

Conflitos de interesse: Os autores declaram não possuir conflitos de interesse.

Suporte financeiro: O presente trabalho não foi suportado por nenhum subsídio ou bolsa.

Consentimento do doente: Consentimento do doente para publicação obtido.

Proveniência e revisão por pares: Não comissionado; revisão externa por pares.

Conflicts of interest: The authors have no conflicts of interest to declare.

Financing support: This work has not received any contribution, grant or scholarship.

Patient consent: Consent for publication was obtained

Provenance and peer review: Not commissioned; externally peer reviewed.

ORCID

Katarína Kieselová

<http://orcid.org/0000-0002-0064-7571>

Felicidade Santiago

<http://orcid.org/0000-0003-2402-4229>

Martinha Henrique

<http://orcid.org/0000-0001-7506-4971>

REFERENCES

1. Torrelo A, Patel S, Colmenero I, Gurbindo D, Lendínez F, Hernández A, et al. Chronic atypical neutrophilic dermatosis with lipodystrophy and elevated temperature (CANDLE) syndrome. *J Am Acad Dermatol.* 2010; 62: 489-95.
2. Liu Y, Ramot Y, Torrelo A, Paller AS, Si N, Babay S, et al. Mutations in proteasome subunit β type 8 cause chronic atypical neutrophilic dermatosis with lipodystrophy and elevated temperature with evidence of genetic and phenotypic heterogeneity. *Arthritis Rheum.* 2012; 64: 895-907. doi: 10.1002/art.33368.
3. McDermott A, Jacks J, Kessler M, Emanuel PD, Gao L. Proteasome-associated autoinflammatory syndromes: advances in pathogenesis, clinical presentations, diagnosis, and management. *Int J Dermatol.* 2015;54:121-9. doi: 10.1111/ijd.12695.
4. Brehm A, Liu Y, Sheikh A, Marrero B, Omoyinmi E, Zhou Q, et al. Additive loss-of-function proteasome subunit mutations in CANDLE/PRAAS patients promote type I IFN production. *J Clin Invest.* 2015;125:4196-211. doi: 10.1172/JCI81260.
5. Torrelo A. CANDLE syndrome as a paradigm of proteasome-related autoinflammation. *Front Immunol.* 2017; 9:8:927.
6. Ferrington DA, Gregerson DS. Immunoproteasomes: structure, function, and antigen presentation. *Prog Mol Biol Transl Sci.* 2012;109:75-112.
7. Xirotagaros G, Hernández-Ostiz S, Arostegui JI, Torrelo A. Newly described autoinflammatory diseases in pediatric dermatology. *Pediatr Dermatol.* 2016;33:602-14. doi: 10.1111/pde.12984.
8. Kitamura A, Maekawa Y, Uehara H, Izumi K, Kawachi I, Nishizawa M, et al. A mutation in the immunoproteasome subunit PSMB8 causes autoinflammation and lipodystrophy in humans. *J Clin Invest.* 2011;121:4150-60. doi: 10.1172/JCI58414.
9. Boyadzhiev M, Marinov L, Boyadzhiev V, Iotova V, Aksentijevich I, Hambleton S. Disease course and treatment effects of a JAK inhibitor in a patient with CANDLE syndrome. *Pediatr Rheumatol Online J.* 2019;17:19. doi: 10.1186/s12969-019-0322-9.
10. Ramot Y, Czarnowicki T, Maly A, Navon-Elkan P, Zlotogorski A. Chronic atypical neutrophilic dermatosis with lipodystrophy and elevated temperature syndrome: a case report. *Pediatr Dermatol.* 2011; 28: 538-41. doi: 10.1111/j.1525-1470.2010.01163.x.
11. Kluk J, Rustin M, Brogan PA, Omoyinmi E, Rowczenio DM, Willcocks LC, et al. Chronic atypical neutrophilic dermatosis with lipodystrophy and elevated temperature syndrome: a report of a novel mutation and review of the literature. *Br J Dermatol* 2014; 170: 215-7. doi: 10.1111/bjd.12600.
12. Cavalcante MP, Brunelli JB, Miranda CC, Novak GV, Malle L, Aikawa NE, et al. CANDLE syndrome: chronic atypical neutrophilic dermatosis with lipodystrophy and elevated temperature—a rare case with a novel mutation. *Eur J Pediatr.* 2016;175:735-40. doi: 10.1007/s00431-015-2668-4.
13. Al-Mayouf SM, AlSaleem A, AlMutairi N, AlSonbul A, Alzaid T, Alazami AM, et al. Monogenic interferonopathies: Phenotypic and genotypic findings of CANDLE syndrome and its overlap with C1q deficient SLE. *Int J Rheum Dis.* 2018;21:208-13. doi: 10.1111/1756-185X.13228.
14. Yamazaki-Nakashimada MA, Santos-Chávez EE, de Jesus AA, Rivas-Larrauri F, Guzmán-Martínez MN, Goldbach-Mansky R, et al. Systemic Autoimmunity in a Patient With CANDLE Syndrome. *J Investig Allergol Clin Immunol.* 2019;29:75-6. doi: 10.18176/jiaci.0338.
15. Tüfekçi Ö, Bengoç Ş, Karapınar TH, Ataseven EB, İrken G, Ören H. CANDLE syndrome: a recently described autoinflammatory syndrome. *J Pediatr Hematol Oncol.* 2015;37:296-9. doi: 10.1097/MPH.0000000000000212.
16. Wang H, Das L, Tan Hung Tiong J, Vasanwala RF,

- Arkachaisri T. CANDLE syndrome: an extended clinical spectrum. *Rheumatology*. 2014;53:2119-20. doi: 10.1093/rheumatology/keu298.
17. Roberts T, Stephen L, Scott C, di Pasquale T, Naser-Eldin A, Chetty M, Shaik S, Lewandowski L, Beighton P. CANDLE syndrome: orofacial manifestations and dental implications. *Head Face Med*. 2015;11:38.
 18. Kieselova K, Santiago F, Guiote V, Amado C, Henrique M. Fever, lipodystrophy and cutaneous lesions. *Clin Exp Dermatol*. 2017;42:939-41. doi: 10.1111/ced.13215.
 19. Torrelo A, Colmenero I, Requena L, Paller AS, Ramot Y, Richard Lee CC, et al. Histologic and immunohistochemical features of the skin lesions in CANDLE syndrome. *Am J Dermatopathol*. 2015;37:517-22. doi: 10.1097/DAD.0000000000000340.
 20. Shwin KW, Lee CR, Goldbach-Mansky R. Dermatologic manifestations of monogenic autoinflammatory diseases. *Dermatol Clin*. 2017; 35:21-38. doi: 10.1016/j.det.2016.07.005.
 21. Marzano AV, Damiani G, Genovese G, Gattorno M. A dermatologic perspective on autoinflammatory diseases. *Clin Exp Rheumatol*. 2018;36 :32-8.
 22. Eleftheriou D, Brogan PA. Genetic interferonopathies: An overview. *Best Pract Res Clin Rheumatol*. 2017;31:441-59. doi: 10.1016/j.berh.2017.12.002.
 23. Montealegre G, Reinhardt A, Brogan P, Berkun Y, Zlotogorski A, Brown D, et al. Preliminary response to Janus kinase inhibition with baricitinib in chronic atypical neutrophilic dermatosis with lipodystrophy and elevated temperatures (CANDLE). *Pediatr Rheumatol*. 2015;13(Suppl 1):O31. doi: 10.1186/1546-0096-13-S1-O31
 24. Sanchez GAM, Reinhardt A, Ramsey S, Wittkowski H, Hashkes PJ, Berkun Y, et al. JAK1/2 inhibition with baricitinib in the treatment of autoinflammatory interferonopathies. *J Clin Invest*. 2018;128:3041-52. doi: 10.1172/JCI98814.
 25. Jabbari A, Dai Z, Xing L, Cerise JE, Ramot Y, Berkun Y, et al. Reversal of alopecia areata following treatment with the JAK1/2 inhibitor baricitinib. *EBioMedicine*. 2015;2:351-5. doi: 10.1016/j.ebiom.2015.02.015.

Educação Médica Contínua

TEST YOURSELF

1. Which of these clinical features is the most consistent with CANDLE syndrome?

- a) Cognitive impairment
- b) Progressive sensorineural hearing loss
- c) Obesity
- d) Ophthalmologic changes
- e) Progressive loss of peripheral fat

2. Which of the following statement is/are true about CANDLE syndrome?

- a) Histological examination reveals dense eosinophilic infiltrate in perivascular and interstitial localization
- b) The predominant cells that comprise the infiltrate in the dermis are mature neutrophils
- c) Hypochromic anemia is present virtually in all patients
- d) Markers of autoimmunity are frequently positive
- e) Brain imaging studies may show basal ganglia calcification

3. Which of the following syndromes is not associated with proteasome dysfunction?

- a) CANDLE (Chronic Atypical Neutrophilic Dermatitis with Lipodystrophy and Elevated temperature) syndrome
- b) Chronic Infantile, Neurological, Cutaneous and Articular (CINCA) syndrome
- c) Nakajo-Nishimura syndrome (NNS)
- d) Japanese autoinflammatory syndrome with lipodystrophy (JASL)
- e) Joint contractures, muscular atrophy, microcytic anemia, panniculitis-associated lipodystrophy (JMP) syndrome

4. Type 1 IFN is the key molecule in CANDLE syndrome. Which of the following intracellular signalling pathway is triggered by type I IFNs?

- a) JAK/STAT
- b) RAS/MAPK
- c) IL-1 β pathway
- d) IL-17 pathway