

# Os Vários Tipos de Angioedema: Classificação, Diagnóstico e Tratamento

Mariana Batista<sup>1</sup>, F Alves<sup>1</sup>, Margarida Gonçalo<sup>2,3</sup>

<sup>1</sup>Interna de Dermatovenereologia, Serviço de Dermatologia, Centro Hospitalar Universitário de Coimbra, Coimbra, Portugal

<sup>2</sup>Assistente Graduada de Dermatovenereologia, Serviço de Dermatologia, Centro Hospitalar Universitário de Coimbra, Coimbra, Portugal

<sup>3</sup>Professora Convidada da Faculdade de Medicina da Universidade de Coimbra, Coimbra, Portugal

**RESUMO** – Angioedema caracteriza-se por edema transitório e localizado da derme e submucosa secundário à libertação de mediadores vasoativos de origem mastocitária ou não. Podem também ser formas agudas ou crónicas, hereditárias ou adquiridas. Os aspectos clínicos, em particular nos sintomas associados, e os mecanismos fisiopatológicos subjacentes a cada tipo de angioedema são distintos, devendo os dermatologistas estar capacitados para o seu reconhecimento uma vez que cada um implica diferentes abordagens diagnósticas e terapêuticas, e distintos prognósticos. Este artigo revê a classificação, o diagnóstico e o tratamento dos diferentes tipos de angioedema.

**PALAVRAS-CHAVE** – Angioedema/classificação; Angioedema/diagnóstico; Angioedema/genética; Angioedema/tratamento.

## The Different Faces of Angioedema: Classification, Diagnosis and Management

**ABSTRACT** – Angioedema is a transient localized and self-limiting edema of the subcutaneous and submucosal tissue, due to the release of vasoactive mediators. However, different mechanisms are at the origin of the different types of angioedema (acute or chronic, related or not with mast cell mediators and genetic and familial or acquired). Dermatologists should be able to recognize the different forms of angioedema as associated symptoms, treatment and prognostic factors are completely different. This paper reviews the classification of angioedema, diagnostic tests and management.

**KEY WORDS** – Angioedema/classification; Angioedema/diagnosis; Angioedema/genetics; Angioedema/therapy.

### INTRODUCTION

Angioedema is a frequent clinical condition that sometimes can be life-threatening. Different mechanisms and vasoactive mediators are implicated in the different forms of angioedema. As each type of angioedema requires distinct treatment approaches and prompt diagnosis is the most important prognostic factor, dermatologists should be aware of the classification of angioedema (acute or chronic, hereditary or acquired) and appropriate management of each. This review focuses on classification, diagnostic tests and treatment of angioedema.

#### 1. DEFINITION

Angioedema is a transient (48-72 hours) localized and

self-limiting edema of the subcutaneous and submucosal tissue, due to the release of vasoactive mediators and a temporary increase in vascular permeability.<sup>1</sup> It frequently affects the face, with swollen eyelids and lips, usually with an asymmetric distribution, which can be disfiguring and disabbling. The swollen areas are larger and less well-defined than wheals and tend to be faint pink or normal in color. There may be pain or pruritus. Angioedema frequently occurs in association with urticaria (wheals) but isolated angioedema (without wheals) is not uncommon,<sup>2</sup> accounting for about 10% of cases of recurrent lesions.<sup>3</sup> When associated with wheals and in most cases of isolated angioedema, this is a mast-cell driven condition. Some cases of isolated recurrent angioedema, which are bradykinin-mediated,

**Correspondência:** Mariana Batista  
Serviço de Dermatologia - Centro Hospitalar e Universitário de Coimbra  
Praceta Prof. Mota Pinto  
3000-075, Coimbra, Portugal  
**E-mail:** [sousabatistamariana@gmail.com](mailto:sousabatistamariana@gmail.com)  
**DOI:** <https://dx.doi.org/10.29021/spdv.77.2.1064>

**Recebido/Received**  
17 Abril/April 2019  
**Aceite/Accepted**  
1 Maio/May 2019

## Educação Médica Contínua

have a distinct prognosis and need special therapy. Most are hereditary, but acquired cases can also occur.

### 2. CLINICAL RELEVANCE

Angioedema is a relatively common presentation in the emergency department (ED), accounting for about one million ED visits each year in the United States,<sup>4</sup> with hereditary angioedema (HAE) responsible for 2280 to 5000 visits. This data may underestimate the true level of angioedema-related ED use.<sup>5,6</sup> A survey in UK revealed that only 30% of patients with hereditary or acquired angioedema have visited the ED.<sup>7</sup> This may be a life-threatening situation that requires immediate intervention but most cases, particularly chronic and relapsing cases associated with urticaria, do not carry that risk and doctors need to distinguish the different forms in order to avoid excessive intervention at the emergency and inform the patient on the absence of significant risk in these cases.

### 3. CLASSIFICATION AND PATHOPHYSIOLOGY

Angioedema can occur as an isolated acute episode or as chronic and relapsing form. Moreover there are several types of acquired angioedema (AAE) and several hereditary angioedema (HAE), with distinct underlying pathophysiology (Fig.1).

Acute acquired angioedema can occur in the context of acute urticaria or anaphylaxis. Chronic recurrent angioedema occurs mostly in association with chronic spontaneous urticaria, or rarely, chronic inducible urticaria and even in the setting it can occur without evident wheals in about 10% of the cases. Chronic and relapsing angioedema without urticaria can also be a manifestation of the different forms of hereditary angioedema or of the rare acquired forms of angioedema.

Angioedema is mostly due to mast cell activation and degranulation, dependent or not on IgE, and results from the effect of histamine and other vasoactive mediators (cysteinyl leukotrienes, prostaglandins, or platelet-activating factor) on blood vessels.<sup>1</sup> Basophils also participate, particularly in anaphylaxis, which presents with laryngeal edema, bronchospasm with respiratory distress, hypotension, and bradycardia, an acute and potentially fatal condition.<sup>8</sup> In acute forms, the main causes are medications, food, and insect bites/stings to which the individuals are sensitized and have specific IgE.

Angioedema may also be mediated by bradykinin. This occurs due to the activation of the kallikrein system either by kininogen, activated factor XII (Hageman factor) or the classic complement pathway (C2a-kinin like), particularly in individuals who lack inhibiting factors (C1-INH deficiency), as in the hereditary forms of angioedema. Lymphoproliferative or autoimmune diseases may also lead to inactivation of C1-INH, causing an acquired form of angioedema. Drugs like angiotensin-converting enzyme (ACE) inhibitors that reduce the breakdown of bradykinin may be responsible for acquired angioedema related to angiotensin-converting enzyme (ACEI-AAE).<sup>9,10</sup>

### 4. CLINICAL PRESENTATION, DIAGNOSTIC TESTS, AND MANAGEMENT (FIG.4)

#### 4.1 Acute angioedema

An acute attack of angioedema may have an allergic (specific IgE) or pseudoallergic cause and may be a presenting feature of anaphylaxis. It develops very quickly after exposure to the culprit medication, food, or venom, may coexist with wheals and is soon followed by other symptoms and signs of anaphylaxis. This form of acute angioedema responds to high dose steroids or epinephrine. Serum tryptase may be high in this setting and becomes normal after resolution of the acute attack. Later it may be indicated to perform an appropriate allergy work-up (specific IgE, skin prick tests, and provocation tests).

#### 4.2. Chronic/recurrent mast-cell dependent angioedema

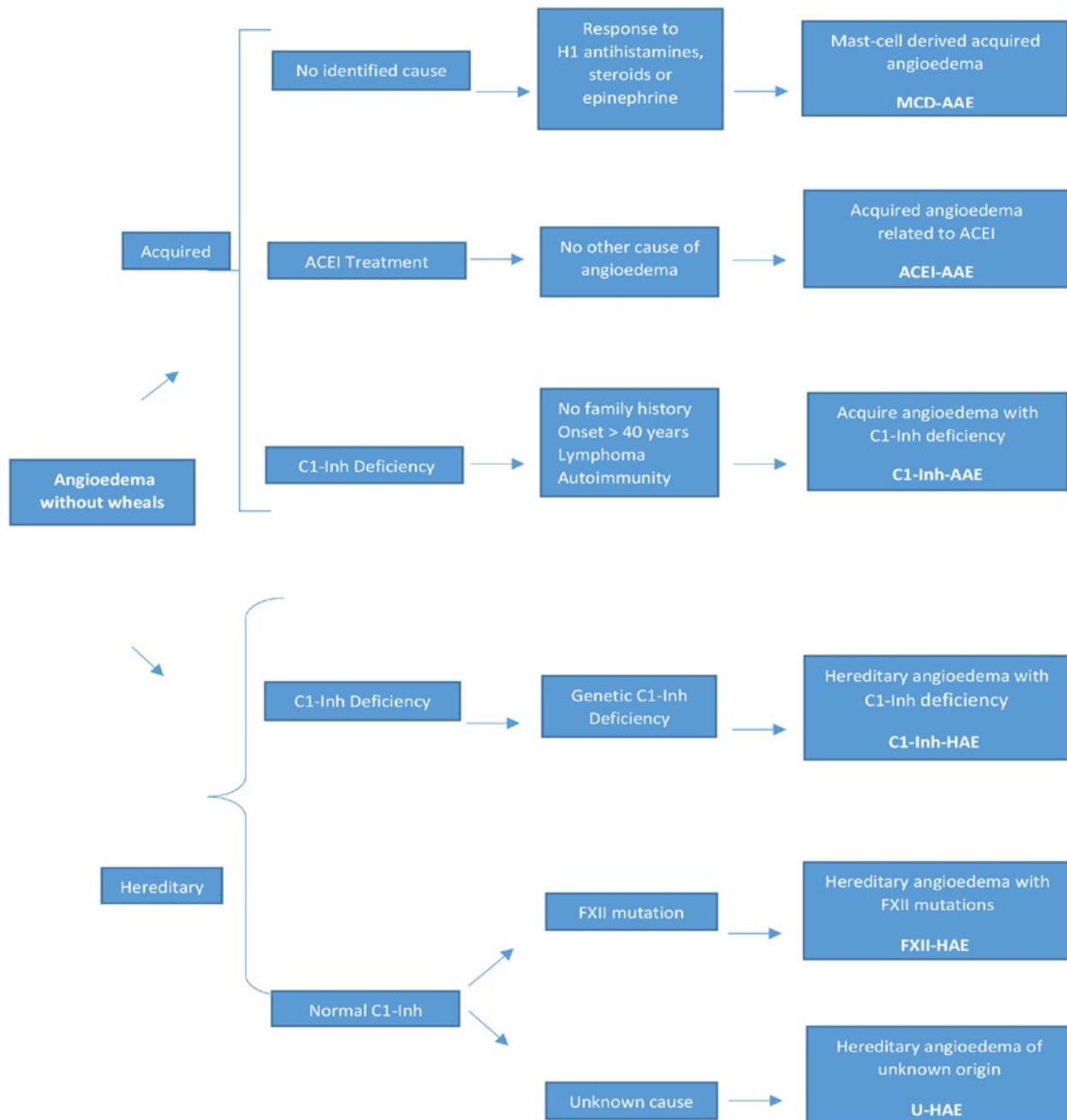
Chronic or recurrent mast-cell dependent angioedema (MCD-AAE), also called histaminergic acquired angioedema, is the most common form of angioedema without wheals, but most often it is associated with wheals in chronic spontaneous urticaria. It can be autoallergic (IgE-mediated autoimmunity type I), autoimmune (autoimmunity type II with IgG antibodies recognizing the high affinity IgE receptor (FcεRI) or IgE) or from an unknown cause, as shown for chronic spontaneous urticaria.<sup>11</sup> Physical stimuli can also induce angioedema (vibratory angioedema),<sup>12</sup> as in chronic inducible urticaria.

There is no specific age for the onset of MCD-AAE and as in CSU females are more often affected. In this setting swelling develops rapidly, reaching a maximum within 6 hours, fades in 24-48 hours, and recurs at a variable frequency. The face is mostly affected (Fig. 2), but gastrointestinal and laryngeal mucosae are spared, therefore with no potential risk of asphyxia.<sup>12</sup> This type of angioedema responds to oral steroids and epinephrine in the acute stage. H1 anti-histamines used prophylactically on a daily basis, often in up to fourfold the recommended dose, are also considered as the first line in the treatment and prevention of attacks. Nevertheless, the presence of angioedema in association with chronic spontaneous urticaria often predicts a non-response to H1 anti-histamines,<sup>13</sup> and second or third line therapy, respectively omalizumab or cyclosporine, may be necessary.

Chronic/recurrent MCD-AAE is diagnosed by clinical features (association with urticaria), exclusion findings (absence of abdominal and laryngeal attacks, no family history, normal laboratory tests, although D-dimers and C-RP may be slightly elevated during the attacks) and by therapeutic response to H1 anti-histamines, steroids, and, eventually, epinephrine.

#### 4.3. Acquired angioedema related to angiotensin-converting enzyme inhibitors (ACEI-AAE)

During treatment of hypertension with captopril or related ACEI drugs, the inhibition of the angiotensin converting enzyme involved in the breakdown of bradykinin results



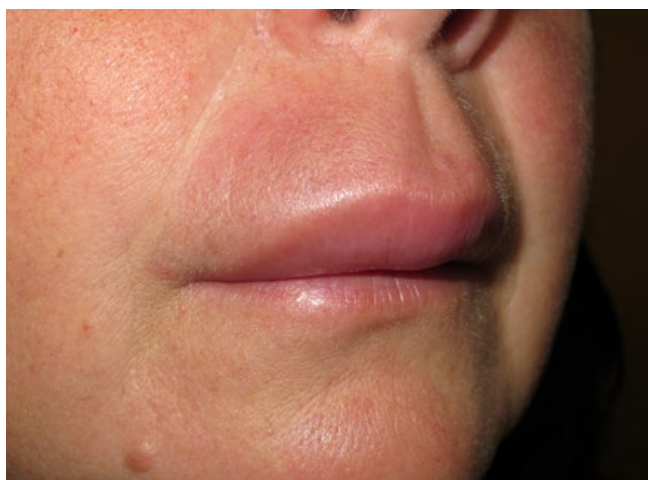**Figure 1** - Schematic classification of chronic / recurrent angioedema without wheals.

in elevated plasma levels of bradykinin that further increase during angioedema.<sup>8,9</sup> Angioedema occurs in <0.5% of treated patients, 3–4.5-fold more often in black than in Caucasian subjects, more in women, and in patients older than 65 years.<sup>14-19</sup> The latency period between the initiation of ACEI therapy and the onset of symptoms varies from a few hours to several years, but it is more likely to occur

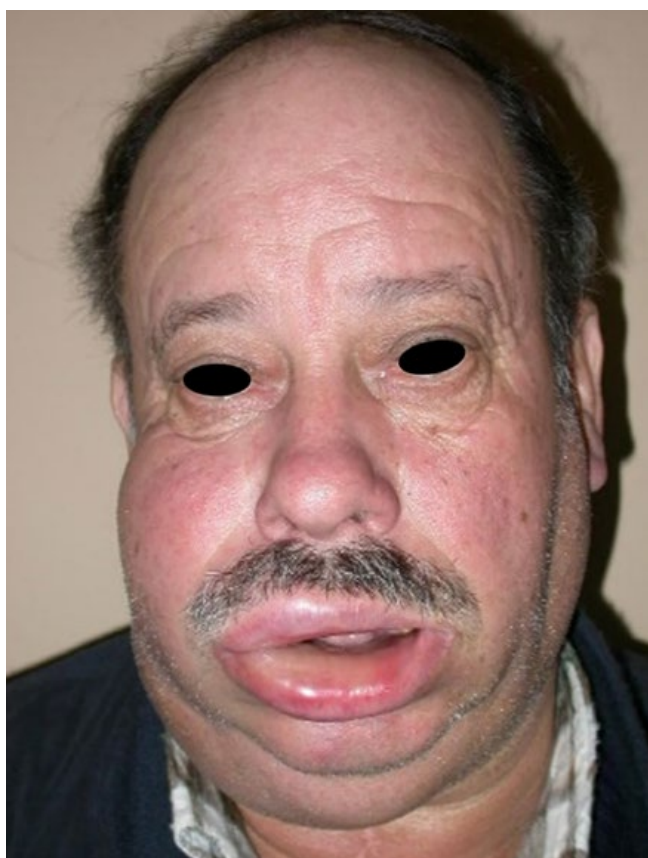shortly after initiation of therapy.<sup>16,20-23</sup> This type of angioedema usually involves the face, lips, eyelids, tongue, neck, and upper airways<sup>24</sup> (Fig. 3). Death may occur from laryngeal edema due to ACEI-AAE.<sup>24-26</sup>

There are no specific tests for this type of angioedema. The diagnosis is based upon the existence of angioedema with no wheals, absence of family history, exposure to ACEI

## Educação Médica Contínua



**Figure 2** - Lip angioedema in a patient with chronic spontaneous urticaria.



**Figure 3** - Asymmetrical facial angioedema with significant disfigurement in a patient taking lisinopril.

and response to icatibant. This agent, which inhibits bradykinin  $\beta$ 2receptors and is licensed to treat C1-INH deficiency hereditary angioedema, has been shown to reverse symptoms in ACEI-AAE.<sup>27</sup>

The culprit drug should be immediately discontinued and a switch to a different antihypertensive therapy is indicated, preferably not a sartan derivative, as it may also interfere with bradykinin degradation.<sup>28</sup> Even after ACEI withdrawal, some patients may have recurrent angioedema.<sup>29</sup> Such patients could be slow bradykinin "catabolizers", have "hidden" InH-AAE disclosed by ACEI, or are exposed to other drugs involved in bradykinin metabolism.<sup>30</sup>

Other drugs have recently been suggested as possibly involved in attacks of angioedema without wheals, namely the gliptins used for diabetes mellitus as they inhibit dipeptidyl peptidase 4 also involved in bradykinin metabolism.<sup>1</sup>

### **4.4. Acquired angioedema with C1 inhibitor deficiency**

Acquired angioedema with C1 inhibitor deficiency with no mutations in *C1-INH* gene (*SERPING1*) and no family history of angioedema, can occur in patients with lymphoproliferative or autoimmune diseases,<sup>32-35</sup> due to C1 and C1-INH consumption.<sup>32,36-8</sup> The prevalence in the general population is estimated to approximate 1 : 500 000.<sup>39</sup>

This form of AAE begins after the age of 40% in 94% of patients, predominantly involves the face, tongue, uvula, and upper airways, and can affect any location. Gastrointestinal attacks are less common than in HAE.<sup>40,41</sup>

As in HAE, plasma levels of C1-INH protein are reduced, its functional activity is below 50%, and a significant reduction in C4 is almost invariably present. Genetic analysis may be necessary to exclude a *SERPING1* mutation. Routine clinical testing should be performed to rule out a lymphoproliferative or autoimmune disease or a monoclonal gammopathy of undetermined significance.<sup>42</sup>

Treatment of the underlying lymphoproliferative disease resolves angioedema attacks. With slow-growing lymphoproliferative diseases that do not require treatment per se, management of angioedema attacks may have to be considered.

C1-INH replacement therapy is associated with a good response in most patients,<sup>43</sup> but with acute life-threatening attacks, doses of C1-INH concentrate higher than in HAE may be needed. On demand subcutaneous icatibant, or the subcutaneous plasma kallikrein inhibitor ecallantide, have been reported to be efficacious.<sup>44,45</sup> Prophylactic therapy can be performed with C1-INH or tranexamic acid.<sup>43,46</sup>

### **4.5. Hereditary angioedema (HAE)**

Hereditary angioedema often occurs due to C1-inhibitor deficiency (C1-INH-HAE). This is a relatively rare autosomal-dominant disorder with an estimated prevalence of 1:10 000 - 1:100 000 inhabitants.<sup>47,48</sup> Mutations in one of the two alleles of *C1-INH* gene, *SERPING1*, result in reduced plasma levels of *C1-INH* and instability of the contact system with facilitated release of bradykinin. There are two main phenotypic variants:

- type I with a quantitative decrease in C1-INH and consequently diminished functional activity (C1-INH-HAE type I)

- type II with normal or high levels of C1-INH protein, which is dysfunctional (C1-INH-HAE type II).<sup>49</sup>

In HAE cases with normal C1-INH activity, previously called "hereditary angioedema type III", approximately 20% of affected individuals have a heterozygous gain-of-function mutation in the gene that encodes FXII, which activates the kallikrein system and secondarily kininogen to produce bradykinin. The term, factor XII-HAE (FXII-HAE), has been proposed for these patients.<sup>1</sup> There are still other cases of HAE with normal C1-INH with no known cause.

HAE presents with recurrent, localized subcutaneous or submucosal edema lasting for 2–5 days, involving the skin, upper airways, gastrointestinal tract, and renal system. The clinical expression is highly variable, ranging from asymptomatic presentations to life-threatening attacks, mostly related to asphyxia.<sup>50,51</sup> Skin swelling affect mainly the face and the extremities. Urticaria does not occur at any time in these patients, but transient "erythema marginatum" preceding the attacks sometimes occurs with C1-INH-HAE. Almost all patients have recurrent attacks of crampy abdominal pain and vomiting, caused by transient bowel obstruction due to mucosal edema.<sup>48,52</sup> This is often misdiagnosed as a surgical emergency and treated with unnecessary surgery.

Swellings in C1-INH-HAE, both type I or II, begin early in life, at puberty, or in early adulthood. In FXII-HAE and HAE of unknown cause, the age of onset is later, usually in the second decade.<sup>53</sup> Both sexes are equally affected except in FXII-HAE, which affects almost only women. *F12* gene mutations are transmitted as an autosomal dominant trait with low penetrance: asymptomatic carriers are >90% in men and around 40% in women.<sup>54-56</sup> In many women, the clinical findings are induced or aggravated by oral contraceptives, hormonal replacement therapy, or pregnancy.

Patients with C1-INH-HAE have a low C4, even in between attacks.<sup>58</sup> C2 is also frequently low, as it is consumed due to the activation of the classic complement pathway lacking its physiologic inhibitor C1-INH. Low plasma C1-INH levels (50% below the normal value) confirm the diagnosis,<sup>58</sup> but in 15% of the patients, only C1-INH functional activity is low (type II). The diagnosis should be based on two serum determination with reduced C4 and low quantitative and/or functional C1-INH, separated by 1–3 months.<sup>59</sup> Genetic testing is needed during the first years, as C1-INH plasma levels may be falsely low.

Diagnosis of HAE of unknown cause is purely based on clinical findings and requires:

- the above-mentioned clinical symptoms
- one or more affected family members
- exclusion of familial and hereditary chronic urticaria with associated angioedema
- normal C1-INH activity and protein in plasma, no HAE-associated mutation in *F12* gene. FXII-HAE has analogous clinical criteria with a *F12* gene mutation.<sup>60</sup>

It must be remembered that in an emergency, when blood tests are not yet available, a family history of similar presentations and the association of abdominal symptoms

with bowel edema and peritoneal effusion observed by ultrasonography can confirm an abdominal attack of HAE, thus avoiding unnecessary surgery.

Treatment of the acute attacks in C1-INH-HAE is based on replacement therapy with intravenous C1-INH concentrate or recombinant C1-INH, bradykinin inhibition with the subcutaneous specific bradykinin  $\beta$ 2 receptor antagonist icatibant, or kallikrein inhibition with subcutaneous ecallantide. Prompt therapy at the emergency room or at home has shown to be life-saving.<sup>61</sup> Fresh frozen plasma may be given as an alternative to C1-INH concentrate if the latter is unavailable. There is no consensual treatment for other forms of HAE but C1-INH replacement, icatibant, ecallantide, progesterone, danazol, and tranexamic acid have been proposed.

In patients with frequent or severe attacks, continuous treatment should be considered, either recombinant C1 esterase inhibitor (Cinryze<sup>®</sup>) or with lanadelumab, a new human monoclonal antibody that targets plasma kallikrein and has recently been approved by the FDA.<sup>62</sup> Attenuated androgens (danazol, stanazolol) that increase hepatic synthesis of C1-INH or antifibrinolytic agents (oral tranexamic acid) can also reduce frequency and severity of attacks. Side effects of long-term treatment include virilizing effects, hepatic inflammation and adenomas for danazol,<sup>64</sup> and increased risk of thrombosis for tranexamic acid.<sup>64</sup>

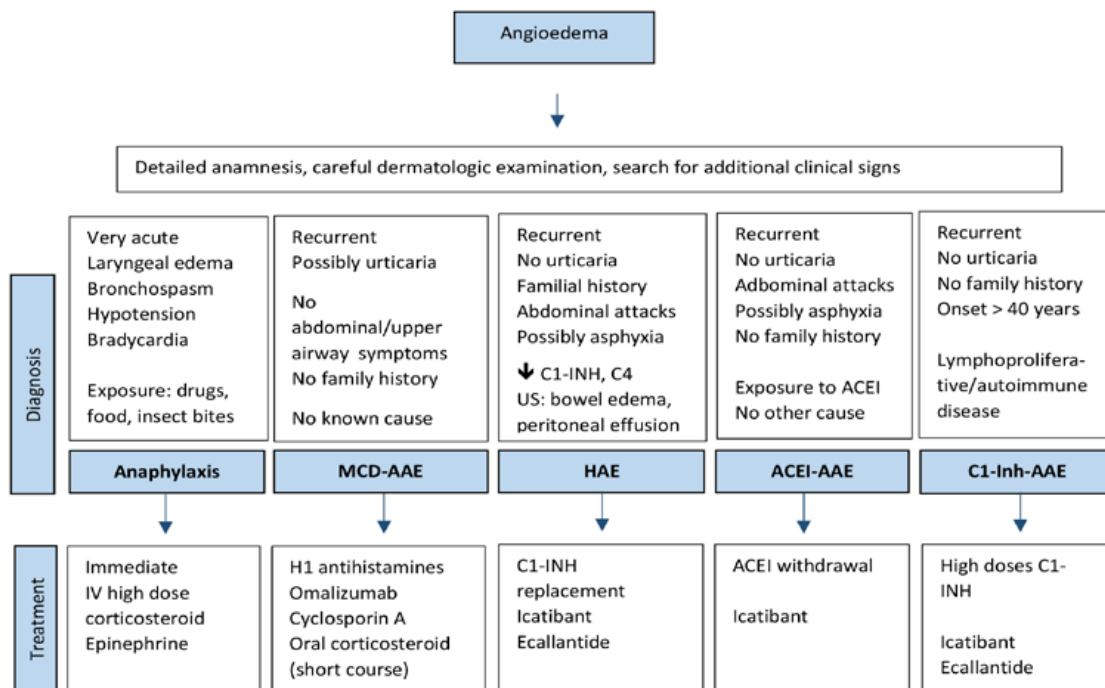
Prophylactic treatment should always be reinforced in C1-INH-HAE patients prior to medical maneuvers, namely dental procedures or general anesthesia that can cause local trauma and may trigger upper airways edema.<sup>65</sup> Plasma-derived or recombinant C1-INH, given as close as possible to the procedure, is the most rational approach.<sup>60</sup> Oral tranexamic acid (1 g four times daily in adults or 500 mg four times daily in children) for 48 hours before and after the procedure, or an increase in established maintenance doses of tranexamic acid or danazol can also be effective as prophylaxis.

As HAE may be induced or exacerbated by estrogens, oral contraceptive pills or hormone replacement therapy should be avoided, if possible.

### CONCLUSION

Different types of angioedema can be challenging to distinguish clinically. However, establishing a correct diagnosis is critical as different forms of angioedema require distinct treatment approaches. Thus, for example, icatibant or C1-INH replacement therapy is indicated in HAE whereas these drugs have no effect on angioedema associated with chronic spontaneous urticaria. Likewise, epinephrine administration will have no effect on an acute attack of HAE in contrast to angioedema in the context of anaphylaxis. A detailed anamnesis, careful physical examination and search for additional clinical signs are the key to the correct diagnosis (Fig. 4). On the other hand, only after an accurate diagnosis, appropriate management strategies are possible.

# Educação Médica Contínua



**MCD-AAE:** Mast-cell derived Acquired angioedema; **C1-INH:** C1-inhibitor; **US** – ultrasonography; **HAE:** hereditary angioedema; **ACEI-AAE:** Acquired angioedema related to ACEI; **C1-Inh-AAE:** Acquire angioedema with C1-inh deficiency

**Figure 4** - Algorithm for diagnosis and management of angioedema.

**Conflitos de interesse:** Os autores declaram não possuir conflitos de interesse.

**Suporte financeiro:** O presente trabalho não foi suportado por nenhum subsídio ou bolsa.

**Consentimento do Doente:** Obtido consentimento.

**Conflicts of interest:** The authors have no conflicts of interest to declare.

**Financing Support:** This work has not received any contribution, grant or scholarship.

**Patient consent:** Consent obtained.

**Proveniência e revisão por pares:** Não comissionado; revisão externa por pares.

**Provenance and peer review:** Not commissioned; externally peer reviewed.

## REFERENCES

- Cicardi M, Aberer W, Banerji A, Bas M, Bernstein JA, Bork K, et al. Classification, diagnosis, and approach to treatment for angioedema: consensus report from the Hereditary Angioedema International Working Group. *Allergy*. 2014;69:602-16. doi:10.1111/all.12380
- Zuberbier T, Aberer W, Asero R, Abdul Latiff AH, Baker D, Ballmer-Weber B, et al. The EAACI/GA(2)LEN/EDF/WAO guideline for the definition, classification, diagnosis and management of urticaria. *Allergy*. 2018;73:1393-1414. doi:10.1111/all.13397
- Mansi M, Zanichelli A, Coerezza A, Suffritti C, Wu MA, Vacchini R, et al. Presentation, diagnosis and treatment of angioedema without wheals: a retrospective analysis of a cohort of 1058 patients. *J Intern Med*. 2015;277:585-93. doi:10.1111/joim.12304
- Kelly M, Donnelly JP, McAnnally JR, Wang HE. National estimates of emergency department visits for angioedema and allergic reactions in the United States. *Allergy Asthma Proc*. 2013;34:150-4. doi:10.2500/aap.2013.34.3640
- Zilberberg MD, Jacobsen T, Tillotson G. The burden of hospitalizations and emergency department visits with hereditary angioedema and angioedema in the United States, 2007. *Allergy Asthma Proc*. 2010;31:511-9. doi:10.2500/aap.2010.31.3403
- Zilberberg MD, Nathanson BH, Jacobsen T, Tillotson G. Descriptive epidemiology of hereditary angioedema emergency department visits in the United States, 2006-2007. *Allergy Asthma Proc*. 2011;32:390-4. doi:10.2500/aap.2011.32.3478
- Jolles S, Williams P, Carne E, Mian H, Huissoon A, Wong G, et al. A UK national audit of hereditary and acquired angioedema. *Clin Exp Immunol*. 2014;175:59-67. doi:10.1111/cei.12159
- Ikizoglu G. Red face revisited: Flushing. *Clin Dermatol*. 2014;32:800-8. doi:10.1016/j.clindermatol.2014.02.019

9. Pellacani A, Brunner HR, Nussberger J. Plasma kinins increase after angiotensin-converting enzyme inhibition in human subjects. *Clin Sci*. 1994;87:567-74.
10. Nussberger J, Cugno M, Cicardi M. Bradykinin-mediated angioedema. *N Engl J Med*. 2002;347:621-2. doi:10.1056/nejm200208223470820
11. Kolkhir P, Church MK, Weller K, Metz M, Schmetzer O, Maurer M. Autoimmune chronic spontaneous urticaria: What we know and what we do not know. *J Allergy Clin Immunol*. 2017;139:1772-81.e1. doi:10.1016/j.jaci.2016.08.050
12. Zingale LC, Beltrami L, Zanichelli A, Maggioni L, Pappalardo E, Cicardi B, et al. Angioedema without urticaria: a large clinical survey. *CMAJ*. 2006;175:1065-70. doi:10.1503/cmaj.060535
13. Magen E, Mishal J, Zeldin Y, Schlesinger M. Clinical and laboratory features of antihistamine-resistant chronic idiopathic urticaria. *Allergy Asthma Proc*. 2011;32:460-6. doi:10.2500/aap.2011.32.3483
14. Miller DR, Oliveria SA, Berlowitz DR, Fincke BG, Stang P, Lillienfeld DE. Angioedema incidence in US veterans initiating angiotensin-converting enzyme inhibitors. *Hypertension*. 2008;51:1624-30. doi:10.1161/HYPERTENSIONAHA.108.110270
15. Brown NJ, Ray WA, Snowden M, Griffin MR. Black Americans have an increased rate of angiotensin converting enzyme inhibitor-associated angioedema. *Clin Pharmacol Ther*. 1996;60:8-13. doi:10.1016/s0009-9236(96)90161-7.
16. Kostis JB, Kim HJ, Rusnak J, Casale T, Kaplan A, Corren J, et al. Incidence and characteristics of angioedema associated with enalapril. *Arch Intern Med*. 2005;165:1637-42. doi:10.1001/archinte.165.14.1637
17. Burkhart DG, Brown NJ, Griffin MR, Ray WA, Hammersstrom T, Weiss S. Angiotensin converting enzyme inhibitor-associated angioedema: higher risk in blacks than whites. *Pharmacoepidemiol Drug Saf*. 1996;5:149-54. doi:10.1002/(sici)1099-1557(199605)5:3<149::Aid-pds222>3.0.Co;2-i
18. Toh S, Reichman ME, Houstoun M, Ding X, Hernandez AF, Levenson M, et al. Comparative risk for angioedema associated with the use of drugs that target the renin-angiotensin-aldosterone system. *Arch Intern Med*. 2012;172:1582-1589. doi:10.1001/2013.jamainternmed.34
19. Kostis JB, Packer M, Black HR, Schmieder R, Henry D, Levy E. Omapatrilat and enalapril in patients with hypertension: the omapatrilat cardiovascular treatment vs. enalapril (OCTAVE) trial. *Am J Hypertens*. 2004;17:103-111.
20. Brown NJ, Snowden M, Griffin MR. Recurrent angiotensin-converting enzyme inhibitor--associated angioedema. *JAMA*. 1997;278:232-3.
21. Agostoni A, Cicardi M, Cugno M, Zingale LC, Giuffrè D, Nussberger J. Angioedema due to angiotensin-converting enzyme inhibitors. *Immunopharmacology*. 1999;44:21-5.
22. Slater EE, Merrill DD, Guess HA, Roylance PJ, Cooper WD, Inman WH, et al. Clinical profile of angioedema associated with angiotensin converting-enzyme inhibition. *JAMA*. 1988;260:967-970.
23. Campo P, Fernandez TD, Canto G, Mayorga C. Angioedema induced by angiotensin-converting enzyme inhibitors. *Curr Opin Allergy Clin Immunol*. 2013;13:337-44. doi:10.1097/ACI.0b013e328362b835
24. Dean DE, Schultz DL, Powers RH. Asphyxia due to angiotensin converting enzyme (ACE) inhibitor mediated angioedema of the tongue during the treatment of hypertensive heart disease. *J Forensic Sci*. 2001;46:1239-43.
25. Cupido C, Rayner B. Life-threatening angio-oedema and death associated with the ACE inhibitor enalapril. *S Afr Med J*. 2007;97:244-5.
26. Messerli FH, Nussberger J. Vasopeptidase inhibition and angio-oedema. *Lancet*. 2000;356:608-9. doi:10.1016/s0140-6736(00)02596-4.
27. Bas M, Greve J, Stelter K, Bier H, Stark T, Hoffmann TK, et al. Therapeutic efficacy of icatibant in angioedema induced by angiotensin-converting enzyme inhibitors: a case series. *Ann Emerg Med*. 2010;56:278-82. doi:10.1016/j.annemergmed.2010.03.032
28. Gosmanov AR, Fontenot EC. Sitagliptin-associated angioedema. *Diabetes Care*. 2012;35:e60. doi:10.2337/dc12-0574
29. Faisant C, Armengol G, Bouillet L, Boccon-Gibod I, Villier C, Lévesque H, et al. Angioedema triggered by medication blocking the renin/angiotensin system: retrospective study using the French National Pharmacovigilance Database. *J Clin Immunol*. 2016;36:95-102. doi:10.1007/s10875-015-0228-3
30. Beltrami L, Zanichelli A, Zingale L, Vacchini R, Carugo S, Cicardi M. Long-term follow-up of 111 patients with angiotensin-converting enzyme inhibitor-related angioedema. *J Hypertens*. 2011;29:2273-7. doi:10.1097/HJH.0b013e32834b4b9b
31. Hahn J, Trainotti S, Hoffmann TK, Greve J. Drug-induced inhibition of angiotensin converting enzyme and dipeptidyl peptidase 4 results in nearly therapy resistant bradykinin induced angioedema: a case report. *Am J Case Rep*. 2017;18:576-579.
32. Hauptmann G, Lang JM, North ML, Oberling F, Mayer G, Lachmann P. Acquired c1-inhibitor deficiencies in lymphoproliferative diseases with serum immunoglobulin abnormalities. A study of three cases. *Blut*. 1976;32:195-206.
33. Caldwell JR, Ruddy S, Schur PH, Austen KF. Acquired C1 inhibitor deficiency in lymphosarcoma. *Clin Immunol Immunopathol*. 1972;1:39-52. doi:https://doi.org/10.1016/0090-1229(72)90006-2
34. Schreiber AD, Zweiman B, Atkins P, Goldwein F, Pietra G, Atkinson B, et al. Acquired angioedema with lymphoproliferative disorder: association of C1 inhibitor deficiency with cellular abnormality. *Blood*. 1976;48:567-80.

## Educação Médica Contínua

35. Hauptmann G, Petitjean F, Lang JM, Oberling F. Acquired C1 inhibitor deficiency in a case of lymphosarcoma of the spleen. Reversal of complement abnormalities after splenectomy. *Clin Exp Immunol.* 1979;37:523-31.
36. Cugno M, Cicardi M, Coppola R, Agostoni A. Activation of factor XII and cleavage of high molecular weight kininogen during acute attacks in hereditary and acquired C1-inhibitor deficiencies. *Immunopharmacology.* 1996;33:361-4.
37. Cugno M, Cicardi M, Bottasso B, Coppola R, Paonessa R, Mannucci PM, et al. Activation of the coagulation cascade in C1-inhibitor deficiencies. *Blood.* 1997;89:3213-8.
38. Nussberger J, Cugno M, Amstutz C, Cicardi M, Pellacani A, Agostoni A. Plasma bradykinin in angio-oedema. *Lancet.* 1998;351:1693-7. doi:10.1016/s0140-6736(97)09137-x
39. Cicardi M, Zanichelli A. Acquired angioedema. *Allergy Asthma Clin Immunol.* 2010;6:14. doi:10.1186/1710-1492-6-14.
40. Cicardi M, Zanichelli A. The acquired deficiency of C1-inhibitor: lymphoproliferation and angioedema. *Curr Mol Med.* 2010;10:354-60.
41. Bouillet-Claveyrolas L, Ponard D, Drouet C, Drouet C, Massot C. Clinical and biological distinctions between type I and type II acquired angioedema. *Am J Med.* 2003;115:420-1.
42. Zuraw BL, Bernstein JA, Lang DM, Craig T, Dreyfus D, Hsieh F, et al. A focused parameter update: hereditary angioedema, acquired C1 inhibitor deficiency, and angiotensin-converting enzyme inhibitor-associated angioedema. *J Allergy Clin Immunol.* 2013;131:1491-3. doi:10.1016/j.jaci.2013.03.034
43. Agostoni A, Cicardi M. Hereditary and acquired C1-inhibitor deficiency: biological and clinical characteristics in 235 patients. *Med.* 1992;71:206-15.
44. Zanichelli A, Bova M, Coerezza A, Petraroli A, Triggiani M, Cicardi M. Icatibant treatment for acquired C1-inhibitor deficiency: a real-world observational study. *Allergy.* 2012;67:1074-7. doi:10.1111/j.1398-9995.2012.02853.x
45. Patel NS, Fung SM, Zanichelli A, Cicardi M, Cohn JR. Ecallantide for treatment of acute attacks of acquired C1 esterase inhibitor deficiency. *Allergy Asthma Proc.* 2013;34:72-7. doi:10.2500/aap.2013.34.3620
46. Zingale LC, Castelli R, Zanichelli A, Cicardi M. Acquired deficiency of the inhibitor of the first complement component: presentation, diagnosis, course, and conventional management. *Immunol Allergy Clin North Am.* 2006;26:669-90. doi:10.1016/j.iac.2006.08.002
47. Cicardi M, Agostoni A. Hereditary angioedema. *N Engl J Med.* 1996;334:1666-7. doi:10.1056/nejm199606203342510
48. Longhurst H, Cicardi M. Hereditary angio-oedema. *Lancet.* 2012;379:474-81. doi:10.1016/s0140-6736(11)60935-5
49. Rosen FS, Pensky J, Donaldson V, Charache P. Hereditary angioneurotic edema: two genetic variants. *Science.* 1965;148:957-8.
50. Lumry WR, Castaldo AJ, Vernon MK, Blaustein MB, Wilson DA, Horn PT. The humanistic burden of hereditary angioedema: Impact on health-related quality of life, productivity, and depression. *Allergy Asthma Proc.* 2010;31:407-14. doi:10.2500/aap.2010.31.3394
51. Wilson DA, Bork K, Shea EP, Rentz AM, Blaustein MB, Pullman WE. Economic costs associated with acute attacks and long-term management of hereditary angioedema. *Ann Allergy Asthma Immunol.* 2010;104:314-20. doi:10.1016/j.anai.2010.01.024
52. Bork K, Staubach P, Eckardt AJ, Hardt J. Symptoms, course, and complications of abdominal attacks in hereditary angioedema due to C1 inhibitor deficiency. *Am J Gastroenterol.* 2006;101:619-27. doi:10.1111/j.1572-0241.2006.00492.x
53. Grattan C, Saini S. Urticaria and Angioedema. In: Bologna JL, Schaffer J, Cerroni L editors. *Dermatology.* Amsterdam: Elsevier; 2018. p.304-19.
54. Bork K, Gul D, Hardt J, Dewald G. Hereditary angioedema with normal C1 inhibitor: clinical symptoms and course. *Am J Med.* 2007;120:987-92. doi:10.1016/j.amjmed.2007.08.021
55. Marcos C, Lopez Lera A, Varela S, Liñares T, Alvarez-Eire MG, López-Trascasa M. Clinical, biochemical, and genetic characterization of type III hereditary angioedema in 13 Northwest Spanish families. *Ann Allergy Asthma Immunol.* 2012;109:195-200.e2. doi:10.1016/j.anai.2012.05.022
56. Vitrat-Hincky V, Gompel A, Dumestre-Perard C, Boccon-Gibod I, Drouet C, Cesbron JY, et al. Type III hereditary angio-oedema: clinical and biological features in a French cohort. *Allergy.* 2010;65:1331-6. doi:10.1111/j.1398-9995.2010.02368.x
57. Donaldson VH, Rosen FS. Action of complement in hereditary angioneurotic edema: the role of c'1-esterase. *J Clin Invest.* 1964;43:2204-13. doi:10.1172/jci105094
58. Agostoni A, Aygoren-Pursun E, Binkley KE, Blanch A, Bork K, Bouillet L, et al. Hereditary and acquired angioedema: problems and progress: proceedings of the third C1 esterase inhibitor deficiency workshop and beyond. *J Allergy Clin Immunol.* 2004;114:S51-131. doi:10.1016/j.jaci.2004.06.047
59. Caballero T, Farkas H, Bouillet L, Bowen T, Gompel A, Fagerberg C, et al. International consensus and practical guidelines on the gynecologic and obstetric management of female patients with hereditary angioedema caused by C1 inhibitor deficiency. *J Allergy Clin Immunol.* 2012;129:308-20. doi:10.1016/j.jaci.2011.11.025
60. Maurer M, Magerl M, Ansoategui I, Aygören-Pürsün E, Betschel S, Bork K, et al. The international WAO/EAACI guideline for the management of hereditary angioedema-The 2017 revision and update. *Allergy.* 2018;73:1575-96. doi:10.1111/all.13384
61. Longhurst HJ, Farkas H, Craig T, Aygören-Pürsün E,



- Bethune C, Bjorkander J, et al. HAE international home therapy consensus document. *Allergy Asthma Clin Immunol.* 2010;6:22. doi:10.1186/1710-1492-6-22
62. Busse PJ, Farkas H, Banerji A, Lumry WR, Longhurst HJ, Sexton DJ, et al. Lanadelumab for the prophylactic treatment of hereditary angioedema with c1 inhibitor deficiency: a review of preclinical and phase i studies. *BioDrugs.* 2019;33:33-43. doi:10.1007/s40259-018-0325-y
63. Zotter Z, Veszeli N, Csuka D, Varga L, Farkas H. Frequency of the virilising effects of attenuated androgens reported by women with hereditary angioedema. *Orphanet J Rare Dis.* 2014;9:205. doi:10.1186/s13023-014-0205-6
64. Myers SP, Kutcher ME, Rosengart MR, Sperry JL, Peitzman AB, Brown JB, et al. Tranexamic acid administration is associated with an increased risk of posttraumatic venous thromboembolism. *J Trauma Acute Care Surg.* 2019;86:20-7. doi:10.1097/ta.0000000000002061
65. Grant JA, White M V, Li HH, Fitts D, Kalfus IN, Uknis ME, et al. Preprocedural administration of nanofiltered C1 esterase inhibitor to prevent hereditary angioedema attacks. *Allergy Asthma Proc.* 2012;33:348-53. doi:10.2500/aap.2012.33.3585

### VERIFIQUE O QUE APRENDEU

#### 1. Concerning acquired angioedema, which of the following is incorrect:

- In chronic/recurrent mast-cell dependent angioedema there are potential risk of asphyxia.
- H1 anti-histamines are used as first-line therapy in chronic/recurrent mast-cell dependent angioedema.
- In angioedema related to angiotensin-converting enzyme inhibitors (ACEI) the latency period between the initiation of ACEI therapy and the onset of symptoms varies from a few hours to several years.
- Acquired angioedema with C1 inhibitor deficiency can occur in patients with lymphoproliferative or autoimmune diseases.
- Epinephrine can be used for the treatment of angioedema in the context of anaphylaxis.

#### 2. In chronic/recurrent mast-cell dependent angioedema gastrointestinal and laryngeal mucosae are spared, so there is no risk of asphyxia.

##### Which of the following is false regarding hereditary angioedema (HAE):

- There are two main phenotypic variants: type I and type II.
- Typically subcutaneous or submucosal edema lasts for 2–5 days.
- May be induced or exacerbated by estrogens.
- Epinephrine is a first-line therapy in an emergency setting of HAE.
- Icatibant is a possible therapeutic option.

Correct answers: 1(a) e 2(d) Epinephrine does not have effect on an acute attack of HAE.