

Qual o Seu Diagnóstico?

Placa Anular Única na Fronte

Francisco Gil¹, Margarida Rato¹, Maria João Silva², José Carlos Cardoso^{3,4}

¹Interno de Dermatologia e Venereologia/Resident of Dermatology and Venereology, Hospital de Santarém EPE, Santarém, Portugal

²Chefe de Serviço, Diretora do Serviço de Dermatologia/Consultant Chief, Head of Department of Dermatology, Hospital de Santarém EPE, Santarém, Portugal

³Assistente Hospitalar de Dermatologia e Venereologia/Consultant of Dermatology and Venereology, Centro Hospitalar e Universitário de Coimbra, Coimbra, Portugal

⁴Centro de Diagnóstico Anátomo-Patológico, Coimbra, Portugal

PALAVRAS-CHAVE – Doenças da Pele; Granuloma; Testa

Dermatology Quiz

Single Annular Plaque on the Forehead

KEYWORDS – Forehead; Granuloma; Skin Diseases.

QUAL O SEU DIAGNÓSTICO?

A 51-year-old caucasian female presented with an 18-month history of an asymptomatic well demarcated annular plaque with central atrophy and raised erythematous margins on her forehead (Fig. 1). The patient had no associated systemic manifestations and denied any preceding local trauma or exposure to previous medication. There was no relevant personal or family history. Laboratory studies were unremarkable. Histopathologic examination showed a granulomatous infiltrate with numerous multinucleated giant cells surrounding solar elastosis (Fig. 2A). Verhoeff-van Gieson stain revealed elastophagocytosis (Fig. 2B). No infectious agents were identified after staining with Ziehl-Neelsen, Grocott and periodic acid-Schiff (PAS).

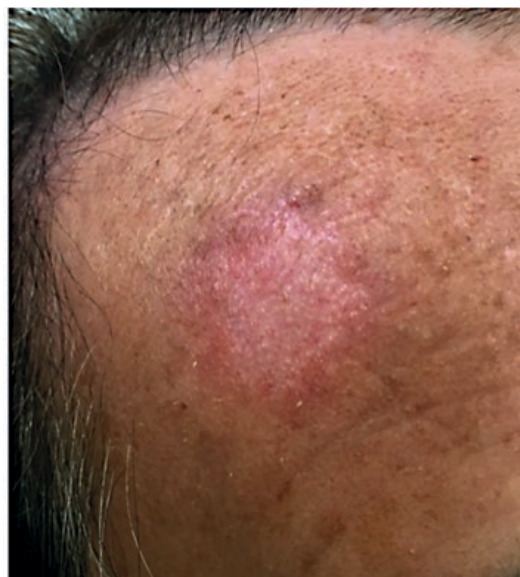

Figure 1 - Annular plaque on the forehead with an atrophic and hypopigmented center and raised erythematous margins.

Correspondência: Francisco Gil
Serviço de Dermatologia - Hospital de Santarém
Av. Bernardo Santareno, 4º piso
2005-177 Santarém, Portugal
E-mail: franciscogil@gmail.com
DOI: <https://dx.doi.org/10.29021/spdv.76.2.859>

Recebido/Received
17 Dezembro/December 2017
Aceite/Accepted
04 Fevereiro/February 2018

Qual o Seu Diagnóstico?

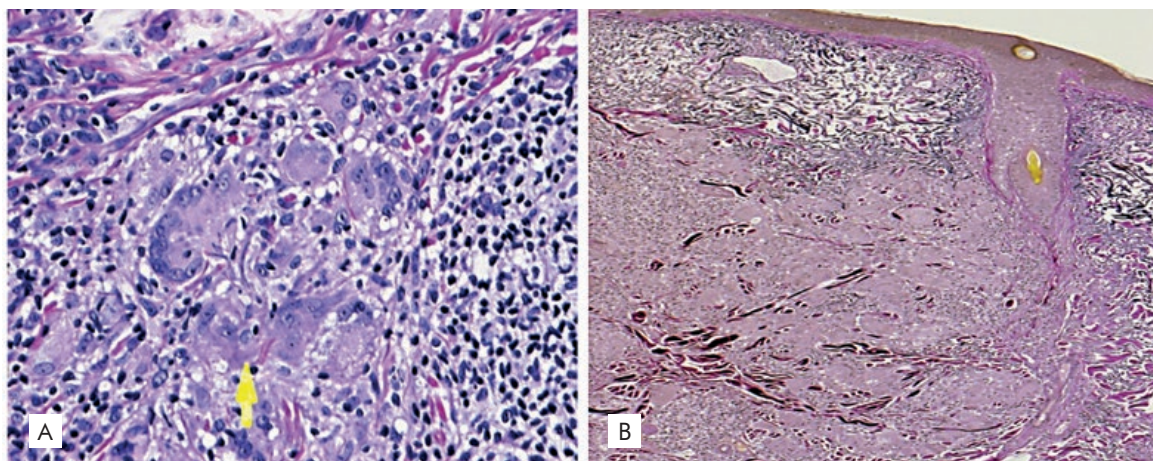


Figura 2 - A) Granulomatous infiltrate with multinucleated giant cells (yellow arrow) - H&E, 400x). B) Verhoeff-van Gieson stain revealed elastophagocytosis (Verhoeff – van Gieson 100x).

DIAGNOSIS

ACTINIC GRANULOMA

The clinical and histopathological findings supported a diagnosis of actinic granuloma. O'Brien's actinic granuloma, or annular elastolytic giant-cell granuloma, is an uncommon form of granulomatous dermatosis appearing on sun-exposed areas. Although the pathogenesis is unknown, solar elastosis resulting from sun damage is believed to be a triggering factor.¹ The postulated mechanism behind this hypothesis is that solar-damaged elastic fibers are weakly antigenic and result in a cell-mediated immune response with a predominance of CD4 lymphocytes trying to repair the actinically damaged skin but resulting in granulomatous inflammation instead.^{1,2}

The usual characteristics of actinic granuloma include asymptomatic annular or polycyclic lesions with centrifugal expansion, an erythematous elevated border and a hypopigmented atrophic center.³ Elastophagocytosis is the typical histopathologic feature, usually associated with an infiltrate of multinucleated giant cells that phagocytize the degenerated elastic fibers.⁴

Clinical differentials include facial lesions of granuloma annulare, necrobiosis lipoidica and annular sarcoid, but they can be readily distinguished by histopathology.¹ Treatment of actinic granuloma is difficult and lesions tend to persist with little response to therapy.² Several treatments have been proposed with varying results: topical or intralesional corticosteroids, acitretin, isotretinoin, cyclosporin, chloroquine, pentoxifyline, cryotherapy, PUVA photochemotherapy and methotrexate.^{2,5} The disease presents a chronic evolution, however some patients experience spontaneous resolution.^{1,2,4}

In the present clinical case there was no significant improvement with topical betamethasone. Assured of the benign nature of the disease, the patient refused other therapies, despite being informed of a potential enlargement and/or appearance of new lesions. The patient was advised to reduce sun exposure and use sunscreen to prevent development of new lesions. The lesion has remained stable for the last 10 months and will be kept under clinical surveillance.

Conflitos de interesse: Os autores declaram não possuir conflitos de interesse.

Suporte financeiro: O presente trabalho não foi suportado por nenhum subsídio ou bolsa.

Confidencialidade dos dados: Os autores declaram ter seguido os protocolos do seu centro de trabalho acerca da publicação dos dados de doentes.

Proteção de pessoas e animais: Os autores declaram que os procedimentos seguidos estavam de acordo com os regulamentos estabelecidos pelos responsáveis da Comissão de Investigação Clínica e Ética e de acordo com a Declaração de Helsínquia da Associação Médica Mundial.

Consentimento dos Doentes: Obtido.

Conflicts of interest: The authors have no conflicts of interest to declare.

Financing Support: This work has not received any contribution, grant or scholarship.

Confidentiality of data: The authors declare that they have followed the protocols of their work center on the publication of data from patients.

Protection of human and animal subjects: The authors declare that the procedures followed were in accordance with the regulations of the relevant clinical research ethics committee and with those of the Code of Ethics of the World Medical Association (Declaration of Helsinki).

Patients consent: Obtained.

REFERENCES

1. Yaghoob R, Ranjbari N, Feily A. Actinic granuloma. *Dermatol Pract Concept*. 2013;4:31-2.
2. Stein JA, Fangman B, Strober B. Actinic granuloma. *Dermatol Online J*. 2007; 13:19.
3. Coutinho I, Ramos LIC, Brites MM, Tellechea O. O'Brien actinic granuloma: a case report and brief review of literature. *Indian J Dermatol*. 2015;60:391-3.
4. Espiñeira-Carmona MJ, Arias-Santiago S, Aneiros-Fernández J, Fernández-Pugnaire MA, Naranjo-Sintes R, Aneiros-Cachaza J. Annular erythematous papules in the neckline. *Dermatol Online J*. 2011;17:7.
5. Lazzarini R, Rotter A, Farias DC, Muller H. O'Brien's actinic granuloma: an unusually extensive presentation. *An Bras Dermatol*. 2011;86:339-42.