

Caso Clínico

Dermatose Degenerativa Induzida por D-penicilamina em Paciente com Doença de Wilson

Rui Pedro Santos¹, Joana Gomes², Celeste Brito²

¹Interno de Dermatovenereologia/Resident, Dermatovenereology, Hospital de Braga, Braga, Portugal

²Especialista de Dermatovenereologia/Specialist of Dermatovenereology, Hospital de Braga, Braga, Portugal

RESUMO – As dermatoses degenerativas induzidas por D-penicilamina incluem, entre outras, a elastose perforante serpiginosa e o pseudo-pseudoxantoma elástico. A elastose perforante serpiginosa é uma doença perforante rara caracterizada pela eliminação transepidermica de fibras elásticas anormais. Esta condição pode ser idiopática, reativa ou induzida por D-penicilamina, habitualmente utilizada para o tratamento da doença de Wilson, cistinúria, artrite reumatóide ou esclerose sistémica. Manifestações cutâneas semelhantes a pseudoxantoma elástico mas sem história familiar e mutações do gene *ABCC6* foram identificadas como sendo uma dermatose induzida por D-penicilamina e designada de pseudo-pseudoxantoma elástico.

Descreve-se o caso de uma mulher de 17 anos tratada por vários anos com D-penicilamina para doença de Wilson, com pápulas assintomáticas, algumas cor de pele e hiperqueratósicas e outras macias e amareladas, na região cervical e face. A histopatologia mostrou a eliminação transepidermica de fibras elásticas espessadas, em forma de dentes de serra. Estes achados sugeriram uma dermatopatia induzida por D-penicilamina e os autores consideraram o diagnóstico de elastose perforante serpiginosa e pseudo-pseudoxantoma elástico no mesmo paciente. O fármaco foi alterado para acetato de zinco sem lesões novas, mas com manutenção das lesões existentes no seguimento a 1 ano.

PALAVRAS-CHAVE – Penicilamina/efeitos adversos; Degeneração Hepatolenticular; Doenças da Pele/induzidas quimicamente; Pseudoxantoma Elástico.

D-Penicillamine Induced Degenerative Dermopathy in a Patient with Wilson Disease

ABSTRACT – D-penicillamine induced degenerative dermatosis include, among others, elastosis perforans serpiginosa, and pseudo-pseudoxanthoma elasticum. Elastosis perforans serpiginosa is a rare perforating disease characterized by transepidermal elimination of abnormal elastic fibers. This condition can be idiopathic, reactive or induced by D-penicillamine, commonly used for the treatment of Wilson disease, cystinuria, rheumatoid arthritis or systemic sclerosis. Cutaneous manifestations resembling pseudoxanthoma elasticum but lacking familiar history and *ABCC6* mutations have been identified as a D-penicillamine induced dermatopathy and called pseudo-pseudoxanthoma elasticum.

The authors present a 17-year-old caucasian female treated for several years with D-penicillamine for Wilson disease who developed asymptomatic papules, some hyperkeratotic skin-colored and other soft and yellowish, on the cervical region and face. Histopathology showed transepidermal elimination of numerous, branched, sawtooth-like elastic fibers. These findings suggested a D-penicillamine induced dermatopathy and the authors considered the diagnosis of both elastosis perforans serpiginosa and pseudo-pseudoxanthoma elasticum in the same patient. The drug was switched to zinc acetate. No newer lesions appeared thereafter but previous lesions persisted at the 1 year follow-up.

KEYWORDS – Penicillamine/adverse effects; Hepatolenticular Degeneration; Pseudoxanthoma Elasticum; Skin Diseases/chemically induced.

Correspondência: Rui Pedro Santos

Serviço de Dermatologia

Hospital de Braga

Rua de Santa Bárbara n°52

4435-595 Baguim do Monte, Braga, Portugal

Email: drruisantos@hotmail.com

DOI: <https://dx.doi.org/10.29021/spdv.76.2.826>

Recebido/Received

12 Outubro/October 2017

Aceite/Accepted

08 Março/March 2018

Caso Clínico

INTRODUCTION

D-penicillamine induced degenerative dermatosis includes elastosis perforans serpiginosa (EPS), pseudoxanthoma elasticum-like skin changes or pseudo-pseudoxanthoma elasticum (PPXE), acquired cutis laxa and anetoderma.¹

Elastosis perforans serpiginosa is a rare perforating disease characterized by transepidermal elimination of abnormal elastic fibers. This condition is typically found in adolescents and young adults with a male preponderance.² EPS has been classified as idiopathic, reactive or drug-induced.³⁻⁵ It is usually an isolated condition but has also been associated with other diseases like Down's syndrome, Marfan syndrome, morphea, systemic sclerosis, cutis laxa and pseudoxanthoma elasticum (PXE).⁶ The only drug known to induce EPS is D-penicillamine, a heavy metal chelator still commonly used in the treatment of Wilson disease (WD), cystinuria, rheumatoid arthritis or systemic sclerosis.^{1,7}

Pseudoxanthoma elasticum is an autosomal recessive disorder characterized by progressive mineralization and fragmentation of elastic fibers in various systems: skin (yellowish papules, "cobblestoning," and redundant folds in flexural areas), eyes (angioid streaks and retinal defects) and cardiovascular system (renovascular hypertension, angina pectoris, myocardial infarction, and stroke).⁸ Cutaneous manifestations resembling PXE without familiar history and *ABCC6* mutations have been identified as a D-penicillamine induced dermatopathy. These pseudoxanthoma elasticum-like skin changes are also known as pseudo-pseudoxanthoma elasticum.

The authors present a case of a D-penicillamine induced dermatopathy in a young adult female with WD treated for several years with D-penicillamine, that poses a difficult distinction between EPS and PPXE and is probably an association of both entities.

CASE PRESENTATION

A 17-year-old caucasian female patient affected with WD from the age of 5 and treated since then with D-penicillamine at daily doses ranging from 900 mg to 4 g. There were no hepatic or neurologic manifestations of WD. There was no relevant family history.

The patient was presented to our Dermatology department with a one year history of multiple, progressively appearing, asymptomatic papules located in the cervical region.

The clinical observation revealed multiple discrete, small, skin-colored to yellowish papules, some hyperkeratotic, others soft to palpation, distributed through the neck and in a smaller number, on the face (Fig 1). In addition, there was an atrophic lesion with a poorly defined arciform border and telangiectasia of about 1.5 cm located on the right cervical area (Fig. 2). No lesions were seen in other locations.

The patient was previously treated topically for *acne vulgaris* without any improvement.

Histopathology from an incisional skin biopsy on the cervical plaque revealed an acanthotic, hyperkeratotic epidermis; transepidermal elimination of numerous, branched, sawtooth-like elastic fibers; a mixed dermal inflammatory infiltrate and some multinucleated giant cells (Fig.s 3-4). These findings suggested a D-penicillamine induced dermatopathy. From the clinicopathological correlation a diagnosis of penicillamine-induced

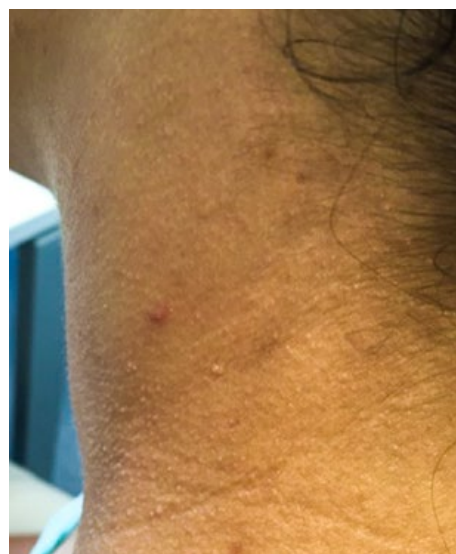

Figure 1 - Multiple discrete skin-colored papules in the neck.

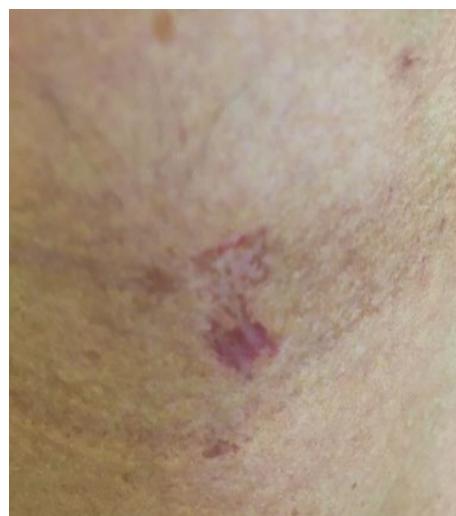

Figure 2 - Atrophic lesion with a poorly defined arciform border and telangiectasia on the right cervical area.

dermatosis consisting of mixed findings of EPS and PPXE was made.

Echocardiogram and ECG were normal. No other exams were performed due to the lack of symptomatic complaints or clinical findings.

D-penicillamine was switched to zinc acetate 50 mg 3 id with good control of WD.

At 1 year follow-up, however, cutaneous lesions still persist but no newer papules appeared.

DISCUSSION

Wilson disease is an autosomal recessive disorder caused by a mutation in the gene *ATP7B* that encodes a protein expressed on hepatocytes and involved in the excretion of copper into the bile.⁹ In WD copper is accumulated in the liver, brain and

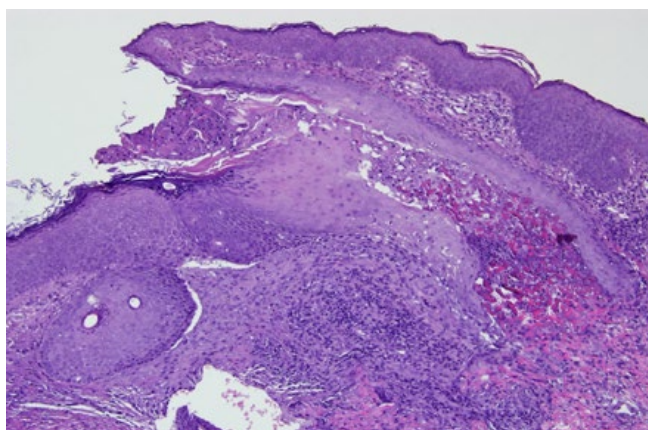


Figure 3 - H&E 100x - Acanthotic epidermis and transepidermal elimination of elastic fibers. Mixed dermal inflammatory infiltrate.

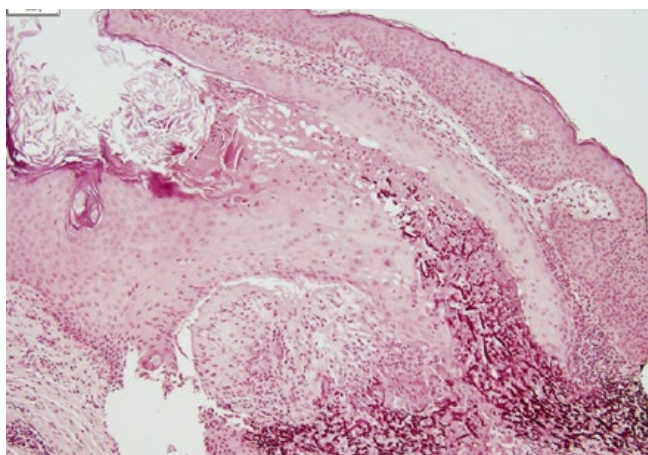


Figure 4 - Orcein staining of elastic fibers 100x - Transepidermal elimination of numerous, branched, sawtooth-like elastic fibers.

eye damaging these organs and causing potentially threatening complications.⁹

The D enantiomer of penicillamine is a well-known heavy metal chelator used as a therapeutic option in several different diseases like WD, cystinuria, rheumatoid arthritis or systemic sclerosis.¹ Although the clinical outcome is good, D-penicillamine is known to cause many adverse effects, both cutaneous and extracutaneous.¹ Approximately half the patients will have a side effect within the first 6 months and up to one-third will have to discontinue the drug.¹⁰ Cutaneous adverse effects are the most prevalent occurring in up to 50% of patients and leading to drug withdrawal in 10% of patients.¹¹ There are four types of penicillamine-induced dermatosis: 1) acute hypersensitive reactions, including urticaria; 2) dermatopathies characterized by elastic fibers abnormalities (like EPS and PPXE); 3) auto-immune disorders including bullous and connective tissue disorders and 4) miscellaneous dermatosis (lichen planus, psoriasisiform dermatitis, alopecia and nail changes).¹

About 1% of the patients treated with penicillamine for decades will develop EPS.¹²

The current theory is that D-penicillamine induces

abnormalities in elastic fibers similar to EPS and PPXE essentially by two mechanisms: 1) direct interference with tropocollagen cross-linking (this applies only to soluble collagen and not mature insoluble collagen which may explain why certain lesions take years to become apparent and others appear after the drug withdrawal); 2) inhibition of lysyl oxidase, a copper dependent enzyme that catalyses the cross-linking of elastic and collagen fibers.¹ These processes result in unstable elastic fibers that may be extruded in a foreign body reaction-like mechanism.^{2,7,12} This phenomenon can theoretically occur in any location with elastic fibers like the skin, lung, pharyngeal tissue, artery walls, joint capsules or cervical connective tissue.¹

Clinically EPS occurs as asymptomatic, erythematous to skin-colored, hyperkeratotic papules usually arranged in annular or serpiginous configuration that can occur anywhere on the body surface but are typically found in the neck and upper extremities.^{6,7} D-penicillamine induced EPS lesions are clinically indistinguishable from the idiopathic form of the disease.¹

Cutaneous findings of PPXE are clinically similar to those of PXE but there is neither a positive familiar history of the disease nor the presence of the mutations of the *ABCC6* gene.¹³ Also, there is an important histological difference: in PPXE there is no evidence of calcium deposition on the dermal elastic fibers, which is a critical factor in the pathogenesis of the disease.¹³ PPXE findings include a “plucked-chicken skin” appearance on the neck and in the axillae with excessive wrinkling and elastotic papules and redundant skin folds in flexural areas.¹³ The typical yellow discoloration of the PPXE and PXE lesions is due to the presence of elevated quantities of abnormal dermal elastic fibers.¹³

In the patient described there were some soft, yellowish papules similar to PPXE but other sites of involvement and redundant folds in flexural areas were lacking. Also, the “plucked-chicken skin” was not evident. On the other side, the hyperkeratotic skin-colored papules on the neck are suggestive of EPS. Although the traditional annular or serpiginous distribution was not present, there are reports of isolated papules on EPS cases.¹⁴ In our patient, we observed an atrophic plaque that may be a sequelar finding of an annular plaque. Before this, the authors considered that three diagnostic options were viable: atypical EPS, atypical PPXE or a combination of both. There are a few reports in the literature supporting this latter option.^{8,15,16}

The histopathology of these diseases are similar and usually show an acanthotic, hyperkeratotic epidermis with a mixed dermal inflammatory infiltrate and few giant cells.⁷ Atrophy of the skin can be found at the center of EPS lesions.⁷ Transepidermal perforating channels extend from the dermis and contain a mixture of eosinophilic elastic fibers, basophilic debris and inflammatory cells.² In drug induced EPS, elastic fiber stain shows thickened serrated morphology resulting in the typical “lumpy-bumpy” or “bramble-bush” pattern both in lesional and non-lesional skin.^{17,18}

EPS and PPXE lesions usually arise after several decades of D-penicillamine medication, have a chronic course and can even arise after drug withdrawal. Spontaneous resolution has been described several months after drug withdrawal.¹⁹ Although there is no effective treatment for D-penicillamine induced dermatopathies the best option seems drug suspension and

Caso Clínico

switch to another medication of the underlying disease.²⁰ For WD the main options are trientine or zinc, both with good results.⁹ In our patient the underlying WD remained well controlled with zinc acetate and no newer lesions appeared for one year. However, a few of the previously existing lesions remain.

In conclusion, we present this case of D-penicillamine induced dermatosis to illustrate the importance of recognition of these lesions, which may be subtle and usually asymptomatic and to highlight that due to the slow penicillamine metabolism, lesions can persist or even arise even after drug withdrawal. Although the association of true PXE and EPS is well recognized, the presence in the same patient of lesions clinically compatible with both EPS and PPXE induced by penicillamine is a rare event with few reports in the literature.

Conflitos de interesse: Os autores declaram não possuir conflitos de interesse.

Suporte financeiro: O presente trabalho não foi suportado por nenhum subsídio ou bolsa.

Confidencialidade dos dados: Os autores declaram ter seguido os protocolos do seu centro de trabalho acerca da publicação dos dados de doentes.

Proteção de pessoas e animais: Os autores declaram que os procedimentos seguidos estavam de acordo com os regulamentos estabelecidos pelos responsáveis da Comissão de Investigação Clínica e Ética e de acordo com a Declaração de Helsínquia da Associação Médica Mundial.

Conflicts of interest: The authors have no conflicts of interest to declare.

Financing Support: This work has not received any contribution, grant or scholarship.

Confidentiality of data: The authors declare that they have followed the protocols of their work center on the publication of data from patients.

Protection of human and animal subjects: The authors declare that the procedures followed were in accordance with the regulations of the relevant clinical research ethics committee and with those of the Code of Ethics of the World Medical Association (Declaration of Helsinki).

REFERÊNCIAS

1. Ishak R, Abbas O. Penicillamine revisited: historic overview and review of the clinical uses and cutaneous adverse effects. *Am J Clin Dermatol.* 2013;14:223-33.
2. Lewis KG, Bercovitch L, Dill SW, Robinson-Bostom L. Acquired disorders of elastic tissue: part I. Increased elastic tissue and solar elastotic syndromes. *J Am Acad Dermatol.* 2004;51:1-21; quiz 2-4.
3. Vearrier D, Buka RL, Roberts B, Cunningham BB, Eichenfield LF, Friedlander SF. What is standard of care in the evaluation of elastosis perforans serpiginosa? A survey of pediatric dermatologists. *Pediatr Dermatol.* 2006;23:219-24.
4. Langeveld-Wildschut EG, Toonstra J, van Vloten WA, Beemer FA. Familial elastosis perforans serpiginosa. *Arch Dermatol.* 1993;129:205-7.
5. Patterson JW. The perforating disorders. *J Am Acad Dermatol.* 1984;10:561-81.
6. Castro Pinho A, Cardoso JC, Gouveia M, Oliveira H. Elastose Perfurante serpiginosa e doença de wilson: uma consequencia rara, mas previsivel da terapeutica a longo prazo com D-penicilamina. *Acta Med Port.* 2016;29:227-30.
7. Hellriegel S, Bertsch HP, Emmert S, Schon MP, Haenssle HA. Elastosis perforans serpiginosa: a case of a penicillamine-induced degenerative dermatosis. *JAMA Dermatol.* 2014;150:785-7.
8. Rath N, Bhardwaj A, Kar HK, Sharma PK, Bharadwaj M, Bharija SC. Penicillamine induced pseudoxanthoma elasticum with elastosis perforans serpiginosa. *Indian J Dermatol Venereol Leprol.* 2005;71:182-5.
9. Ranucci G, Di Dato F, Leone F, Vajro P, Spagnuolo MI, Iorio R. Penicillamine-induced elastosis perforans serpiginosa in Wilson disease: is useful switching to zinc? *J Pediatr Gastroenterol Nutr.* 2017;64:e72-e73
10. Shiokawa Y, Horiuchi Y, Honma M, Kageyama T, Okada T, Azuma T. Clinical evaluation of D-penicillamine by multicentric double-blind comparative study in chronic rheumatoid arthritis. *Arthritis Rheum.* 1977;20:1464-72.
11. Bialy-Golan A, Brenner S. Penicillamine-induced bullous dermatoses. *J Am Acad Dermatol.* 1996;35:732-42.
12. Tovar S, Parlatescu I, Dumitriu AS, Bucur A, Kaplan I. Oral complications associated with D-penicillamine treatment for Wilson disease: a clinicopathologic report. *J Periodontol.* 2010;81:1231-6.
13. Bolognia JL, Braverman I. Pseudoxanthoma-elasticum-like skin changes induced by penicillamine. *Dermatology.* 1992;184:12-8.
14. Bennett JA, Clarke JT, Ioffreda MD. Annular keratotic papules on the extremities. *J Am Acad Dermatol.* 2015;73:891-3.
15. Becuwe C, Dalle S, Ronger-Savle S, Skowron F, Balme B, Kanitakis J, et al. Elastosis perforans serpiginosa associated with pseudo-pseudoxanthoma elasticum during treatment of Wilson's disease with penicillamine. *Dermatology.* 2005;210:60-3.
16. Meyrick Thomas RH, Kirby JD. Elastosis perforans serpiginosa and pseudoxanthoma elasticum-like skin change due to D-penicillamine. *Clin Exp Dermatol.* 1985;10:386-91.
17. Bergman R, Friedman-Birnbaum R, Ludatscher R, Lichtig C. An ultrastructural study of the reactive type of elastosis perforans serpiginosa. *Arch Dermatol.* 1987;123:1127-9.
18. Bardach H, Gebhart W, Niebauer G. "Lumpy-bumpy" elastic fibers in the skin and lungs of a patient with a penicillamine-induced elastosis perforans serpiginosa. *J Cutan Pathol.* 1979;6:243-52.
19. Deguti MM, Mucenic M, Cancado EL, Tietge UJ. Elastosis perforans serpiginosa secondary to D-penicillamine treatment in a Wilson's disease patient. *Am J Gastroenterol.* 2002;97:2153-4.
20. Wang D, Liang J, Xu J, Chen L. Effective treatment of d-penicillamine induced elastosis perforans serpiginosa with ALA-PDT. *Photodiagnosis Photodyn Ther.* 2015;12:140-2.