

Neurotequeoma Celular em Criança: Descrição de um Caso Involgar e Breve Revisão da Literatura

Eugénia Matos Pires¹, Rodrigo Carvalho², André Lencastre², Maria João Paiva Lopes³

¹Interna do Internato Complementar de Dermatologia e Venereologia / Resident, Dermatology and Venereology, Centro Hospitalar de Lisboa Central, Hospital de Santo António dos Capuchos, Lisboa, Portugal

²Assistente Hospitalar de Dermatologia e Venereologia / Consultant Dermatology and Venereology, Centro Hospitalar de Lisboa Central, Hospital de Santo António dos Capuchos, Lisboa, Portugal

³Assistente Hospitalar Graduada de Dermatologia e Venereologia / Graduate Consultant Dermatology and Venereology, Centro Hospitalar de Lisboa Central, Hospital de Santo António dos Capuchos, Lisboa, Portugal

RESUMO – O neurotequeoma é uma neoplasia benigna, rara, cuja histiogénese permanece incerta. Os avanços nos estudos com a imunohistoquímica, no entanto, permitiriam o reconhecimento de uma possível origem na linhagem fibrohistiocitária. Histopatologicamente são reconhecidas três variantes de acordo com a quantidade de matriz mixóide e com a análise imunohistoquímica: mixóide, celular ou misto. Os raros casos reportados, localizaram-se sobretudo na cabeça, pescoço e membros superiores, em mulheres jovens. Na revisão da literatura não há referência às características dermatoscópicas do neurotequeoma. Neste contexto, descrevemos o caso involgar de um neurotequeoma celular, localizado na axila de uma criança de 7 anos, do sexo feminino, e respectivos achados dermatoscópicos.

PALAVRAS-CHAVE – Criança; Dermoscopia; Neurotequeoma.

An Unusual Case of Cellular Neurothekeoma in a Child: Case Report and Brief Review of Literature

ABSTRACT – Neurothekeoma is a rare benign neoplasm of uncertain histogenesis. Progresses in immunohistochemistry have brought new insights into its cellular differentiation and origin, recognizing the possibility of a fibrohistiocytic lineage. Also, it has been subclassified histopathologically as either myxoid, cellular, or mixed type, depending on the amount of myxoid matrix and on immunohistochemical analysis. Few cases of cellular neurothekeoma have been reported. Most of them are found on the head, neck and upper extremities and mostly in young female adults. On review of literature we have not found reports regarding dermoscopic features of neurothekeoma. Herein we report an uncommon case of cellular neurothekeoma on the axilla of a 7-year-old girl, with description of its dermoscopic findings.

KEYWORDS – Child; Dermoscopy; Neurothekeoma.

INTRODUCTION

Cellular neurothekeoma (CNT) is a distinctive, uncommon and benign dermal neoplasm.¹ The term CNT was first introduced in by Rosati *et al*,² to describe a variant of neurothekeoma with high cellularity in a very sparse myxoid matrix. Two other variants of neurothekeoma have been described, according on the amount of myxoid matrix: mixed and myxoid.³ In this setting it is of outmost importance to distinguish between

myxoid NT, and CNT, which are unrelated. The former, also termed “nerve sheath myxoma” have a strong predilection for the extremities (mainly fingers), is characterized by a well circumscribed proliferation of spindle cells in a background of abundant myxoid stroma, in which ultrastructural and immunohistochemistry studies have been favored an origin from neuronal cells, staining consistently for S-100 protein and other neural markers namely glial fibrillary acidic

Correspondência: Eugénia Matos Pires
Hospital dos Capuchos, Serviço de Dermato-Venereologia
Alameda Santo António dos Capuchos
1169-050 Lisboa, Portugal
Email: eugeniamp@gmail.com
DOI: <https://dx.doi.org/10.29021/spdv.76.1.807>

Recebido/Received
22 Setembro/September 2017
Aceite/Accepted
24 Novembro/November 2017

Caso Clínico

protein (GFAP).^{4,5} On the other hand, CNT usually occurs as an asymptomatic pink or red-brown, dome-shaped, solitary papule or nodule. Nevertheless multiple lesions were described in two patients.³ It is mainly located on the face (nose, cheeks and chin), neck, arms and shoulders of children and young adults, and is more frequent in females.^{1,3,6} The histogenesis of CNT remains enigmatic.⁷ Formerly, it was considered a nerve sheath tumor. However, there is no unequivocal evidence for neuroectodermal derivation.¹ A case of CNT expressing both PG-M1 and KP-1(CD68), reliable markers of histiocytic differentiation, led to speculation that these tumors were of fibrohistiocytic lineage.⁸ Latter, in a review, Jaffer S *et al*⁵ found that more than half of CNT stained for CD68, reinforcing the previous conception. Histopathological examination shows a multilobular pattern with cellular nests, fibrous stroma on the superficial or reticular dermis, and sometimes in subcutis. The tumor consists of nests and fascicles of epithelioid and short spindle-shaped eosinophilic cells with vesicular nuclei.⁹ The histopathological pattern may resemble other conditions namely neuronal and melanocytic lesions. Therefore, the immunohistochemistry panel is crucial for the differential diagnosis. CNT are consistently negative for neural markers such as S-100 protein and also for CD57 and EMA (5). CNT stain for PGP 9.5, S-100A6 protein and NKI-C3.⁹⁻¹¹ Of note mixed NT characterized by a histopathological pattern that is

an intermediate between NTC and myxoid NT (5).

The scarcity of cases may explain why the dermoscopy features have rarely been described.¹²

CASE REPORT

We report a case of a 7-year-old girl, whose medical history was unremarkable and presented with a 1 year history of an asymptomatic red-pink nodule on the left axilla. A well circumscribed erythematous, firm, non-tender, nodule with 1 cm diameter was seen on the anterior pillar of the left axilla (Fig. 1). Dermoscopy revealed a whitish and yellow patch on an erythematous homogeneous background (Fig. 2). There was no previous history of trauma or inflammatory dermatitis and physical examination was otherwise unremarkable. Our clinical impressions included: dermatofibroma, insect bite, granulomatous reaction, skin adnexal tumor and keloid/scar. Complete excision was performed. Histopathological examination revealed a dermal tumour composed of collagen encircled nests of spindle and epithelioid cells with ample clear cytoplasm, and vesicular nuclei with light pleomorfism (Fig. 3). Immunohistochemistry was positive for vimentin and negative for S100, Melan A, HMB – 45, EMA and SMA. (Fig. 4). These findings were compatible with CNT. After 1 year of follow-up, the patient remained asymptomatic without recurrence and excellent healing process.

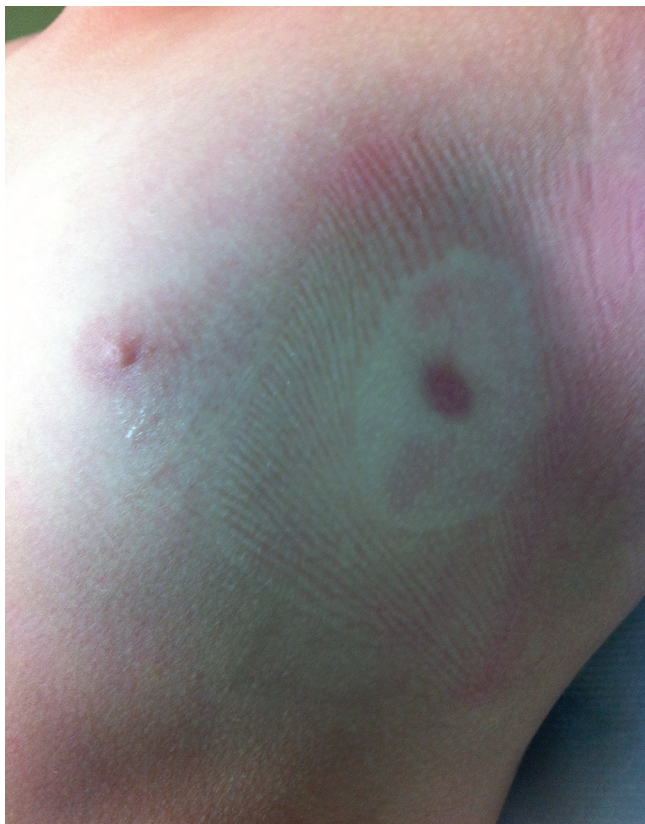

Figure 1

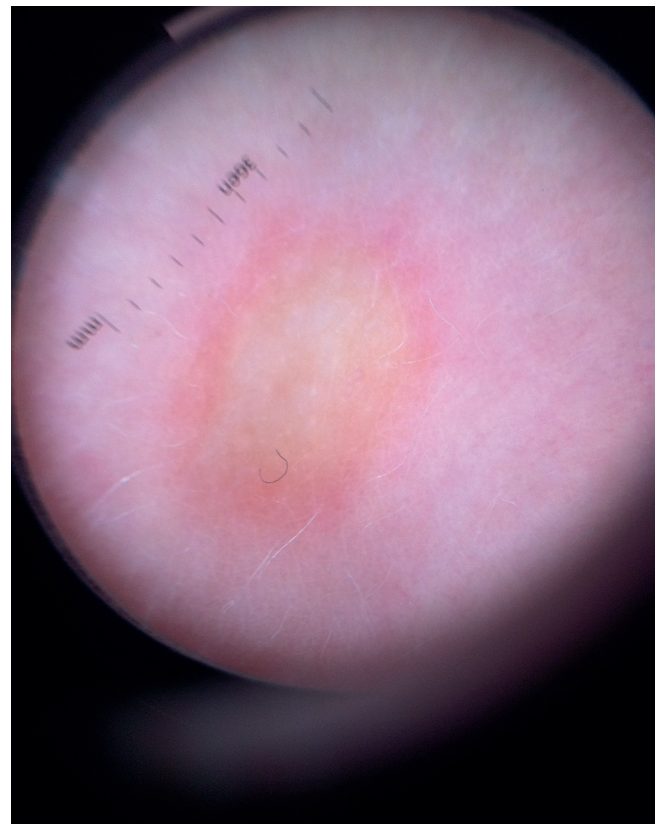

Figure 2

Caso Clínico

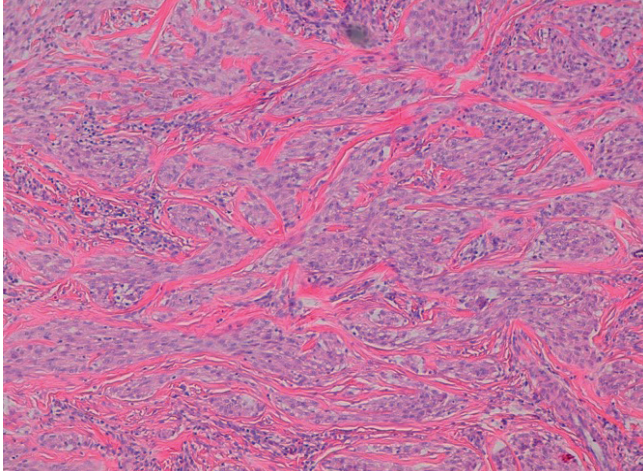


Figure 3

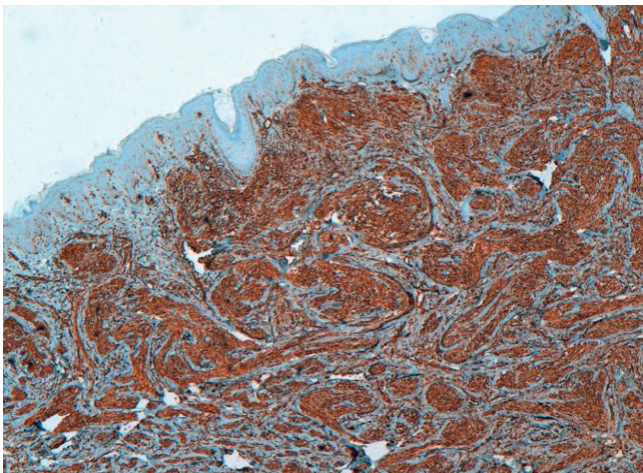


Figure 4

DISCUSSION

Cellular neurothekeoma is an infrequent, dermal tumor with a two-fold female predominance.¹ It is more common in the second decade of life, with a mean age of 25 years.¹ Only 24% occur in patients aged under 10, and 20% in patients above 30 years of age.³ It is commonly located on the arms (35%), head and neck (33%), legs (17%) and trunk (15%). To date, only one case has been previously reported on axilla.¹ Clinically, it manifests as an asymptomatic, erythematous papule or nodule, with a slow growth rate.¹³ The differential clinical diagnosis is broad, including benign and malignant neoplasms, as well as inflammatory reactions, e.g: epidermal cyst, nevus, dermatofibroma, adnexal tumor, basal cell carcinoma, amelanotic melanoma, cutaneous metastasis, hemangioma, insect bite, granulomatous reaction and keloid/scar.³

In the present case, dermoscopic findings included an erythematous homogenous area surrounding a white-yellow

patch, with striking similarity to those that has been described for other tumors of fibrohistiocitary origin, such as dermatofibroma.^{14,15}

It is remarkable that in great series conducted by different authors^{1,3} the clinical diagnosis of CNT was never suspected, whereby the final diagnosis was histologic. Nevertheless, considering its wide differential clinical diagnosis (with malignant and benign conditions) the histopathological examination and immunohistochemistry remain crucial for a definitive diagnosis of CNT. Few studies have evaluated the prognosis of CNT. The risk of recurrence of CNT is somewhere around 3%, but metastases were never described.² Thereby, complete excision of CNT with free margins is the treatment of choice.

CONCLUSION

Although uncommon, CNT is a diagnosis to be considered in children with a pinkish, brown nodule, with slow progression even in an atypical location, such as the axilla. Histology remains the cornerstone for the definitive diagnosis of the tumor. The authors encourage publication of new cases of CNT with dermoscopic findings in order to improve the description of a common pattern that could be helpful in clinical recognition of this entity.

Conflitos de interesse: Os autores declaram não possuir conflitos de interesse.

Suporte financeiro: O presente trabalho não foi suportado por nenhum subsídio ou bolsa.

Confidencialidade dos dados: Os autores declaram ter seguido os protocolos do seu centro de trabalho acerca da publicação dos dados de doentes.

Proteção de pessoas e animais: Os autores declaram que os procedimentos seguidos estavam de acordo com os regulamentos estabelecidos pelos responsáveis da Comissão de Investigação Clínica e Ética e de acordo com a Declaração de Helsínquia da Associação Médica Mundial

Conflicts of interest: The authors have no conflicts of interest to declare.

Financing Support: This work has not received any contribution, grant or scholarship.

Confidentiality of data: The authors declare that they have followed the protocols of their work center on the publication of data from patients.

Protection of human and animal subjects: The authors declare that the procedures followed were in accordance with the regulations of the relevant clinical research ethics committee and with those of the Code of Ethics of the World Medical Association (Declaration of Helsinki).

REFERENCES

1. Hornick JL, Fletcher CD. Cellular neurothekeoma: detailed characterization in a series of 133 cases. *Am J Surg Pathol.* 2007;31:329-40.
2. Rosati LA, Fratamico FC, Eusebi V. Cellular neurothekeoma. *Appl Pathol.* 1986;4:186-91.

Caso Clínico

- Fetsch JF, Laskin WB, Hallman JR. Neurothekeoma: an analysis of 178 tumors with detailed immunohistochemical data and long-term patient follow-up information. *Am J Surg Pathol.* 2007;31:1103-14.
- Fetsch JF, Laskin WB, Miettinen M. Nerve sheath myxoma: a clinicopathologic and immunohistochemical analysis of 57 morphologically distinctive, S-100 protein- and GFAP-positive, myxoid peripheral nerve sheath tumors with a predilection for the extremities and a high local recurrence rate. *Am J Surg Pathol.* 2005; 29: 1615-24.
- Jaffer S, Ambrosini-Spaltro A, Mancini AM, Eusebi V, Rosai J. Neurothekeoma and plexiform fibrohistiocytic tumor: mere histologic resemblance or histogenetic relationship? *Am J Surg Pathol.* 2009; 33: 905-13.
- Barnhill RL, Dickersin GR, Nickleit V, Bhan AK, Muhlbauer JE, Phillips ME, et al. Studies on the cellular origin of neurothekeoma: clinical, light microscopic, immunohistochemical, and ultrastructural observations. *J Am Acad Dermatol.* 1991;25:80-8.
- Calonje E, Wilson-Jones E, Smith NP, Fletcher CD. Cellular 'neurothekeoma': an epithelioid variant of pilar leiomyoma? Morphological and immunohistochemical analysis of a series. *Histopathology.* 1992;20:397-404.
- Misago N, Satoh T, Narisawa Y. Cellular neurothekeoma with histiocytic differentiation. *J Cutan Pathol.* 2003; 30:196-201.
- McKee PH, Calonje E, Granter SR. Pathology of the skin with clinical correlations. Philadelphia: Elsevier Mosby; 2005.
- Wang GY, Nazarian RM, Zhao L, Hristov AC, Patel RM, Fullen DR, et al. Protein gene product 9.5 (PGP9.5) expression in benign cutaneous mesenchymal, histiocytic, and melanocytic lesions: comparison with cellular neurothekeoma. *Pathology.* 2017; 49 :44-9.
- Plaza JÁ Torres-Cabala C, Evans H, Diwan AH Prieto VG. Immunohistochemical expression of S100A6 in cellular neurothekeoma: clinicopathologic and immunohistochemical analysis of 31 cases. *Am J Dermatopathol.* 2009; 31: 419-22
- Aydingoz IE, Mansur AT, Dikicioglu-Cetin E. Arborizing vessels under dermoscopy: A case of cellular neurothekeoma instead of basal cell carcinoma. *Dermatol Online J.* 2013;19: 5.
- Papadopoulos EJ, Cohen PR, Hebert AA. Neurothekeoma: report of a case in an infant and review of the literature. *J Am Acad Dermatol.* 2004; 50:129-34.
- Ferrari A, Soyer HP, Peris K, Argenziano G, Mazzocchetti G, Piccolo D et al. Central white scarlike patch: a dermoscopic clue for the diagnosis of dermatofibroma. *J Am Acad Dermatol.* 2000; 43:1123-5.
- Karaarslan KI, Gencoglan G, Akalin T, Ozdemir F. Different dermoscopic faces of dermatofibromas. *J Am Acad Dermatol.* 2007; 57:401-6.