

Caso Clínico

Erupção Acneiforme Refratária Reveladora de Doença de Behçet: A Propósito de um Caso Clínico com Resposta Tardia mas Eficaz ao Adalimumab

Júlia Vide¹; Sofia Lopes¹; Sofia Magina^{1,2}; Filomena Azevedo¹

¹Serviço de Dermatologia e Venereologia, Centro Hospitalar de São João EPE, Porto, Portugal

²Faculdade de Medicina da Universidade do Porto, Portugal

RESUMO – A doença de Behçet é uma vasculite sistémica crónica e recidivante que pode levar a um aumento significativo da morbidade e mortalidade. Após superar o desafio em fazer o seu diagnóstico atempado, que muitas vezes se impõe, surge a dificuldade no seu tratamento.

Relata-se um caso de um doente que se apresentou com uma erupção acneiforme reveladora de doença de Behçet, refratária à terapia convencional, que respondeu mais tarde e completamente, ao adalimumab.

Na literatura científica, embora faltem ensaios clínicos controlados e randomizados, há já evidência significativa que suporta o papel dos agentes anti-TNF como um importante avanço terapêutico na doença de Behçet, particularmente em casos graves, refratários ou intolerantes à imunossupressão clássica.

PALAVRAS-CHAVE – Adalimumab; Erupções Acneiformes; Factor de Necrose Tumoral alfa /antagonistas & inibidores; Síndrome de Behçet.

Recalcitrant Acneiform Eruption Revealing Behçet's Disease: A Case with Late but Successful Response to Adalimumab

ABSTRACT – Behçet's disease is a systemic vasculitis with a chronic-relapsing course, which can lead to significant morbidity and mortality. From the often-compelling challenge of making a prompt diagnosis comes the difficulty in its treatment.

We report the case of a patient with an acneiform skin eruption revealing Behçet's disease that was refractory to conventional therapy and later completely responded to adalimumab.

Although randomized controlled clinical trials are lacking in the literature, there is already significant evidence supporting anti-TNF agents as a major therapeutic advance in Behçet's disease, particularly in cases that are severe, refractory or intolerant to classical immunosuppression.

KEYWORDS – Acneiform Eruptions; Adalimumab; Tumor Necrosis Factor-alpha/antagonists & inhibitors; Behçet Syndrome.

BACKGROUND

Behçet's disease (BD) has a wide clinical spectrum along different degrees of severity. The main clinical manifestations include recurrent oral and genital ulcers, skin lesions and uveitis, but practically all organs can be affected. There are no clinical or laboratory findings pathognomonic of BD, therefore the diagnosis is based on clinical criteria after exclusion of other conditions.^{1,2}

BD is associated with significant morbidity and mortality, especially when there is neurological, cardiovascular, gastrointestinal or ophthalmic involvement, the latter potentially leading to vision loss.³ Poorer prognosis is related to male gender, young age at diagnosis, positive HLA-B51, arterial involvement and frequent outbreaks.³⁻⁵ The therapeutic approach depends on the clinical presentation and its severity. Insufficient or total lack of disease activity control

Correspondência: Júlia Vide
Alameda Prof. Hernâni Monteiro
4200-319 Porto, Portugal
Email: juliavide@gmail.com
DOI: <https://dx.doi.org/10.29021/spdv.75.4.759>

Recebido/Received
08 Junho/June 2017
Aceite/Accepted
03 Outubro/October 2017

Caso Clínico

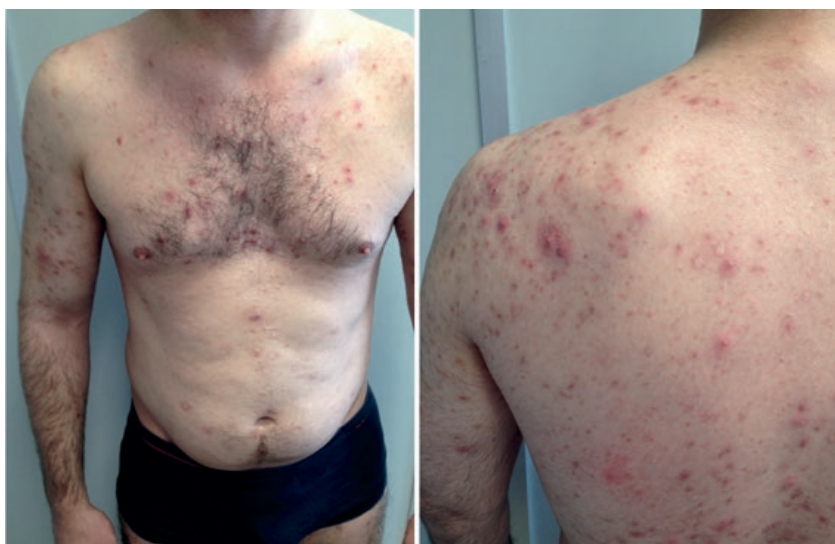

Figure 1 - Papulo-pustular lesions and atrophic scars on the trunk and limbs.

with conventional immunosuppressive therapy represents a need for new drugs. With the discovery of TNF- α as a central inflammatory mediator in BD, anti-TNF agents, mainly infliximab and adalimumab, have been used with promising results concerning efficacy and safety.⁶⁻⁸

CASE REPORT

A 31-year-old Caucasian man, with no relevant medical history, was referred to the Dermatology department with papulo-pustular lesions and atrophic scars on the trunk and limbs that were present for one year, unresponsive to minocycline and partially responsive to oral prednisone 0.5 mg/kg/day (Fig.1). Blood test results were unremarkable, with negative autoimmune and viral serologies. Skin histopathology from one of these lesions in the back performed eight months previously suggested *pityriasis lichenoides et varioliformis acuta* (PLEVA) but there was no clinical evidence of this diagnosis. Skin biopsy

was repeated and histopathologic evaluation disclosed a deep folliculitis rich in neutrophils with vascular involvement, with no observable microorganisms (Fig. 2).

The patient showed partial improvement with oral prednisolone 0.5 mg/kg/day and lack of response to dapsone 50 mg/day, introduced during the corticoid tapering once the biopsy was compatible with a neutrophilic dermatosis. It was suspended four months later due to the lack of response and the onset of anemia when the dose was increased to 100 mg/day, one month after the beginning of dapsone. Prednisolone was always maintained and adjusted according to the clinical state. Two months after stopping dapsone, the number of skin lesions increased and worsened, some of them exhibiting central necrosis. During this time, the patient struggled with a very slowly healing of a post-traumatic wound on the nasal bridge, which led us to perform a pathergy test, with a positive result. When questioned, the patient confirmed previously

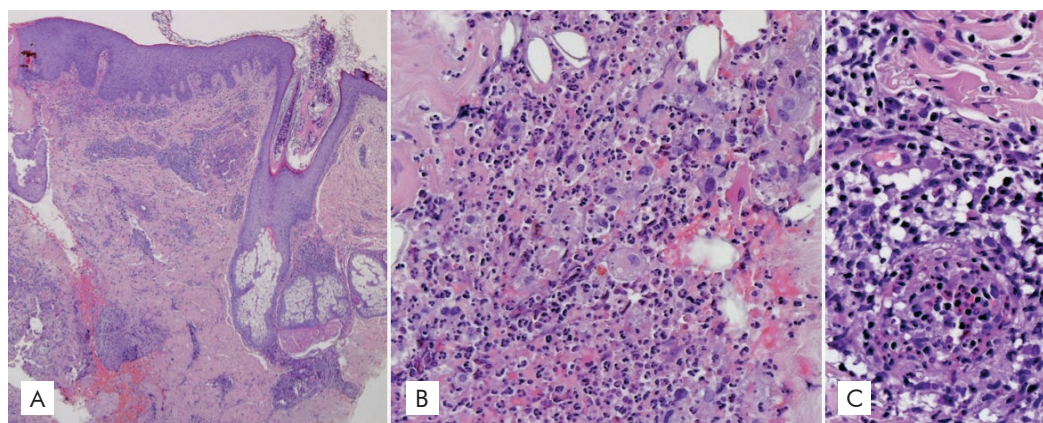


Figure 2 - Histology: deep folliculitis rich in neutrophils with accompanying vasculitis. A) Hematoxylin-eosin original magnification $\times 40$; B) Hematoxylin-eosin original magnification $\times 200$; C) Hematoxylin-eosin original magnification $\times 400$.

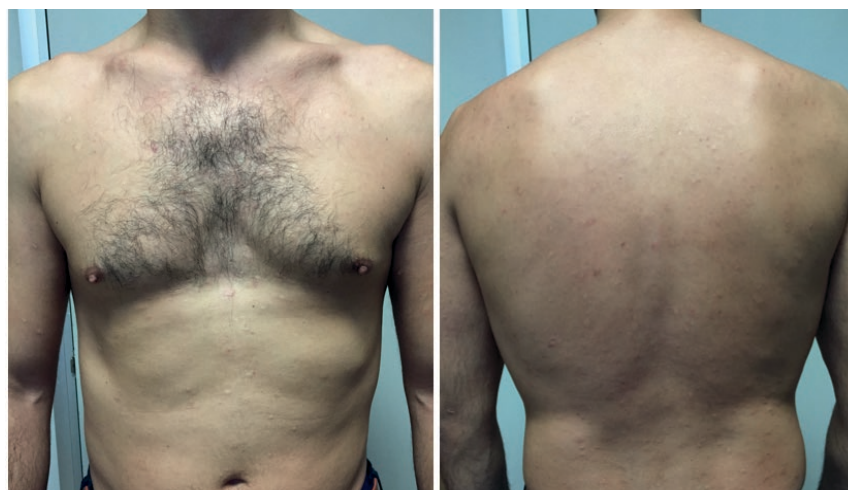


Figure 3 - Complete and sustained remission with adalimumab treatment.

devalued episodes of oral and genital ulcers for more than five years, which resolved in a few days, with no scars, and occurred nearly five times per year, hence gathering criteria for the diagnosis Behçet Disease, according to the International Criteria for Behçet Disease (ICBD).² During the subsequent six months' follow-up, four additional episodes of oral aphthosis were identified and a left knee oligoarthritis was detected. Arthritis and widespread deep folliculitides of the skin were the most limiting signs. No response was seen with colchicine 2 mg/day. Prednisolone 0.5 mg/kg/day provided only partial improvement. A trial of azathioprine 50 mg/day had to be quickly suspended after severe hepatotoxicity. Subcutaneous adalimumab 40mg biweekly was then introduced, with a slow and gradual improvement, allowing corticosteroid suspension four months later. Complete remission was achieved six months after starting adalimumab and remission remains after 24 months of follow-up on continuous therapy (Fig. 3).

DISCUSSION

There are still some difficulties in establishing an exact diagnosis of BD, because of its widely variable clinical presentations and limited diagnostic tests. Prompt recognition of the diverse dermatological aspects that, although unspecific per se, may suggest BD when in association, can be an important clue to an early diagnosis. In addition to oral and genital aphthosis, erythema nodosum, papulo-pustular lesions and the presence of pathergy are considered major diagnostic criteria of BD.^{1,2}

Papulo-pustular lesions, folliculitis, pseudofolliculitis and acneiform eruption are all terms that have been applied for the same type of lesion, which is polymorphous in nature, and one of the most common findings in BD, reported in 28% – 96% of cases.⁹ However, since these lesions may be confused with acne vulgaris, some authorities do not recommend using papulo-pustular lesions for diagnostic criteria.¹⁰ Still, these lesions may hold additional features that might be helpful to enhance their specificity: post-puberty onset under no steroid treatment, systemic symptoms, widespread distribution affecting face,

limbs, trunk and buttocks, cutaneous ulcers healing with scar formation and neutrophilic non-follicular or vasculitic lesions on histopathology.⁹⁻¹¹

Current evidence suggests that early treatment may, to some extent, control and perhaps change the course of BD.^{2,3,7} The new ICBD, derived from multinational data, exhibit much improved sensitivity over the previously used International Study Group of Behçet Disease criteria (ISGBD) (93.9% vs 81.2%), while maintaining reasonable specificity (92.1% vs 95.9%). It allows the early recognition and referral to expert centres, thus leading to prompt diagnosis and treatment, with salutary results. According to the ICBD, a patient scoring 4 or more points is classified as having BD. Ocular lesions, oral aphthosis and genital ulcers are assigned 2 points each, while skin lesions, central nervous system involvement, vascular manifestations and a positive pathergy test are assigned 1 point each.²

The aim of the therapeutic strategy in BD is to induce and maintain remission in order to minimize potential irreversible damage and improve patients' quality of life. Treatment selection is based on the organ involved and on the assessment of its severity. Based largely on case reports and isolated observations, systemic therapy including corticosteroids, colchicine, dapsone, azathioprine, methotrexate, cyclosporine, cyclophosphamide, mycophenolate mofetil and thalidomide has been used. Nevertheless, a few patients have relapses, exhibit life-threatening events, develop disease-related complications or present side-effects to standard immunosuppressive agents. In these conditions, TNF- α antagonism emerges as a valid option.⁶⁻⁸

Anti-TNF therapy has been shown to be effective, with sustained efficacy and safety in more than 85% of severe or refractory BD manifestations, significantly increasing remissions and decreasing corticosteroid prescription.^{7,8} Reportedly, when introduced later in the disease course, response to anti-TNF drugs is weaker, especially in the setting of ophthalmic damage, which may be irreversible.^{12,13}

Caso Clínico

Even though most of the experience with anti-TNF inhibition in BD derives from infliximab, adalimumab seems to have similar efficacy and safety profile.^{7,8} In addition, a recent paper has showed successful treatment of 17 BD patients with predominant mucocutaneous lesions, when switched from infliximab to adalimumab.¹⁴ Late response to anti-TNF, as in the above mentioned case has been described, although not usual.¹⁵ Recent studies emphasize that Th17 cells also have a significant role in BD, presenting as an additional possible therapeutic target.¹⁰

Our patient presented with an acneiform eruption, while undervaluing the preceding manifestations of his BD (i.e. episodes of oral and genital ulcerations) and these were therefore undisclosed spontaneously. A few acne vulgaris-directed therapies were initially tried but failed, raising clinical suspicion of BD. Clinician's should therefore be aware of isolated acneiform eruptions as a presenting form of BD and include BD in the differential of acne-vulgaris, while referring to particular features that suggest the former diagnosis. Regarding BD treatment, although randomized controlled clinical trials are lacking, there is already significant evidence supporting anti-TNF inhibition as a major therapeutic advance, particularly in severe or refractory disease, in patients who are intolerant to classical immunosuppression and in patients with BD manifestations that significantly reduce their quality of life.

Conflitos de interesse: Os autores declaram não possuir conflitos de interesse.

Suporte financeiro: O presente trabalho não foi suportado por nenhum subsídio ou bolsa.

Confidencialidade dos dados: Os autores declaram ter seguido os protocolos do seu centro de trabalho acerca da publicação dos dados de doentes.

Protecção de pessoas e animais: Os autores declaram que os procedimentos seguidos estavam de acordo com os regulamentos estabelecidos pelos responsáveis da Comissão de Investigação Clínica e Ética e de acordo com a Declaração de Helsinquia da Associação Médica Mundial

Conflicts of interest: The authors have no conflicts of interest to declare.

Financing Support: This work has not received any contribution, grant or scholarship.

Confidentiality of data: The authors declare that they have followed the protocols of their work center on the publication of data from patients.

Protection of human and animal subjects: The authors declare that the procedures followed were in accordance with the regulations of the relevant clinical research ethics committee and with those of the Code of Ethics of the World Medical Association (Declaration of Helsinki).

REFERENCES

1. International Study Group Behçet's Disease. Criteria for diagnosis of Behçet's disease. *Lancet*. 1990; 335:1078-80.
2. International Team for the Revision of the International Criteria for Behçet's Disease (ITR-ICBD). The International Criteria for Behçet's Disease (ICBD): a collaborative study of 27 countries on the sensitivity and specificity of the new criteria. *J Eur Acad Dermatol Venereol*. 2014; 28:338-47.
3. Kural-Seyahi E, Fresko I, Seyahi N, Ozyazgan Y, Mat C, Hamuryudan V, et al. The long-term mortality and morbidity of Behçet syndrome: a 2-decade outcome survey of 387 patients followed at a dedicated center. *Medicine*. 2003; 82:60-76.
4. Krause I, Uziel Y, Guedj D, Mukamel M, Molad Y, Amit M, et al. Mode of presentation and multisystem involvement in Behçet's disease: the influence of sex and age of disease onset. *J Rheumatol*. 1998; 25:1566-9.
5. Saadoun D, Wechsler B, Desseaux K, Le Thi Huong D, Amoura Z, Resche-Rigon M, et al. Mortality in Behçet's disease. *Arthritis Rheum*. 2010; 62:2806-12.
6. Sfikakis PP. Behçet's disease: a new target for anti-tumor necrosis factor treatment. *Ann Rheum Dis*. 2002; 61:51-3.
7. Arida A, Fragiadaki K, Giavri E, Sfikakis PP. Anti-TNF agents for Behçet's disease: analysis of published data on 369 patients. *Semin Arthritis Rheum*. 2011; 41:61-70.
8. Vallet H, Riviere S, Sanna A, Deroux A, Moulis G, Addimanda O, et al. Efficacy of anti-TNF alpha in severe and/or refractory Behçet's disease: Multicenter study of 124 patients. *J Autoimmun*. 2015; 62:67-74.
9. Mendes D, Correia M, Barbedo M, Vaio T, Mota M, Gonçalves O, et al. Behçet's disease-a contemporary review. *J Autoimmun*. 2009; 32:178-88.
10. Kalkan G, Karadag AS, Astarci HM, Akbay G, Ustun H, Eksioglu M. A histopathological approach: when papulopustular lesions should be in the diagnostic criteria of Behçet's disease? *J Eur Acad Dermatol Venereol*. 2009; 23:1056-60.
11. Cho S, Kim J, Cho SB, Zheng Z, Choi MJ, Kim DY, et al. Immunopathogenic characterization of cutaneous inflammation in Behçet's disease. *J Eur Acad Dermatol Venereol*. 2014; 28:51-7.
12. Levy-Clarke G, Jabs DA, Read RW, Rosenbaum JT, Vitale A, Van Gelder RN. Expert panel recommendations for the use of anti-tumor necrosis factor biologic agents in patients with ocular inflammatory disorders. *Ophthalmology*. 2014;121:785-96.
13. Hatemi G, Silman A, Bang D, Bodaghi B, Chamberlain AM, Gul A, et al. EULAR recommendations for the management of Behçet disease. *Ann Rheum Dis*. 2008; 67:1656-62.
14. Olivieri I, Leccese P, D'Angelo S, Padula A, Nigro A, Pallazzi C, et al. Efficacy of adalimumab in patients with Behçet's disease unsuccessfully treated with infliximab. *Clin Exp Rheumatol*. 2011; 29:S54-7.
15. Aikawa NE, Gonçalves C, Silva CA, Gonçalves C, Bonfá E, de Carvalho JF. Late response to anti-TNF- α therapy in refractory mucocutaneous lesions of Behçet's disease. *Rheumatol Int*. 2011; 31:1097-9.