

Revista SPDV 71(2) 2013; Felipe Ladeira de Oliveira, Deborah Maria Brito Sírío, Gisele Cerutti, et cols;
Sarcoma de Kaposi associado à Síndrome de Reconstituição Imune.

Caso Clínico

SÍNDROME DE RECONSTITUIÇÃO IMUNE: UM OBSTÁCULO EM POTENCIAL NO MANEJO DO SARCOMA DE KAPOSI EM PACIENTES HIV POSITIVOS? – RELATO DE CASO

Felipe Ladeira de Oliveira¹, Deborah Maria Brito Sírío², Gisele Cerutti³, Natallia Barreiros de Natividade⁴, Vinicius Martins de Menezes⁵, Alice Miranda⁶, Luna Azulay-Abulafia⁷, José Augusto da Costa Nery⁸

¹⁻⁴Department of STDs and Leprosy, Instituto de Dermatologia Professor Rubem David Azulay (IDPRDA)

⁵MD - Fundação Oswaldo Cruz, FIOCRUZ, Rio de Janeiro, Brazil

⁶MD, PhD Leprosy Laboratory, Oswaldo Cruz Institute, FIOCRUZ, Brazil

^{7,8}MD PhD - Instituto de Dermatologia Professor Rubem David Azulay (IDPRDA), Institution: Instituto de Dermatologia Professor Rubem David Azulay (IDPRDA), Santa Casa da Misericórdia, Rio de Janeiro, Brazil

RESUMO – A diversidade de apresentações clínicas da síndrome de reconstituição imune faz da mesma um desafio clínico, na medida em que é difícil o manejo de infecções oportunistas e outras condições clínicas relacionadas com tal síndrome. A relevância da mencionada síndrome o Sarcoma de Kaposi após o início da terapia antiretroviral é notável, principalmente em países que possuem altos níveis de transmissão de doenças sexualmente transmissíveis e HIV. Desta forma, clínicos e dermatologistas devem estar atentos para identificar sinais e sintomas dessa progressão neoplásica e diferenciá-los do Sarcoma de Kaposi relacionado à síndrome de reconstituição imune de acordo com os critérios de classificação recentes da doença. Vital mencionar que terapia anti-retroviral não deve ser interrompida na maioria dos casos.

PALAVRAS-CHAVE – Infecção por VIH; Sarcoma de Kaposi; HAART.

IMMUNE RECONSTITUTION INFLAMMATORY SYNDROME: A POTENTIAL PITFALL IN THE MANAGEMENT OF KAPOSI'S SARCOMA IN HIV POSITIVE PATIENTS? – A CASE REPORT

ABSTRACT – The variety of immune reconstitution inflammatory syndrome's (IRIS) clinical presentations makes this syndrome a challenge, in that it is difficult to manage opportunistic infections and other serious clinical conditions related to the manifestation of this syndrome. The relevance of immune reconstitution inflammatory syndrome – associated with Kaposi sarcoma (IRIS-KS) after initiation of highly active antiretroviral therapy (HAART) is noteworthy, mainly in countries that still have high levels of transmission of sexually transmitted diseases and HIV. Clinicians and dermatologists should be aware to identify signs and symptoms of this neoplasm progression and to differentiate them from KS related IRIS according to the recent classification criteria of this disease and antiretroviral therapy should not be discontinued in the most cases.

KEY-WORDS – Antiretroviral therapy, highly active; HIV infections; Sarcoma, Kaposi.

Conflitos de interesse: Os autores declaram não possuir conflitos de interesse.

No conflicts of interest.

Suporte financeiro: O presente trabalho não foi suportado por nenhum subsídio ou bolsa.

No sponsorship or scholarship granted.

Direito à privacidade e consentimento escrito / Privacy policy and informed consent: Os autores declaram que

Caso Clínico

pediram consentimento ao doente para usar as imagens no artigo.

The authors declare that the patient gave written informed consent for the use of its photos in this article.

Recebido/Received – Dezembro/December 2012; Aceite/Accepted – Janeiro/January 2013

Correspondência:

Dr. Felipe Ladeira de Oliveira

Rua Conselheiro Autran 35/805, Vila Isabel

20551-060, Rio de Janeiro, Brazil

Tel.: (55) (21) 97087370

Email: oliveiraflmed@gmail.com

INTRODUCTION

Kaposi's Sarcoma (KS) is the most frequent neoplasm in homosexual and bisexual men with AIDS^{1,2}. An analysis of 107 patients with AIDS-KS in São Paulo – Brazil found it to occur mainly in men (94.4%); one fourth were identified as HIV seropositive after a diagnosis of KS³, illustrating the high incidence of HIV in our country and the correlation between AIDS and KS.

Another virus is also linked to this neoplasm and plays an etiopathological role: the Human Herpes Virus 8 (HHV-8) often referred to as KS associated herpes virus⁴. Evidences indicate that HAART containing at least one inhibitor of HIV protease or a non nucleoside reverse transcriptase inhibitor can reduce the incidence or induce the regression of KS and of other AIDS-associated tumors⁵⁻⁷. This can be attributed to Three factors can be linked to that action: the reduction in HIV viral load, HIV Tat protein an inflammatory cytokine the improvement in CD8+ cytotoxic response against HHV-8; and the anti-inflammatory and anti-angiogenic properties of some drugs included in HAART. All these three actions result in directly inhibiting HIV-KS⁸.

However, in a few HIV seropositive patients, HAART-induced improvement in immune status (temporally related to an increase in the host's CD4+ lymphocyte count) paradoxically results in recrudescence cutaneous and/or visceral KS, attributed to an inflammatory reaction to an opportunistic pathogen or tumor antigen that occurs early after initiation of HAART, the so called immune reconstitution inflammatory syndrome (IRIS)⁹.

CASE REPORT

A 35-year-old, male, born in Rio de Janeiro - Brazil,

sought medical treatment in July 2010 because of strong pain in the epigastric region and asthenia accompanied by loss of appetite. He had no previous history of sexually transmitted infections or drug use. During the investigation, the patient was diagnosed as HIV positive and in September 2010, small and numerous violaceous nodules appeared only on both legs. In early December 2010, laboratory investigations showed an HIV viral load of 172,950 copies per millimeter and CD4+ count of 214 cells/mm³ and antiretroviral therapy (HAART)

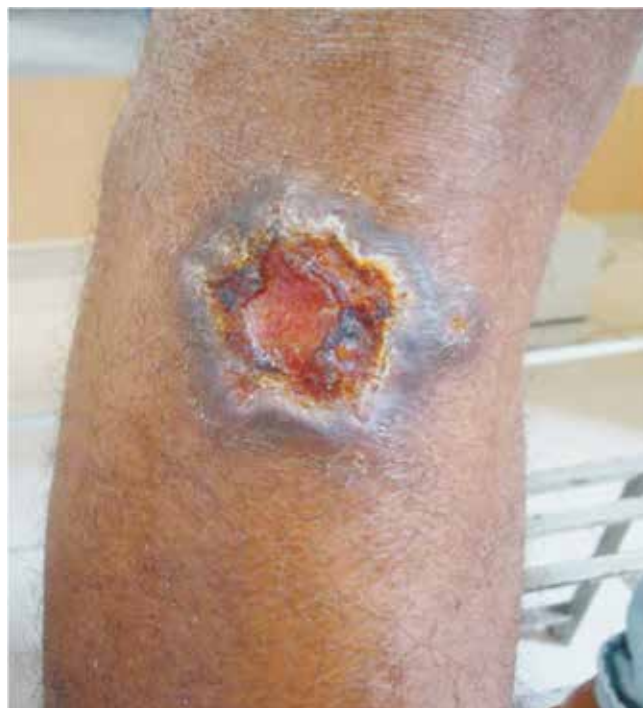

Fig. 1 - Ulcerated Kaposi's Sarcoma lesion with a clean base and well-defined violaceous borders on the right leg.

Caso Clínico

was implemented. The patient was referred to the STDs section of Professor Rubem David Azulay Dermatology Institute, Santa Casa da Misericórdia Hospital, Rio de Janeiro, Brazil.

In January 2011, six weeks after the initiation of HAART (zidovudine, lamivudine, and efavirenz), the patient returned referring worsening of the lesions and fever. Physical examination revealed new violaceous and painful nodules and ulcerated lesions, with a clean base and well-defined borders on the right leg (Fig. 1), chest (Fig. 2) and upper limbs. Neither mucocutaneous KS nor symptoms of visceral involvement were present. VDRL and FTA-abs tests for syphilis were negative.

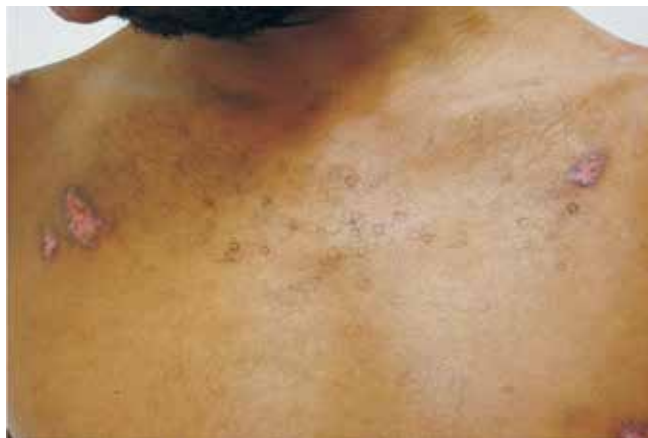

Fig 2 - New ulcerated lesions on chest.

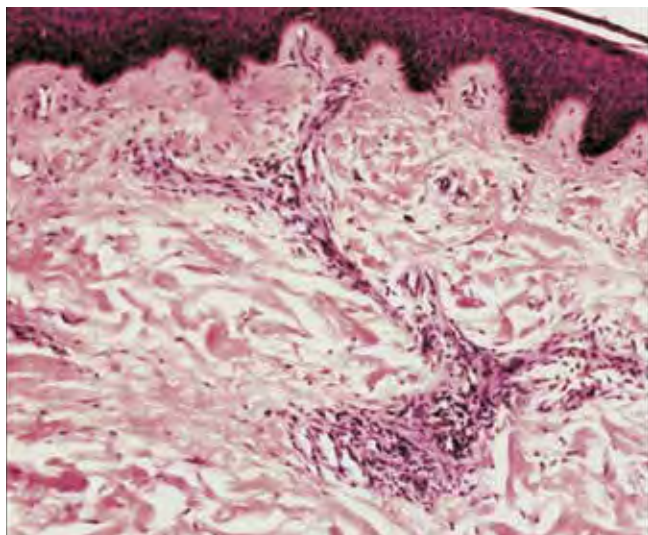


Fig 3 - Normal and newly formed blood vessels in superficial dermis (H&E, 100x).

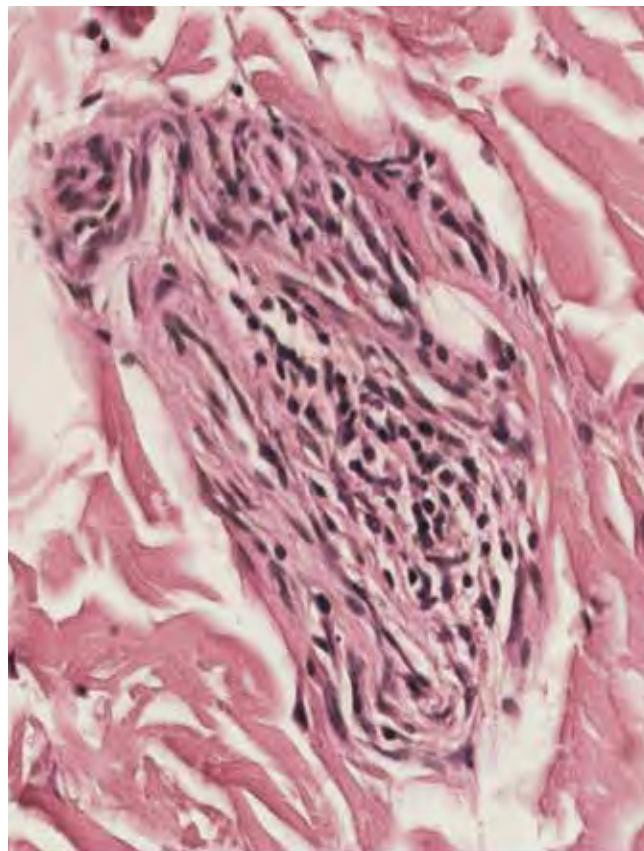


Fig 4 - Small vascular and slit-like spaces, lined by delicate endothelial cells; some spaces show evidence of red blood cells infiltration (H&E, 400x).

A biopsy was taken from a nodular lesion and histologically diagnosed as KS (Figs. 3 and 4). By this time, the HIV viral load was 410 copies per millimeter and CD4+ count was 370 cells per mm³.

Four weeks after the biopsy, the majority of ulcerated and nodular violaceous lesions improved and the patient had no further complaints, even without therapeutic changes.

DISCUSSION

Two important pieces of information lead us to believe that this patient was affected by IRIS and not a simple progression of the Kaposi sarcoma.

The first is that there was no clinical progression of the Kaposi sarcoma lesions (neither in number nor in size) in the month before beginning HAART and the time elapsed between early use of HAART and the worsening of the patient's lesions (about 6 weeks). According to

Caso Clínico

the literature, the development of new lesions due to IRIS occur within 8 weeks (usually ranging from 3 to 22 weeks) after initiating HAART⁸. During the immune status restoration the ability to mount an inflammatory response to a variety of previously indolent antigens is also restored¹⁰. This fact can result in clinical signs of disease activity⁵, triggered by antigenic stimuli which can be tumor antigens or pathogens present in the body (but clinically latent), rather than development or progression of opportunistic infections¹¹.

In addition, according to French *et al*¹² our patient presents a major criteria: atypical presentation of tumor in patients responding to HAART with exaggerated inflammatory reaction (eg, severe fever or painful lesions) and 2 minor criteria: increased CD4 cell account and spontaneous resolution of disease without specific antimicrobial therapy or tumor chemotherapy with continuation of HAART. Our case is also consisted with Robertson J, *et al* case definition of IRIS¹³.

Most IRIS events are represented by the occurrence or recurrence of dermatological diseases¹⁴. KS flare attributed to IRIS may produce life-threatening visceral progression even if cutaneous nodules regress, with deaths from pulmonary KS^{5,15}. Visceral manifestations of the disease was not observed in our patient but the cutaneous nodules enlargement can rapidly and frequently ulcerate and lead to secondary infection^{16,17}.

In turn, the diagnosis of KS was confirmed by skin biopsy. The skin lesions of KS can be divided into patch, plaque and nodular stages, but these stages often overlap clinically and histologically¹⁸. In this report, the lesions exhibit features of nodular stage with a network of slit-like vascular spaces and erythrocytes within the narrow vascular clefts^{18,19}.

In the medical literature revised till now, there are no specific guidelines for the diagnosis and treatment of IRIS¹². However, the antiretroviral therapy should not be discontinued, except in the severely ill patients^{14,20}. In our patient, this approach was successful showing the benefit of the continuation of HAART.

We can conclude that the clinician should be aware to identify signs and symptoms of neoplasm progression and to differentiate them from KS related IRIS and thus, to choose the better approach in the patient's follow-up.

REFERENCES

1. Goedert JJ. The epidemiology of acquired immunodeficiency syndrome malignancies. *Semin Oncol*. 2000; 27(4): 390-401.
2. Dourmishev LA, Dourmishev AL, Palmeri D, Schwartz RA, Lukac DM. Molecular genetics of Kaposi's sarcoma associated herpesvirus (human herpesvirus-8) epidemiology and pathogenesis. *Microbiol Mol Biol Rev*. 2003; 67(2):175-212.
3. Yoshioka MC, Alchorne MM, Porro AM, Tomimori-Yamashita J. Epidemiology of Kaposi's sarcoma in patients with acquired immunodeficiency syndrome in Sao Paulo, Brazil. *Int J Dermatol*. 2004; 43(9):643-7.
4. Tamburro KM, Yang D, Poisson J, Fedoriw Y, Roy D, Lucas A, *et al*. Vironome of Kaposi sarcoma associated herpesvirus-inflammatory cytokine syndrome in an AIDS patient reveals co-infection of human herpesvirus 8 and human herpesvirus 6A. *Virology*. 2012; 433(1):220-5.
5. Bower M, Nelson M, Young AM, Thirlwell C, Newsom-Davis T, Mandalia S, *et al*. Immune reconstitution inflammatory syndrome associated with Kaposi's sarcoma. *J Clin Oncol*. 2005; 23(22):5224-8.
6. Murdoch DM, Venter WD, Feldman C, Van Rie A. Incidence and risk factors for the immune reconstitution inflammatory syndrome in HIV patients in South Africa: a prospective study. *AIDS*. 2008; 22(5):601-10.
7. Nasti G, Martellotta F, Berretta M, Mena M, Fasan M, Di Perri G, *et al*. Impact of highly active antiretroviral therapy on the presenting features and outcome of patients with acquired immunodeficiency syndrome-related Kaposi sarcoma. *Cancer*. 2003; 98(11):2440-6.
8. Feller L, Lemmer J. Insights into pathogenic events of HIV-associated Kaposi sarcoma and immune reconstitution syndrome related Kaposi sarcoma. *Infect Agent Cancer*. 2008; 3:1.
9. Hirsch HH, Kaufmann G, Sendi P, Battegay M. Immune reconstitution in HIV-infected patients. *Clin Infect Dis*. 2004; 38(8):1159-66.
10. Lederman MM. Immune restoration and CD4+ T-cell function with antiretroviral therapies. *AIDS*. 2001; 15 (Suppl 2):S11-5.
11. Connick, E; Kane, MA; White, IE; Ryder, J; Campbell, TB. Immune Reconstitution Inflammatory Syndrome Associated with Kaposi Sarcoma during Potent Antiretroviral Therapy. *Clin Infect Dis*. 2004; 39(12):1852-5.
12. French MA, Price P, Stone SF. Immune restoration disease after antiretroviral therapy. *AIDS*. 2004; 18(12):1615-27.
13. Robertson J, Meier M, Wall J, Ying J, Fichtenbaum CJ. Immune reconstitution syndrome in HIV:

- validating a case definition and identifying clinical predictors in persons initiating antiretroviral therapy. *Clin Infect Dis* 2006; 42 (11):1639-46.
14. Papagatsia Z, Jones J, Morgan P, Tappuni AR. Oral Kaposi sarcoma: a case of immune reconstitution inflammatory syndrome. *Oral Surg Oral Med Oral Pathol Oral Radiol Endod*. 2009; 108(1):70-5.
 15. Lehloenya R, Meintjes G. Dermatologic manifestations of the immune reconstitution inflammatory syndrome. *Dermatol Clin*. 2006; 24(4):549-70, vii.
 16. Nguyen S, Giurca C, Melliez H, Dehecq C, Baclet V, Ajana F, et al. Kaposi's sarcoma in HIV-infected patients: when and how should we evaluate bone involvement? *AIDS*. 2007; 21(16):2251-2.
 17. Von Roenn JH. Clinical presentations and standard therapy of AIDS-associated Kaposi's sarcoma. *Hematol Oncol Clin North Am*. 2003; 17(3):747-62.
 18. Calonje, E. Soft-Tissue Tumours and Tumour-like Conditions. In: Burns T, Breathnach S, Cox N, Griffiths C, editors. *Rook's Textbook of Dermatology*. 8th ed. Oxford: Wiley-Blackwell; 2010. p. 56.35-56.36
 19. Buonaguro FM, Tomesello ML, Buonaguro L, Satriano RA, Ruocco E, Castello G, et al . Kaposi's sarcoma: aetiopathogenesis, histology and clinical features. *J Eur Acad Dermatol Venereol*. 2003; 17(2):138-54.
 20. Loke WC, Spittle MF, Mitchell S, Kulasegaram R. Timing of highly active antiretroviral therapy and chemotherapy for Kaposi's sarcoma in patients with HIV infection. *Int J STD AIDS*. 2006; 17(8):565-6.