

# IMCAS

International Master Course on Aging Science

**ASIA** JULY 21 TO 23  
**2017** **BALI**  
INDONESIA

BALI INTERNATIONAL CONVENTION CENTRE  
THE WESTIN RESORT - NUSA DUA

**BALI**  
TOURISM  
INDONESIA  
2017

www.balitourismindonesia.com




ENDORSED BY

PERDOSKI  
Indonesian Society  
of Gerontology

THE REGISTERED AND AUTHORIZED  
INDONESIA ASSOCIATION

# Content



**Ask your questions**  
**Share your thoughts**  
**Participate in debates**

Increase your involvement any time during the session using our unique interactive platform

**LIVE.IMCAS.COM**

TAKE PART IN  
TWO EASY STEPS:

1. Connect to the venue's WiFi network
2. Login with your personal congress key (written on your badge)

Now you're free to browse IMCAS Live!


Join the conversation!  
**#IMCASASIA**

#### SPONSORED ADVERTISEMENTS

- 60 CYNOSURE
- 62 ESTHETICO DERMA INSTITUTE
- 64 EUNSUNG
- 66 HSC CO., LTD
- 68 ILOODA
- 70 LG CHEM
- 72 SYNERON CANDELA
- 74 THE AESTHETIC GUIDE
- 76 THERMI
- 78 LABORATOIRES VIVACY
- 80 VIVEVE
- 82 WONTECH



- 5 CIRCULATION MAP**  
Find your way around
- 6 SCIENTIFIC BOARD & SPEAKER LIST**  
Which experts will you be learning from this year?
- 8 SCIENTIFIC PARTNERSHIP**  
Take a look at our esteemed scientific partners
- 9 STATISTICS & KEY MOMENTS**
- 10 SESSION FORMATS**  
Take a look at what's in store
- 11 SCHEDULE-AT-A-GLANCE**
  - 11 FRIDAY**
  - 12 SATURDAY**
  - 13 SUNDAY**
- 14 FOCUS ON**
  - 14 LIVE ANATOMY ON CADAVER WORKSHOP**
  - 16 GENITAL TREATMENTS**
  - 17 ONE DAY SURGERY: FRANCE - ASIA**
- 18 ASIA EXCITING DEVELOPMENTS**
- 19 A MOMENT WITH THE EXPERTS**
- 20 QUALITY AND TRANSPARENCY**  
How to obtain your certificate of attendance
- 22 IMCAS ACADEMY & IMCAS ALERT**
- 23 PROGRAM BY DAY**
  - 24 FRIDAY**
  - 32 SATURDAY**
  - 46 SUNDAY**
- 43 WEBCAST LECTURES**
- 56 POSTERS**  
Displayed in the Exhibition Hall
- 52 VIDEO CLASSES**
- 54 TARGET COURSES**
- 57 GALA DINNER**  
We hope to see you there!
- 58 CORPORATE FUNDING**  
Read more about where IMCAS derives its revenues
- 59 SPONSOR LIST**  
Meet our exhibitors at their booth
- 94 BALI EVENTS AGENDA**
- 95 REGISTRATION GUIDELINES**
- 96 EXHIBITION MAP**  
Find your way around easily
- 98 GENERAL INFORMATION**
- 99 IMCAS ANNUAL WORLD CONGRESS 2018**  
20 years later, 20 years younger
- 100 IMCAS AGENDA OF CONGRESSES**



**CME Accredited**  
See page 20 for details

# Speaker list

## HONORARY PRESIDENT

*HIDAYAT SJARIEF*, Dermatologist, Indonesia

## SCIENTIFIC COMMITTEE

*ASCHER BENJAMIN*, Plastic surgeon, France  
*LISTIAWAN MUHAMMAD YULIANTO*, Dermatologist, Indonesia  
*PRASETYO ADRI DWI*, Dermatologist, Indonesia

## SCIENTIFIC SECRETARY

*CHAN HENRY HIN LEE*, Dermatologist, Hong Kong  
*GARSON SEBASTIEN*, Plastic surgeon, France  
*HUANG PO HAN PATRICK*, Dermatologist, Taiwan  
*WIDIANSYAH ANDREAS*, Dermatologist, Indonesia

## SCIENTIFIC COMMITTEE

*ABS RICHARD*, Plastic surgeon, France  
*ARIMUKO ABRAHAM*, Dermatologist, Indonesia  
*BADAWI ASHRAF M*, Dermatologist, Canada  
*BERRENI NICOLAS*, Gynecologist, France  
*CASSUTO DANIEL*, Plastic surgeon, Italy  
*CHANG TSE MING*, Otorhinolaryngologist, Taiwan  
*CHUANGSUWANICH APIRAG*, Plastic surgeon, Thailand  
*DEL VECCHIO DANIEL*, Plastic surgeon, United States  
*ELLYANI SRI*, Dermatologist, Indonesia  
*FLYNN JOHN HINTON*, Cosmetic surgeon, Australia  
*GOH CHEE LEOK*, Dermatologist, Singapore  
*KAMAKURA TATSURO*, Plastic surgeon, Japan  
*KAO CHUAN HSIANG STEVE*, Facial plastic surgeon, Taiwan  
*KONO TARO*, Plastic surgeon, Japan  
*LAM STEPHANIE CHUK KWAN*, Plastic surgeon, Hong Kong  
*LE HANH*, Cosmetic surgeon, Vietnam  
*OEIRIA DAVID SUDARTO*, Dermatologist, Indonesia  
*OMI TOKUYA*, Dermatologist, Japan  
*ROUIF MICHEL*, Plastic surgeon, France  
*SUDHARMONO SRI ARYANI*, Dermatologist, Indonesia  
*SUNDARAM HEMA*, Dermatologist, United States  
*WATTANAKRAI KAMOL*, Plastic surgeon, Thailand  
*ZAKINE GILBERT*, Plastic surgeon, France

## FACULTY

*ANDJELKOV KATARINA*, Plastic surgeon, Serbia  
*BADER ALEXANDROS*, Gynecologist, United Kingdom  
*BOUCHER FABIEN*, Plastic surgeon, France  
*BUNMAS PICHANSAK*, Facial plastic surgeon, Thailand  
*CHHABRA CHIRANJIV*, Dermatologist, India  
*CHIU PIN CHI*, Dermatologist, Taiwan  
*COSTE JEAN-YVES*, Financial analyst, France  
*CUI HAIYAN*, Plastic surgeon, China  
*DESAI SEJAL*, Gynecologist, India  
*DESAI VIRAL RAMESH*, Plastic surgeon, India  
*DHAMI LAKSHYAJIT D*, Plastic surgeon, India  
*DHANASARI NI KOMANG YENI*, Gynecologist, Indonesia  
*DJUANDA EDWIN*, Dermatologist, Indonesia  
*ERMISCH CHRISTIANE*, Plastic surgeon, France  
*FERRARIZ TERESITA SANTILLAN*, Dermatologist, Philippines  
*FUNDARO SALVATORE*, Plastic surgeon, Italy  
*GAFOOR ABDUL MUBARAK*, Cosmetic surgeon, Malaysia  
*CANJOO ANIL*, Dermatologist, India  
*GHANNAM SAHAR FOAD*, Dermatologist, Canada  
*CONDOWARDOJO JANE RATNA MAITRIDEWI*, Dermatologist, Indonesia  
*GOUT ULIANA*, MD, United Kingdom  
*HARLIM MARS AGO*, Dermatologist, Indonesia  
*HUANG CHING HSIN*, Dermatologist, Taiwan  
*IKEDA YOSHIO*, Plastic surgeon, Japan  
*JUNIARTI LANNY*, MD, Indonesia  
*JORGE ALVIN M*, Cosmetic surgeon, Philippines  
*KANG IN SOOK*, Plastic surgeon, South Korea  
*KAPOOR KRISHAN MOHAN*, Plastic surgeon, India  
*KERSCHER MARTINA J*, Dermatologist, Germany  
*KESTEMONT PHILIPPE*, Facial plastic surgeon, France  
*KIM JONG SEO*, Plastic surgeon, South Korea  
*KUSMANA FELIX*, Dermatologist, Indonesia  
*KUSUMA PUTRA BAGUS HARYO*, Dermatologist, Indonesia  
*KWON HAN JIN*, Cosmetic surgeon, South Korea  
*KWON TAEK KEUN*, Plastic surgeon, South Korea  
*LANDAU MARINA*, Dermatologist, Israel  
*LEE JENNIFER PONING*, Gynecologist, Taiwan  
*LEGIAWATI LILI*, Dermatologist, Indonesia  
*LE TAN HUNG*, Facial plastic surgeon, Vietnam  
*LIM ADRIAN*, Dermatologist, Australia  
*LIN SHANG LI*, Dermatologist, Taiwan  
*LIN TSAI MING*, Plastic surgeon, Taiwan  
*LLULL CERDA RAMON*, Plastic surgeon, Spain  
*LUCERO FLORENCIO QUIOGUE*, Plastic surgeon, Philippines  
*LUTHRA AMIT*, Dermatologist, India  
*MAWARDI PRASETYADI*, Dermatologist, Indonesia  
*MAY SIMONE*, MD, Austria  
*MOCHTAR FRANSISKA*, Gynecologist, Indonesia  
*MUTALIK SHARAD*, Dermatologist, India  
*NAOURI MICHAEL*, Dermatologist, France  
*NGUYEN TRAN GIAP*, Cosmetic surgeon, Vietnam  
*PAVICIC TATJANA*, Dermatologist, Germany

## FACULTY

- PENG HSIEN LI PETER, Dermatologist, Taiwan  
 PERDANAKUSUMA DAVID SONTANI, Plastic surgeon, Indonesia  
 PIAMPHONGSANT THADA, Dermatologist, Thailand  
 PINATHI INDRA GUNA, Nutritionist, Indonesia  
 PUYAT MARIA CRISTINA ALCAREZ, Dermatologist, Philippines  
 RAMAS RAIN, Marketing specialist, Philippines  
 RAPPL THOMAS, Plastic surgeon, Austria  
 RUDENKO IGOR, Dermatologist, Ukraine  
 RUMMANEETHORN PAISAL, Cosmetic surgeon, Thailand  
 SACHDEV MUKTA, Dermatologist, India  
 SAKAI NAOHIKO, Plastic surgeon, Japan  
 SFORZA MARCOS PAULO, Plastic surgeon, United Kingdom  
 SHELKOVITZ TZACHI, Dermatologist, Israel  
 SMARRITO STÉPHANE, Cosmetic surgeon, Switzerland  
 SULAMANIDZE CONSTANTIN, Plastic surgeon, Georgia  
 SUMAETHEIWIT RASSAPOOM, Dermatologist, Thailand  
 SUWANCHINDA ATCHIMA, Dermatologist, Thailand  
 TANGLERTSAMPAN CHUCHAI, Dermatologist, Thailand  
 TSAO SU BEN, Plastic surgeon, Taiwan  
 UCHMAN - MUSIELAK, MALGORZATA, Gynecologist, Poland  
 VITALE GILBERT, Plastic surgeon, France  
 WANG SHIOU HAN, Dermatologist, Taiwan  
 WINTER CECILE, Facial plastic surgeon, France  
 WU WENYU, Dermatologist, China  
 XU HAISONG, Plastic surgeon, China  
 YANG MING CHUAN WILSON, Cosmetic surgeon, Taiwan

## INDUSTRY SPEAKERS

- ABDELAZIZ AHMED, Industry representative, Switzerland  
 AHN SANG TAE, Plastic surgeon, South Korea  
 ANINDITA JONATHAN, MD Indonesia  
 BANKOWSKI RICHARD, Industry representative, United States  
 BEUSTES STEFANELLI MATTHIEU, Plastic surgeon, France  
 BYERS M BRUCE, Industry representative, United States  
 CHAO YEN YU YATES, Dermatologist, Taiwan  
 CLIFF SANDEEP H, Dermatologist, United Kingdom  
 CORDUFF NIAMH ANNE, Plastic surgeon, Australia  
 COUCHOUREL DENIS, Industry representative, France  
 CRABAI PIERO, Plastic surgeon, Italy  
 DANG CHRISTOPHE, Industry representative, France  
 GHAZZAWI MOHAMMAD ISSAM, Dermatologist, Jordan  
 HO WAI SUN WILSON, Plastic surgeon, Hong Kong  
 KASJMIR YOGA I, Rheumatologist, Indonesia  
 KIM AUSTIN, Industry representative, South Korea  
 KIM HYUNG DO, Plastic surgeon, South Korea  
 LEE JAE HYUK, Industry representative, South Korea  
 LEE YOUNG SEOB, Plastic surgeon, South Korea  
 LEONARD DAVID, MD, Indonesia  
 LESTHARI NI NYOMAN INDRA, Dermatologist Indonesia  
 LUCAS CAROLINE, Industry representative, France  
 MARIET RENCA, Beautician, Indonesia  
 MIYATA NARIAKI, Plastic surgeon, Japan  
 OH SEUNG MIN, Cosmetic surgeon, South Korea  
 ONDRICHOVA ANNA, Industry representative, Czech Republic  
 PANGKAHILA ERIVIA DEBORA, Dermatologist, Indonesia  
 POLNIKORN NIWAT, Dermatologist, Thailand  
 PRAGER WELF, Dermatologist, Germany  
 SEO JUNG HO, Dermatologist, South Korea  
 SERRANO SANMIGUEL GABRIEL, Dermatologist, Spain  
 SHOAB TAIMUR, Plastic surgeon, United Kingdom  
 TSENG FANG WEN, Dermatologist, Taiwan  
 VIZINTIN ZDENKO, Industry representative, Slovenia  
 WAHYUDI NATALIA, Dermatologist, Indonesia  
 WANG HANG, Plastic surgeon, China  
 WANITPHAKDEEDECHA RUNGSIMA, Dermatologist, Thailand  
 WU SHEUNG YUNG RAYMOND, MD, Hong Kong  
 ZERBINATI NICOLA, Dermatologist, Italy

## CONTRIBUTING SPEAKERS

- AMANI SAAD YASSINE, MD, Lebanon  
 AZHARI HIDAYAT NIKO, Medical office staff, Indonesia  
 BAE SANG MO, Plastic surgeon, South Korea  
 BALAKRISHNAN JANETHY, MD, Malaysia  
 CAHYAWARI DARTRI, Dermatologist, Indonesia  
 CHOI KOANGHYUN, Dermatologist, South Korea  
 COSSICH PAOLO, Industry representative, Italy  
 ELGHBLAWI EB TISAM, Dermatologist, Libya  
 GORENSEK KATJA, Dermatologist, Slovenia  
 HERGYANA FITRA, Dermatologist, Indonesia  
 HERLINA LENGGA, MD, Indonesia  
 HIDAJAT INNEKE JANE, Dermatologist, Indonesia  
 JANG JU YUN, Plastic surgeon, South Korea  
 JUNG JAE YUN, Cosmetic surgeon, South Korea  
 KERAMIDAS EVANGELOS, Plastic surgeon, Greece  
 KHAIRANI FATIMA AULIA, MD, Indonesia  
 KIM HANNAH, Not specified, South Korea  
 KIM CHANG SIK, Dermatologist, South Korea  
 KIM WON SERK, Dermatologist, South Korea  
 KRYCHMAN MICHAEL, Gynecologist, United States  
 LEE KYUNGREAL, Dermatologist, South Korea  
 LEE YOU JIN, Dermatologist, South Korea  
 LEE YOUNG BOK, Dermatologist, South Korea  
 LIM TINGSONG, MD, Malaysia  
 MAJLESSI HESHMAT, Phlebologist, United States  
 MALETIC DUSAN, Cosmetic surgeon, Croatia  
 MICHAEL ALICE, Cosmetic surgeon, Malaysia  
 MORALLO JOAN CLARENCE SORIANO, Dermatologist, Philippines  
 NARA KISHEN, Cosmetic surgeon, Australia  
 PARK J E YOUNG, Dermatologist, South Korea  
 PARK TAE HWAN, Plastic surgeon, South Korea  
 PARK YUN JOO, Radiologist, South Korea  
 PERMATASARI NADIA, MD, Indonesia  
 POLNIKORN NIWAT, Dermatologist, Thailand  
 POR YONG CHEN, Plastic surgeon, Singapore  
 QUINONES ORO RICARDO GALVEZ, Cosmetic surgeon, Philippines  
 RODOPOULOU VILLY, Plastic surgeon, Greece  
 ROSLINA NINA, Dermatologist, Indonesia  
 RUCHIATAN KARTIKA, Dermatologist, Indonesia  
 RUSLI SITI MUYASSARAH, Plastic surgeon, Malaysia  
 SHIN MI YOUNG, Gynecologist, South Korea  
 SHRESTHA DAS PRATIVA, Dermatologist, Nepal  
 SI LUMIN, Plastic surgeon, China  
 SINGH SEEMA SATYAPAL, Dermatologist, United Arab Emirates  
 SOMSUP SARITTHA, Neurologist, Thailand  
 SUBRATA TANJUNG, MD, Indonesia  
 THANYAVUTHI APICHAYA, Dermatologist, Thailand  
 VO HUY RICHARD, Plastic surgeon, Vietnam  
 WONG POWELL AMANDA, MD United, Kingdom  
 WU KEJIA, Dermatologist, China

# SATURDAY


BROWSE THE PROGRAM AND CORRESPONDING LECTURES ONLINE  
WWW.IMCAS.COM

	ROOM 1	ROOM 2 ONE-DAY SURGERY FRANCE-ASIA	ROOM 3	ROOM 4 <sup>A</sup>	ROOM 4 <sup>B</sup>	ROOM 5 <small>030 A</small> TARGET COURSES (TC)	Exhib. Hall
7							
8:30	S37 FILLERS UPPER FACE	S45 MODERN TECHNIQUES IN BLEPHAROPLASTY	S53 MORPHOTYPES. DIFFERENT APPROACHES FOR MINIMAL INVASIVE PROCEDURES	S61 ALOPECIA ARE LASERS & PRP EFFECTIVE?	S69 MALE TREATMENTS WHAT'S HOT?	S77 TARGET COURSE ANATOMY TO OPTIMIZE INJECTIONS	
9:30	S38 FILLERS MIDFACE & NOSE	S46 RHINOPLASTY IN THE ASIAN NOSE	S54 SYMPOSIUM MERZ	S62 HAIR TRANSPLANT	S70 SYMPOSIUM DELEO	S78 TARGET COURSE THREAD TECHNIQUES STEP BY STEP	
10:30							
11	S39 FILLERS LOWER FACE & NECK	S47 FACELIFTS	S55 SYMPOSIUM CLASSYS	S63 LIVE DEMO THREADS	S71 SYMPOSIUM ULTRA V	S79 TARGET COURSE HAND REJUVENATION TECHNIQUES STEP BY STEP	VIDEO PAPERS
12	S40 THE SECRET OF LIP REJUVENATION	S48 PROFILOPLASTY	S56 SYMPOSIUM REGEN LAB	S64 LIVE DEMO FILLERS, TOXINS, PEELINGS & COSMECEUTICALS	S72 SYMPOSIUM MERZ	S80 TARGET COURSE MEDICAL RHINOPLASTY	VIDEO PAPERS
1							
2	S41 SYMPOSIUM HYACORP	S49 RECENT ADVANCES IN BREAST AUGMENTATION	S57 SYMPOSIUM VIVACY	S65 LIVE DEMO FILLERS, TOXINS, PEELINGS & COSMECEUTICALS	S73 SYMPOSIUM GALDERMA	S81 TARGET COURSE STATE OF THE ART RHINOPLASTY	VIDEO PAPERS
3	S42 SYMPOSIUM LG CHEM	S50 BREAST-PLASTY	S58 SYMPOSIUM CYNOSURE	S66 LIVE DEMO FILLERS, TOXINS, PEELINGS & COSMECEUTICALS	S74 SYMPOSIUM LAUTAN LUAS ABADI-APTOS	S82 TARGET COURSE BUTTOCKS	VIDEO PAPERS
4							
4:30	S43 VIDEO CLASS (VC) FILLERS & TOXINS 2017 UPDATE	S51 ENHANCEMENTS IN BLEPHAROPLASTY	S59 CLINICAL CASES ANALYSIS & TREATMENTS IN PATIENTS OF DIFFERENT AGES	S67 THE ART OF USING THREADS	S75 VIDEO CLASS (VC) COMBINED TREATMENTS EBD & BODY SHAPING	S83 TARGET COURSE PRP, STEM CELLS & REGENERATIVE MEDICINE	VIDEO PAPERS
6	GALA DINNER						
8	GALA DINNER						

Registration opens Lunch Coffee break

Video Class Target Course Sponsored sessions Subject to additional fees

- Body shaping
- Lasers & EBD
- Breast surgery
- Face surgery
- Regenerative medicine & lipofilling
- Clinical dermatology
- Hair restoration
- Injectables
- Suspendng devices



# IMCAS Asia 2017

International Master Course on Aging Science  
Bali, Indonesia - July 21 - 23, 2017



## SPEAKER CERTIFICATE

### IMCAS ASIA 2017 Scientific Board

#### Honorary President

Sjarief Hidayat  
Dermatologist (Indonesia)

#### Course Coordinators

Benjamin Ascher  
Plastic Surgeon (France)  
Muhammad Yulianto Listiawan  
Dermatologist (Indonesia)

Adri Dwi Prasetyo  
Dermatologist (Indonesia)

#### Scientific Secretaries

Henry Hin Lee Chan  
Dermatologist (Hong Kong)  
Sebastien Garson  
Plastic Surgeon (France)  
Patrick Po Han Huang  
Dermatologist (Taiwan)  
Andreas Widiaryah  
Dermatologist (Indonesia)

IMCAS (International Master Course on Aging Science) hereby certifies that:

Dr HARLIM MARS Ago  
Dermatologist,  
Indonesia

has given the following lecture(s) during IMCAS Asia 2017, held in Bali from July, 21 to 23:

**Webcast lecture - "Immunology behind the fillers which cause granulomas"**

**Webcast lecture - "Stem cells for aesthetics and anti aging"**

**Video paper Injectables: "How to treat the complications of silicone nasal injections"**

IMCAS Course Director  
*Dr Benjamin ASCHER*

Date of issue: 06/10/2017

# FACULTY

## IMCAS ASIA 2017 July 21 to 23 **Bali**

#IMCASAsia2017

Ago  
HARLIM MARS



Free IMC  
Abstracts  
Participate

# SPEAKER

### HARLIM MARS Ago

The responsibility of the pharmacist in the development of the pharmaceutical industry in Indonesia

Your schedule on IMCAS ASIA 2017

IMCAS ASIA 2017

DATE	TIME	TOPIC	SESSION
14 Jul	8:45 AM - 10:30 AM	Webcast Lecture	Immunology Behind The Fever Which Cause Granuloma Of ESOPH
14 Jul	11:40 AM - 12:15 PM	Webcast Lecture	Gene Cells For Antibiotic And Antiviral (2)
14 Jul	1:15 PM - 1:45 PM	Video Paper - updated	How To Treat The Complications Of Glucose Insulin Injections (2)

## How to Treat The Complication of Silicone Nasal Injection

Ago harlim  
IMCAS 2017

### Abstract

The use of silicone as filler material has been banned by FDA. Nevertheless, there are still some risks of using topical silicone, particularly cosmetic products that contain silicone. Bioavailability of silicone in skin tissues and long-term complications of silicone use in cosmetic products must be evaluated for safety reasons. Silicone can penetrate to the skin by injection. Because of economic issues and the rarity of medical grade silicone, various developing countries use industrial silicone, which results in even more complications. Patients with liquid silicone injected to their nose will usually visit a doctor after experiencing complication issues such as granuloma, edema, redness with telangiectasia. Usually the patients want to remove the silicone and treat the complication. Unfortunately, silicone is difficult to be removed completely. Some complications are difficult to treat. To handle this complication issue, the doctor has to create a specific design of nose implant, performed curratage, or remove silicone and granuloma, and then a laser treatment and steroid injection will be performed.

Keywords: Silicone, skin, topical, nasal implant, laser

### Introduction

Silicone injection has been used since 40 years ago, and at that time, many problems occurred such as migration, inflammation, and granuloma. In 1992, the FDA prohibited silicone injection for cosmetic use [1]. In addition to injection, silicone may be introduced into our body or skin through food intake and cosmetic. Silicone has been widely used in daily cosmetics. Nowadays, due to technology advances, topical drugs can pass through skin barrier and can be penetrated into the skin, which has become a great concern as it may induce granuloma formation. There are relatively very few studies that have been done on silicone concentration in the normal skin.

A study conducted by Harlim in 2018 found that a normal skin contained silicon. The study was performed by taking skin samples from normal subjects and those with face-lift procedure and subsequently compared those samples using the same criteria with the control group, which included skin samples of subjects that had received silicone injection, and the study found granuloma formation. The study found an average amount of silicon level of  $44.07 \pm 75.86 \mu\text{g/g}$  in patients with normal skin, while in patients with granuloma, they found 38 times greater silicon level ( $1709.21 \pm 1851.72 \mu\text{g/g}$ ) [2].

### Silicone

Injectable-grade silicone for medical use has been manufactured widely since the element has been known for its stable and inert characteristics [3, 4]. It includes the use of silicone oil, which has been utilized in the treatment of complicated retinal detachment and heavy silicone oil tamponade. The treatment seems to offer promising results, particularly on improving visual acuity as well as great results on some anatomical parameters; however, there are some concerns as it may cause several complications such as cataract, increased ocular pressure, heavy silicone oil emulsification, and mild inflammatory reaction [5, 6, 7].

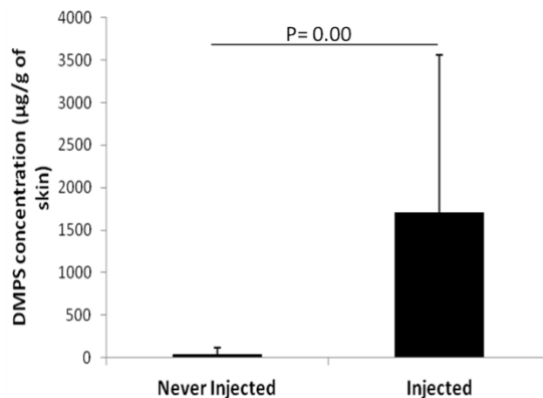
Injectable-grade silicone has also been widely used in the form of silicone oil injection. Some studies have suggested that it may have an essential role in reducing the risk of developing diabetic foot ulcer due to its pressure-reducing properties; therefore, it can maintain plantar tissue thickness and alleviate symptoms of diabetic foot ulcer, which may be associated with foot biomechanics [8, 9].

Although it brings advantages, silicone injection may still develop some complications, either local or systemic complications. Local complications may include formation of palpable nodule surrounding injection site, arthralgia, fatigue, electrical neuropathy, and electrical sensation [10], while systemic complications may also occur in the form of lymphadenopathy, renal disease, and hepatic disease. It indicates that the injected silicone can migrate from injection site to other organs causing local and systemic complications. An animal experimental study in mouse model may explain the pathogenesis of such complications. The study has demonstrated that macrophage of skin tissue may engulf the injected silicone and the silicone may be distributed through lymphatic circulation, ultimately causing accumulation in lymph nodes, adrenal glands, and the kidney, liver, and spleen as well as granuloma formation in the skin [11]. Complications due to silicone injection, particularly the



granuloma formation may be dose-dependent. A study by Harlim has demonstrated that granuloma formation could be developed when there is a large amount of silicone exposure as the study only found a low level of silicone without any granuloma formation in the normal skin (Figure 1) [2].

Cultural changes have been encouraging people to pursue their passion on beauty and youth; therefore, cosmeticology has been rapidly growing. With technological advances, more mixed drug ingredients have been added to cosmetic products in order to beautify their customers. Thus, it may indirectly increase the use of topical cosmetics that usually contain silicone; therefore, it will lead to increase silicone uptake to the skin. It has raised a concern that the prolonged and continuous use of cosmetics will cause granuloma formation and other chronic inflammatory effects.



**Figure 1.** The level of silicon (Si) in normal subjects who had never received silicone injection (never injected) and in subjects with granuloma who had received silicone injection. (cited from A Harlim, et all) [2].

### Dietary intake and silicon

Aside from medical use, silicon has also been used in food industry, cosmetics, and pharmaceutical industries. Our data shows that the silicon levels in gastrointestinal medications (e.g., antacids), mineral water, and soda drinks are 44.1, 25.6, and 2.91 µg/g, respectively. It can be said that there are many routes for administering silicon into our body. The average daily intake of silicon for European and North American populations is 20–50 mg/day. In China and India, the daily intake of silicon is larger that may reach as many as 140–200 mg/day, in which wheats, fruits, and vegetables are the greatest producers [12].

A research institution of healthy aging and nutrition in the United Kingdom has recently reported a strong correlation between silicon in dietary intake and the health of bone and connective tissue. Therefore, it can be assumed that the correlation is associated with collagen synthesis and/or stabilization of mineral matrix, i.e., silicone intake may affect bone density [13].

Another study, which is an animal experimental study, has demonstrated that there is no evidence of silicon accumulation in silicon consumption. Silicon can be eliminated through digestion process and can be found in feces (93–97%), urine (0.001–0.22%), and expired air (0.01–0.02%) [3]. It indicates that silicon is a stable element and at certain degree it can be resistant to digestive enzymes including gastric acid; therefore, it seems that silicon is not accumulated in the gastrointestinal system.

### Silicone in Cosmetics

Beauty products for face, hair, and cosmetics may have high silicone content, in which it will be accumulated in the skin tissue. When a topical beauty product containing silicone is applied to the skin, the elastomeric particles of silicone will absorb various liquids including emollient and oil; therefore, silicone is used in skin care product as vehicle (carrier) of active ingredient for the skin or as oil control product of the skin [4, 5].

- Types of silicone that are commonly used in cosmetic products
- Dimethicone—clear, inert, liquid and its solubility depends on the length of polymer backbone ranging in thickness from watery consistency to thick.
- Dimethicone copolyol—silicone that contains an —OH group; therefore, it is more water-soluble resulting in easier incorporation into water-based formulations and also reduces the “slip effect” of the silicone.

- Cyclomethicone—the shortest cyclic molecule, which has many similarities with dimethicone except it can evaporate, while dimethicone cannot.
- Cyclo-dimethicone—a combination of dimethicone and cyclomethicones.

The great use of silicones in cosmetic product may increase the risk of accumulation of the substance in our body, particularly in the facial skin. No clear evidence has been found on the bioavailability and concentration of accumulated silicone in topical uses.

### Granuloma: Definition

Granuloma is a foreign body reaction against foreign substances that enter the skin. Granuloma occurs due to continuous or chronic inflammation against foreign substances. Silicone is a foreign substance in the body, which will be encapsulated by the body. Giant cells (giant cells) will encapsulate silicone material, and therefore inflammatory mediators cannot perform phagocytosis, which results in continuous inflammation and causes side effect. The encapsulated material has poor vascularization; therefore, it may potentially induce infections [6].

### Classification and etiology

There are many kinds of granuloma classification; however, the common classifications are those which have been adjusted to the etiologies [7, 8]. Granuloma formation may occur due to various factors such as biologic, chemical, and physical irritative agents [7]. Classification based on clinical, etiological, and histopathological features can be categorized further into infection, vasculitis, immunological aberration, leukocyte oxidation deficiency, hypersensitivity, chemicals, or neoplasma [14, 15]. Table 1 presents classification of granuloma based on etiology [8].

Infections	Immunological aberration
<b>Fungi</b> <i>Histoplasma</i> <i>Coccidioides</i> <i>Blastomyces</i> <i>Sporothrix</i> <i>Aspergillus</i> <i>Cryptococcus</i>	Sarcoidosis Crohn's disease Primary biliary cirrhosis Giant cell arteritis Peyronie's disease Hypogammaglobulinaemia Langerhans' granulomatosis Hepatic granulomatous disease Immune complex disease
<b>Protozoa</b> Interferon- $\delta$ -receptor deficiency Toxoplasma Leishmania	<b>Vasculitic granulomatosis</b> Wegener's Necrotizing sarcoidal Churg-Strauss Lymphomatoid Polyarteritis nodosa Bronchocentric Systemic lupus
<b>Metazoa</b> Toxocara Schistosoma	
<b>Spirochaetes</b> <i>T.Pallidum</i> <i>T.carateum</i> <i>T.pertune</i>	
<b>Mycobacteria</b> <i>M. tuberculosis</i> <i>M. leprae</i> <i>M. kansasii</i> <i>M. marinum</i> <i>M. avian</i> <i>BCG vaccine</i>	<b>Leukocyte coidase defect</b> Chronic granulomatous disease of childhood
<b>Bacteria</b> Brucella Yersinia	<b>Hypersensitivity pneumonitis</b> Farmers' lung Bird fanciers' Mushroom workers' Suberosis (cork dust) Bagassosis Marple bark strippers'

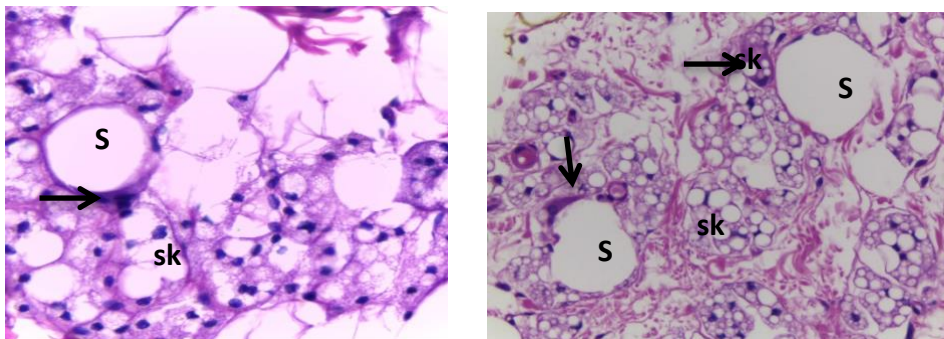
<b>Other infections</b>	Paprika splitters'
Cat-scratch	Coffee bean
Lymphogranuloma	Spatlese lung
<b>Neoplasia</b>	<b>Other</b>
Carcinoma	Fibrosing alveolitis
Reticulosis	Whipple's disease
Pinealoma	Pyrexia of unknown origin
Dysgerminoma	Radiotherapy
Seminoma	Cancer chemotherapy
Reticulum cell sarcoma	Panniculitis
Malignant nasal granuloma	Chalazion
<b>Chemicals</b>	Sebaceous cyst
Beryllium	Dermoid
Zirconium	Sea urchin spine injury
Silica	Tattoo
Starch	Malakoplakia
	Blau's syndrome

Table 1. Classification of granulomatous disorders (cited from James DG, Williams WL) [8].

### Silicone granuloma

Silicone granuloma is a foreign body granuloma, which is characterized by the presence of multinuclear Datia cells and macrophages surrounded by lymphocytes and infiltrates of neutrophils. The granulomatous histological lesion caused by silicone varies depending on the type of silicone.

Tissue reactions to silicone gel or liquids are characterized by the formation of silicone granuloma with cystic space containing foreign body [9]. The irregular surface of silicone cannot be phagocytosed completely by macrophage. Datia cells are formed due to "frustrated" macrophages. Microspheres in the size of less than 15 microns will be phagocytosed and transferred to the lymph node, while those with big size and nonabsorbable polymer will be encapsulated by fibrotic tissue [10].



**Figure 2.** Results of histopathological examination (HE 400× magnification) in one of study subject. There is a Datia cell (arrow), which is phagocytosing silicone (S) and is trying to destroy it into smaller pieces (sk) [1].

Datia cell is essential in tissue response to silicone as seen in [Figure 2](#), in which the Datia cell is phagocytosing the silicone. It appears that although the Datia cell cannot eliminate the silicone, it would produce fragmented silicone into smaller pieces. Within a month, the silicone will be in the size of 20–100 microns [11]. However, it still cannot be completely phagocytosed, and ultimately it will be encapsulated by fibrotic tissue.

In general, silicone granuloma can be categorized into three phases according to the natural history of our immune response, which are mild inflammatory phase, i.e., stage 1; inflammation with datia cells, i.e., stages 2, 3, 4, and 5; and tolerance phase with fibrosis, i.e., stages 6 and 7 ([Figure 3](#)).

According to Harlim in 2018, histopathological features of silicone granuloma can be categorized into seven stages, which are: [11]

Stadium 1, moderate reaction with a few inflammatory cells

Stadium 2, inflammatory cells with one or two Datia cells

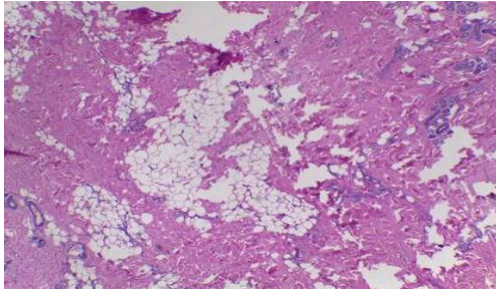
Stadium 3, inflammatory cells with more than two Datia cells and <50% fibrotic area

Stadium 4, inflammatory cells with more than two Datia cells and >50% fibrotic area

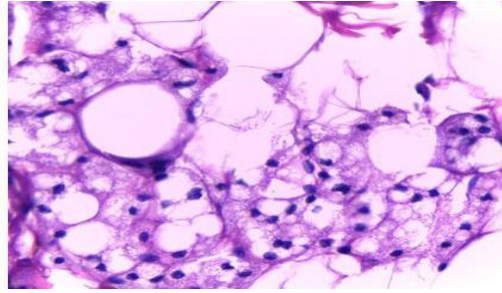
Stadium 5, inflammatory cells with one Datia cell and >50% fibrotic area

Stadium 6, <50% fibrotic area with no Datia cell

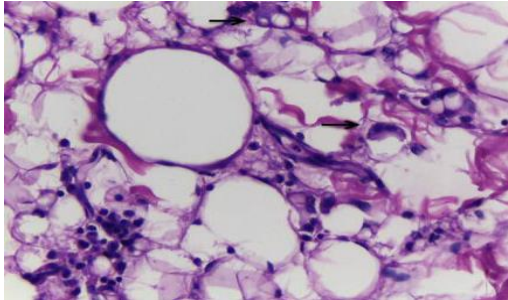
Stadium 7, >50% fibrotic area with no Datia cell



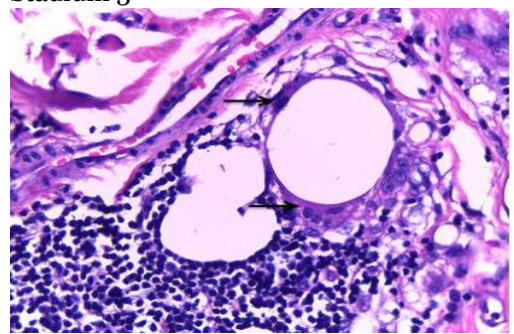
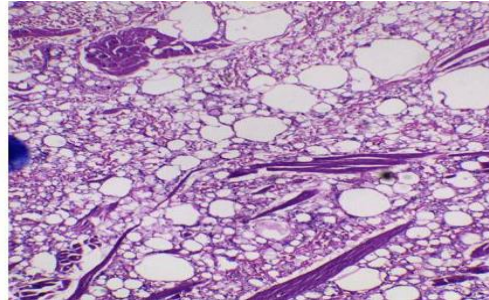
Stadium 1



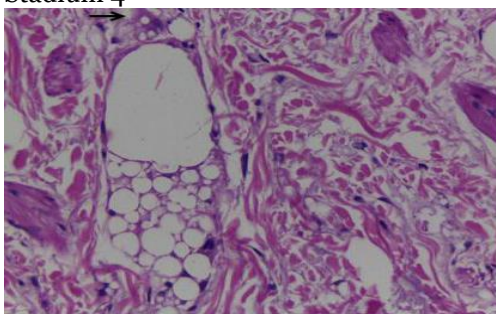
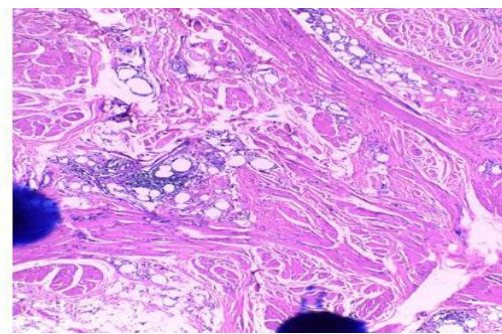
Stadium 2



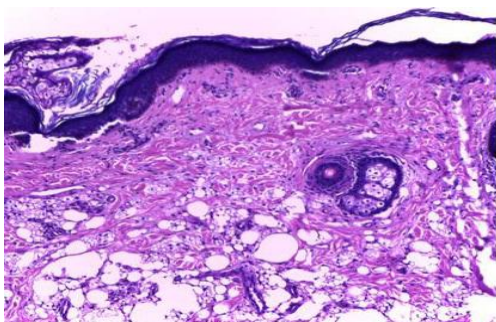
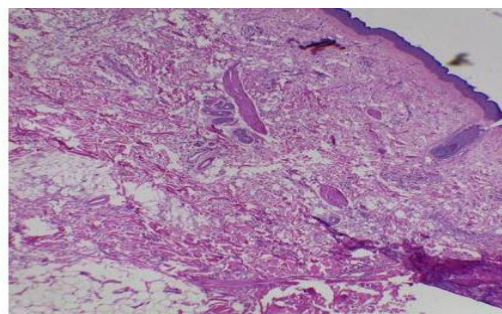
Stadium 3



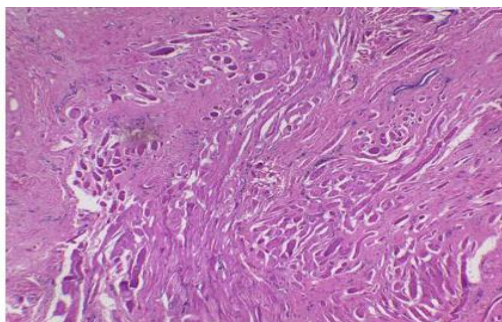
Stadium 4



Stadium 5



Stadium 6



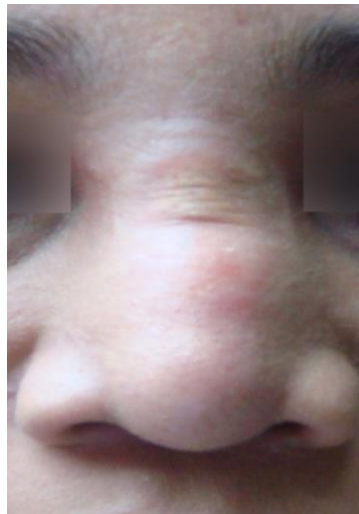Stadium 7

**Figure 3.** Stadium 1, moderate reaction with a few inflammatory cells. Stadium 2, inflammatory cells with one or two Datia cells. Stadium 3, inflammatory cells with more than two Datia cells and <50% fibrotic area. Stadium 4, inflammatory cells with more than two Datia cells and >50% fibrotic area. Stadium 5, inflammatory cells with one Datia cell and >50% fibrotic area. Stadium 6, <50% fibrotic area with no Datia cell. Stadium 7, >50% fibrotic area with no Datia cell. (cited from A Harlim, et all) [11].

### Diagnosis

Granuloma is a form of localized nodular inflammation, which is found in tissues [7]. On examination, there is a tumor-like mass or node of granulation tissue with active fibroblast growth and capillaries that contain epithelial-like macrophages surrounded by mononuclear cells, lymphocytes, and sometime multinucleated Datia cells present at the central core of granuloma [16].

On clinical point of view, silicone granuloma is characterized by the presence of complications of silicone. There are usually granuloma nodes, migrating silicone, wider nose, and signs of inflammation such as redness and swelling depending on the stage (Figure 4).



**Figure 4.** Granuloma due to nasal silicone injection. The photograph shows granuloma node, migrating silicone, wider nose, and signs of inflammation such as edema and redness.

### Management

The management of silicone-induced granuloma is often difficult due to migrating silicone and some of the silicone penetrating into the skin reaching the epidermis. In general, the management of granuloma can be categorized into two, i.e., surgical and pharmacological treatments. The management of nasal silicone granuloma is adjusted for the occurring complications. We must remove granuloma, which is under the skin; afterward, we perform excision of the excessive skin or implant insertion, creating a firmer and cosmetically more attractive skin. Remaining fibrosis or granuloma can be treated using steroid injection, and laser therapy is performed for redness.

### Recommendation for surgical care

Granuloma formation occurs due to the presence of foreign body. Skin granuloma will cause a cosmetic problem; therefore, it should be removed.

### Preoperative preparation

The preoperative preparation is similar to all kinds of skin surgery. A consultation prior to surgical procedure is necessary so that the doctor can perform both physical and psychological evaluation for the candidate. The patient should be informed about surgical procedure and the result may not be perfect as clean silicone injection can never be performed and there is a possibility of swelling. Patients with extreme high expectation will file their complaints in the future.

During the consultation, we must find out about coagulation disorder, either primary or secondary, either due to medication of pharmacological treatment or supplementation. The patients are advised to avoid food or medication that may prolong the bleeding time within 1 or 2 weeks prior to the procedure such as anticoagulants, aspirin, ginseng, garlic, cod liver oil, anticholesterol agent, vitamin E, warfarin, and Ginkgo biloba.

Curettage procedure of nasal silicone granuloma is similar to skin graft procedure, in which the covering skin must be viable. On curettage, the skin will be thinner, and it can be necrotic if there is

poor vascularization. Other issues that should come into our consideration are alcohol intake, smoking habit, metabolic disorder, and poor nutrition. Blood pressure and diabetes mellitus must be well-controlled [17, 18, 19].

### **Informed consent**

When a skin surgeon decides to perform a surgical procedure, both doctor and patient must consequently understand the impact, risk, and advantages of the procedure. First, the doctor needs to explain the diagnosis and the procedure that will be performed. Treatment of nasal silicone injection is a combination of medical therapy and cosmetic procedure because when it is left untreated, there will be changes such as migration, granuloma, and continuous inflammation. The risks and the advantages of the procedure should be emphasized. Moreover, the procedure during the surgery and the expected result after surgery need to be explained. Possible risks that may develop such as infection and its prevention including the use of antibiotics must also be explained. Patients must know other probable risks such as bleeding, crooked nose, wound scar that probably occurs, asymmetrical nostrils, an implant impression on the skin, granuloma or fibrosis that cannot be cleaned up, persistent redness of skin color, and other modalities of treatment that need to be carried out after the surgical procedure. It should also be explained that the results probably may be imperfect, particularly for patients with unrealistic wish. Results of discussion and patient's consent are written on an informed consent form, which is subsequently signed by the doctor and patient.

### **Technique and procedure**

Every granuloma in the skin that causes cosmetic problem must be removed. Granuloma at inflammatory phase must also be removed to prevent the extension of inflammation. Local or general anesthesia could be used for procedures of skin excision, granuloma curettage, or installation of nasal implant. Instruments that must be prepared included minor surgery set, which can be equipped with curettage kit for cases that need curettage.

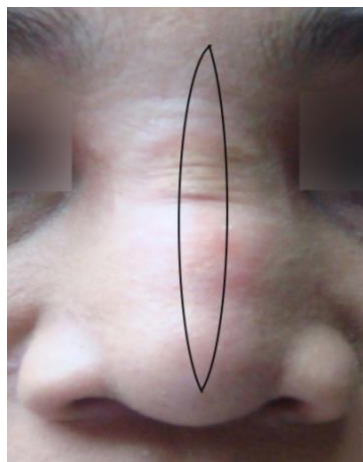
### **Preoperative Planning**

The management of silicone-induced granuloma depends on the affected area; however, basically a doctor will first make a design planning. Next, the doctor will perform procedures according to the design or images and following the plan that has been discussed with the patient.

Depending on the occurring complication, we evaluate whether we need to remove the excessive skin from the nasal columella or should only perform curettage and subsequently install a nasal implant.

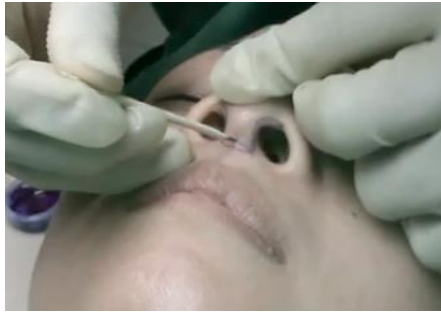Mark the area that will be excised and the protruding granuloma on the dorsal of the nose; therefore, during the surgery we emphasize on the location where the curettage will take place. If we plan to place a solid nasal implant, then we need to make a midline to ensure the implant stays straight when the swelling occurs due to anesthetic drugs.

Depending on the problem, when the nasal dorsum has become wider along with inflammation and the damaged skin, an elliptical vertical excision can be performed on it (Figure 5).



**Figure 5.** Elliptical excision of granuloma on the nasal skin.

During silicone injection, it is common to have a wider and descending skin at the area of nasal columella due to migration of silicone injection, which always run downward from the nose; therefore, a skin excision can be performed at lateral and dorsal areas of the nasal columella (Figure 6).



**Figure 6.** Design of excision procedure to remove the excessive skin at columella area.

### Technique

After we have planned the management to overcome nasal problems, we subsequently transfer the plan into preoperative design images and subsequently perform an incision or excision following the plan.

### Design of nasal implant

In some cases that require implants, the nasal implant is first carved before an excision is performed. Solid implant that has been commonly used is the L-shaped solid implant; however, other kinds of solid implant can also be used.

In making an implant, there are some guidelines on facial esthetics and architectural balance that should be considered.

The face can be divided into three zones with identical width. The first includes a horizontal line from the hairline to the eyebrow; the second horizontal line is from the eyebrow to the nasal base and menton; and the third horizontal line is the line from the nasal base to the end border of the chin.

The association between the lips and chin should be evaluated. The chin projection is determined by a vertical line drawn from a point of one and a half ideal length of the nose to the part of vermilion of the upper lip. The lower lip cannot be more than 2 mm posterior to this line. The position of chin varies extremely depending on sex. In women, the position is slightly posterior to the lower lips, while in men the position of the chin is in-line[20, 21].

The implant is carved or made prior to anesthetic procedure following the guidelines of architectural balance and problems of nasal silicone granuloma as well as the patient's preferences. For nasal silicone granuloma cases, L-shaped nasal solid implant is used, and part of the nasal bridge is shaved so that it becomes slender since patients with granuloma due to silicone injection usually have wider nose and they want the nose become slender (Figure 3).

The height or the length of the implant is the midline border between the eye and eyebrow up to the nose. The crus of the implant must be measured following the base of columella to the nose. Usually, the crus is made straight so that it can elevate the descending skin caused by silicone injection (

**Figure 9.** Patients with silicone injection usually have wider columella area since liquid silicone will migrate downward due to gravity. Therefore, we have to remove the excessive skin of the lateral and the dorsal columella and place the implant to create a straight nose.

Incision is always made on a hidden area and follows the contour of Langer's line. The excision is made following preoperative design image, which is an elliptical excision on the nasal dorsum (Figure 5); the procedure is generally performed when the condition is very severe with inflammation and the skin is wrinkled and extremely wider. The risks of the procedure are the formation of thin vertical scar line on the nasal dorsum and dog-ear phenomenon at the end of excision. An accurate calculation before surgery is essential. It is suggested that the skin removal should not be too wide to prevent dog-ear phenomenon or we can place a nasal implant so that it seems firm and creates a better look. Excision can also be made on the area adjacent to excision cut in order to reduce granuloma around the lateral nose. The skin superior to the granuloma must be thick enough to maintain vascularization and a viable skin. Many patients do not want any lengthy scar along their nose; therefore, the management of nasal silicone granuloma only includes curettage, placement of implant, and excision of the excessive skin at columella area.

After the patient received anesthetics using lidocaine or xylocaine without adrenalin, we perform a skin excision at the columella area and remove the excessive skin on the lateral and dorsal columella; afterwards, we perform undermining procedure inferior to the granuloma using a curved clamp starting from the nasal dorsum area to the nasal bridge near the glabella and lateral of nose

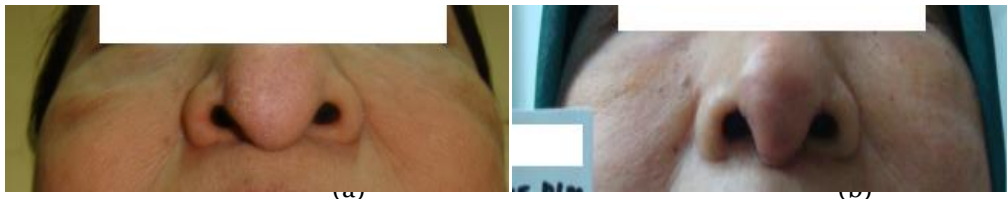depending on the occurring problem. Next, curettage is performed to remove the granuloma. The skin superior to it must be thick enough and well-vascularized. In cases with remaining granuloma with thick fibrosis and those with difficulty in curettage, other modalities should be performed after surgical recovery period such as steroid injection.

To create a good-shaped nose, we remove the excessive skin at the columella area, and at the nasal bridge, we can place an implant so that the skin is firmer and the shape is cosmetically better. Nasal silicone implant is placed under the nasal skin at the curettage area, which has been previously occupied by silicone granuloma.

We can perform curettage to remove silicone and granuloma. In order to create a better superior nasal tip so that the nose seems straighter, we have two choices. The first choice is that we can place the implant under the skin, and at the area, the curettage is performed; or we can put sutures at the lateral area of superior tip of the nose from lateral columella with opposite direction as presented in the following video.

### Postoperative Management

1. Use nasal splint or gauze for a week to prevent splint displacement.
2. Prescribing antibiotics for 5–7 days.
3. Prescribing analgetics every 4–6 hours as necessary.
4. Prescribing anti-inflammatory drugs for 5–7 days.
5. Normal saline solution for the nose to overcome postsurgical nasal congestion.
6. To reduce swelling, apply cold compress to periorbital within the first 48 hours.
7. When sleeping, the patient should keep the head elevated approximately 45°.
8. If there is a seroma, we can remove it by suctioning using syringe during the follow-up visit.
9. Avoid any trauma for 2 weeks.
10. Remove the stitches on day 10–14.
11. Have a normal diet, but avoid foods that cause excess lip movement such as apples and corn on the cob for 2 weeks after surgery ([Figure 10](#)).



**Figure 7.** Patients with silicone injection usually have wider columella area (a). After the excessive skin of the lateral and the dorsal columella are removed and the implant is placed, the columella area will be more slender, thus shaping a straighter nose (b).

### Adjunctive Therapy to Overcome Other Complications

The principle of therapy in managing patients with granuloma due to silicone injection is preventing the development of inflammation as it will cause extension of damage.

Evacuation of silicone-induced granuloma should be performed since the liquid silicone in the tissue is persistent and will continuously induce immune response. Although the granuloma has been excised, the remaining silicone, which has migrated to all direction and has been absorbed in the skin, cannot be removed, and therefore, it may cause recurrent granuloma. The remaining inflammation, both granuloma and fibrosis, requires further treatment.

For granuloma or fibrosis that cannot be removed by surgical procedure, other modalities are required to treat the remaining fibrosis and inflammation that can still be seen on the skin, i.e., skin redness and telangiectasia.

### Fibrosis and remaining granuloma

Some case reports suggest that to treat silicone-induced granuloma, intralesion injection can be used as well as topical treatment of pimecrolimus, which is applied two times daily for 3 months. Topical imiquimod can be used for 8 weeks as well as minoxidil, allopurinol, and oral prednisone at the dose of 30 mg/day [22, 23]. Results of those treatment have not been satisfying although intralesion injection of triamcinolone is more significant for treating the occurring inflammation [24].

Granuloma and remaining fibrosis may also be treated with subdermal injection of triamcinolone acetonide at a dose of 10 mg/ml or a combination of triamcinolone acetonide and 5-fluorouracil. Steroid injection can be performed at the earliest within 2 weeks after wound closure.



The injection is performed once or twice weekly as many as five to seven times. The dose depends on the amount of remaining granuloma and fibrosis, and usually it is at dose of 0.2–0.4 cc per injection.

Etanercept, which works on TNF- $\alpha$  receptor and Fc-IgG1 binding, has been reported providing good result for silicone granuloma [25, 26, 27]. The administration of this drug at the dose of 50 mg twice weekly or 25 mg of subcutaneous injection two times a week has offered relatively satisfying results [27].

### **Redness on Nasal Skin**

When the silicone has entered into the skin, it can cause granuloma due to chronic inflammation. Although the granuloma has been removed, the remaining inflammation, e.g., redness on skin, still exists. One of them is redness due to neovascularization such as telangiectasia due to silicone block in the skin.

Nasal redness and telangiectasia can be reduced using laser treatment. To utilize laser for treatment, we need basic knowledge about the use of laser.

There are three characteristic properties of laser light: monochromatic light. The light contains only a single wavelength, which is determined by the magnitude of released energy. The light has coherent characteristic, and the photon moves regularly as it has the same wavefront to one another.

The light is highly directional. A laser light has a very tight beam that is dense, strong, and concentrated. The three abovementioned characteristics can be achieved since there is a process of stimulated emission.

A light is part of the spectrum of electromagnetic radiation with an energy known as photon, while the molecule that absorbs the light is called chromophore. The energy is transferred from photon entering into chromophore in the skin. After the energy is absorbed, the light can initiate photochemical reaction, heat up the tissue to the state of coagulation or evaporation, and can destroy or detonate tissue structure through extremely rapid localized heating.

Laser is an instrument that produces light beam with certain wavelength or color that is very parallel and coherent. The light wavelength is absorbed maximally by the component of the treated skin. When the absorption characteristics of the target tissue accurately meet the most ideal wavelength, it will develop maximum specificity of laser to tissue interaction.

The mechanism of action of laser is consistent with specific chromophore with certain wavelength. There are three major chromophores in the body, which are hemoglobin, pigment, and water. For redness and telangiectasia cases, we use laser, which mostly works on hemoglobin. The wavelength of laser must be adjusted to the existing problem. Laser light enters the target area on the skin, and subsequently the light is absorbed by specific blood vessel in the skin causing damage on the target blood vessel that contains hemoglobin without injuring the surrounding tissue. We need basic knowledge to perform safer use of laser [28, 29].

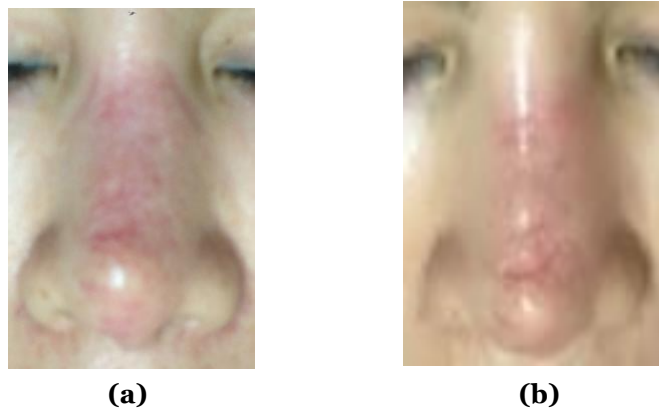
In addition to chromophore, we also need to know about thermal relaxation time (TRT). TRT is the time it takes for a target substance to cool half the temperature needed for heating the target without increasing the temperature of surrounding tissue. In order to perform safe procedure, the fluence of a laser pulse must be high enough to heat the target, and the pulse duration must be shorter than the TRT of the target. Each target has its own TRT. For blood vessel, which has TRT up to microseconds, we need long pulse duration; therefore, we should use the long-pulse Nd:Yag laser instead of the QS Nd:Yag laser, which only has pulse duration of nanoseconds. QS Nd:Yag is usually used for tattoo removal.

Laser works based on the selective photothermolysis principle. In this case, it can be used for hemoglobin to treat redness due to the silicone injection. Some lasers that can also be used are vascular laser such as pulse dye laser (PDL) or long-pulse Nd:Yag [30, 31].

A previous study shows that pulse dye laser (PDL) with a wavelength of 595 nm can be used for vascular disorder such as angioma, port-wine stain, rosacea, or other vascular disorders at the dose of 6–8 J/cm<sup>2</sup> every 8 weeks. To prevent side effect, cooling is always performed before laser procedure; some instruments have already had a cryo cooler. The side effects of post-PDL laser treatment are bruising, crust, post-inflammatory hyperpigmentation, particularly for skin types 3–6 according to Fitzpatrick classification [30].

Long-pulse Nd:Yag laser with a wavelength of 1064 nm is also good for treatment of vascular disorder. For deeper vascular disorders and those abnormalities in patients with dark skin types such as the Fitzpatrick skin types 3–6, the instrument will give greater advantages because the 1064 nm wavelength is usually used for pigment chromophore. In contrast, the instrument also has lower safety limit as poor cooling process can often burn the skin. Side effects of long-pulse Nd:Yag laser are bullae, crust, post-inflammatory hyperpigmentation, and scar [31, 32].

In utilizing the long-pulse Nd:Yag laser, we need to set the pulse duration. In silicone-induced disorders, there will be redness on the skin, and one of them is telangiectasia that requires higher dose but lower pulse duration



**Figure 8.** Illustration of a patient's skin due to complication of silicone injection on the nasal skin; there is an erythematous skin, and among them, there is a telangiectasia (a). After Nd:Yag laser, the reddish skin and telangiectasia are reduced (b).

In erythematous skin cases, the long-pulse Nd:Yag laser with a wavelength of 1064 nm, at dose of approximately 100 J, spot size of 4, and pulse duration of 10 ms, can be used. For telangiectasia, the power is approximately of 180 J, a spot size of 2, and pulse duration of 5 ms. Sufficient cooling before and after laser procedure should be done, either by using ice pack, air cooling, cryo, or other methods. The laser treatment should be started at a low dose, and the dose is increased gradually for each visit until a change can be observed. The target does not diminish instantly; the color does not always change rapidly; sometimes it only becomes paler.

### **Pitfalls and the Management**

For a necrotic skin, skin excision on the nasal dorsum is usually done, which is followed by curettage of the surrounding area. We usually clean up the necrotic area and performed wound care, open wound healing enhanced with topical medication that can induce granulation, laser diode, PRP, or others. In general, the wound will heal in 2–3 months.

Excessive granuloma or extensive fibrotic area occurs due to a hard necrotic skin, which creates difficulty in curettage. We can repeat the curettage procedure after a few months, which is followed by steroid injection. For less good-looking nose, excision procedure of the remaining skin can be repeated.

The skin can be burnt due to laser treatment for removing redness or telangiectasia for nasal area. Sufficient cooling before and after laser procedure should be done immediately. Sometime a strong topical steroid such as clobetasol propionate can be applied directly onto the skin after the laser procedure.

### **Conclusion**

Treatment for silicone-induced granuloma is not easy because the silicone that enters the skin can migrate and a lot of modalities are required to treat complications. Although the use of silicone injection has been prohibited, we still need to be cautious because there are many cosmetics containing silicone, especially with technological advances that can make the silicone readily absorbed by the skin.

### **REFERENCES**

1. Peters W, Fomarsier V. Complication from injectable material used for breast augmentation. *The Canadian Journal of Plastic Surgery*. 2009; 17(3).89-96
2. Harlim A, Aisah S, Sihombing R. Silicon Level in skin tissues of normal female individuals. *Journal of Pakistan Association of Dermatologists* 2018; 28:2
3. Eighteenth Report of the Joint FAO/WHO Expert Committee on Food Additives, Wld Hlth Org. Techn. Rep. Ser., No. 557. FAO Nutrition Meetings Report Series, No. 54. 1974. Available from: <http://www.inchem.org/documents/jecfa/jecmono/v06je42.htm>

4. Liles DT, Lin F. Silicon Elastomeric Particles in Skin Care Applications, Chapter 11. Vol 1053. Science & Technology Department; 2010. pp 207-219.
5. Nair A, Jacob S, Al-Dhublab B, Attimarad M, Harsha S. Basic considerations in the dermatokinetics of topical formulations. *Brazilian Journal of Pharmaceuticals Sciences*. 2013; 49(3): 423-434
6. Alcon Laboratories, Inc. Liquid Silicon Injection. 2010. Available from: <http://www.yesthebest.com/liquid-silicon-injection> [Accessed: August 18, 2010]
7. Granuloma. Medterms - Online Medical Dictionary [Internet]. 1998. Available from: <http://medterms.com> [Accessed: 20 March, 2011]
8. James DG, Williams WL. Classification of granulomatous disorders: A clinico-pathological synthesis. In: James DG, Zumla A, editors. *Granulomatous Disorders*. United Kingdom: Cambridge Press; 1999.p.17-27.
9. Bondurant S, Ernster V, Herdman R. Antinuclear antibodies and silikon breast implants. In: *Safety of Silikon Breast Implants*. Washington: The National Academy Press;1999. pp.198-214.
10. Lemperle G, Morhenn V, Charrier U. Human histology and persistence of various injectable filler substances for soft tissue augmentation. *Aesthetic Plastic Surgery*. 2003;27:354-366. DOI:10.1007/s00266-003-3022-1.
11. Harlim A, Kanoko M, Aisah S. Classification of foriegn body reaction due to industrial silicone injection. *Dermatologic Surgery*.2018 ;9(44):1174-1182
12. Price CT, Koval KJ, Langford JR. Silicon: A review of its potential role in the prevention and treatment of postmenopausal osteoporosis. *International Journal of Endocrinology*. 2013;2013:316783
13. Jugdaohsingh R. Silicon and bone health. *The Journal of Nutrion, Health & Aging*. 2007; 11(2): 99-109
14. James DG. A clinicopathological classification of granulomatous disorders. *Postgraduate Medical Journal*. 2000;76(898):457-465.
15. Agustini C, Semenzato G. Biology and immunology of granuloma. In: James DG, Zumla A, editors. *Granulomatous Disorders*. United Kindom: Cambridge Press; 1999.pp.3-16.
16. Granuloma. *Dorland's Medical Dictionary*. [Internet]. Saunders & Elsevier; 2007. Available from: <http://www.medical-dictionary.thefreedictionary.com>. [Accessed: 13 April 2007]
17. Pollack SV. Wound healing: A review . IV. Systemic medications affecting wound healing. *The Journal of Dermatologic Surgery and Oncology*. 1982;8:667-672.
18. Adams C, Ratner D. Composite and free cartilage grafting. *Dermatologic Clinics* 2005;23:129-140, vii.
19. Kovich O,Otley CC. Thrombotic complications related to discontinuation of warfarin and aspirin therapy perioperatively for cutaneous operation. *Journal of the American Academy Dermatology*. 2003;48:233-237.
20. Sheen JH, Sheen AP. *Aesthetic Rhinoplasty*, 2nd ed. St Louis: Quality Medical Publishing, 1998.
21. Tardy ME. *Rhinoplasty: The Art and the Science*. Philadelphia: WB Saunders, 1997.
22. Ellis LZ, Cohen JL, High W. Granulomatous reaction to silicone injection. *The Journal of Clinical and Aesthetic Dermatology*. 2012;5(7):44-7.
23. Arin MJ, Bate J, Krieg T, Hunzelmann N. Silicone granuloma of face treated with minocycline. *The Journal of American Academy of Dermatology*. 2005;52(2): S53-S56.
24. Sharma MD, Hou D, Liu Y, Koni PA, Metz R, Chandler P, et al. Indoleamine 2,3-dioxygenase controls conversion of Foxp3+ Tregs to Th17-like cells in tumor-draining lymph nodes. *Blood*. 2009; 113: 6102-6111.
25. Pasternack FR, Fox LP, Engler DE. Silicone granulomas treated with etanercept. *Archieves Dermatology*. 2005;141(1):13-15.
26. Desai AM, Browning J, Rosen T. Etanercept therapy for siicone granuloma. *Journal of Drugs in Dermatology* . 2006;5(9):894-896
27. Styperek A, Bayers S, Beer K. Nonmedical-grade injections of permanent fillers medical and medico-legal considerations. *The Journal of Clinical and Aesthetic Dermatology*. 2013; 6(41): 20-27.
28. Wheeland RG. Clinical uses of lasers in dermatology. *Lasers in Surgery and Medicine*. 1995; 16: 2-23.
29. Nelson JS. An introduction to lasers and laser-tissue interactions in dermatology. In: Kaminer MS, Arndt KA, Dover JS, editors. *Principles and Practices in Cutaneous Laser Surgery*. 1 st ed. Philadelphia: Harcourt Saunders; 2002. pp. 59-77.
30. Brauner GJ. Cutaneous laser surgery: Historical perspectives. In: Kaminer MS, Arndt KA, Dover JS, editors. *Principles and Practices in Cutaneous Laser Surgery*.1 st ed. Philadelphia; Harcourt Saunders; 2002. pp. 3-57.

31. Smit JM, Bauland CG, Winberg DS, Spauwen PHM. Pulsed dye laser treatment, a review of indication and outcomes based on published trials. *Journal of Plastic , Reconstructive & Aesthetic Surgery* 2005 :58(7): 981-987
32. Say Mese E, Gokhan O, Gokemir G. Treatment outcomes of long pulsed Nd:Yag laser for two different subtypes of rosacea. *The Journal of Clinical and Aesthetic Dermatology* 2015:8(9): 16-20