

We are IntechOpen, the world's leading publisher of Open Access books Built by scientists, for scientists

4,800

Open access books available

122,000

International authors and editors

135M

Downloads

Our authors are among the

154

Countries delivered to

TOP 1%

most cited scientists

12.2%

Contributors from top 500 universities



WEB OF SCIENCE™

Selection of our books indexed in the Book Citation Index
in Web of Science™ Core Collection (BKCI)

Interested in publishing with us?
Contact book.department@intechopen.com

Numbers displayed above are based on latest data collected.

For more information visit www.intechopen.com



Investigation into Whether Proximal Suspensory Desmitis of the Hindlimb Could Predispose Horses to Sacroiliac Disease

Anne Skivington, Milomir Kovac, Elena Zakirova, Albert A. Rizvanov and Catrin Sian Rutland

Abstract

Proximal suspensory desmopathy/desmitis (PSD) of the hindlimb is a well understood condition with widely accepted treatment protocols; however, there is little research demonstrating understanding or potential correlation between hindlimb PSD and sacroiliac disease (SID). Several studies have examined the co-existence of hindlimb PSD and SID each investigating unique predisposing factors. This has led to little direct correlation of cause and effect with no definitive conclusions drawn. The need to be objective is highlighted by the limited number of studies and that two studies used anecdotal evidence to support their hypothesis and thus creating the question does hindlimb proximal suspensory desmopathy predispose horses to sacroiliac disease? This review looks at the two conditions and compares the literature for each, including the incidence, biomechanics, anatomy, and treatment. The review further discusses whether one disorder predisposes horses/equids to the other.

Keywords: hindlimb proximal suspensory desmitis, sacroiliac disease, lameness, equine, sacroiliac joint, interosseous, kinematics

1. Introduction

The objective of this review was to assess whether there is a correlation between hindlimb proximal suspensory ligament desmopathy (hindlimb PSD) and sacroiliac dysfunction (SID), and provide an understanding of the current thought process of examining these disorders. There are several studies examining the coexistence of back pain and poor performance, however for the most part, the discussion focusses on the efficacy of diagnostic techniques of the thoracolumbar region with some recognition of influencing factors [1–3]. Some authors have assumed a correlation between the two disorders in their treatment programmes [4, 5] but none quantified the association or correlation of the two conditions. There are limited studies that have looked at the structure of the sacroiliac region and applied those principles to locomotion [2] however there are many text books that describe the structure alone [6, 7]. This chapter explores the two conditions and explores the background and present theories behind hindlimb PSD and SID.

1.1 Sacroiliac joint structure and function

The sacroiliac joint lies deep within the pelvis of the horse, made up of the sacrum (five vertebrae fused together) and the surrounding ligaments. It is known as an atypical synovial joint [2] and a cartilaginous joint [7]. The iliac surface has fibrocartilage coverage, with the sacral surface lined with hyaline cartilage, thus creating a modified symphysis [8]. There is great variation in the joint form from L shaped to C shaped either being relatively flat or concaved, although most are at an angle of 30° [2].

The sacroiliac joint lies between the ilium wings, forming a synchondrosis that is held in place by a multitude of ligaments. These ligaments are called the dorsal and ventral sacrosiatic ligaments and the broad sacrotuberous ligament [7]. The dorsal sacrosiatic ligament has two elements, a band that runs from the dorsal tuber sacrale to the apex of the sacral spinous processes; with the lateral dorsal sacrosiatic ligament running from the tuber sacrale and ilial wing to the sacral crest on the lateral aspect. The broad sacrotuberous ligament runs from the sacrum and transverse processes of the 1st and 2nd caudal vertebrae to the ischiatic spine and tuber ischium [2, 7]. The function of this joint is to provide a relatively inelastic structure that is capable of asymmetric pelvic deformation during movement [2, 9]. The muscle structure of the back plays significant influential roles in both anatomy and biomechanics.

The movement of the horses back differs depending on the location and medio-lateral swing of body mass; dorsoventral movement is seen with the greatest being middle of the back (40–47 mm per peak per stride) with a reduction cranially and caudally [10–12]. The natural movement of the lumbosacral area and the hindlimb produce a sinusoidal movement of no more than 4° within each stride cycle. Extension within this sinusoidal curve starts just moments before ground contact with the hoof, with the hindlimb at maximal protraction. In the sound horse this means that movement of the sacroiliac joint is minimal as longissimus dorsi is inactive in the impact and support phase of the flight arc of the hoof, in theory resulting in a stable joint [12–14]. Having said that linear regression revealed a significant deviation in movement over Lumbar 1 and Sacral 3 correlated to increasing speed [12]. This indicated that the movement of the back and sacroiliac joint is complex [2] and changes with every change in pace (**Figure 1**) [11].

The movement within the joint is assumed to be little [15] due to the middle gluteal and surrounding ligaments holding it in place. Despite this, a series of studies of the human sacroiliac joint revealed adaptations to forces transmitted through the joint;

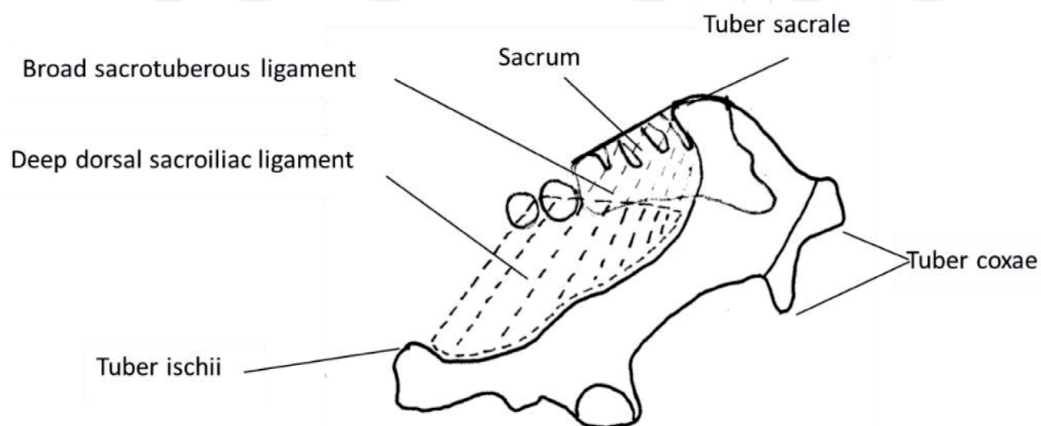


Figure 1.

Schematic of the right lateral view of the pelvis showing the position of the sacroiliac joint between the wings of the ilium and wing of the sacrum and the sacrotuberous ligament (adapted from [2]).

which was seen as roughened areas on the contrasting surfaces [16]. Comparable studies of the equine sacrum have looked at nutational forces to determine the degree of movement and suggested there is limited movement [2]. However, another investigation raised the interesting point that when the sacrotuberous ligament was cut there was a marked increase in movement [2]. This would seem obvious, as its function is to reduce movement but does suggest that ligament damage or laxity could cause increased asymmetrical movement which in itself could have an adverse effect on the soft tissue structures of the distal limb.

1.2 The interosseous muscle structure and function

The structure of the third interosseous muscle, also known as the suspensory ligament, the middle interosseous muscle or the interosseous ligament, is relatively straight forward. It originates from the proximal palmar surface of the metacarpal bones, running distally where just proximal to the sesamoid bones it bifurcates inserting on to each of the two sesamoid bones. From here it travels as the extensor branch joining the common digital extensor tendon. Even though it is termed a muscle, it is believed that once the horse matures it becomes completely collagenous in nature [7]. However, this is an over simplification as others describe the ligament as having a reduction of muscle fibres [17], while still retaining some which reduce with increased age [18, 19]. Muscle fibres quantitation showed a difference of 40% between the Thoroughbreds and Standardbreds with the Thoroughbred having less muscle fibres than its counterpart, with more muscle content being found in the hindlimb suspensory ligament than the forelimb [20]. It was also noted that the proximal region of the suspensory ligament contained less muscular tissue [19, 21]. This work also showed that the number of muscle fibres reduced with increased work intensity, thus suggesting that the suspensory ligament becomes less elastic and more susceptible to strain with increased work load (**Figure 2**).

The composition of the interosseous muscle is something of a hybrid, with the majority being collagen fibres but approximately 10% being type I muscle fibres and less than 5% type II muscle fibres. The suspensory ligament is defined by the infrequent fibroblasts embedded in the collagen matrix. These fibres are dispersed differently throughout the length of the ligament. Proximally, they are grouped as loose fascicles medially and laterally with the greater concentration just below the

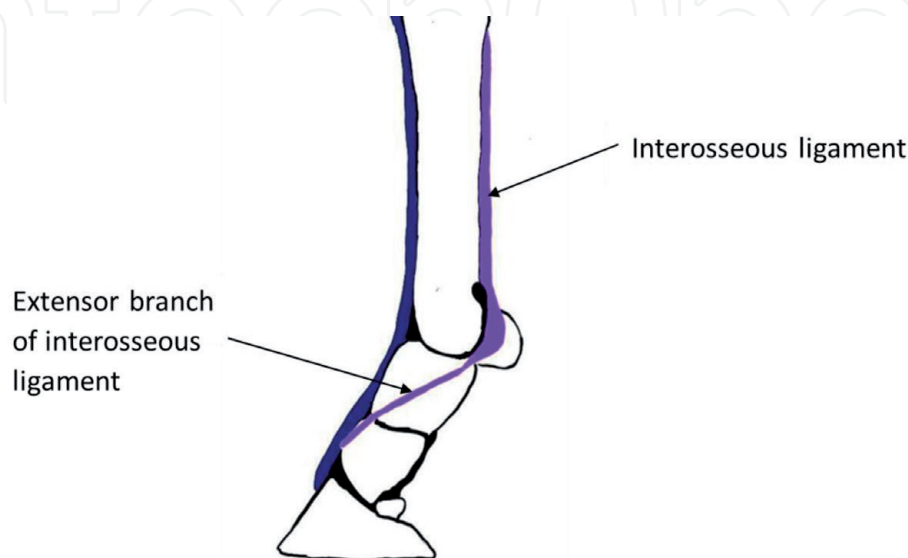


Figure 2. Schematic left lateral view showing the interosseous ligament of the hindlimb (adapted from Budras et al. [6]).

surface. As it reaches the three quarter mark they become less distinct, fewer in number with reduced striations. Interestingly these fibres are arranged pinnately between 45 and 80° [17, 22, 23] leading to theories that high forces are created because of the greater pinnate angle in order to stabilise the joint and indications that its purpose is anti-fatigue and postural support [24]. This was supported further by the suggestion that the elasticity of the lower limb, creating a vibration of 30–40 Hz, needs damping to reduce the likelihood of damage to tendons or bones and that this is achieved through these short muscle fibres [25, 26]. Due to the elastic nature of the suspensory ligament, it is unable to cope with sudden surges in force and is not built to deal with increased amounts of fatigue [27, 28]. It has also been noted that as the age of the horse increases so does the stiffness of a tendon unit which in turn could induce a change in kinematics [29].

1.3 Elastic strain energy

It is commonly understood that tendons and ligaments play an important role in elastic strain energy during locomotion. Humans and ungulates have evolved to have more efficient locomotory systems; with equine evolution determining the distal limb muscle mass would not only be challenging to manoeuvre but very costly in terms of energy expenditure. Thus we see tendons and ligaments in the distal limb as a means of storing elastic energy [25, 28, 30–33]. In order for the horse to utilise this mechanism within the suspensory ligament the energy from the ground reaction force is stored as strain energy to retract the limb [27, 32] helping to produce the break over point [34].

The function of the suspensory ligament is to stabilise the metacarpophalangeal joint and hindlimb in preventing hyper flexion in locomotion but also to act as part of the stay apparatus in preventing collapse of the fetlock joint when immobile [35, 36] effectively acting as passive control [17, 28]. However, the suspensory ligament differs slightly in its role compared to the other tendons of the distal limb. For example, the maximal stress the superficial digital flexor tendon (SDFT) and deep digital flexor tendon (DDFT) functions at is 40–50 MPa (mega-pascal units) compared to the suspensory ligament functioning at 18–25 MPa when in gallop; of course this is maximal output and decreases with decreased speeds. To gain a relative perspective, muscles work at 200–240 MPa. By comparison this seems quite small but provides an elastic energy saving of 25% for the suspensory ligament and 40% for the SDFT and DDFT which translates into an energy saving of 1.23 J/Kg at trot and 6 J/Kg at the gallop [33]; thus reducing metabolic expenditure [25, 31].

Biewener [31] calculated the peak activity stress mean standard deviation on the fore and hindlimb suspensory ligament with $53 \pm 14\%$ from walk to trot and $23 \pm 19\%$ into gallop. When ground reaction forces are considered and coupled with an increase in pace, the change in stress has an astonishingly small mean of 4%. This could be due to the kinematic calculation methods or potentially due to the biomechanical nature of the suspensory ligament. As the hoof makes contact with the ground, the suspensory ligament briefly stretches as a reaction to the ground reaction force and the sinking action of the metacarpal-phalangeal joint. The ligament then shortens to create an anti-hyperextension force. This elastic strain energy depends greatly upon the tendon shape and volume. These are varied as the suspensory ligament bifurcates distally resulting in a greatly reduced cross sectional area, leaving it under greater stress and strain [25, 31]. The elastic property of the lower limb is also heavily influenced by the individual gait pattern of each horse.

1.4 Kinematics and kinetics of locomotion

In order to understand the process of veterinary examination and its resultant observations; it is imperative to fully understand the kinematics and kinetics of the locomotion of the horse. The structure and function of the cursorial musculo-skeletal systems have evolved to provide structures and patterns of movement that favour acceleration, manoeuvrability speed and endurance [30, 37, 38] which has been harnessed over centuries for various disciplines such as racing and dressage.

It is also important to note the influence central pattern generators (CPG) and proprioception have on the biomechanics of the horse. The regulated rhythm of a pace is created by the CPG neurons which are capable of generating the stimuli and therefore a rhythmic motor behaviour. Even though some believe that the CPG neurons are capable of producing this regulatory rhythm without stimulus, sensory feedback is still required [39, 40]. Minute differences the timings or intensity of these impulses of the right and left central pattern generators cause asymmetrical movement [41]. Horses that have modified their locomotory movement in an attempt to compensate for discomfort or pain of either hindlimb PSD or SID will in effect cause the CPG neurons to adapt their “pacemaker” like outputs; thus creating a new norm for the horses locomotion [38].

Locomotion occurs as a result of torque at the hip joint [42, 43] and ground reaction forces exerted on the hoof which in gallop can be as much as 2.5 times the horses body weight [44, 45], with equal magnitude working in the opposite direction providing propulsion [46]. Therefore, it is worth considering the kinematic pattern of hoof placement, to determine how the pathology of SID and hindlimb PSD may occur. The structure and function of the cursorial musculoskeletal systems have evolved to provide structures and patterns of movement that favour acceleration, manoeuvrability speed and endurance [30, 37].

The hoof does not hit the ground with a total sole impact, but instead, as a measure of control, impacts the ground with the lateral edge. This reduces the concussive effect of the initial ground contact [47, 48]. It is important to remember that the hoof at ground contact is moving forward and downward during the initial loading phase [38]. The degree of impact when the hoof hits the ground is determined by several factors; the 57:43% split of vertical impulse for fore and hindlimb respectively [23, 38], the hoof mass, size and shape of the hoof, contact surface, type of shoe i.e. racing plate or hunter with or without grips or studs. These all influence the vertical and horizontal hoof velocity, and degree of slip [37, 38, 49]. The degree of lameness also has a large influence on interplay between hoof and ground reaction force [14].

Several studies have analysed hoof velocity [38, 44, 50], two of which have considered horizontal hoof velocity of fore and hindlimbs; one demonstrating the greatest being in the non-leading limb [49] and other the leading limb [51]. The hoof velocity and leading limb has important implications to the structures in the hindlimbs; if it is the forelimb the majority of the velocity will be absorbed by the thoracic sling, if it is the hindlimb the velocity can only end at the sacroiliac joint, although this is greatly simplified. Having said that, longitudinal velocity reduces (regardless of limb) as the horse starts to break in early stance phase. In this early phase the hindlimb suspensory ligament (third interosseous muscle) is at its peak inertial capacity to prevent hyper extension, while at the same time the pitch avoidance movement of raising the head and neck backwards increases forces on the pelvic limb, as the weight is shifted backwards in the late stance phase. This increases propulsion of the moment arms of the hindlimbs, creating oscillating forces though the hindlimb [28, 52]. These oscillating forces are created with

hoof-ground impact causing the limb to vibrate in a craniocaudal movement at 30–40 Hz, the greatest impact being distal in the limb. The muscles of the hindlimb act as adequate shock absorbers however risk of soft tissue damage increases with the increase in loading cycles [26]. This suggests that the greater the work load and discipline level of the horse, the more likely they are to sustain an injury. One method of removing force is slipping or sliding. The hoof is designed to allow an element of slip as a natural method of dissipating energy [53] however if sliding continues in the right conditions this can increase the risk of damage to soft tissue structures. Coupled with the ground reaction forces, this means that there are two opposing forces meeting at the horizontal axis, namely the sacroiliac joint [51].

1.5 Conformation of the horse

There are many variable factors when considering the relationship between hindlimb PSD and SID; one of which is the natural biological variation in every horse, in that no two are exactly the same in conformation which ultimately enhances or impedes function. Discipline desirable traits have been documented for enhancing performance, such as the warmblood breeds for dressage, with greater hock angle reducing the incidences of injury compare to those with smaller hock angles [54, 55]. However, this was refuted in a later study of 66 warmblood horses that had the supposedly undesirable tarsal joint angle of $<155.50^\circ$ [56]. This was agreed with in another study examining the hock angles of 194 Warmblood horses with hindlimb PSD [57]. Hobbs et al. [54] described a selection of horses that had variations between contralateral limbs conformation and those with bone morphology variance in contralateral limbs [58]. The results of these differences may induce compensatory movements in an attempt to redistribute the weight through the stride cycle. In an attempt to counter this, and stabilise the gait, the hindlimbs may start to load in a pattern similar to a lame horse. Having said that this load distribution pattern may come from the horses' handedness. This raises the question, if the horse is not physiologically capable of creating vertical impulsion (due to straight hocks), how and where will this affect the soft tissue structures in the hindlimb?

Asymmetries come in many forms, however each will have a marked effect on the biomechanics of the horse and more importantly the ground reaction forces; in the horses attempt to maintain equilibrium [54]. Of course, this need to maintain stability has different ground reaction forces depending on breed. Elite dressage Lusitano horses had lower vertical impulses compared to their Dutch Warmblood counterparts in collected trot with a range of 1.64 ± 0.02 N/Kg and 1.90 ± 0.08 N/Kg respectively. However this evened out with a change from collected trot to passage, with minimal difference being seen. Nevertheless, the key point in this is that the centre of mass is moved closer to the hindlimbs in the higher movements. Heim and co-authors [11] demonstrated a significant difference between Franches-Montagnes stallions ($n = 27$) and a general populous of horses ($n = 6$) in the dorsoventral movement ($p < 0.02$) and mediolateral movement ($p < 0.01$) for the spine, although to say this is a generalisation of differing anatomical parts and their role in locomotion. There is also the influence of the rider to consider here; not only as their body mass is part of the calculation but as the elite rider is capable of re-balancing even the most uneducated of horses to maintain the uphill longitudinal balance that is required of a dressage horse [59]. Dyson and colleagues [60] refuted this in their pilot study of rider weight, in that the weight of the rider had a greater significance than body mass index. Although this situation is not definitive, as there are many influencing factors in this scenario. For example, the balance of the rider and the dynamics between saddle and rider, both of which have a role in distribution of forces. In essence if the rider is displaced by an ill-fitting saddle or the rider

is inexperienced the horse has to re-balance itself in order to compensate [10, 44], which in itself produces compensatory locomotion. Another interesting factor relating to distribution of forces, body movement and rider interaction was demonstrated during the heavy and very heavy rider trials, as the horse demonstrated 3/8 lameness (based on the 0–8 grade lameness scale where 0 is sound and 8 is non-weightbearing) with these heavier riders [60]. The thoracolumbar width changed with weight of rider, from 3.9% with a light rider to 2.8% with a heavy rider. Heim et al. [11] noted that there was less mediolateral movement in the vertebrae when under saddle, with a difference of approximately 10 mm in the 3rd lumbar vertebrae as compared to an 8 mm difference in the movement of the tuber sacrale. This suggested that the horses may be bracing themselves against the movement of the heavier rider. However this was an observation and not a direct conclusion. It was also suggested that the interactive surface between horse and rider, the saddle, if not fitted correctly increased the mediolateral movement of the rider, which led to their conclusion that the closer contact the rider has with the horse the more likely they are to be working in equilibrium with them [10].

1.6 Conformation of the hoof and influence of shoeing

The conformation of the hoof capsule and the angle of the internal structures have a role to play in suspensory ligament desmopathy and limb kinematics. A significant level of research focusses on the correlation between the navicular bone angle and force applied to the deep digital flexor tendon [44, 61]. Although the research was not directed at the hindlimb suspensory ligament; their findings still shed light on this area due to the anatomical angle of bordering structure and limb kinematics. The shape of the hoof has been reported to change the kinetics and kinematics of the distal limb. Dyson et al. [61] reported that the distal phalanx to hoof wall angle and distal phalanx to horizontal angle were smallest for deep digital flexor tendon injuries at $52.27^\circ \pm 3.29$ and $50.32^\circ \pm 3.70$ (mean \pm SD) respectively. However, it would seem there was no direct correlation between that and the angles of the hoof wall. Research suggests that optimal hoof angles for both front and back feet should be 50–55° [62]. In addition, minimal correlation between the dorsal aspect of the distal phalanx angle and deep digital flexor tendon injury has been found and the hoof wall angle was not the same as the distal phalanx angle [61], which could account for natural variation in hoof pastern axis.

The deviation of distal phalanx angle affects the orientation of the structures above it and subsequently the metacarpophalangeal joint; which in turn has the potential to cause soft tissue injuries [63, 64]. This is because the ground reaction forces are reduced delaying break-over to latter breaking phase [64] whereas the horse should have increased loading at this point [62, 65]. This has the potential to reduce the strain on the interosseous muscle but could also inhibit the elastic strain energy needed to create its passive force.

Kane et al. [63] identified 43 race horses with ruptured suspensory ligaments with lower heel and toe angles; for example the difference between the toe heel angle control group and those with suspensory apparatus failure was 1.3° less, a relatively small number in terms of angles but quite significant over the lifetime of a horse. In real terms this means that an increase in angle of 10° increases the chance of suspensory ligament failure by 6.75 times [63].

Shoeing has been used since domestication of the horse as a means to improve performance and help maintain hoof balance. The combination of farriery techniques like rolled toes, plus different types of shoe have a significant effect on the horse's feet and their movement [34, 45, 66]. It could be assumed that the application of the shoe would only affect the gait pattern of the horse but an 11% vertical

displacement of the trunk has been observed [66], which implies a physiological effect of the structures of the back over a lifetime of a horse. Different types of shoe also have varying effects on the horse [67]. The glue on heart bar increased strain of the suspensory ligament while the racing plate alone increased strain in the superficial digital flexor tendon, interestingly when packing was added to the racing plate the increased strain was seen in the suspensory ligament. Others demonstrated an increase force of 101 N between the unshod and the steel shod foot [45, 66]. However, when looking at this in greater detail it can be seen that there is a difference in kinetics between the two states. By comparison the shod foot remains medial throughout the entire stance phase putting greater strain on the medial aspect of the limb structures. This is due to the gripping nature of the steel shoe which effectively shortens the natural slip effect of the bare foot and increases musculoskeletal forces after impact, altering the dampening effect of the suspensory ligament and preventing hoof and frog expansion on impact [34]. The stride duration also increased with the application of a shoe from (mean) 694 to 706 ms as did the stride length from 2.78 to 2.82 m; with the stride protraction and retraction decreasing after the application of shoes. This was seen as the carpal joint extending later in the swing phase and the foot being behind the movement at impact [66]. The unshod foot lands medially to then shift laterally at mid stance to then move back again medially. The application of a metal shoe removed the hoofs natural cycle of wear from the equation, which proved to be beneficial for the horse when assessing the morphology of 100 feral Brumbies [68]. Increased substrate hardness and distance travelled reduced the likelihood of hoof wall flare, however a possible negative of this is the loading of the peripheral sole in locomotion as well as the expected loading of the hoof wall [68].

1.7 Influence of discipline

There are many influencing factors when taking into consideration the relationship between horse and rider; the riders ability to control their balance, the weight of the rider and the fit of the saddle, all of these factors can have an effect on the equilibrium and the physiology of the horse. The influence of rider weight on horse movement has also been investigated. Riders were classified as light, medium, heavy and very heavy; all of which were classified as experienced riders [69]. Horses were subjectively and objectively observed with inertial sensors to determine movement at the poll and pelvis, each horse was then assessed with each rider. All heavy and very heavy rider assessments were abandoned due to temporary lameness inducement, suggesting a biomechanical change with the introduction of a dynamic load. In a study that used a lead weight added to the saddle they found the addition of weight extended the spine [70]. Thoracolumbar width changes have also been observed in another study, differing by 7.3% from the lightest to heaviest riders [71]. Variables such as saddle fit were accounted for by Master Saddlers checking prior to the tests being ridden and on the days of the test being ridden. However oscillation of the saddle in trot was reported with all rider weight groups; very heavy 14.0%, heavy 50.0%, medium 76.9% and light 84.6%, although there was no depth of discussion as to the occurrence of this except to say not all saddles fitted perfectly. Saddle bounce also occurred with the very heavy rider on 4 out of 6 horses, although this was associated with the horse being crooked in canter. Having said that, in the objective gait analysis a pelvic minimal difference of 2.2 ± 4.8 (mean \pm SD) was observed [72].

Influential factors also include rider height and leg length, as this affects the fit of the saddle for both horse and rider, plus the rider's core strength for which it is assumed that an increase in core strength would reduce rider movement in the

saddle. One of the stark conclusions drawn from this study was that lameness was observed in most of the horses when being ridden regardless of rider weight (that was not apparent in hand) and that the heavier riders consistently induced severe lameness [71, 72]. This research did not answer the question of rider weight ratio but it highlighted the importance of a well-fitting saddle and the role that it plays in maintaining normal gait patterns for that horse.

An important consideration is also the discipline of the horse and the movements they are required to perfect. An example of this was elite dressage horses which are required to produce collection; “maintaining impulsion from behind to allow a lighter shoulder”, to carry out higher level movements thus distinguishing the important factor of higher proportion of bodyweight carried by the pelvic limb [73]. Although this was recognised there was no appreciation that the movement must originate in the sacroiliac joint. Furthermore the link between tarsal joint compressions was made but not associated to orthopaedic injury. However this point was contradicted by the description that the greatest movement of the SIJ to be on the transverse plane [2]. This allowed for a wider overall viewpoint comparing the likelihood of SID by disciplines; with dressage horses and show jumpers being more susceptible [2]. This suggested that SID is induced by the greater degree of collection required of each discipline and increased angles of the moment arms of the hindlimbs, in effect reducing stability of the joint.

Data analysis primarily segregates elite and non-elite horses in order to classify gross morphology [73], demonstrating the understanding that each discipline has a differing physiological impact. This is then subdivided to location or type of injury. Conversely, they did not make the distinction in forelimb and hindlimb suspensory ligament injuries, and although there were a significant number of classifications observed, it was not stated whether these were distinct individual injuries or if the horses had sustained more than one [73]. However Barstow and Dyson [1] went a step further and subdivided their cohort into sacroiliac pain only and sacroiliac pain with hindlimb lameness; thus starting to demonstrate a correlation between the two. In comparison, others recognised the presence of other abnormalities but mainly focussed on osseous changes [74]. Dyson [61] considered an alternative perspective of tarsal conformation predisposing horses to PSD and acknowledged biomechanics as a possible influencing factor but again with no correlation to SID.

1.8 Surface variables

The surface that horses work on have to be taken into consideration as they directly influence the impact on hoof loading (hoof sliding and the declarative longitudinal forces) and therefore the reaction of the limb structures [38]. Surfaces vary based on their composition, a ménage situation will have a hard under layer with surface applied to a specific depth, while some race tracks will run on turf. The most important element here is the cushion depth as this has the potential to absorb some of the concussion [75, 76]. Having said that, a softer surface encourages the toe to pivot causing a rotational force on the distal limb structures [38]. In a human based assessment it was found that peak forces reduced with an increase in compliant surfaces [76]. The compliance of track surfaces has also been examined, each type of surface had a distinct effect on the hoof velocity and swing phase, with the greatest deformation coming from the most compliant surface [75]. Even though it was noted that this surface caused significant increases in stance time and angle of hoof on landing, they did not draw any conclusions from this or discuss the soft tissue implications for the horse. However, it does imply that the suspensory ligament would have to sustain its force for a prolonged period and thus potentially fatigue if longer stance time occurred. This concept was looked at in greater detail with the use

of a dynamometric shoe applied to three race horses which showed that turf surfaces had a greater ground reaction force (42.9 ± 3.8 g; mean \pm SEM) compared to synthetic surfaces which reduced the ground reaction forces significantly (28.5 ± 2.9 g; mean \pm SEM) [77]. This implies that there will be less impact on the soft tissue structures of the hindlimb and subsequently the sacroiliac joint.

1.9 Lameness and evaluation

In order to gain a full understanding of the relationship between hindlimb PSD and SID, the way in which the horse works, its discipline and level, plus the rider influence and ability must be considered [73, 78, 82]. Barstow and Dyson [1] used rider colloquialisms to aid quantification of lameness; this is very subjective even when well versed in this terminology [12]. This highlights the need to be objective and specific in pinpointing lameness. Similarly another study used anecdotal evidence to support their hypothesis of sports performance level and orthopaedic injury diagnosis, suggesting that this is frequently seen in practice but not yet documented [73]. Having said that, some studies [4, 5] have noted that some horses may suffer concurrent injuries of the sacroiliac joint or proximal suspensory (respectively) but did not draw conclusions from this regarding cause and effect or relationship.

As already stated, it is difficult, if not impossible to ascertain where the pain is coming from within the sacroiliac joint; one of the possibilities is the articular surface. As the horse ages there is an increased likelihood of cartilaginous deterioration irrespective of breed type or discipline. This deterioration and possible changes may be the result of long term laxity of the surrounding ligaments [83] which in itself could cause instability of the sacroiliac joint or degenerative suspensory desmitis which would alter the gait pattern of the horse permanently [84]. Another factor, of course, could be the ground reaction forces and the impact of hard work on hard ground for sustained periods.

It is recognised that lameness of the hindlimb creates compensatory movements within the lumbosacral region [74, 85]. Signs of subtle discomfort or pain are not so easily detected. A reduction in equine motivation to work or refusing jumps or bolting with their rider can be seen [4]. However, use of inertial measurement units can make the process of assessing asymmetry objective. The assessment of 60 horses used for polo showed 36 horses (60%) demonstrated an asymmetrical movement in the head, pelvic or both [86]. Statistical analysis linear regression revealed none of these measures had a slope greater in difference than zero. This tells us two things; that inertial measures are able to quantify small asymmetries in the horse but the value of this in a lameness evaluation must be left with the veterinary professionals to interpret. In reality this technology is not commonly used in practice and the standardised approach is to use diagnostic nerve blocks to determine the area of pain. However, this is not straight forward as they need to be used in conjunction with clinical examination and imaging modalities. In fact Pilsworth and Dyson [87] described clinically sound horses receiving a palmer nerve block to have a change in gait. This was echoed by Denoix and co-authors [88] when describing the pitfalls of sacroiliac nerve blocks, in that potential error could cause a false positive. In contrast others focussed on the biomechanics of the entire vertebral column [11, 82] but limited the discussion of the limbs to kinematics. This was echoed following assessment of the dynamic asymmetry of polo ponies, which again reverberated the question of correlation and cause [89].

The need to be more specific was demonstrated by Murray et al. [73] in their results making reference to thoracolumbar and pelvis but not specifically the SIJ. Goff and co-authors [90] advanced this to identify degenerative changes of the SIJ causing poor performance. However there is no correlation to unilateral or bilateral distal

limb lameness. To emphasise the need to be unambiguous Murray et al. [73] used a large sample size (1069 horses), which potentially could be representative of the equine population. However, as the study was conducted at a referral hospital it would not represent primary veterinarians seeing acute injuries or stages of disease; emphasising the need for a retrospective study of primary veterinary practices.

In a study by Barstow and Dyson [1] 296 horses were assessed for SIJ pain, of which 203 (80%) showed hindlimb lameness with 181 specifically identified with proximal suspensory desmitis (89% [94% bilateral, 6% unilateral]). Although this represents relatively small numbers by comparison to sports performance studies [73] its findings are significant and showed a direct correlation. Furthermore, the work up of the horses was carried out by the same veterinarian reducing the likelihood of subjectivity in gait analysis.

In a similar study the prevalence of orthopaedic injuries was examined, classifying the horse by injury alone [91]. Having said that, discipline was acknowledged but no relationship established; although the kinematics of the show jumper's pelvic limb were noted. A limitation of this study was that the information was extracted from yard records rather than from veterinarian's records. Furthermore the initial assessments were made by several veterinarians potentially providing greater diversity in objectivity of lameness detection. In contrast, a unique perspective examining the likelihood of heritable degenerative suspensory ligament desmitis in the Peruvian Paso was published [92]. Dyson [61] demonstrated an understanding of this but also questioned conformation as a predisposing factor.

All of this begs the question as to how a horse with sacroiliac dysfunction and hindlimb PSD can be identified? Generalised pain detection using facial expressions has been used for many years with infants. Langford et al. [93] took this principle and adapted it to form the mouse grimace scale for those used in biomedical research, this was hailed as a great success as a pain indicator. Miller et al. [94] developed this further to include pain behaviours. The assessment of pain has always been subjective and relative to the experience of the practitioner, formalising a grimace scale for horses [95] has made this an objective process for the equine veterinarian. There are general indicators of pain as seen in the horse grimace scale whereby an assessment of the horses facial postures are calculated on an ethogram to determine general level of pain. For example, a horse with tension above the eye alone may not be indicative of pain, but coupled with ears stiffly backwards and prominent chewing muscles, it may indicate a level of pain [95]. The facial grimace scale alone has been identified as limiting an ethogram for equine pain behaviours both ridden and in hand has been developed [60]. Importantly this study ensured its efficacy by refining its use with a "within observer repeatability study" to confirm this as a suitable tool for quantifying pain behaviours. This concept was taken a step forward in order to develop a scale for the ridden horse, for example the horse moving on three tracks in trot or canter could be an indicator of sacroiliac pain [69–96]. Some other indicators are a direct reflexion of the location of pain such as bucking going into canter demonstrating pain in the sacroiliac region; however, a horse at the very start of its education may resist the rider and buck out of frustration. Having said that, persistent displays of these behaviours are a direct indicator of pain [69]. There are many more subtle signs including asymmetry of the tuber coxae and the tuber ischii that can be visually assessed by the practitioner, asymmetrical muscle mass of the superficial gluteal and holding the tail to one side can also be seen as pain indicators [97]. Saddle slip has also been identified as an indicator of hindlimb lameness with a direct correlation between bilateral and unilateral lameness ($p = 0.344$ and $p = 0.286$ respectively) [98]. This advancement could improve criteria in determining the subtle variations in lameness between sacroiliac dysfunction and hindlimb PSD.

2. Conclusions

Research in the last 10 years has focussed on poor performance and diagnostic techniques, back pain and biomechanics or suspensory ligament disease. The correlation of information to demonstrate that lameness may be from one or more sites in the horse is limited. This indicates the necessity for further studies to determine whether there are correlations between hindlimb proximal suspensory desmopathy and sacroiliac disease. Understanding whether correlations are present between the two disorders could have an impact on evaluation and diagnosis, treatment and recovery, prognostics and welfare.

Acknowledgements

Albert A. Rizvanov (<https://orcid.org/0000-0002-9427-5739>) was supported by state assignments 20.5175.2017/6.7 and 17.9783.2017/8.9 of the Ministry of Science and Higher Education of Russian Federation. Kazan Federal University was supported by the Russian Government Program of Competitive Growth. Catrin S. Rutland (<https://orcid.org/0000-0002-2009-4898>) was funded by the University of Nottingham.

Conflicts of interest

The authors declare no conflicts of interest.

Author details

Anne Skivington¹, Milomir Kovac², Elena Zakirova³, Albert A. Rizvanov^{1,3} and Catrin Sian Rutland^{1*}

¹ School of Veterinary Medicine and Science, Faculty of Medicine, University of Nottingham, UK

² Veterinary Clinic “New Century”, Moscow State Academy of Veterinary Medicine and Biotechnology, Moscow, Russia

³ Institute of Fundamental Medicine and Biology, Kazan Federal University, Kazan, Russia

*Address all correspondence to: catrin.rutland@nottingham.ac.uk

IntechOpen

© 2020 The Author(s). Licensee IntechOpen. This chapter is distributed under the terms of the Creative Commons Attribution License (<http://creativecommons.org/licenses/by/3.0>), which permits unrestricted use, distribution, and reproduction in any medium, provided the original work is properly cited. 

References

- [1] Barstow A, Dyson S. Clinical features and diagnosis of sacroiliac joint region pain in 296 horses: 2004-2014. *Equine Veterinary Education*. 2015;**27**(12): 637-647. DOI: 10.1111/eve.12377
- [2] Goff LM, Jeffcott LB, Jasiewicz J, McGowan CM. Structural and biomechanical aspects of equine sacroiliac joint function and their relationship to clinical disease. *Veterinary Journal*. 2008;**176**(3):281-293. DOI: 10.1016/j.tvjl.2007.03.005
- [3] Zimmerman M, Dyson S, Murray R. Close, impinging and overriding spinous processes in the thoracolumbar spine: The relationship between radiological and scintigraphic findings and clinical signs. *Equine Veterinary Journal*. 2012;**44**(2):178-184. DOI: 10.1111/j.2042-3306.2011.00373.x
- [4] Dyson S. Hindlimb lameness associated with proximal suspensory desmopathy and injury of the accessory ligament of the suspensory ligament in five horses. *Equine Veterinary Education*. 2014;**26**(10):538-542. DOI: 10.1111/eve.12217
- [5] Bathe A. Outcome of the treatment of sacroiliac region pain. In: BEVA Congress. London, UK: British Equine Veterinary Association; 2012
- [6] Budras K, Sack WO, Rock S. *Anatomy of the Horse*. 6th ed. Hannover, Germany: Schlutersche; 2009
- [7] Pasquini C, Spurgeon T, Pasquini S. *Anatomy of Domestic Animals*. 11th ed. Texas, USA: Sudz Publishing; 2007
- [8] Reese WO. *Functional Anatomy and Physiology of Domestic Animals*. 4th ed. Iowa, USA: Wiley-Blackwell; 2009
- [9] Haussiler KK, McGilvray KC, Ayturk UM, Puttlitz CM, Hill AE, McIlwraith CW. Deformation of the equine pelvis in response to in vitro 3D sacroiliac joint loading. *Equine Veterinary Journal*. 2009;**41**(3):207-212. DOI: 10.2746/042516409x395697
- [10] Clayton HM, Hampson A, Fraser P, White A, Egenvall A. Comparison of rider stability in a flapless saddle versus a conventional saddle. *PLoS One*. 2018;**13**(6):e0196960. DOI: 10.1371/journal.pone.0196960
- [11] Heim C, Pfau T, Gerber V, Schweizer C, Doherr M, Schupbach-Regula G, et al. Determination of vertebral range of motion using inertial measurement units in 27 Franches-Montagnes stallions and comparison between conditions and with a mixed population. *Equine Veterinary Journal*. 2016;**48**(4):509-516. DOI: 10.1111/evj.12455
- [12] Warner SM, Koch TO, Pfau T. Inertial sensors for assessment of back movement in horses during locomotion over ground. *Equine Veterinary Journal*. 2010;**42**:417-424. DOI: 10.1111/j.2042-3306.2010.00200.x
- [13] Audigie F, Pourcelot P, Degueurce C, Denoix JM, Geiger D. Kinematics of the equine back: Flexion-extension movements in sound trotting horses. *Equine Veterinary Journal*. 1999;**31**: 210-213. DOI: 10.1111/j.2042-3306.1999.tb05219.x
- [14] Greve L, Pfau T, Dyson S. Thoracolumbar movement in sound horses trotting in straight lines in hand and on the lunge and the relationship with hind limb symmetry or asymmetry. *Veterinary Journal*. 2017;**220**:95-104. DOI: 10.1016/j.tvjl.2017.01.003
- [15] Degueurce C, Chateau H, Denoix JM. In vitro assessment of movements of the sacroiliac joint in the horse. *Equine Veterinary Journal*. 2004;**36**(8):694-698. DOI: 10.2746/0425164044848064

- [16] Vleeming A. The Sacroiliac Joint: A Clinical-Anatomical, Biomechanical and Radiological Study. Netherlands: University of Rotterdam; 1990
- [17] Soffler C, Hermanson JW. Muscular design in the equine interosseous muscle. *Journal of Morphology*. 2006;**267**:696-704
- [18] Dyce KM, Sack WO, Wensing CJ. *The Forelimb of the Horse*. USA: Saunders Elsevier; 2010
- [19] Spinella G, Loprete G, Castagnetti C, Musella V, Antonelli C, Vilar JM, et al. Evaluation of mean echogenicity of tendons and ligaments of the metacarpal region in neonatal foals: A preliminary study. *Research in Veterinary Science*. 2015;**101**:11-14. DOI: 10.1016/j.rvsc.2015.05.011
- [20] Wilson DA, Baker GJ, Pijanowski GJ, Boero MJ, Badertscher RR II. Composition and morphologic features of the interosseous muscle in Standardbreds and thoroughbreds. *American Journal of Veterinary Research*. 1991;**52**(1):133-139
- [21] Nagy A, Dyson S. Magnetic resonance imaging and histological findings in the proximal aspect of the suspensory ligament of forelimbs in nonlame horses. *Equine Veterinary Journal*. 2012;**44**(1):43-50. DOI: 10.1111/j.2042-3306.2011.00365.x
- [22] Clayton HM. Horse Species Symposium: Biomechanics of the exercising horse. *Journal of Animal Science*. 2016;**94**(10):4076-4086. DOI: 10.2527/jas.2015-9990
- [23] Payne RC, Hutchinson JR, Robilliard JJ, Smith NC, Wilson AM. Functional specialisation of pelvic limb anatomy in horses (*Equus caballus*). *Journal of Anatomy*. 2005;**206**(6):557-574. DOI: 10.1111/j.1469-7580.2005.00420.x
- [24] Crook TC, Cruickshank SE, McGowan CM, Stubbs N, Wakeling JM, Wilson AM, et al. Comparative anatomy and muscle architecture of selected hind limb muscles in the Quarter Horse and Arab. *Journal of Anatomy*. 2008;**212**(2):144-152. DOI: 10.1111/j.1469-7580.2007.00848.x
- [25] Biewener AA, Roberts TJ. Muscle and tendon contributions to force, work, and elastic energy savings: A comparative perspective. *Exercise and Sport Sciences Reviews*. 2000;**28**(3):99-107
- [26] Wilson AM, McGuigan MP, Su A, van den Bogert AJ. Horses damp the spring in their step. *Nature*. 2001;**414**(6866):895-899. DOI: 10.1038/414895a
- [27] Chavers JC, Allen AK, Ahmed W, Fuglsang-Damgaard LH, Harrison AP. The equine hindlimb proximal suspensory ligament: An assessment of health and function by means of its damping harmonic oscillator properties, measured using an acoustic myography system: A new modality study. *Journal of Equine Veterinary Science*. 2018;**71**:21-26. DOI: 10.1016/j.jevs.2018.09.006
- [28] Harrison SM, Whitton RC, Kawcak CE, Stover SM, Pandy MG. Evaluation of a subject-specific finite-element model of the equine metacarpophalangeal joint under physiological load. *Journal of Biomechanics*. 2014;**47**(1):65-73. DOI: 10.1016/j.jbiomech.2013.10.001
- [29] Addis PR, Lawson SE. The role of tendon stiffness in development of equine locomotion with age. *Equine Veterinary Journal*. 2010;**(38)**:556-560. DOI: 10.1111/j.2042-3306.2010.00296.x
- [30] Alexander MR, Alexander RM, Alex MR. *Principles of Animal Locomotion*. 2nd ed. USA: Princeton University Press; 2006

- [31] Biewener AA. Muscle-tendon stresses and elastic energy storage during locomotion in the horse. *Comparative Biochemistry and Physiology. Part B, Biochemistry & Molecular Biology*. 1998;**120**(1):73-87. DOI: 10.1016/s0305-0491(98)00024-8
- [32] Harrison SM, Whitton RC, Kawcak CE, Stover SM, Pandy MG. Relationship between muscle forces, joint loading and utilization of elastic strain energy in equine locomotion. *The Journal of Experimental Biology*. 2010;**213**(23):3998-4009. DOI: 10.1242/jeb.044545
- [33] Minetti AE, Ardigo LP, Reinach E, Saibene F. The relationship between mechanical work and energy expenditure of locomotion in horses. *The Journal of Experimental Biology*. 1999;**202**(17):2329-2338
- [34] Aoki O. Biomechanical analysis of horse shoeing. *Equine Veterinary Journal*. 1999;**31**:629-630. DOI: 10.1111/j.2042-3306.1999.tb05298.x
- [35] Symons J, Hawkins D, Fyhrie D, Upadhyaya S, Stover S. Modelling the interaction between racehorse limb and race surface. *Procedia Engineer*. 2016;**147**:175-180. DOI: 10.1016/j.proeng.2016.06.209
- [36] Back W, Clayton H. *Equine Locomotion*. 2nd ed. London, UK: Saunders Elsevier; 2013
- [37] Clayton HM, Dyson S, Harris P, Bondi A. Horses, saddles and riders: Applying the science. *Equine Veterinary Education*. 2015;**27**(9):447-452. DOI: 10.1111/eve.12407
- [38] Clayton HM, Hobbs SJ. Ground reaction forces: The sine qua non of legged locomotion. *Journal of Equine Veterinary Science*. 2019;**76**:25-35. DOI: 10.1016/j.jevs.2019.02.022
- [39] Dyer RM, Neerchal NK, Tasch U, Wu Y, Dyer P, Rajkondawar PG. Objective determination of claw pain and its relationship to limb locomotion score in dairy cattle. *Journal of Dairy Science*. 2007;**90**(10):4592-4602. DOI: 10.3168/jds.2007-0006
- [40] Guertin PA. Central pattern generator for locomotion: Anatomical, physiological, and pathophysiological considerations. *Frontiers in Neurology*. 2013;**3**:183. DOI: 10.3389/fneur.2012.00183
- [41] Dyson S. Science-in-brief: Horse, rider, saddlery interactions: Welfare and performance. In: *Saddle Research Trust 3rd International Conference*. Nottingham, UK: Saddle Research Trust; 2018
- [42] Hobbs SJ, Licka T, Polman R. The difference in kinematics of horses walking, trotting and cantering on a flat and banked 10 m circle. *Equine Veterinary Journal*. 2011;**43**(6):686-694. DOI: 10.1111/j.2042-3306.2010.00334.x
- [43] Williams SB, Payne RC, Wilson AM. Functional specialisation of the pelvic limb of the hare (*Lepus europeus*). *Journal of Anatomy*. 2007;**210**(4):472-490. DOI: 10.1111/j.1469-7580.2007.00704.x
- [44] Eliashar E. The biomechanics of the equine foot as it pertains to farriery. *Veterinary Clinics of North America: Equine Practice*. 2012;**28**(2):283-291. DOI: 10.1016/j.cveq.2012.06.001
- [45] Panagiotopoulou O, Rankin JW, Gatesy SM, Hutchinson JR. A preliminary case study of the effect of shoe-wearing on the biomechanics of a horse's foot. *PeerJ*. 2016;**4**:e2164. DOI: 10.7717/peerj.2164
- [46] Clayton HM. *The Dynamic Horse: A Biomechanical Guide to Equine Movement and Performance*. USA: Sport Horse Publications; 2004

- [47] Agass RF, Wilson AM, Weller R, Pfau T. The relationship between foot conformation, foot placement and motion symmetry in the equine hind limb. *Equine Veterinary Journal*. 2014;**46**(47):19-20
- [48] Johnston C, Back W. Hoof ground interaction: When biomechanical stimuli challenge the tissues of the distal limb. *Equine Veterinary Journal*. 2006;**38**(7):634-641. DOI: 10.2746/042516406x158341
- [49] Parsons KJ, Spence AJ, Morgan R, Thompson JA, Wilson AM. High speed field kinematics of foot contact in elite galloping horses in training. *Equine Veterinary Journal*. 2011;**43**(2):216-222. DOI: 10.1111/j.2042-3306.2010.00149.x
- [50] Boye JK, Thomsen MH, Pfau T, Olsen E. Accuracy and precision of gait events derived from motion capture in horses during walk and trot. *Journal of Biomechanics*. 2014;**47**(5):1220-1224. DOI: 10.1016/j.jbiomech.2013.12.018
- [51] Holden-Douilly L, Pourcelot P, Desquilbet L, Falala S, Crevier-Denoix N, Chateau H. Equine hoof slip distance during trot at training speed: Comparison between kinematic and accelerometric measurement techniques. *Veterinary Journal*. 2013;**197**(2):198-204. DOI: 10.1016/j.tvjl.2013.02.004
- [52] Channon AJ, Walker AM, Pfau T, Sheldon IM, Wilson AM. Variability of Manson and Leaver locomotion scores assigned to dairy cows by different observers. *The Veterinary Record*. 2009;**164**(13):388-392. DOI: 10.1136/vr.164.13.388
- [53] Harvey AM, Williams SB, Singer ER. The effect of lateral heel studs on the kinematics of the equine digit while cantering on grass. *Veterinary Journal*. 2012;**192**(2):217-221. DOI: 10.1016/j.tvjl.2011.06.003
- [54] Hobbs SJ, Nauwelaerts S, Sinclair J, Clayton HM, Back W. Sagittal plane fore hoof unevenness is associated with fore and hindlimb asymmetrical force vectors in the sagittal and frontal planes. *PLoS One*. 2018;**13**(8):e0203134. DOI: 10.1371/journal.pone.0203134
- [55] Holmstrom M, Magnusson LE, Philipsson J. Variation in conformation of Swedish Warmblood horses and conformational characteristics of elite sport horses. *Equine Veterinary Journal*. 1990;**22**(3):186-193. DOI: 10.1111/j.2042-3306.1990.tb04245.x
- [56] Sole M, Santos R, Gomez MD, Galisteo AM, Valera M. Evaluation of conformation against traits associated with dressage ability in unriden Iberian horses at the trot. *Research in Veterinary Science*. 2013;**95**(2):660-666. DOI: 10.1016/j.rvsc.2013.06.017
- [57] Routh J, Gilligan S, Strang C, Dyson S. Is there an association between straight tarsus (hock) conformation and hindlimb proximal suspensory desmopathy? *Equine Veterinary Journal*. 2017;**49**(51):17
- [58] Watson KM, Stitson DJ, Davies HM. Third metacarpal bone length and skeletal asymmetry in the thoroughbred racehorse. *Equine Veterinary Journal*. 2003;**35**(7):712-714. DOI: 10.2746/042516403775696348
- [59] Clayton HM, Schamhardt HC, Hobbs SJ. Ground reaction forces of elite dressage horses in collected trot and passage. *Veterinary Journal*. 2017;**221**:30-33. DOI: 10.1016/j.tvjl.2017.01.016
- [60] Dyson S, Berger J, Ellis AD, Mullard J. Development of an ethogram for a pain scoring system in ridden horses and its application to determine the presence of musculoskeletal pain. *Journal of Veterinary Behavior*. 2018;**23**:47-57. DOI: 10.1016/j.jveb.2017.10.008

- [61] Dyson S. Clinical commentary. Is degenerative change within hindlimb suspensory ligaments a prelude to all types of injury. *Equine Veterinary Education*. 2010;**22**(6):271-274
- [62] Lesniak K, Williams J, Kuznik K, Douglas P. Does a 4-6 week shoeing interval promote optimal foot balance in the working equine? *Animals*. 2017;**7**(4):29. DOI: 10.3390/ani7040029
- [63] Kane AJ, Stover SM, Gardner IA, Bock KB, Case JT, Johnson BJ, et al. Hoof size, shape, and balance as possible risk factors for catastrophic musculoskeletal injury of thoroughbred racehorses. *American Journal of Veterinary Research*. 1998;**59**(12):1545-1552
- [64] Ramsey GD, Hunter PJ, Nash MP. The effect of hoof angle variations on dorsal lamellar load in the equine hoof. *Equine Veterinary Journal*. 2011;**43**(5):536-542. DOI: 10.1111/j.2042-3306.2010.00319.x
- [65] McCarty CA, Thomason JJ, Gordon K, Hurtig M, Bignell W. Effect of hoof angle on joint contact area in the equine metacarpophalangeal joint following simulated impact loading ex vivo. *Equine Veterinary Journal*. 2015;**47**(6):715-720. DOI: 10.1111/evj.12354
- [66] Willemen MA, Savelberg HHCM, Barneveld A. The improvement of the gait quality of sound trotting warmblood horses by normal shoeing and its effect on the load on the lower forelimb. *Livestock Production Science*. 1997;**52**(2):145-153. DOI: 10.1016/S0301-6226(97)00130-9
- [67] Ault B, Starling G, Parkes R, Pfau T, Pardoe C, Day P, et al. The effects of three different shoeing conditions on tendon strain in the thoroughbred forelimb. *Equine Veterinary Journal*. 2015;**47**(48):17
- [68] Hampson BA, Ramsey G, Macintosh AMH, Mills PC, de Laat MA, Pollitt CC. Morphometry and abnormalities of the feet of Kaimanawa feral horses in New Zealand. *Australian Veterinary Journal*. 2010;**88**(4):124-131. DOI: 10.1111/j.1751-0813.2010.00554.x
- [69] Dyson S, editor. *The Influence of Rider to Horse Body Weight Ratios on Equine Gait and Behaviour: A Pilot Study*. London, UK: National Equine Forum; 2018
- [70] de Cocq P, van Weeren PR, Back W. Effects of girth, saddle and weight on movements of the horse. *Equine Veterinary Journal*. 2004;**36**(8):758-763. DOI: 10.2746/0425164044848000
- [71] Quiney LE, Ellis A, Dyson SJ. The influence of rider weight on exercise induced changes in thoracolumbar dimensions and epaxial muscle tension and pain. *Equine Veterinary Journal*. 2018;**50**(52):3-35
- [72] Dyson S, Ellis AD, Mackechnie-Guire R, Douglas J, Bondi A, Harris P. The influence of rider: Horse body weight ratio and rider horse saddle fit on equine gait and behaviour: A pilot study. *Equine Veterinary Education*. 2019;**2**:1-13
- [73] Murray RC, Dyson SJ, Tranquille C, Adams V. Association of type of sport and performance level with anatomical site of orthopaedic injury diagnosis. *Equine Veterinary Journal*. 2006;**(36)**:411-416. DOI: 10.1111/j.2042-3306.2006.tb05578.x
- [74] Girodroux M, Dyson S, Murray R. Osteoarthritis of the thoracolumbar synovial intervertebral articulations: Clinical and radiographic features in 77 horses with poor performance and back pain. *Equine Veterinary Journal*. 2009;**41**(2):130-138. DOI: 10.2746/042516408x345099
- [75] Burn JF, Usmar SJ. Hoof landing velocity is related to track surface properties in trotting horses. *Equine*

and Comparative Equine Physiology. 2005;**2**(1):37-41

[76] McMahon TA, Greene PR. The influence of track compliance on running. *Journal of Biomechanics*. 1979;**12**(12):893-904. DOI: 10.1016/0021-9290(79)90057-5

[77] Setterbo JJ, Garcia TC, Campbell IP, Reese JL, Morgan JM, Kim SY, et al. Hoof accelerations and ground reaction forces of thoroughbred racehorses measured on dirt, synthetic, and turf track surfaces. *American Journal of Veterinary Research*. 2009;**70**(10):1220-1229. DOI: 10.2460/ajvr.70.10.1220

[78] Dyson S. Evaluation of poor performance in competition horses: A musculoskeletal perspective. Part 2: Further investigation. *Equine Veterinary Education*. 2016;**28**(7):379-387. DOI: 10.1111/eve.12498

[79] Dyson S, Murray R. Pain associated with the sacroiliac joint region: A clinical study of 74 horses. *Equine Veterinary Journal*. 2003;**35**(3):240-245. DOI: 10.2746/042516403776148255

[80] Dyson S, Murray R. Management of hindlimb proximal suspensory desmopathy by neurectomy of the deep branch of the lateral plantar nerve and plantar fasciotomy: 155 horses (2003-2008). *Equine Veterinary Journal*. 2012;**44**(3):361-367. DOI: 10.1111/j.2042-3306.2011.00445.x

[81] Orsini JA. Equine biomechanics. *Journal of Equine Veterinary Science*. 2010;**30**(7):344. DOI: 10.1016/j.jevs.2010.06.001

[82] van Weeren PR, McGowan C, Haussler KK. Science overview: Development of a structural and functional understanding of the equine back. *Equine Veterinary Journal*. 2010;**42**:393-400. DOI: 10.1111/j.2042-3306.2010.00207.x

[83] Jeffcott LB. Disorders of the thoracolumbar spine of the horse—A survey of 443 cases. *Equine Veterinary Journal*. 1980;**12**(4):197-210. DOI: 10.1111/j.2042-3306.1980.tb03427.x

[84] Halper J, Mueller POE. Dystrophic mineralisation in degenerative suspensory ligament desmitis. *Equine Veterinary Education*. 2018;**30**(8):424-426. DOI: 10.1111/eve.12732

[85] Alvarez CBG, Bobbert MF, Lamers L, Johnston C, Back W, van Weeren PR. The effect of induced hindlimb lameness on thoracolumbar kinematics during treadmill locomotion. *Equine Veterinary Journal*. 2008;**40**(2):147-152. DOI: 10.2746/042516408x250184

[86] Pfau T, Parkes RS, Burden ER, Bell N, Fairhurst H, Witte TH. Movement asymmetry in working polo horses. *Equine Veterinary Journal*. 2016;**48**(4):517-522. DOI: 10.1111/evj.12467

[87] Pilsworth R, Dyson S. Where does it hurt? Problems with interpretation of regional and intra-synovial diagnostic analgesia. *Equine Veterinary Education*. 2015;**27**(11):595-603. DOI: 10.1111/eve.12392

[88] Denoix JM, Jacquet S. Ultrasound-guided injections of the sacroiliac area in horses. *Equine Veterinary Education*. 2008;**20**(4):203-207. DOI: 10.2746/095777308x292128

[89] Burden ER, Pfau T, Witte TH. Objective assessment of gait asymmetry in polo ponies. *Equine Veterinary Journal*. 2013;**45**(44):9

[90] Goff L, Jeffcott L, Riggs C, McGowan C. Sacroiliac joint morphology: Influence of age, body weight and previous back pain. In: *International Conference on Equine Exercise Physiology*. Chester, UK: *Equine Veterinary Journal*; 2014

[91] de Sousa NR, Luna SPL, Pizzigatti D, Martins MTA, Possebon FS, Aguiar ACS. Relation between type and local of orthopaedic injuries with physical activity in horses. *Ciência Rural*. 2017;47(2):36-41. DOI: 10.1590/0103-8478cr20151218

[92] Luo W, Sandy J, Trella K, Gorski D, Gao S, Li J, et al. Degenerative suspensory ligament desmitis (DSLDD) in Peruvian Paso horses is characterized by altered expression of TGFbeta signaling components in adipose-derived stromal fibroblasts. *PLoS One*. 2016;11(11):e0167069. DOI: 10.1371/journal.pone.0167069

[93] Langford DJ, Bailey AL, Chanda ML, Clarke SE, Drummond TE, Echols S, et al. Coding of facial expressions of pain in the laboratory mouse. *Nature Methods*. 2010;7(6):447-449. DOI: 10.1038/nmeth.1455

[94] Miller AL, Kitson GL, Skalkoyannis B, Flecknell PA, Leach MC. Using the mouse grimace scale and behaviour to assess pain in CBA mice following vasectomy. *Applied Animal Behaviour Science*. 2016;181:160-165. DOI: 10.1016/j.applanim.2016.05.020

[95] Dalla Costa E, Minero M, Lebelt D, Stucke D, Canali E, Leach MC. Development of the Horse Grimace Scale (HGS) as a pain assessment tool in horses undergoing routine castration. *PLoS One*. 2014;9(3):e92281. DOI: 10.1371/journal.pone.0092281

[96] Hockenull J, Creighton E. The use of equipment and training practices and the prevalence of owner-reported ridden behaviour problems in UK leisure horses. *Equine Veterinary Journal*. 2013;45(1):15-19. DOI: 10.1111/j.2042-3306.2012.00567.x

[97] Dyson S. Proximal suspensory desmitis in the hindlimb. In: 9th

International Congress of World Equine Veterinary Association (WEVA). Marrakech, Morocco: World Equine Veterinary Association; 2009

[98] Greve L, Dyson SJ. An investigation of the relationship between hindlimb lameness and saddle slip. *Equine Veterinary Journal*. 2013;45(5):570-577. DOI: 10.1111/evj.12029