

# We are IntechOpen, the world's leading publisher of Open Access books Built by scientists, for scientists

4,800

Open access books available

122,000

International authors and editors

135M

Downloads

Our authors are among the

154

Countries delivered to

TOP 1%

most cited scientists

12.2%

Contributors from top 500 universities



WEB OF SCIENCE™

Selection of our books indexed in the Book Citation Index  
in Web of Science™ Core Collection (BKCI)

Interested in publishing with us?  
Contact [book.department@intechopen.com](mailto:book.department@intechopen.com)

Numbers displayed above are based on latest data collected.  
For more information visit [www.intechopen.com](http://www.intechopen.com)



# Management of Ascending Aorta Calcification in Coronary Artery Bypass Grafting

*Chuan Wang, Yang Yu, Chengxiong Gu and Jingxing Li*

## Abstract

Neurological complications are one of the most common complications after coronary artery bypass grafting. With the development of off-pump coronary artery bypass grafting (OPCABG), the incidence of postoperative neurological complications caused by aortic intubation decreased significantly; however, the continuous suture of the great saphenous vein-aortic anastomosis in the coronary artery bypass grafting requires the operation of surgical clamp and perforation on the ascending aorta, which may lead to potential plaque detachment. Calcification of ascending aorta is an independent risk factor for cerebrovascular events after OPCABG. Therefore, it is crucial to explore and operate on the ascending aorta. There are three main methods of proximal anastomosis in OPCABG: (1) partial blocking of ascending aorta with side wall clamp for anastomosis; (2) application of proximal anastomosis auxiliary device (Enclose, Heartstring, etc.) for proximal anastomosis; and (3) original auxiliary device (urethra catheter-water sac) or no-clamp surgical techniques for proximal anastomosis.

**Keywords:** neurological complications, coronary artery bypass grafting, ascending aorta, stroke, clamp, proximal anastomosis, auxiliary device

## 1. Introduction

Neurological complications are the most common complications after coronary artery bypass grafting (CABG) with high mortality rate [1]. With the advantages of off-pump coronary artery bypass grafting (OPCABG), the proportion of OPCABG in CABG is increasing continuously. The use of OPCABG procedures peaked in 2002 (23%) and in 2008 (21%), followed by a progressive decline in OPCABG frequency to 17% by 2012 [2]. OPCABG is regarded as a milestone in the development of CABG and the most effective minimally invasive surgery as it avoids the injury of multiple organ malfunction caused by cardiopulmonary bypass [3–4]. With the widespread of OPCABG, the incidence of postoperative neurological complications caused by aortic intubation decreased significantly [5–6]. Nevertheless, great saphenous vein is still the main material for most CABG. It has been nearly half a century since the continuous suture of the great saphenous vein-aortic anastomosis in the coronary artery bypass grafting required the operation of surgical clamping and perforation on the ascending aorta, which may lead to potential plaque detachment and cause

postoperative neurological complications [4]. Calcification of ascending aorta is an independent risk factor for cerebrovascular events after OPCABG, especially for postoperative stroke [3]. Therefore, careful exploration and accurate management of the ascending aorta are important. Traditional proximal anastomosis in OPCABG requires partial blocking of ascending aorta with side wall clamp; however, for patients with ascending aortic disease (e.g., serious ascending aorta atherosclerosis), connective tissue disease-related arteritis and syphilitic arteritis, the mechanical damage of aortic intima may be caused by the lateral cutting force produced by side wall clamp, which may lead to the rupture, dissection of aorta, rupture and detachment of atherosclerotic plaque and other serious perioperative complications. In recent years, a large number of auxiliary devices for proximal anastomosis of grafts have emerged, which can complete great saphenous vein-aortic anastomosis safely, simply, reliably and quickly without clamping ascending aorta, including commercial proximal anastomosis auxiliary device (Enclose, Heartstring, etc.) [7–9], original auxiliary device (urethra catheter-water sac) or no-clamp surgical techniques for proximal anastomosis [10–12]. This chapter will mainly introduce the anastomotic method of the auxiliary device of proximal anastomose.

## 2. Enclose technique

Proximal anastomosis auxiliary device was introduced to resolve the disadvantage of side wall clamping [13]. These devices were designed to avoid clamping the lateral wall of the aorta and to reduce complications of the ascending aorta and the nervous system. For patients undergoing CABG, OPCABG is recommended to reduce the risk of cerebral complications caused by side wall clamping. Selective use of Enclose proximal anastomotic device in patients with severe ascending aorta atherosclerosis will be discussed in this section.

### 2.1 Composition and principle of Enclose II anastomotic device

The device is composed of upper and lower rhombic mechanical jaws. The upper knob can adjust the vertical movement of the upper jaw, and it can make the upper and the lower jaws match at the anastomosis position of the ascending aorta to form a low-pressure cavity. The lower knob controls the opening and closing of the rhombic membrane at the end of the lower jaw, which makes the proximal anastomose area form a bloodless field of vision.

### 2.2 Method of application

#### 2.2.1 Position selection

The ascending aorta should be explored routinely to avoid the atherosclerotic area on the aortic wall. Puncture site should be selected in the softest part of anterior wall of ascending aorta. The diameter of anastomosis area is about 1 cm.

#### 2.2.2 Placement

- First, a purse suture with 2–0 polypropylene suture and rubber sleeve is used at the insertion point, and then mean arterial pressure is maintained at 100 mmHg (1 mmHg = 0.133 kPa) by medical management. The aorta wall is

punctured at the central position of the purse suture with the puncture needle provided by Enclose.

- The lower jaw of Enclose is inserted into the aorta through the above-mentioned puncture point and placed at the pre-selected anastomotic position, and then the sleeve is tightened to limit the bleeding.
- Unscrew the membrane at the end of the lower jaw with the self-contained rotary rod of Enclose.
- Adjust the knob of the upper jaw to move the upper arm vertically downward and then attach the aortic adventitia and tighten the fixator. When no blood flows out of the suction tube of the lower arm, a blood-free environment is formed between the intima and the arterial wall. Behind the suction tube, a 50 ml syringe can be connected to absorb a small amount of blood oozing from the anastomosis area.
- Use a circular knife to cut the aortic wall at the preselected anastomosis position perpendicular to the metal rod of the lower jaw.
- Use Enclose's own perforator to drill through the aortic incision. The perforator shall be close to the metal rod of the lower jaw to ensure full layer drilling (**Figure 1**).

### *2.2.3 Anastomosis*

Anastomosis of saphenous vein (A) to ascending aorta (B) is performed with 6–0 polypropylene suture. The local bleeding that affects the suture field can be removed by suction. At the same time, maintain systolic blood pressure of systemic circulation at 90–100 mmHg level to reduce bleeding and ensure full layer suture of aortic wall and then exhaust and knot (**Figure 2**).

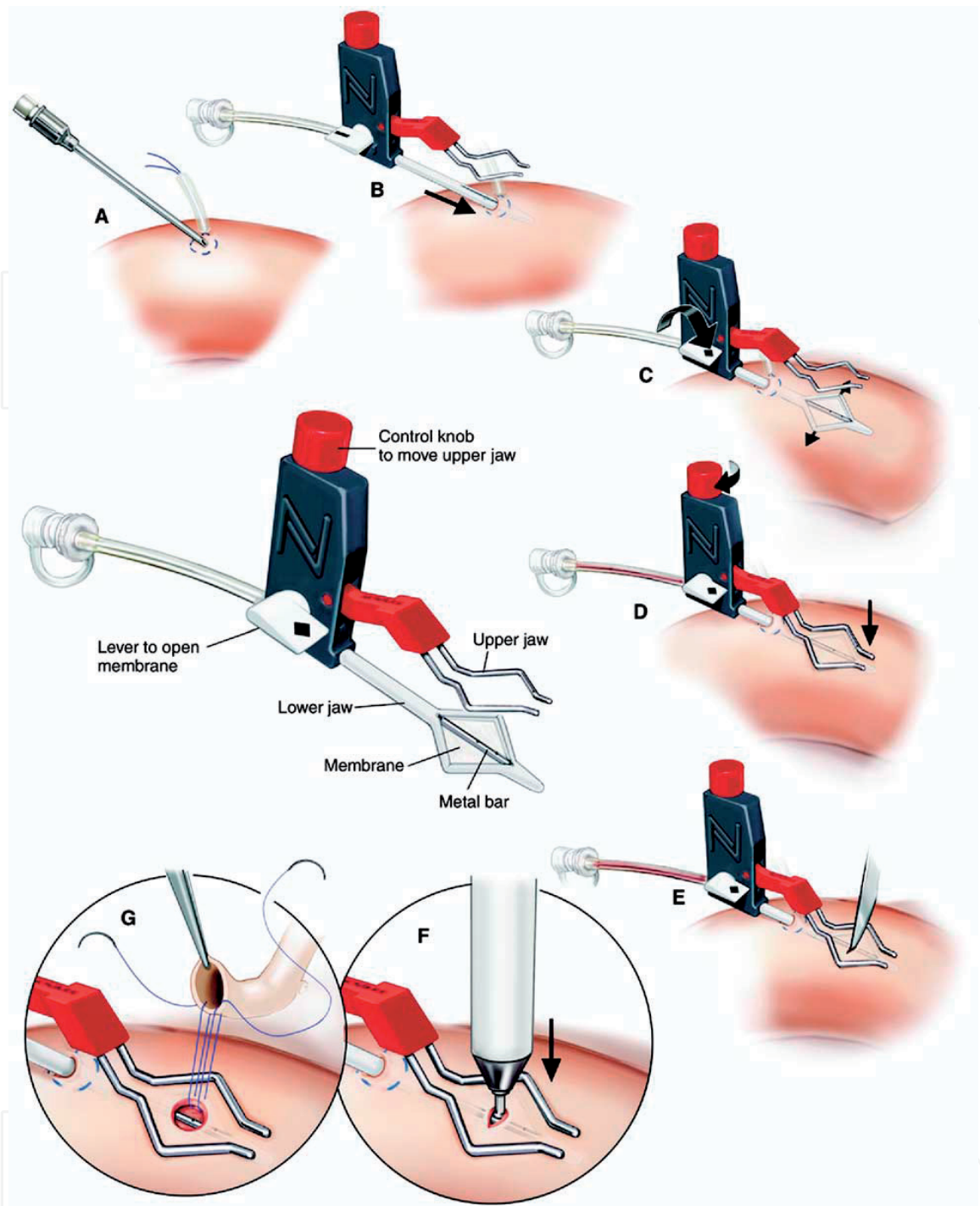
### *2.2.4 Remove*

Close membrane after anastomosis and then release and remove Enclose. Knot the purse suture and use 2–0 polypropylene suture with felt pad to mattress suture for reinforcement.

## **2.3 Key points of Enclose using technique**

### *2.3.1 Position selection*

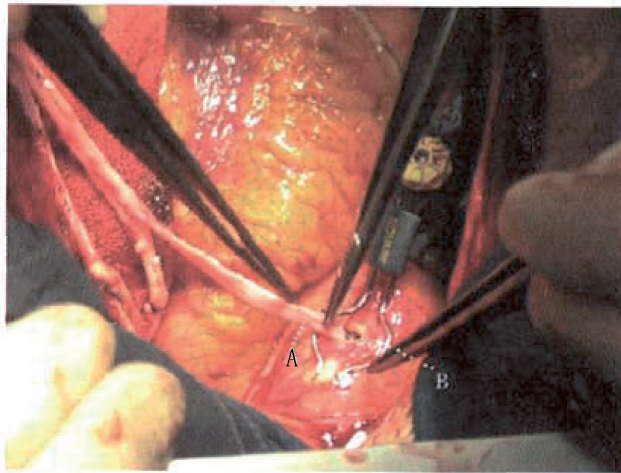
A considerable proportion of patients with coronary disease has ascending atherosclerosis. Many soft atherosclerotic plaques similar to “toothpastes” exist in the middle layer of ascending aorta, whereas obvious calcification can be identified by finger touch on the surface of aorta. Therefore, the plaques are prone to break and fall off after the application of side wall clamp and lead to organ embolism along with blood flow. In addition, except for the requirement of healthy aortic tissue at the puncture insertion point and anastomotic site, healthy tissue should also be selected between the two points as much as possible to avoid excessive bleeding due to atherosclerosis or calcification of the arterial wall between the two points, or plaque falling off due to extrusion.



**Figure 1.** Enclose device demonstration. (A) Needle puncture; (B) Enclose insertion; (C) Membrane unscrewed; (D) Upper jaw downward; (E) Circular knife cut; (F) Perforation; (G) Anastomosis.

### 2.3.2 Avoid damage to Enclose membrane

Most of the damage occurred in the process of aortic wall incision with circular knife and suturing. The aortic wall should be cut perpendicular to the connecting rod as much as possible to avoid cutting the diaphragm. When suturing, the needle should be carefully pressed against the inner wall of the aorta from internal to external, to avoid massive hemorrhage caused by deep penetration of Enclose diaphragm or vertical needle insertion. Slight injury of diaphragm may lead to increased bleeding risk in the operation area. In most cases, operations can be continued under the control of blood pressure and sufficient suction. If the diaphragm's damage is too serious, most of the surgeons will have to use other methods to avoid massive blood loss.



**Figure 2.**  
*Application of Enclose: (A) the great saphenous vein; (B) aortic anastomosis.*

### 2.3.3 Puncture point reinforcement

Although we use 2–0 polypropylene suture to reinforce the puncture points during the operation for the Enclose cases, there are still a few patients in intensive care unit (ICU) with pericardial drainage fluid increase sharply and in bright red color. This is found to be blood leakage at the puncture point during emergency thoracotomy and hemostasis. The secondary suture for reinforcement with 2–0 polypropylene and felt pad can effectively stop bleeding. The reason for bleeding may be attributable to the inaccurate suture during the process. When the blood pressure is stable without obvious bleeding under anesthesia, the huge postoperative blood pressure fluctuation may increase the arterial pressure and lead to suture avulsion.

### 2.3.4 Mechanical failure

We have met several cases where the Enclose membrane could not be opened and the equipment was replaced. It is considered to be related to the technology and process in the production process. Therefore, it is necessary to test whether the membrane can open and close smoothly before each aortic implantation.

### 2.3.5 Aortic wall injury

Implantation and use of Enclose may also lead to injury, rupture and even aneurysm formation of the aortic wall. It may be due to the insertion of Enclose's lower jaw into the wall of ascending aorta, or due to the damage of aortic intima caused by overcompression, which is easy to form aneurysm when the blood pressure rises. Therefore, it is very important to control blood pressure during the operation and, at the same time, on the premise of no blood environment in the operation area, to loosen the knob as much as possible to reduce the excessive pressure on the aortic wall.

### 2.3.6 Re-implantation

It is often the case that the intimal dissection of the internal mammary artery (IMA) has to be replaced by the total vein coronary artery bypass grafting. Thus, Enclose was re-implanted after the injury of the IMA or when the flow of the IMA graft is poor. The distance between the suture and the punch hole should not be

too wide ( $\leq 5$  cm); otherwise, the hemostasis effect of membrane will be affected. The suction tube of the stabilizer should be connected with the suction device or 50 ml syringe to eliminate possible blood accumulation and keep the operation field clean.

## 2.4 Advantages and limitations of Enclose technology

### 2.4.1 Advantages

- The Enclose greatly reduces the risk of plaque falling off due to the clamping of ascending aorta, and it has fewer requirements for anastomotic area, which merely concerns a relatively soft and healthy area with a diameter about 1 cm.
- Compared with the disposable aortic proximal anastomotic device such as Heartstring, Enclose can support the operation of two or more anastomoses, especially for the aged patients undergoing total vein CABG with severe aortic atherosclerosis.
- Compared with the first generation of products, Enclose II improved the way of opening the internal aortic diaphragm umbrella: from the hand push knob to the rotary rod operation. This facilitates the operation in the narrow pericardial cavity. Meanwhile, the design of hexagon suture ring is more reasonable than the rhombic suture ring from the previous generation.

### 2.4.2 Limitations

- Enclose requires at least two healthy areas of the aorta: one is the insertion point, and the other is the anastomosis point. Its application is limited to patients with large-area diffuse calcification aorta.
- A completely bloodless operation field could not be guaranteed. When the suture is too tight, there will be different degrees of bleeding.
- Due to the technology in the production process, Enclose's membrane might fail to open and need to be replaced. However, the incidence of mechanical failure is very low.
- Enclose II is relatively expensive, which to some extent increases the medical expenses of patients.

## 2.5 Clinical significance of Enclose technology

Cerebrovascular complications are one of the most common complications after CABG. The main reasons could be mainly attributable to the atherosclerotic plaque or new thrombus falling off and embolism of ascending aorta or carotid artery during and after operation [14]. Other possible causes might be the excessive anticoagulation, or the sudden rise of blood pressure, causing the rupture and hemorrhage of cerebral vessels [15]. Atherosclerosis is a group of systemic diseases, and vascular endothelial dysfunction has been widely considered as the most important initiating link in its process and exists in the whole process of atherosclerosis. Atherosclerosis is a chronic, progressive and multiple endovascular disease, involving many large and medium-sized arteries. For patients with severe coronary atherosclerosis, especially those over 70 years old, the incidence of aortic atherosclerosis or calcification

is higher. Therefore, the use of no-clamp aortic proximal anastomotic device can reduce the cerebrovascular complications caused by aortic atherosclerosis.

### 3. Heartstring technique

The Heartstring proximal anastomosis system is suitable for the proximal anastomosis of the graft and the aorta without the use of aortic clamp in CABG [16–17]. The first generation of Heartstring proximal anastomosis system was launched by Guidant Company in 2002 and the most commonly used Heartstring III was launched by MAQUET after continuous technical improvement. The American Thoracic Surgery study [18] of 1380 patients with aortic calcification found that the predicted risk of stroke in patients using Heartstring was reduced by 44%, especially in patients with aortic calcification above grade II (**Figure 3**).

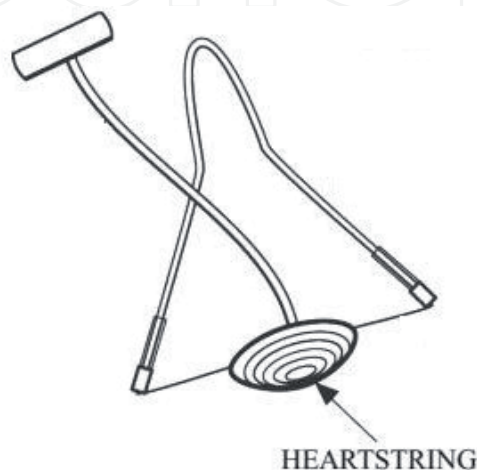#### 3.1 Device composition of Heartstring proximal anastomosis system

Heartstring proximal anastomotic system consists of proximal anastomotic device, conveying device, loading device and aortic perforator device. The Heartstring anastomotic device enters the aorta through the aortic incision established by the aortic drilling device and provides an anastomotic area for proximal anastomosis. The conveyor is a syringe-like tube with a piston, which is used to place the Heartstring anastomosis device into the aorta. The loading device is used to roll up the Heartstring anastomosis device and load the Heartstring anastomosis device into the conveyor. The aortic perforator device is a disposable device, which consists of a handle, a drilling device, an aortic block, a cover, a needle, a safety lock and an action button, which is used to establish an aortic incision for anastomosis.

#### 3.2 Indications and contraindications of Heartstring technology

##### 3.2.1 Indications

For patients with high risks of atherosclerosis, the possibility of ascending atherosclerosis is increased, and the operation of aorta needs to be reduced or avoided. A strict aortic non-touch technique can most effectively reduce the occurrence of plaque embolism. This requires the use of an auxiliary device for proximal aortic anastomosis. The Heartstring proximal anastomotic system is adopted in CABG to



**Figure 3.**  
*The Heartstring device.*



maintain hemostasis during operation and to complete the proximal anastomotic operation without the use of arterial side wall clamp.

### 3.2.2 Contraindications

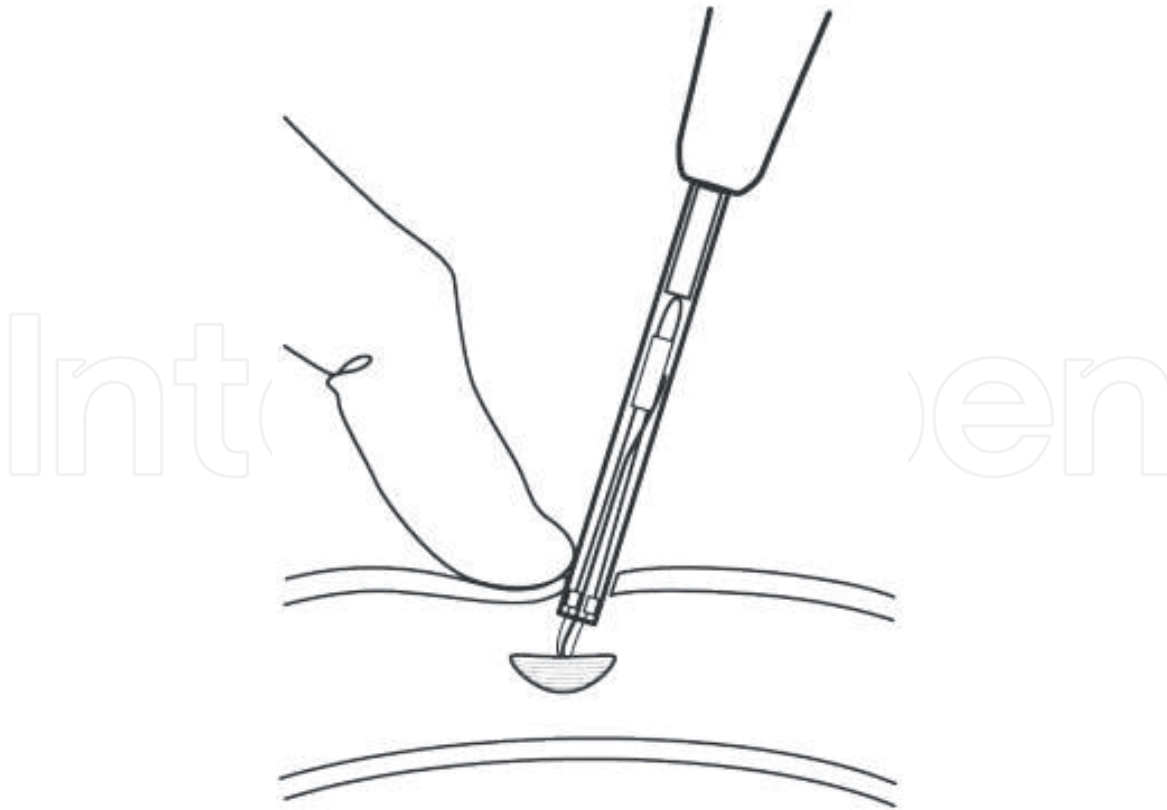
- If conventional anastomosis is impossible due to a significant disease in an aortic region, do not use the Heartstring proximal anastomosis system in that region. It can also be judged by echocardiography.
- Do not use the Heartstring proximal anastomosis system in patients with aortic diameter less than 2.5 cm.

### 3.3 Method of application

- Heparin was used according to CABG standard procedure.
- Remove the device from the sterile packaging and make sure that the safety lock is locked.
- Load the Heartstring proximal anastomosis device into the conveyor tube. Avoid triggering the conveyor when loading.
- Take the conveyor out of the loader then unlock the Heartstring.
- Establish soft and safe aortic anastomosis area with aortic perforator device.
- Deliver the Heartstring device to the anastomose point. The presence of blood in the conveyor indicates the correct insertion. Use carefully when inserting the conveyor to reduce the risk of aortic posterior wall penetration (**Figure 4**).
- Heartstring anastomose after the proximal anastomose device is in position. During suturing, it is necessary to be careful and avoid movement of the proximal anastomotic device of Heartstring or winding of the suture around the rod of the anastomotic device. If the above-mentioned happens, please return the needle and ensure the hemostasis. If hemostasis is insufficient, use a partial occlusal clamp, remove the Heartstring proximal anastomotic device and use the aortic clamp to complete the anastomosis.
- Remove the Heartstring proximal anastomotic device after the anastomosis is completed. Do not continue to pull the anastomotic rod if resistance is constantly remains when pulling out the Heartstring, or the non-invasive anastomotic device is not pulled out successfully.
- The aortic perforator is a disposable device. If multiple proximal anastomoses are needed on the ascending aorta, select a location at least 1.5 cm from the previous anastomotic position.

### 3.4 Consideration of Heartstring technology

- Surgeons should be properly trained before using the Heartstring proximal anastomosis system.
- For disposable use. Do not re-sterilize.



**Figure 4.**

*Place the Heartstring proximal anastomotic device into the aortic incision and extract the conveyor.*

- Do not use the Heartstring proximal anastomotic system in the aorta that cannot be partially clamped, to prevent patients from being at risk from bleeding.
- To ensure effective hemostasis, make sure that the anastomoses are at least 1.5 cm apart before performing multiple anastomoses.
- Check the unit to guarantee that it is not damaged during transportation.
- Aortic perforator should only be used on the unmodified aortic tissue. Use on altered tissue, such as the presence of a cardiologic orifice and/or an aortotomy incision, may result in an unblocked aortic incision and the embolus may enter in the aorta.

### **3.5 Advantages and limitations of Heartstring technology**

#### *3.5.1 Advantages*

Heartstring is also a proximal anastomotic device that can effectively reduce the probability of aortic atherosclerotic plaque shedding or dissection. Its advantages are as follows:

- Low requirements for anastomotic area. A relatively healthy area with a diameter of around 1 cm available for suture will be sufficient, especially for those with multiple plaques in the ascending aorta.
- Heartstring is easy to operate and does not need to be punched or sutured in other positions of the ascending aorta.

- The sealing membrane of Heartstring is composed of a line-type concave disc with good adhesion. At the end of anastomosis, “hat” shaped membrane can be pulled out directly through the anastomosis position, avoiding the risk of aortic wall damage when other devices are pulled out through the anastomosis position.

### 3.5.2 Limitations

When using Heartstring for proximal anastomosis, the uneven calcified aortic inner wall may lead to a loose fit between the plug-like membrane and the inner wall of the ascending aorta, causing continuous bleeding of the anastomosis and affecting the operation.

## 3.6 Heartstring technology and stroke

Stroke is one of the most serious complications of coronary revascularization, with high morbidity, mortality and cost. High-risk factors include peripheral vascular disease, left main artery disease, diabetes mellitus, atherosclerosis and calcification of arterial wall. After OPCABG, the risk of both stroke and mortality has been reduced, especially for high-risk groups and elderly patients [3]. However, the causes of stroke are various, not a single technology (including OPCABG) can completely avoid the occurrence of postoperative stroke. The off-pump total artery CABG provides a relatively “non-touch” way for revascularization and is effective to reduce the complications of nervous system. Although non-touch technology may be the best clinical option, it cannot be applied to every patient, nor can it be carried out routinely in most medical centers. When high-risk patients do need proximal anastomosis, Heartstring can assist to complete the proximal anastomosis with minimum aortic contact.

In the past few years, more evidences have shown that Heartstring technology could significantly minimize atherosclerotic embolism and neurological complications compared with side wall clamp, but those researches did not classify aortic lesions [19–20]. Another randomized controlled trial from Emory University showed that the use of Heartstring technology in patients with low risk of atherosclerotic embolism can significantly reduce cerebral embolic events. For patients with aortosclerosis of grade I or II, Heartstring technique can reduce solid emboli by 35% [21]. Emmert et al. took the total arterial CABG as the gold standard for clinical trial [22]. It is demonstrated that the incidence of stroke and major adverse cardiovascular and cerebrovascular event (MACCE) was 0.7 and 6.7% in the OPCABG with Heartstring group, 2.3 and 10.8% in the OPCABG with side wall clamp group, and 0.8 and 7.9% in the total arterial CABG group [22]. Hilker et al. performed 542 proximal anastomoses in 412 consecutive patients with Heartstring technique [23]. The incidence of postoperative stroke in this series was 0.48%, whereas the prediction of preoperative stroke was 1.3%. It indicated that the Heartstring technology could reduce the risk of stroke prediction by 44% [23]. This technology might not be as beneficial for patients with aortosclerosis I, as for patients with aortosclerosis II or above, among which there is no stroke incidence that occurred even in patients with aortosclerosis. More importantly, there was no significant difference in the incidence of stroke between the clampless off-pump CABG and the no-touch technique [24], which indicated that the clamp per se was an independent risk factor for the stroke. The combination of OPCABG and Heartstring technology not only achieves the revascularization but also has a relatively low incidence of neurological complications compared with percutaneous coronary intervention (PCI) [25–26]. In comparison with the traditional CABG with cardiopulmonary bypass, OPCABG is indeed a step forward.

## **4. Urethra catheter-water sac technique**

When the great saphenous vein anastomosis with the ascending aorta, the ascending aorta should be clamped with side wall clamp, which may cause the atherosclerotic plaque of the ascending aorta to fall off and, thus, increase the risk of cerebral infarction. Further, the falling-off plaque may also block the great saphenous vein graft and reduce its patency rate. We applied the self-made water sac blocking method for the patients with severe ascending aortic calcification upon OPCABG and achieved satisfying results.

### **4.1 The birth of water sac technique**

Patients with severe calcification in the ascending aorta are more likely to have stroke after anastomosis of ascending aorta and great saphenous vein in OPCABG. The most common reason is the loose or detached atherosclerotic plaque on the inner wall of ascending aorta, or detached thrombus due to clamp damage. Multivariable analysis revealed that the use of aortic wall clamp was the most important independent risk factor for postoperative stroke, resulting in a sixfold increase of postoperative stroke rate. It is suggested that the indicators of serious calcification of ascending aorta include carotid stenosis, hypertension, peripheral vascular disease or abdominal aortic aneurysm, male gender, renal insufficiency and left main artery disease in patients over 65 years old.

There are two main methods hitherto to solve the problem of proximal anastomosis in patients with calcification of ascending aorta, including using proximal anastomotic device and using non-touch ascending aorta of CABG. The former mainly includes the application of Enclose, Heartstring and other devices, while the latter mainly refers to the methods of CABG without ascending aorta operation, such as bilateral internal mammary artery and other forms of total arterial CABG.

The indications of non-touch technique of ascending aorta are limited to some extent, and the requirements to operation are relatively high. Moreover, collection of bilateral internal mammary artery will reduce the blood supply of sternum, affect the healing of sternum, and may cause complications such as loosening of sternum, delayed healing and infection of incision. Radial artery is also commonly used in total arterial CABG; however, when comparing with internal mammary artery, it is more prone to produce spasm and affect surgical effect.

There are some limitations in the use of proximal anastomotic devices. For example, when using Heartstring for proximal anastomosis, the internal umbrella cap may not fit tightly with the uneven calcified aortic inner wall, causing continuous bleeding at the anastomosis and affecting the operation. When using Enclose for proximal anastomosis, at least two holes are needed to be drilled in the ascending aorta, increasing the chance of atherosclerotic plaque falling off. Further, the needle tip may puncture the diaphragm with hemostatic effect and lead to uncontrollable bleeding. In addition, the cost of proximal anastomotic device is high and will increase the medical burden for patients in developing countries and remote areas.

Given the above situation, we have figured out the method of water sac blocking proximal anastomosis method in clinical practice. Its short-term and medium-term effects were similar to those of patients without ascending aortic calcification who used side wall clamp, and no patients had complications such as stroke or proximal anastomotic stenosis. It is well demonstrated that OPCABG combined with water sac blocking anastomotic method can further reduce the incidence of postoperative stroke.

## 4.2 Operation process

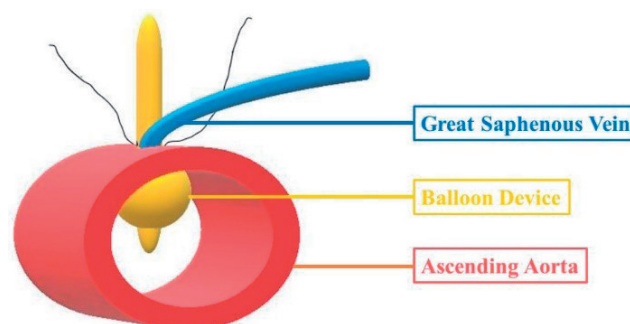
“Water sac blocking” refers to the method of proximal anastomosis without using side wall clamp when anastomosing great saphenous vein or radial artery with ascending aorta (**Figure 5**).

The specific processes are as follows:

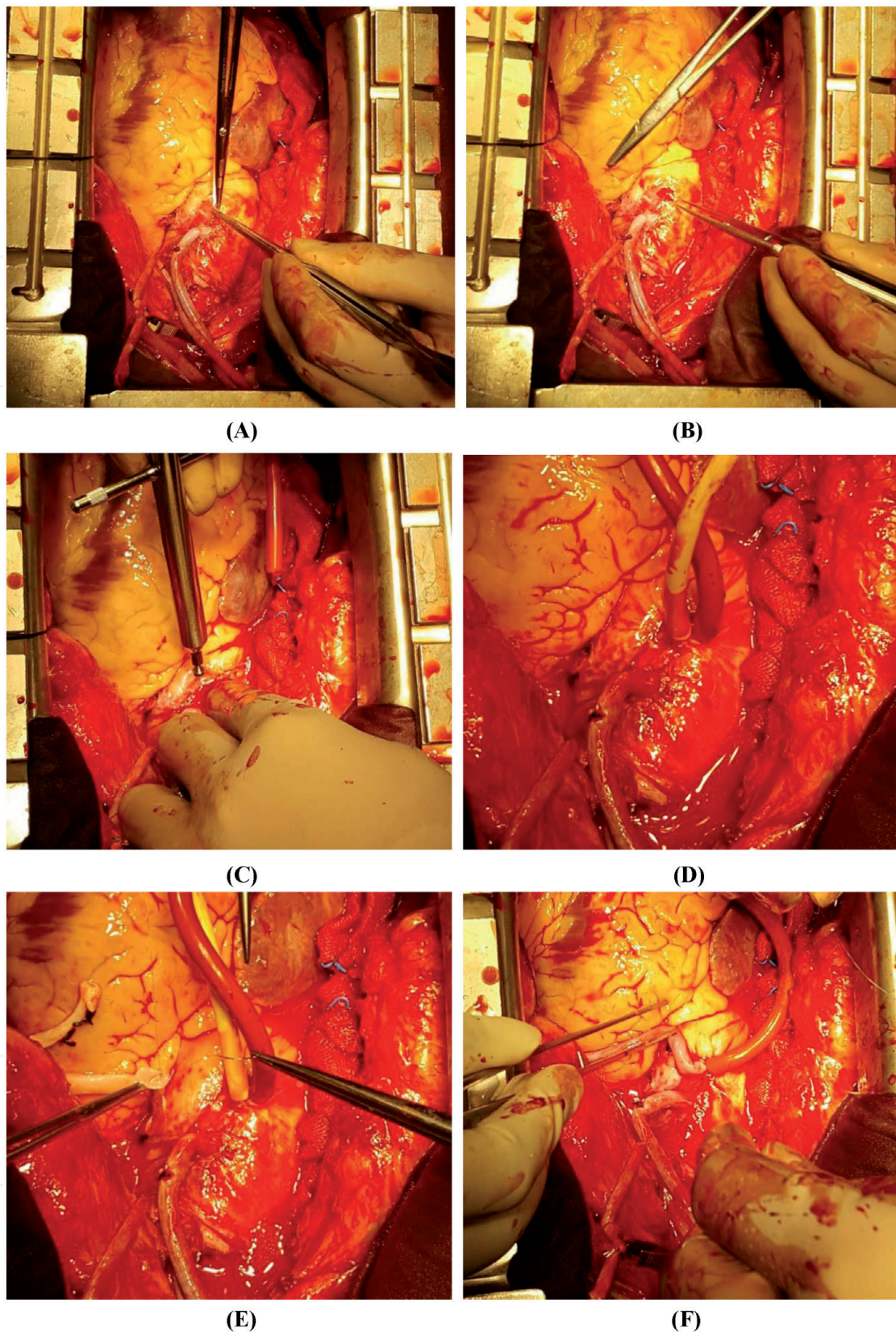
- Left internal thoracic artery and great saphenous vein are harvested routinely. In OPCABG, the internal thoracic artery is usually anastomosed to the left anterior descending branch, and the rest are treated by sequential CABG of great saphenous vein.
- When the saphenous vein is anastomosed with the ascending aorta, the adventitia of the artery is cut off at the perforating position.
- After purse string is anastomosed, use a sharp knife to prick a small incision, and press to stop bleeding.
- Use an aortic perforator to make a hole.
- Quickly insert a 12–14F urethra catheter into the aorta, inject 8–10 ml sterile normal saline through the water injection hole, make the water sac inflate, fix the distal end, and make the water sac tightly close to the anastomosis position for hemostasis.
- The saphenous vein was anastomosed with ascending aorta by 6–0 polypropylene suture while removing the pre-sutured purse string. The direction of the needle entering the aortic wall was from the internal to the external, without penetrating the whole layer of the arterial wall. The total number of needles was 8–10.
- Use a syringe to suck out the normal saline in the water sac, quickly remove the urethra catheter, pull down the great saphenous vein, and tighten the suture and knot.
- Lastly, another 6–0 polypropylene suture was used to full-layer suture the aortic wall along the previous anastomosis position. (**Figure 6**).

## 4.3 Considerations in the use of water sac blocking method

- Since the needle tip of the anastomosis is easy to puncture the water sac, polypropylene suture for the first time in non-full-layer type, and then another



**Figure 5.**  
*Composition of the water sac device.*



**Figure 6.**  
*Procedures: (A) cutting off the adventitia; (B) purse string suture; (C) perforation and finger hemostasis; (D) urinary catheter insert and sterile normal saline injection; (E) great saphenous vein anastomosis (non-full layer); (F) balloon suction and removing for secondary anastomosis (full layer).*

polypropylene suture can be performed for full layer suture after knotting to ensure the accuracy of the anastomosis.

- The change of arterial pressure should be observed when injecting water into water sacs, and the circulation index should not be affected as much as

possible. The amount of water injected into the water sac is usually less than 10 ml; otherwise, it may cause bursting or affect the left ventricular blood flow.

- When the distal end of the urethra catheter is fixed after the water injection, the rubber tube should keep a certain tension to make the water sac stay closed to the inner wall of the aorta.
- During the drill, anesthesiologists should control blood pressure and slow down heart rate to minimize bleeding.
- When inserting the catheter, it is necessary to press the anastomose with the help of fingers and inject water quickly to avoid excessive bleeding.
- During suturing, the position of the urethra catheter should be adjusted and the same tension should be maintained to ensure that the suturing field is exposed. Avoid the bleeding caused by the needle penetrating the water sac or pulling out the urethra catheter-water sac.
- Surgeons should be properly trained before using water sac blocking method.

#### **4.4 Advantages and limitations of urethra catheter-water sac technology**

##### *4.4.1 Advantages*

- As an innovative suture method, “water sac blocking” method has the advantages of both OPCABG and proximal anastomosis device. It requires no additional medical costs, and the operation process is simple, effective and accurate. It can minimize the incidence of stroke or embolism caused by the detachment of atherosclerotic plaque via clamping or intubating on the aorta.
- This method is very safe. Due to the softness of the water sac, it is rare that the aortic wall will be damaged, even when the water sac is broken.
- For patients who fail to use Heartstring and Enclose, the water sac method could be the remedy.

##### *4.4.2 Limitations*

- During the first suture, it is possible that the urethra catheter could not be pulled out when the needle caught the outer membrane of the water sac. In this case, it may be necessary to cut the suture and pull out the urethra catheter, and then repeat the operation.
- It is relatively time-consuming due to the requirement for secondary suture. Moreover, the operation around the aortic incision is more frequent, which increases the risk of bleeding.

#### **4.5 Clinical significance of urethra catheter-water sac technology**

For patients with severe aortic atherosclerosis, avoiding the use of side wall clamp is one of the important methods to reduce postoperative neurological complications [27]. The water sac blocking method is simple, effective, accurate and

cost-efficient (the cost of the catheter is negligible), with minimized risk of stroke or cerebral infarction caused by the detachment of atherosclerotic plaque due to the clamping of the aortic wall. When proximal anastomosis is performed in patients with severe ascending aortic calcification, the water sac method is a feasible option and has a wide range of clinical application and dissemination value.

## **5. No clamp anastomosis technique**

When using great saphenous vein to anastomose with ascending aorta during OPCABG, it is necessary to clamp part of ascending aorta wall and may cause ascending aorta atherosclerotic plaques to fall off, leading to cerebral embolism. Meanwhile, it may also induce great saphenous vein graft obstruction and influence its patency rate. We applied “no clamp” suture method in OPCABG for patients with severe aortic calcification and achieved satisfying results.

### **5.1 The birth of no clamp technique**

Although OPCABG avoids cardiopulmonary bypass and greatly reduces brain damage caused by cerebral air embolism and insufficient perfusion, the incidence of neurological complications (including stroke, transient ischemic attack, coma, postoperative delirium or epileptic attack, etc.) remains one of the most common postoperative complications [28]. Cerebral infarction is mostly related to atheromatous plaque or calcification breaking and detachment in the aorta caused by operating on it, and cerebral hemorrhage may also be related to post infarction hemorrhage [29–30]. Patients often show delayed awake or coma for longer time as this kind of disease often occurs in the operation or the early postoperative period. However, patients could hardly move and remain in the state of respiratory assistance; as a result, computed tomography (CT) or magnetic resonance imaging (MRI) diagnose and further treatment are often delayed with more serious consequences. Among all the risk factors, calcification plaque shedding caused by clamping the ascending aorta is the most important risk factor [31]. Thus, using proximal anastomotic device to assist or complete proximal aortic anastomosis without side wall clamp can effectively avoid the complications caused by clamping ascending aorta during traditional proximal aortic root anastomoses, such as the damage of the aortic wall and the detachment of atheromatous plaque. Therefore, avoiding the ascending aorta clamping is the key to reduce the incidence of aortic dissection and nervous system complications in OPCABG, and thus improving the postoperative survival rate. Indicators of severe ascending aortic calcification include carotid stenosis, hypertension, peripheral vascular disease or abdominal aortic aneurysm, male gender, renal insufficiency and being over 65 years old. As an innovative suture method, the no clamp suture method can minimize the incidence rate of systemic infarction caused by the detachment of atherosclerotic plaques. The operation process is simple, effective, accurate and cost-efficient. Therefore, in the OPCABG for patients with severe ascending aortic calcification, the method without clamp has its practical and generalization value.

### **5.2 Operation process**

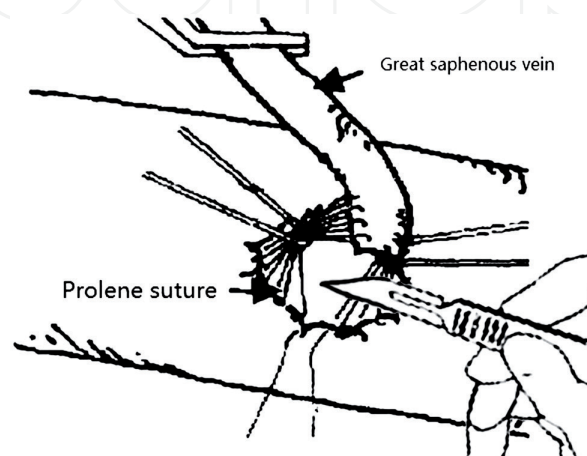
The method without clamp refers to that when the great saphenous vein is anastomosed with ascending aorta, and the aortic wall is not clamped with side wall clamp. The specific operation process is as follows:



- Use 6–0 polypropylene suture to perform end to side anastomosis in anticlockwise direction before perforating ascending aorta. The direction of the needle entering the aortic wall is from the internal to the external through the whole layer of the arterial wall.
- The polypropylene suture is divided into two clusters, and two thick sutures for traction are used to pull it in the opposite direction respectively to fully expose the position of the anastomosis.
- Use a sharp knife to pierce the artery wall in the middle of the anastomotic position, press with fingers for hemostasis, and then use an aortic perforator to perforate (**Figure 7**).
- Remove the traction suture, pull down the great saphenous vein, tighten the polypropylene suture and knot.
- Finally, another 6–0 polypropylene suture was used to suture the aortic wall along the previous anastomosis position.

### 5.3 Considerations of no clamp technique

- Before aortic wall suture with polypropylene, ascending aorta palpation should be carried out in order to avoid atherosclerotic plaques and local thickening part and prevent plaques detachment.
- The two traction sutures should be pressed as close to the aortic surface as possible for maximum expose of anastomotic position.
- The perforator shall be positioned accurately before drilling to prevent damage to the polypropylene suture.
- During drilling, anesthesiologists should reduce blood pressure and slow down heart rate to minimize bleeding.
- As the polypropylene suture requires a long distance in the aortic wall, it may be astringent when tightening, and as a result, it should be tightened one by one with a nerve hook.



**Figure 7.**  
*Puncture the artery wall and press it with fingers to stop bleeding.*

## 5.4 Advantages and limitations of no clamp technology

### 5.4.1 Advantages

- As an original suture method, “no clamp” method has the advantages of both OPCABG and proximal anastomosis device. It requires no additional medical costs, not even tiny cost of urethra catheter. The operation process is simple, effective and accurate, with minimum risk of neurological complications from clamping or intubating on the aorta.
- Compared with the water sac method, no clamp method avoids the possible risks associated with water sac. Direct suture is fast and effective. This technique is the alternative if the water sac technique is unavailable because of the severe uneven aortic inner wall.
- For patients who fail to use Heartstring and Enclose, no clamp method could be also considered as remedy.

### 5.4.2 Limitations

- Both the piercing and perforating operation could damage or even cut off the suture, causing severe hemorrhage or suture failure. In this case, repeated suture is required.
- This operation is also relatively time-consuming due to the secondary suture. Moreover, the piercing and perforating operation is under no cover of any inner aortic device, such as diaphragm umbrella of Enclose, spiral coil shape umbrella of Heartstring and water sac, which increases the possibility of bleeding and operative time.
- Because the great saphenous vein is closed to the anastomotic position after the first suture and blood vortex exists during the secondary suture, a high accuracy of the suture is required to avoid thrombosis.
- Surgeons should be properly trained before using no clamp method.

## 5.5 Clinical significance of no clamp technology

The most common cause of stroke after OPCABG is the detachment of embolus, which is closely related to the progressive arteriosclerosis of ascending aorta. “No clamp” method is simple and effective, with minimum risk of the infarction induced by the detachment of atherosclerotic plaques through clamping operation.

## 6. Conclusions

When OPCABG is performed in patients with severe ascending aortic calcification, the above methods of proximal anastomosis are of practical and dissemination value. Based on decades of clinical experience, when encountering atherosclerotic plaque of ascending aorta, proximal anastomosis devices can be used to anastomose proximal aorta as priority, in order to maximally avoid the detachment of aortic atherosclerotic plaque or the damage of aortic dissection. When the proximal

anastomosis device or the suture fails, the water sac or no clamp method could also be applied for remedy. For well-trained surgeons, they will be able to use water sac or no clamp method for proximal anastomosis directly, saving huge costs while achieving the same outcomes. The two original techniques are of great significance for patients in developing countries and remote areas. All these surgical applications aim to avoid complications of nervous system and embolism caused by plaque detachment due to partial blocking of ascending aorta with side wall clamp for proximal anastomosis.

### **Conflict of interest**

The authors declare no conflict of interest.

### **Author details**

Chuan Wang, Yang Yu, Chengxiong Gu and Jingxing Li\*  
Department of Cardiac Surgery, Beijing Anzhen Hospital, Capital Medical University, Beijing, China

\*Address all correspondence to: sci4vv@hotmail.com

### **IntechOpen**

© 2020 The Author(s). Licensee IntechOpen. This chapter is distributed under the terms of the Creative Commons Attribution License (<http://creativecommons.org/licenses/by/3.0>), which permits unrestricted use, distribution, and reproduction in any medium, provided the original work is properly cited. 

## References

- [1] Davila-roman VG, Barzilai B, Wareing TH. Atherosclerosis of the ascending aorta. Prevalence and role as an independent predictor of cerebrovascular events in cardiac patients. *Stroke*. 1994;**109**(11):1637-1643
- [2] Bakaeen FG, Shroyer AL, Gammie JS, et al. Trends in use of off-pump coronary artery bypass grafting: Results from the Society of Thoracic Surgeons adult cardiac surgery database. *The Journal of Thoracic and Cardiovascular Surgery*. 2014;**148**(3):856-853
- [3] Goto T, Baba T, Matsuyama K, et al. Aortic atherosclerosis and postoperative neurological dysfunction in elderly coronary surgical patients. *The Annals of Thoracic Surgery*. 2003;**7**(5):556-563
- [4] Wang B, Jia M, Jia S, et al. Influencing factors for early acute cerebrovascular accidents in patients with stroke history following off-pump coronary artery bypass grafting. *Heart, Lung & Circulation*. 2014;**23**(6):560-565
- [5] Sylivris S, Levi C, Matalanis G, et al. Pattern and significance of cerebral microemboli during coronary artery bypass grafting. *The Annals of Thoracic Surgery*. 2013;**9**(6):1062-1070
- [6] Chavanon O, Carrier M, Cartier R, et al. Increased incidence of acute ascending aortic dissection with off-pump aortocoronary bypass surgery? *The Annals of Thoracic Surgery*. 2001;**71**:117-121
- [7] Patel NC, Hemli JM. Anastomotic devices in coronary artery surgery: It is about the anastomosis? *Multimedia Manual of Cardiothoracic Surgery*. 2013;**2013**:mmt019
- [8] Akpınar B, Guden M, Sagbas E, et al. Clinical experience with the novare enclose ii manual proximal anastomotic device during off-pump coronary artery surgery. *European Journal of Cardio-Thoracic Surgery*. 2005;**27**(6):1070-1073
- [9] Wang S, Zhao T, Liu D, et al. Enclose-without blocking the proximal anastomosis system in the application of OPCAB in elder patients. *Chinese Journal of Cardiology*. 2011;**9**(6):426-428
- [10] Lev-Ran O, Braunstein R, Sharony R, et al. No-touch aorta off-pump coronary surgery: The effect on stroke. *The Journal of Thoracic and Cardiovascular Surgery*. 2011;**129**(2):307-313
- [11] Fukuda I, Daitoku K, Minakawa M, et al. Shaggy and calcified aorta: Surgical implications. *General Thoracic and Cardiovascular Surgery*. 2013;**61**(6):301-313
- [12] Wolf LG, Abu-Omar Y, Choudhary BP, et al. Gaseous and solid cerebral microembolization during proximal aortic anastomoses in off-pump coronary surgery: The effect of an aortic side-biting clamp and two clampless devices. *The Journal of Thoracic and Cardiovascular Surgery*. 2007;**133**(2):485-493
- [13] Aranki SF, Shekar PS, Ehsan A, et al. Evaluation of the enclose proximal anastomosis device in coronary artery bypass grafting. *The Annals of Thoracic Surgery*. 2005;**80**(3):1091-1095
- [14] Abu-Omar Y, Balacumaraswami L, Pigott D, et al. Solid and gaseous microembolization during off-pump, on-pump, and open cardiac surgery procedures. *The Journal of Thoracic and Cardiovascular Surgery*. 1994;**109**(11):1637-1643
- [15] Barbut D, Hinton RB, Szatrowski TP. Cerebral emboli detected during bypass surgery are associated with clamp removal. *Stroke*. 1994;**28**(3):266-278

- [16] Medalion B, Meirson D, Hauptman E, et al. Initial experience with the heartstring proximal anastomotic system. *The Journal of Thoracic and Cardiovascular Surgery*. 2012;**164**(3):402-409
- [17] Vicol C, Oberhoffer M, Nollert G, et al. First clinical experience with the heartstring a device for proximal anastomoses in coronary surgery. *The Annals of Thoracic Surgery*. 2012;**109**(5):724-728
- [18] Thourani VH, Razavi SA, Nguyen TC, et al. Incidence of postoperative stroke using the heartstring device in 1,380 coronary artery bypass graft patients with mild to severe atherosclerosis of the ascending aorta. *The Annals of Thoracic Surgery*. 2014;**97**(6):2066-2072
- [19] Kim DJ, Lee SH, Joo HC, et al. Effects of a proximal seal system on neurologic outcomes of off-pump coronary artery bypass grafting. *International Heart Journal*. 2019;**60**(3):593-600
- [20] Lamm P, Eifert S, Kilian E, et al. Preventing blood loss during application of the HEARTSTRING proximal seal system. *The Annals of Thoracic Surgery*. 2009;**88**(1):310-312
- [21] El Zayat H, Puskas JD, Hwang S, et al. Avoiding the clamp during off-pump coronary artery bypass reduces cerebral embolic events: Results of a prospective randomized trial. *Interactive Cardiovascular and Thoracic Surgery*. 2012;**14**(1):12-16
- [22] Emmert MY, Seifert B, Wilhelm M, et al. Aortic no-touch technique makes the difference in off-pump coronary artery bypass grafting. *The Journal of Thoracic and Cardiovascular Surgery*. 2011;**142**(6):1499-1506
- [23] Hilker M, Arlt M, Keyser A, et al. Minimizing the risk of perioperative stroke by clampless off-pump bypass surgery: A retrospective observational analysis. *Journal of Cardiothoracic Surgery*. 2010;**5**:14
- [24] Formica F, Tata G, Singh G, et al. Incidence of perioperative stroke in clampless aortic anastomosis during off-pump coronary artery bypass grafting. *Heart and Vessels*. 2018;**33**(6):595-604
- [25] Emmert MY, Grunenfelder J, Scherman J, et al. HEARTSTRING enabled no-touch proximal anastomosis for off-pump coronary artery bypass grafting: Current evidence and technique. *Interactive Cardiovascular and Thoracic Surgery*. 2013;**17**(3):538-541
- [26] Liu R, Gu C, Chen C, et al. Application of heartstring in non-blocking proximal anastomosis system in OPCAB. *Chinese Journal of Thoracic and Cardiovascular Surgery*. 2006;**22**(5):347
- [27] Yu Y, Gu CX, Wei H, et al. Evaluation of the early and medium-term curative effect of water sac blocking used in the proximal anastomosis during off-pump coronary artery bypass. *Zhonghua Wai Ke Za Zhi*. 2010;**48**(24):1864-1867
- [28] Manabe S, Fukui T, Miyajima K, et al. Impact of proximal anastomosis procedures on stroke in off-pump coronary artery bypass grafting. *Journal of Cardiac Surgery*. 2009;**24**(6):644-649
- [29] Tabas I, Garcia-Cardena G, Owens GK. The cell biology of disease: Recent insights into the cellular biology of atherosclerosis. *Journal of Cell Biology*. 2015;**209**(1):13-22
- [30] Vassiliades TA Jr, Nielsen JL, Lonquist JL. Hemodynamic collapse during off-pump coronary artery bypass grafting. *The Annals of Thoracic Surgery*. 2002;**73**(10):1874-1879
- [31] Neumann FJ, Sousa-Uva M, Ahlsson a, et al; ESC scientific document group. 2018 ESC/EACTS guidelines on myocardial revascularization. *European Heart Journal*. 2019;**40**:87-165