

We are IntechOpen, the world's leading publisher of Open Access books Built by scientists, for scientists

4,800

Open access books available

122,000

International authors and editors

135M

Downloads

Our authors are among the

154

Countries delivered to

TOP 1%

most cited scientists

12.2%

Contributors from top 500 universities



WEB OF SCIENCE™

Selection of our books indexed in the Book Citation Index
in Web of Science™ Core Collection (BKCI)

Interested in publishing with us?
Contact book.department@intechopen.com

Numbers displayed above are based on latest data collected.
For more information visit www.intechopen.com



Deformity of Craniofacial Skeleton by Traumatic Injuries

Raja Kummoona

Abstract

Road traffic crashes on highways with high speed cars can end with termination of life. Immediately after the accident, the medical management includes early transportation by ambulance with highly equipped machines, skilled nurses and doctors to check blood pressure, blood loss, and breathing, administration of intravenous fluid plasma and collecting blood samples for blood grouping. Other treatment can be undertaken by ambulance staff such as temporary splinting (SPICA) of fractured legs and neck support. A helicopter may be used for urgent transport of injured patients with multiple injuries to highly equipped intensive care units in general hospitals. The cooperation of different specialties is required, such as neurosurgeons, craniomaxillofacial surgeons, chest surgeons, general surgeons, and orthopedic surgeons. The order of priority is head injuries, chest injuries, and abdominal injuries. Neglecting early treatment opportunities or delaying treatment results in severe deformities of the facial skeleton and damage to growth of the face in children, leading to severe deformity of the face. Isolated injuries to the eye orbit, nose, jaws, and temporo-mandibular joint (TMJ) may end in ankylosis of the joint in children. A series of clinical cases will be shown.

Keywords: trauma, injuries, craniofacial, deformity

1. Introduction

Road traffic accidents (RTA) in highways occur due to a crash between cars or motorcycles and these crashes cause very common injuries worldwide. It's a disaster and can end in severe injuries to the drivers and passengers. There have been great advances in injury management and in the prevention of these severe cases; some of them with multiple injuries.

There are many steps in the process of early transportation to hospital by ambulance, with highly trained personnel with fully equipped ambulances. The process starts with checking blood pressure, pulse rate, measuring oxygen saturation, giving IV fluid, collecting plasma and blood samples for blood grouping, checking blood sugar. In cases with severe bleeding from the nose and mouth, they have to open the airways by performing a tracheotomy before reaching the emergency room in the hospital. Helicopter transportation might be used for critical cases with multiple injuries such as head injuries, severe facial skeleton injuries, chest injuries, abdominal injuries, and limb injuries [1].

There have been great advances in the radiological diagnostic tools including ultrasound and Doppler, three-dimension CT scan, MRI, and radiological X-ray

equipment, including tomography with advances in biochemistry analysis. All these tools assist in the evaluation of the severity of injuries, in addition to proper clinical examination.

Many steps are taken to reduce the severities of car crashes with less damage to the head, chest, and abdominal organs by controlling the rate of speed, preventing alcohol consumption during driving, the wearing of helmet for motorcycle drivers, and compulsory shoulder seatbelts and seat restraints with a special chair for children in the back seat [1].

Vehicle safety measures are incorporated during the manufacturing of cars, from manufacturing air bags to protect the driver and all passengers in small cars, to having safety glass beads with collapsible steering to reduce the trauma to the head, face, and chest. Children should sit in the back in a special seat. All these measures have significantly reduced the incidence of road traffic crashes in both children and adults.

1.1 Materials, results and discussion

As we reported previously in 2011, clinical studies included 673 patients with craniofacial injuries and there were 530 males and 143 females, in the age range between 1 and 75 years (mean 38 years).

Distribution of injuries was as follows: fracture of the mandible 287 (42.64%), middle third injuries 39 (5.79%), and orbital injuries 236 (35.07%) including 12 cases of cranio-orbital ethmoidal injuries. In children, we reported 27 cases (4.0%) of the total cases, we reported also 52 cases that represent (7.73%) zygomatic complex, and zygoma and fracture nose were reported in 40 cases, which form (5.94%) the total cases. 1.

The many advances in the treatment of craniomaxillofacial injuries have been achieved by improvements in medication, tools of diagnosis, and anesthetic machines and medication. These are in addition to the skills and expertise of the anesthetists and care of injured patients by advancing trauma life support by application of the Kummooona 4 golden C rules and ATLAS [2] by,

1. Control of breathing and maintenance of patient airway (tracheotomy sometimes required).
2. Control shock and circulation by intravenous fluid (IV), plasma, and blood after blood grouping.
3. Control of bleeding by cauterization of small vessels and ligation of large vessels.
4. Control of bone fragments and soft tissue laceration.

Craniofacial injuries have been classified as follows:

- A. Craniofacial injuries with cerebrospinal fluid (CSF) leakage
- B. Fractures of middle thirds Le Fort I, Le Fort II, and Le Fort III and sometimes with midline split of the face with or without CSF leakage
- C. Fracture of mandible and other isolated injuries such as simple zygoma fracture or more complicated zygomatic complex, orbital skeleton complex and isolated nose fracture.

The most common anatomical area damaged in severe road traffic accidents in the cranial region was the frontal bone with anterior cranial fossa, roof of both orbits, and nose with Dura tears and CSF leakage with head injury [1–3].

The facial skeleton consists of fifty small bones articulating like a pyramid, the top of the pyramid is the nasal tip. Seldom is only one bone of the facial skeleton fractured. The shape and function of the facial skeleton bony articulation acts as a shock absorber and cushion to absorb the impact of trauma and this is because these small bones of the facial skeleton also absorb the force of mastication transmitted along and through the buttress of bones to the base of the skull and this shock absorber of the facial skeleton also protects the vital structures from severe trauma to the underlying vital structures of vision, hearing, smell, taste, speech, and swallowing.

In children, the growth of the face is not completed, except the orbit, in 7 years. Once trauma has occurred, the impact of severe trauma can displace the middle third of the face downward and backward by 45°, with the palate of the maxilla positioned on the dorsum of the tongue, obstructing oral airway with profuse bleeding from fractured nose due to injuries to ethmoidal arteries obstructing nasal airway. This combination of injuries is associated with head injuries, chest injuries, and abdominal injuries and is critical and a life threatening condition.

If children survived from these injuries, they usually recover quickly. Mistreated cases end with severe deformities of the craniofacial region because they received great damage to the growth centers in the cranial sutures, base of skull (sphenoid-occipital synchondrosis), cartilage of the nose, and primary growth center in the condyle.

Treatment of craniomaxillofacial trauma injuries requires expertise, skills and knowledge and these injuries should be treated in highly equipped cranial-maxillofacial centers. Mismanagement or delays in treatment end with severe deformities of the craniofacial region and end by destroying the life of the victim. Even an isolated fracture of the nose, orbit, zygoma, or jaw can end with obvious deformity in a time where people are very concerned about their appearances.

Our aim was directed to prevent complications, deformities, and to restore the normal function and esthetic features of the craniofacial region.

Severe cases of craniomaxillofacial injuries with head injuries and chest injuries need to be admitted immediately to an intensive care unit for a few days until the patient has recovered from the head and chest injuries before adequate treatment of the craniofacial injuries [1–4].

The treatment of a CSF leak usually follows the conservative principle of reduction and repair of craniofacial fractures through the following steps:

1. Reduction of intra cranial pressure (ICP) by elevation of the head by 45°
2. Reduction of CSF leakage using carbonic anhydrase inhibitors (Acetazolamide {Diamox 3-kcl}) 250 mg twice daily, to correct hyperkalemia as a complication of Diamox and 4 triple antibiotics to prevent meningitis
3. The CSF leak usually stops within 4–5 days. If the CSF does not stop, a lumbar puncture is required to reduce the ICP by aspiration of CSF
4. If the CSF leakage does not stop after all the previous procedures and measurement, perform a craniotomy indicated for Dura repair by piece of Gale aponeurosis or a piece of temporalis muscle and sutured watertight.

The treatment of head injuries is the responsibility of the neurosurgeon, with collaboration of the craniofacial surgeon [2].

We undertook research on CSF analysis by taking several samples from patients with head injuries and blood serum from the same patients to study the differences between the two samples. We used a high specific isoelectric focusing electrophoresis set on polyacrylamide gel for direct immunofixation of transferrin by a plex electrophoresis set and spectrophotometer for serum sample. Using this study, we can detect the CSF leakage due to traumatic injuries and differentiate it from serum exudate.

Through this research we were able to detect the concentration of the B2-Transferrin enzyme in CSF and this level was 90.26 ppm, which represents about 35 times more than that detected in serum exudate [1].

The facial skeleton and the face are the mirror of the body reflecting happiness, sadness, beauty, and ugliness. The face is a mirror of intelligence and dullness and it also shows the body's signs of disease such as paleness, dryness of skin, yellow skin, dark or bluish skin, blisters, or pigments. These are all features of illness.

2. Clinical features, deformities and treatments

Trauma to the face and subsequent deformities is a disaster to the patient and our duty is to restore the normal architecture of the face by restoring esthetic and functional activity of the facial skeleton. The problem is that the face is not padded by clothing and traumatic impact has a direct effect on the soft and hard tissue of the face. Once an accident has happened, we have to direct our effort to repair the soft tissue properly as the first step and to put every piece of bone of the facial skeleton in its anatomical position and to fix it either by plating or by soft stainless steel wires of 0.25 and 0.5 mm as a basic principle. Soft tissue damage may be a laceration or loss of soft tissue and these are repaired using local rotational flaps or regional flaps such as the forehead flap or Kummoona lateral cervical flap [5].

Deformities of the frontal bone and anterior cranial fossa can occur with severe trauma to the area associated with severe nasal-ethmoidal-orbital bone injuries with CSF leakage and head injuries. Serious injuries require admission to intensive care units until the patient recovers from the head injuries. A craniotomy through a bi-coronal flap is used for exploration of the anterior cranial fossa after retraction of the brain. Dura are repaired by galea aponeurosis or a piece of temporalis muscle with watertight suturing with silk and reconstruction of the anterior cranial fossa and the roofs of both orbits by bone grafting from the iliac crest. The frontal bone is repaired by bone graft or by rubber silicone material (Sialastic). The nose can be reduced at the same time [3] (Figures 1–3).

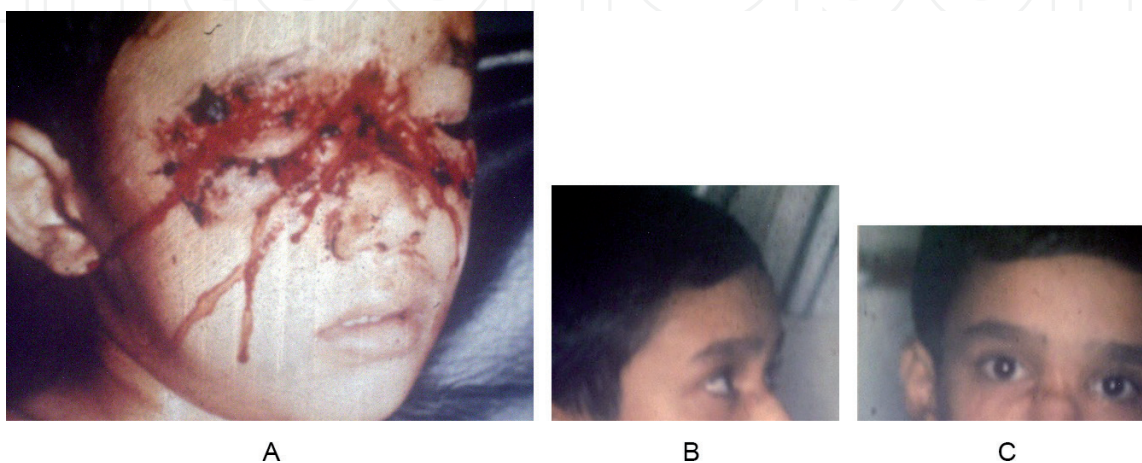

Figure 1. (A) Severe traumatic injuries to the nasal-ethmoidal-orbital region with laceration of overlying skin in a 4-year-old boy. (B and C) Post-operative photo after reconstruction of the region after 2 years.

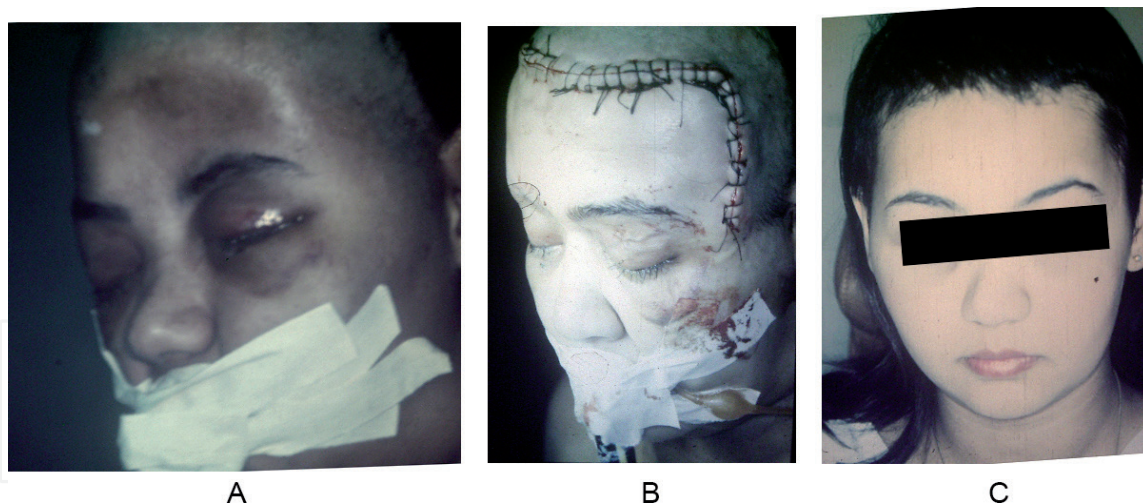


Figure 2.
(A) Severe road traffic accident with deformity of cranial-facial region with damage to frontal bone, anterior cranial fossa with Dura tear; CSF leakage, and nasal-ethmoidal-orbital skeleton and nasal bone. (B) Bi-coronal flap used for craniotomy and for exploration of the anterior cranial fossa, for reconstruction of Dura, anterior cranial fossa, roof of the orbits, frontal bone, and nasal-ethmoidal-orbital region by bone graft and Sialastic implant. (C) Post-operative photo after 3 months showing slight dislocation of medial canthal ligament.

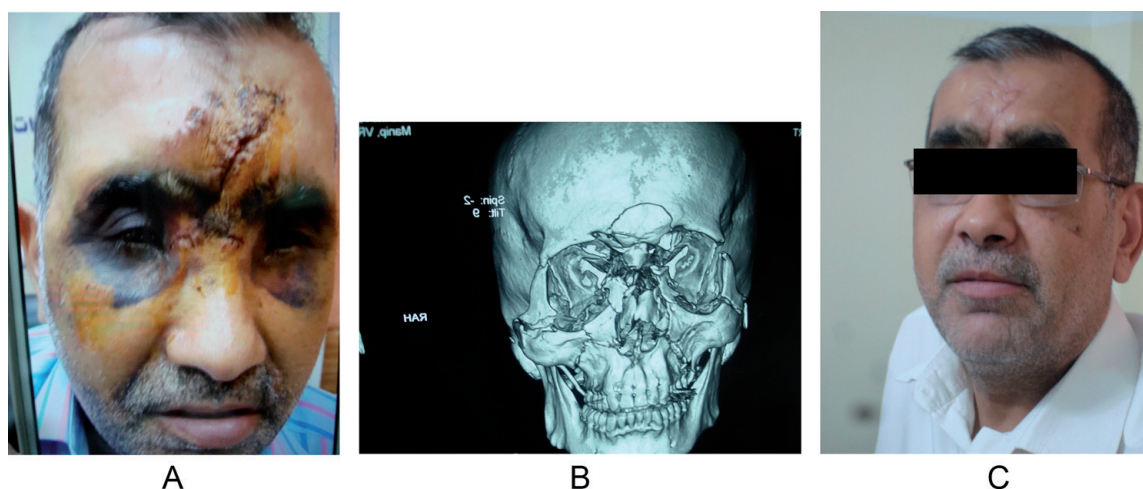


Figure 3.
(A) Severe injuries from a road traffic accident to the craniofacial region with CSF leakage, elongation of the face, and displacement of the facial skeleton downward and backward. (B) 3D CT scan of the face showing the severity of the injuries. (C) Three months post-operative photo showing restoration of the facial skeleton after several operations.

Deformities of the face can occur either to the whole facial skeleton in a scattered manner or to a part of it, such as the orbital skeleton damage with the globe of the eyes, an isolated fracture roof with downward displacement of eye ball, a fracture of the medial wall with dislocation of medial canthi and damage to nasolacrimal duct with enophthalmos, fracture of the floor of the orbit featuring diplopia and enophthalmos, or fracture of the zygoma and lateral wall with displacement of the zygomatic bone either downward or laterally or rotated or inward.

In more severe cases with compression of the superior orbital fissures, this can result in superior orbital fissure syndrome and will be manifested as exophthalmos, ptosis, ophthalmoplegia, and fixed pupil with loss of vision and loss of sensation in the surrounding area and edema of the eyelids. Immediate treatment may restore the function of the eye and vision by reduction of zygomatic bone and elevation of compression on the superior orbital fissure. If there has been a severe impact with a sharp object to the globe of the eye with severe laceration and with no response of the pupil to light, evisceration of the eye must be performed by an ophthalmologist [6–8] (Figures 4–6).

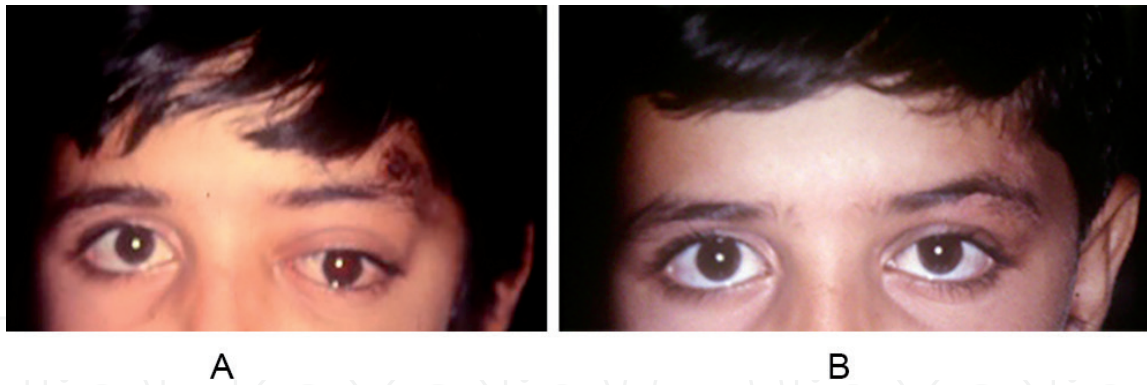


Figure 4. (A) Deformity of the orbit due to traumatic injuries with downward displaced eyeball due to fracture in the roof of the orbit of a 4-year-old boy. (B) Post-operative photo after reconstruction of the roof of the orbit by Sialastic implant.

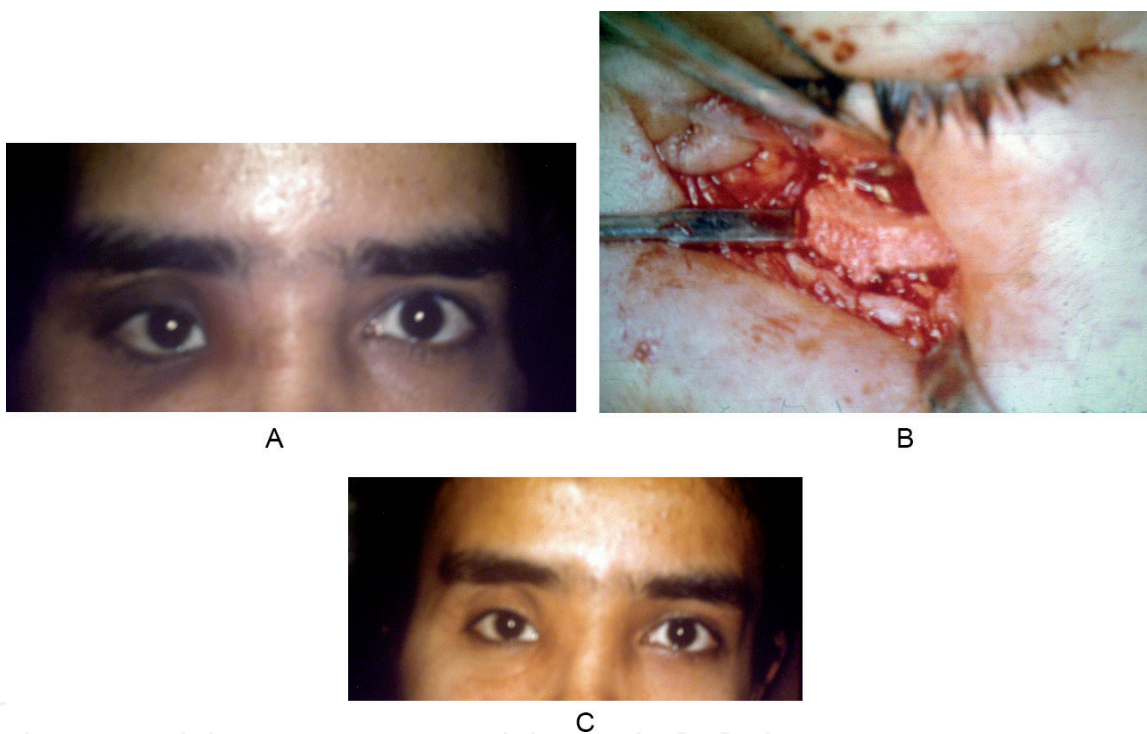


Figure 5. (A) Severe enophthalmos due to traumatic injury to the floor and medial wall of the orbit with dislocation of medial canthal ligament. (B) Reconstruction of the orbital floor by bone graft from iliac crest. (C) Post-operative photo after reconstruction of the floor and medial wall and fixation of median canthal ligament.

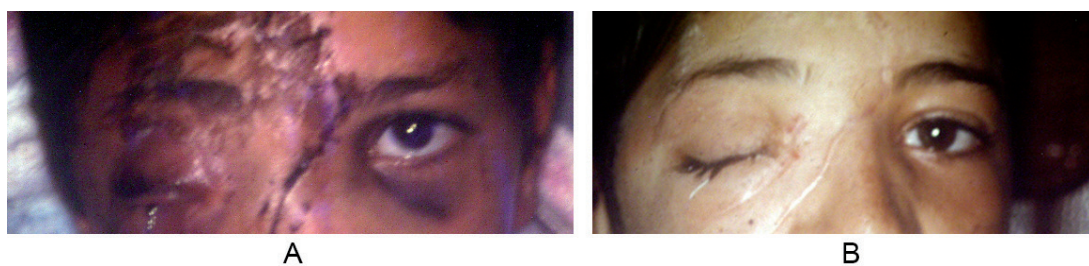

Figure 6. (A) Severe injuries to orbital skeleton and content with loss of eyeball. (B) Reconstruction of all orbital skeleton with ptosis of upper lid required in a secondary surgery and artificial eyeball.

Bad injuries to the mandible with multiple fractures and delayed treatment can cause severe deformity with open bite and malocclusion. Usually the injuries affect the body and angle either as a favorite fracture or an unfavored fracture. The favorite fracture is not affected by muscles of mastication. The direction of the fracture line plays an important role in preventing displacement. The unfavorite type of fractures of the angle with displacement were affected by temporalis, medial pterygoid, and masseter muscles. These fractures required an open reduction through a submandibular incision, fixation of fragments done by plating or by soft stainless steel wire of 0.5 mm as a double eight crossing each other with inter maxillary fixation (IMF). A less severe form of this fracture angle might be treated by upper border wiring with IMF (**Figure 7A–D**).

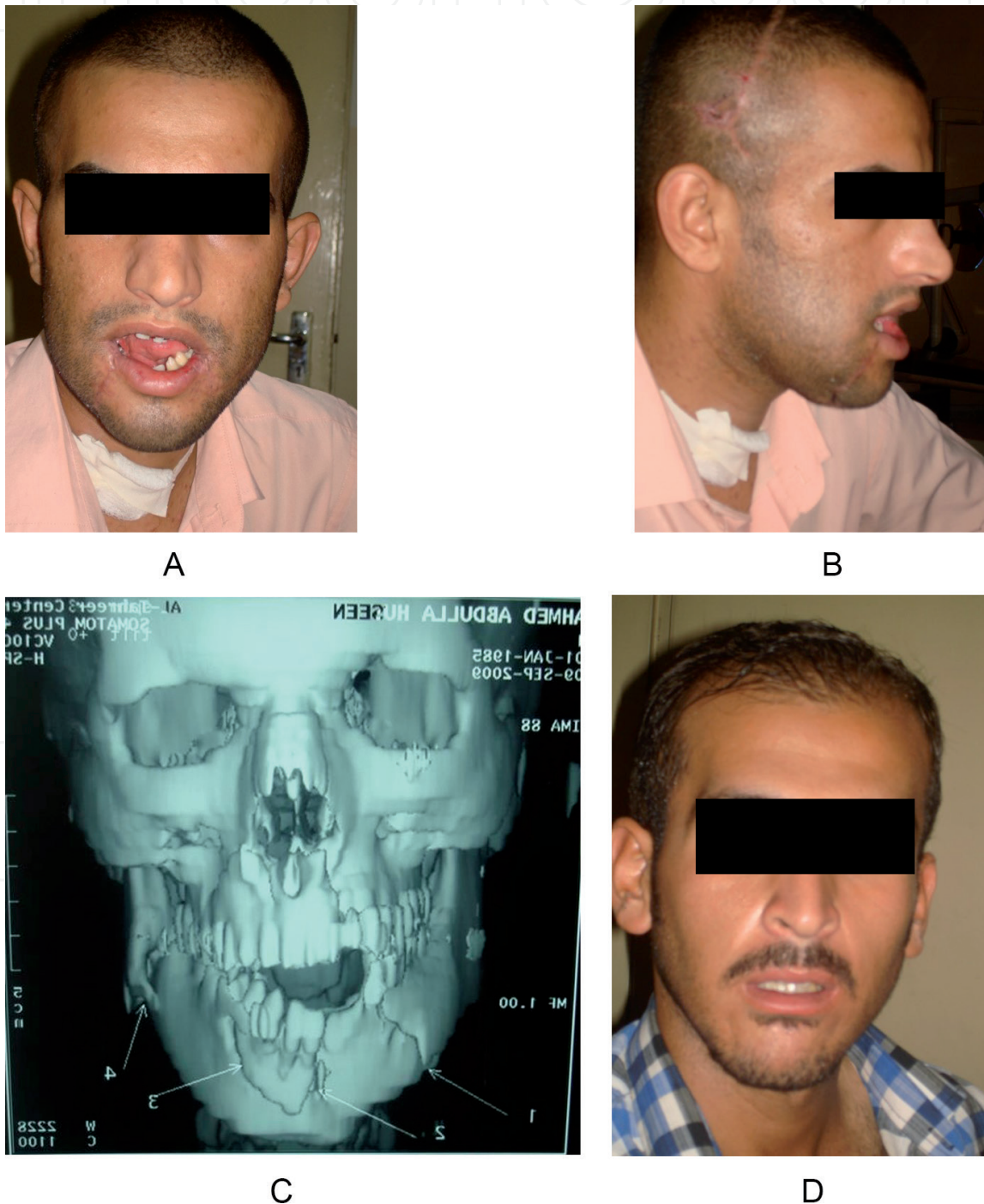

Figure 7. (A and B) Severe traumatic deformity of the mandible with open bite and injuries to cranial region with head injury and CSF leakage treated by craniotomy and Dural repair. (C) 3D CT scan of lower jaw showing multiple injuries. (D) Six months post-operative photo.

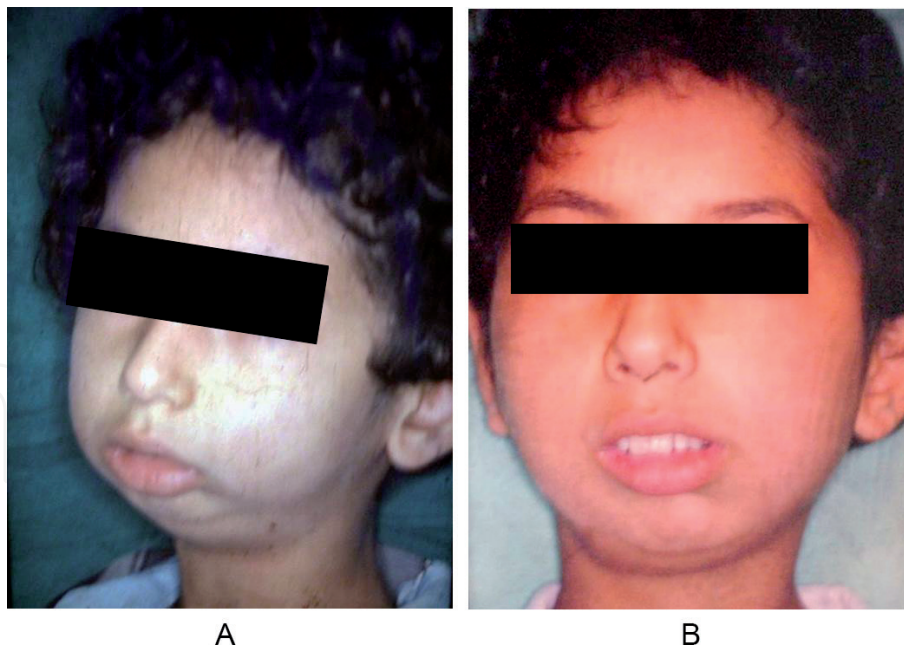


Figure 8.

(A) Severe deformity of the mandible due to intra-uterine injuries to the right temporo-mandibular joint and the child born with ankylosis of the TMJ. (B) One year post-operative after reconstruction of the right TMJ by Kummoona Chondro-Osseous graft at age of 5 years.

The other types of fracture affect the ramus and the most common two types of fractures are the condylar (intra capsular) type and sub condylar type. The intracapsular type of fracture condyle is a very serious injury that requires special attention while the sub condylar type is treated by inter maxillary fixation (IMF) for 3–4 weeks.

Intracapsular fracture of the condyle in children is very serious. If mistreated, it can lead to ankylosis with severe deformity of the mandible and midface due to damage to the growth center in the condyle. Early treatment of an intracapsular fracture should be carried out by administration of a few drops of hydrocortisone to prevent adhesion and to reduce edema with IMF for 3–4 days to relief spasm of muscles and to remodel the shape of the condyle followed by early mobilization.

Once adhesion of the condyle had occurred and deformity of the jaw has appeared, we must excise the ankylosed joint with hyperplastic coronoid, re-attach of the muscles of mastication and reconstruct the TMJ by using Kummoona Chondro-Osseous graft was harvested from iliac crest in children for restoration of growth, remodeling, and repair of the condyle (**Figure 8**). The graft can restore the growth of the mandible and midface and prevent residual deformity [2, 4, 6].

In craniofacial injuries, after reconstruction of the anterior cranial fossa and frontal bone, we have immediately to reduce and fix the middle third fracture of the facial skeleton including Le Fort I, II, III, and mid line split of the face. Reduction was achieved by using Rowe dis impaction forceps to move the displaced facial skeleton upward and forward in the reverse direction of the displacement of the middle third and to put the skeleton in its normal anatomical position with intermaxillary fixation (IMF).

Fixation of the facial skeleton was performed by using our techniques of fixation by suspension of middle third through the sandwich technique using soft stainless steel wire of 0.5 mm and making hole by using round bur in the frontal-zygomatic suture above the fracture line and the wire is passed below the zygoma down through the cheek to the lower arch bar fixed by wires and IMF and reinforced by a circum-mandibular wire with proper occlusion of the teeth.

Another technique is the Halo Frame fixed by 4 pins to the skull and again two cheek wires attached to the Halo Frame and passed below the zygoma to the upper or lower arch bar. Another technique is the Box frame technique that requires insertion of 4 pins (2 in the frontal process of the frontal bone and 2 pins in the angle of the lower jaw) with 4 rods fixed after reduction of the displaced midface with IMF to achieve proper occlusion. The success of treatment is based on proper occlusion and proper fixation of the small bones of the facial skeleton to be sited in their anatomical position and to get normal facial length and height.

3. Conclusion

The aim of our research is to share our techniques and expertise in the treatment and management of traumatic craniofacial deformities with other colleagues worldwide.

In this clinical research, we studied 673 patients with craniofacial injuries and deformities and the incidence of these injuries to affect various parts of craniofacial region, we did classify these injuries and how serious, primary care described thoroughly and cases with cranial or LeFort III injuries might associated with CSF leakage, methods of management were described by conservative technique if not by craniotomy. Different techniques for reduction and fixation of the craniofacial regions were also described.

This study shows the ability of the author to deal with very difficult cases of craniofacial region. I hope this chapter satisfies the curiosity of the readers.

Author details

Raja Kummoona

Maxillofacial Surgery, Iraqi Board for Medical Specialization, Baghdad, Iraq

*Address all correspondence to: raja_kummoona@hotmail.com

IntechOpen

© 2020 The Author(s). Licensee IntechOpen. This chapter is distributed under the terms of the Creative Commons Attribution License (<http://creativecommons.org/licenses/by/3.0>), which permits unrestricted use, distribution, and reproduction in any medium, provided the original work is properly cited. 

References

[1] Kummoona R. Managements of maxillofacial injuries in Iraq. *Journal of Craniofacial Surgery*. 2011;22:1561-1567

[2] Kummoona R. Pediatrics maxillofacial injuries with special attention to fracture condyle. *EC Pediatrics*. 2017;5(6):170-171

[3] Kummoona R. Orbital trauma with special references to pediatrics and children. *EC Pediatrics*. 2018;7(5)

[4] Kummoona R. Pediatrics and children facial deformity with special reference to Ankylosis of the TMJ. *EC Pediatrics*. 2018;7(3):112-115

[5] Kummoona R. Kummoona lateral cervical flap for reconstruction of oral defect after cancer surgery. *Clinical Case Reports*. 2018;1(1):1006

[6] Kummoona R. Temporomandibular joint ankylosis that affect children and reconstruction by Kummoona Chondro-Osseous Graft. *EC Pediatrics*. 2018;7(11)

[7] Kummoona R. Pediatrics and children facial deformity with special reference to ankylosis of the temporomandibular joint. *EC Pediatrics*. 2018;7(3):112-115

[8] Kummoona R. Kummoona Chondro-Ossous graft good substitute to condylar growth center and fore correction of facial deformity in children. *Archives of Otolaryngology and Rhinology*. 2017;3(3):098-102