

We are IntechOpen, the world's leading publisher of Open Access books Built by scientists, for scientists

4,800

Open access books available

122,000

International authors and editors

135M

Downloads

Our authors are among the

154

Countries delivered to

TOP 1%

most cited scientists

12.2%

Contributors from top 500 universities



WEB OF SCIENCE™

Selection of our books indexed in the Book Citation Index
in Web of Science™ Core Collection (BKCI)

Interested in publishing with us?
Contact book.department@intechopen.com

Numbers displayed above are based on latest data collected.
For more information visit www.intechopen.com



Introductory Chapter: An Overview of the Diagnosis and Treatment of Non-tubal Ectopic Pregnancy

Julio Elito Jr

1. Introduction

Non-tubal ectopic pregnancies represent 7–10% of all ectopic pregnancies [1]. The incidence is increasing in the past years especially because of assisted reproduction treatment, particularly IVF, and the high rates of cesarean sections [2].

Non-tubal locations of ectopic pregnancies are cervix, cesarean section scar, interstitial portion of the fallopian tube, cornual, ovary, abdominal cavity, and broad ligament (**Figure 1**).

There is a broad spectrum of clinical presentation according to the location of the pregnancy. The first symptoms are pelvic pain and vaginal bleeding. In ruptured ectopic pregnancies, the patients present with severe abdominal pain, shoulder tip pain, nausea, vomiting and dizziness and collapse. However, some women with ectopic pregnancy are asymptomatic.

The diagnosis is usually late, because these pregnancies present themselves later than tubal pregnancies. Therefore, the risks of maternal morbidity and mortality are higher than in tubal ectopic pregnancies.

The management of non-tubal ectopic pregnancy depends on their location. The cases of abdominal pregnancy must be individualized and the treatment is different from the other sites of ectopic pregnancy. The diagnosis of ovarian pregnancy is usually confirmed only during the surgery.

The other sites (cesarean scar, cervical and interstitial pregnancy) follow a similar non-surgical protocol.

The classic treatment is surgery; however, it is very aggressive, because in the majority of the cases it is necessary to perform a hysterectomy. Several minimally invasive techniques have been proposed to avoid the mutilation of the uterus. Some of the alternative treatments to avoid surgery are local injection of MTX guided by transvaginal ultrasound, systemic medical treatment with methotrexate (MTX), and embolization of uterine arteries. There are several case reports in this subject but very few original articles. And in the few articles, there is no consensus on the best treatment. This book aims to provide the reader with a concise, comprehensive, and updated review of the epidemiology, diagnosis, and treatment of non-tubal ectopic pregnancy. As there is a lack of consensus on the guideline for the treatment of non-tubal ectopic pregnancy, this book intends to fill this gap in the literature, compiling the best evidences in the medical literature guiding the reader on choosing the adequate treatment. An overview of each non-tubal ectopic pregnancy site will be presented in this introductory chapter.

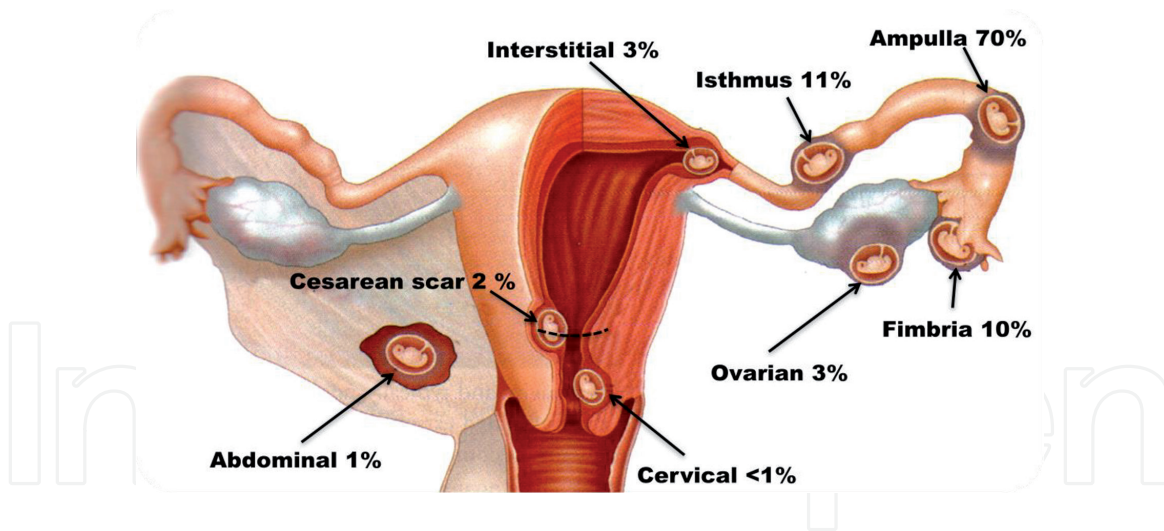


Figure 1.
Principal sites of ectopic pregnancy.

2. Ovarian pregnancy

It represents 3% of ectopic pregnancies [3]. The sonographic aspect of ovarian pregnancy may range from gestational sac containing embryonic structures to solid and complex masses similar to those of tubal pregnancy. The major diagnosis difficulty is due to the fact that the pregnancy develops in the intimacy of the ovarian parenchyma, losing the reference used in tubal pregnancy, which is to identify the ovaries and then look for the pelvic mass. In the case of tubal pregnancy, it is imperative to demonstrate the ipsilateral ovary, as well as the adnexal mass, in order to decrease the possibility of false-positive diagnosis with ovarian masses. Therefore, ultrasound in this eventuality is not specific, once it may confuse ovarian pregnancy with other ovarian tumors. If gestational sac characteristics with embryonic structures are observed in the ovary, the diagnosis can be made with great precision [4].

Due to the difficulty of confirming the diagnosis noninvasively, most of the time, it is made during the intraoperative period. Thus, MTX treatment is used sporadically.

3. Intraligamentary abdominal pregnancy

Intraligamentary abdominal pregnancy is a rare form of ectopic pregnancy with a reported incidence of less than one in 250 ectopic pregnancies [5]. It usually results from the trophoblastic penetration of a tubal pregnancy through the serosa into the mesosalpinx, with secondary implantation between the leaves of the broad ligament. The placenta usually invades the intraligament space, ovary, uterus, omentum, pelvic peritoneum, and adjacent viscera [6].

Signs that may suggest intraligamentary abdominal pregnancy are abnormal vaginal bleeding, abdominal pain, painful fetal movements, easy palpation of the fetal parts, excessive nausea and vomiting, evidence of intrauterine growth restriction, and oligoamnios. The main antenatal complications include abdominal pain, gestational sac rupture with hemorrhage to the peritoneal cavity, vaginal bleeding, anomalous presentation, placental insufficiency, and fetal death.

During surgery, the placenta should preferably be removed to reduce the risk of peritonitis, abscess, disseminated intravascular coagulation, and persistent trophoblastic disease.

Intraligamentary pregnancy is a condition of high maternal morbidity and mortality, and a judicious preoperative evaluation and surgical technique are imperative for a favorable outcome.

4. Abdominal pregnancy

It constitutes of about 1.5% of ectopic pregnancies [7]. It represents a risk of maternal death 7.7 times higher than that of tubal pregnancy and 90 times higher than that of intrauterine pregnancy [8]. The blastocyst can be implanted anywhere in the abdomen and in the different organs covered by the visceral peritoneum. Thus, in abdominal pregnancy, there is the development of the pregnancy in the peritoneal cavity. It can be classified into primary or secondary. Primary abdominal pregnancy is rare; most are secondary due to tubal rupture or tubal abortion. Few fetuses survive in the abdominal cavity and advance beyond the second trimester of pregnancy. The diagnostic and therapeutic difficulties are remarkable regardless of the location of advanced abdominal pregnancy.

The most frequent ultrasound findings in abdominal pregnancy are as follows [9]:

- Uterus separated from fetus (90%)
- Extrauterine placenta (75%)
- Oligoamnium (45%)
- Fetal parts near the abdominal wall (25%)
- Absence of myometrium between fetus/placenta and bladder (15%)
- Anomalous fetal presentation (25–70%)
- Difficulty viewing the placenta (25%)
- Maternal intestinal loops obscuring fetal visualization (25%)
- Fetal anomalies (20–40%)
- Restricted intrauterine growth
- Lack of communication between endocervical canal and gestational sac

The most important signs are overlooked by the examiner because some unusual findings do not draw the examiner's attention to the diagnosis of abdominal pregnancy. For example, uterine walls should be visualized even if attention is focused entirely on fetal evaluation, as myometrial tissue may not be identified. Given the clinical suspicion of abdominal pregnancy (the mother reports feeling the child superficially in the abdomen), ultrasound becomes mandatory, but will not always be able to confirm the diagnosis accurately. Magnetic resonance imaging can confirm the diagnosis.

Fetal survival in abdominal pregnancy is the exception rather than the rule, and the live-born fetus is often malformed. As conditions for the concept are precarious, they succumb most of the time. In abdominal pregnancy, perinatal mortality ranges

from 85 to 95% and maternal mortality is around 3% [10]. Anomalies occur in about 1/3 to 1/4 of the fetuses whose viability is possible.

As pregnancy progresses, the placenta develops in any portion or organ of the abdominal cavity. We often observe digestive symptoms of subocclusion and excessive abdominal pain to fetal movements. The superficiality of the fetus is clear on palpation, as well as the auscultation of the fetal heartbeat. Ultrasound may demonstrate that the uterus is empty and compressed by the fetus and placenta.

As fetal survival is the exception, many advise against hospitalization to await the viability of the fetus. In addition, the risk of life-threatening bleeding is high.

In cases of late diagnosis and with the fetus alive, the follow-up may be to wait until the 36th week. In the presence of a dead fetus or living fetus after the 36th week, laparotomy is required. Antenatal diagnosis of abdominal pregnancy is essential for proper planning of the procedure. Precise placement of the placenta can be done more accurately by magnetic resonance imaging (MRI). Preoperative care should be individualized for each case according to its severity. Interventional radiology can be used with the placement of balloon catheters to prevent significant bleeding during surgery. In cases of dead fetus, selective embolization of the placental vessels may be performed. In addition, a multiprofessional staff may be required to perform insertion of ureteral catheters (double J), bowel preparation or transfusion blood reserve. An appreciable volume of blood and catheterized veins should be available to allow large volume to be infused rapidly, as well as a central venous pressure control and diuresis. In surgery, once the fetus is removed, the placenta is observed and, in particular, the site of its implantation. In cases where the placenta is attached to large vessels and the diagnosis is only made during surgery, the placenta could be left to prevent massive bleeding and the cord removed very close to its implantation site. This attempt should be considered to transfer the patient to a tertiary hospital. Evidently, there is a possibility of complications, infection, abscess formation, bruising, and intestinal obstruction.

5. Interstitial pregnancy

Interstitial pregnancy is defined as an ectopic pregnancy that is implanted in the interstitial portion of the fallopian tube. The interstitial portion is thick, 0.1–0.7 mm in diameter and 1–2 cm in length, and this part of the tube has a greater capacity to expand before rupture than the other segments of the tube [11]. Therefore, some cases are asymptomatic until the end of the first trimester of gestation and rupture may occur resulting in severe hemorrhage [12]. Because of the rich vascular anastomosis of the uterine and the ovarian arteries in this region, there may be accentuated hemorrhage. For this reason, early diagnosis is essential to reduce morbidity and mortality.

Interstitial pregnancies account for only 2–4% of ectopic pregnancies. However, the mortality rate is 2.5% [13]. This is because of the difficulty to confirm the diagnosis. Therefore, the late presentation could result in rupture and hemorrhage.

Interstitial pregnancy sometimes is incorrectly confused with cornual. Cornual pregnancy refers to a pregnancy in a horn of a bicornuate uterus or a rudimentary noncommunicating cavity horn or other Mullerian anomalies. The clinical outcome of cornual pregnancy varies greatly, depending on the size and expansile nature of the affected horn.

Risk factors for interstitial pregnancy are previous ectopic pregnancy, previous ipsilateral or bilateral salpingectomy, conception after *in vitro* fertilization, and history of sexually transmitted disease [14]. The symptoms of interstitial pregnancy

are pelvic pain and vaginal bleeding in the first trimester of pregnancy. On physical examination, an asymmetric uterine enlargement may be palpable. Signs of acute abdomen may occur in interstitial pregnancy rupture with hemoperitoneum; in some cases, tachycardia and hypotension may be present.

The following are the ultrasound features for the diagnosis of interstitial pregnancy are (**Figure 2**):

- Interstitial line (echogenic line between the gestational sac in the interstitial region and the endometrial cavity)
- Eccentrically located gestational sac and myometrial thickness less than 5 mm

It is important to point out that some viable intrauterine pregnancies are visualized by ultrasound in its early stages, in one of the lateral angles of the uterine cavity, medial to the uterotubal junction. This situation usually evolves to a viable intrauterine pregnancy and in some cases the incorrect diagnosis could lead to an unnecessary pregnancy interruption.

Classical treatments for interstitial pregnancy are resection of the interstitial portion of the tube or hysterectomy. If the diagnosis is made before rupture, minimally invasive surgery and nonsurgical treatment options can be used. Conservative options include methotrexate administration (local and systemic), expectant management, and minimally invasive surgical techniques that include resection of the involved interstitial portion of the tube and preserving the uterine architecture. The potential advantage of clinical treatment is to avoid a surgical scar on the uterus and the risks associated to surgery.

Expectant management that has been practiced based on the natural course of many early EPs is a self-limiting process [16]. The patients selection for this management are hemodynamically stable patients, beta-hCG ≤ 2000 mUI/ml, decline

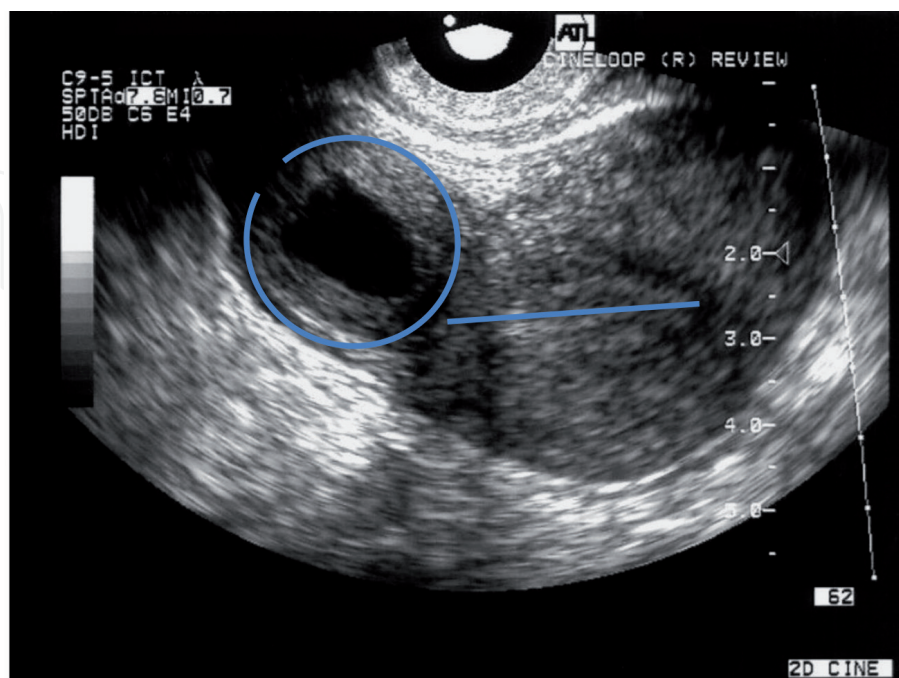


Figure 2. Interstitial ectopic pregnancy: Presence of an eccentric gestational sac with myometrial tissue that surrounds the gestational sac with a thickness of 2 mm and the interstitial line [15].

of the titers of beta-hCG in an interval of 24/48 h, and interstitial pregnancy mass ≤ 3.5 cm and without fetal cardiac activity.

Systemic methotrexate treatment was used for the first time in an interstitial pregnancy. In 1982, Tanaka et al. [17] successfully treated an interstitial pregnancy using methotrexate. Ectopic interstitial pregnancies without embryonic cardiac activity and beta-hCG ≤ 5000 mUI/ml should be treated using a single dose of MTX 50 mg/m² IM. Cases with beta-hCG > 5000 mUI/ml should be treated with a protocol of multiple doses of MTX. On the other hand, cases with embryonic heart activity should be treated with transvaginal administration of MTX under sonographic guidance.

6. Cervical pregnancy

Cervical ectopic pregnancy is defined by the implantation and development of the conceptus in the cervical canal. Among all ectopic pregnancies, the cervical pregnancy is the rarest, representing about 0.4% of cases [1]. It is accompanied by high morbidity and mortality, which can lead to severe hemorrhage, due to the rich vascularization of the cervix and a small amount of muscle fibers. The etiology is not well established; however, some predisposing factors were related, such as previous uterine curettages and cesarean section, Asherman syndrome, history of uterine and cervical surgeries, and in vitro fertilization. The diagnosis is made through history and physical examination and confirmed by ultrasound. Patients with menstrual delay and positive pregnancy tests may be asymptomatic, complain of vaginal bleeding, or even have severe vaginal bleeding. On vaginal examination, the cervix will be enlarged and congested, with painful tumoration. In addition, however, complaints and physical examination are often nonspecific, making clinical diagnosis difficult.

Early diagnosis made by ultrasound contributes to the success of conservative therapies. Ultrasound findings include empty uterine cavity; endometrial decidual reaction; hourglass-shaped uterus; enlarged cervical canal; gestational sac within the canal, with or without heartbeat; placental tissue surrounding the gestational sac; and closed internal os of the cervix. These findings can also be visualized in MRI with more accuracy (**Figure 3**).

If the clinical condition is unstable due to the hemorrhagic situation, it is valid to use the Foley catheter into the cervix insufflating from 30 to 100 ml while the patient is stabilized and then to evaluate the need for a hysterectomy.

With the development of conservative treatment protocols, the need for hysterectomies has decreased from 89.5% before 1987 to 21% in 1994. Conservative treatment options can be categorized as tamponade, which is performed with intracervical balloon after curettage; cerclage to reduce cervical artery blood flow associated with manual intrauterine cervical aspiration; reduced blood supply through embolization or uterine artery ligation; excision of trophoblastic tissue by hysteroscopic resection; intra-amniotic feticide, by local injection of methotrexate; and systemic chemotherapy with intramuscular methotrexate.

In cases of embryo without heartbeat with high beta-hCG titers, multiple dose of systemic MTX treatment is the preferred therapeutic option. When the embryo presents heartbeat, local treatment with MTX is indicated. Elito et al. [18] published a series of eight cases of cervical pregnancy with live embryo treated with transvaginal US-guided gestational sac puncture and MTX injection (1 mg/kg). All patients were successfully treated. The initial beta-hCG ranged from 3013 to 71,199 mIU/mL. Only one case evolved to infection. There was no need for further interventions in this case series. The time interval for beta-hCG titers to be negative was

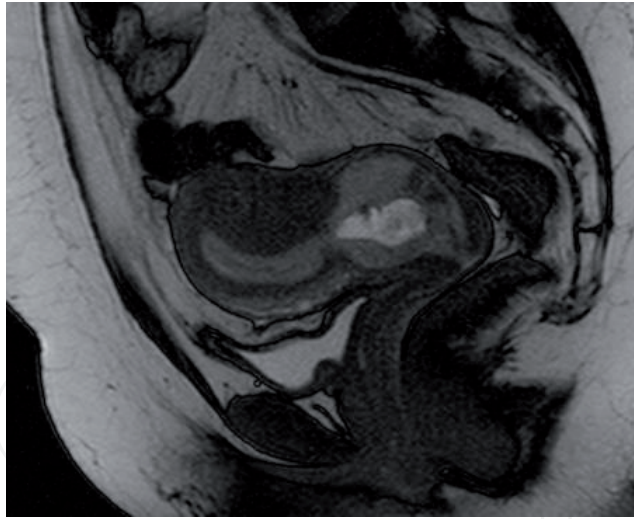


Figure 3.

Magnetic resonance image showing cervical pregnancy, hourglass-shaped uterus, empty uterine cavity, and cervix with heterogeneous mass inside. (author image file).

2–12 weeks. The period for the disappearance of the image of the ectopic pregnancy assessed by ultrasound was 3–14 weeks. Two patients had subsequent intrauterine pregnancies. The authors concluded that conservative treatment of cervical ectopic pregnancy with live embryos treated with transvaginal US-guided puncture and MTX injection is effective and avoids other mutilating interventions.

7. Cesarean scar pregnancy

Pregnancy in cesarean section scar is the rarest form of ectopic pregnancy. From the first case described in 1978 [19] to 2001, there were only 19 reported cases [20]. In 2006, there were 155 cases and in 2011 the number of cases described in the literature was 751, which shows a rapid increase in the incidence of this type of pregnancy. The estimated incidence is from 1 in 1800 to 1 in 2216 pregnancies, with a rate of 6.1% of all ectopic pregnancies in women with a history of previous cesarean section [1].

The basis of the pathophysiology is the invasion of the blastocyst in the myometrium through minimal communication between the anterior cesarean section scar and the endometrial cavity.

Risk factors are previous cesarean sections, short time between cesarean section and current pregnancy, IVF treatment, and retroverted uterus, which may lead to greater cesarean section scar dehiscence increasing the chance of implantation of the gestational sac in this region.

The cesarean scar ectopic pregnancy tends to behave more aggressively because of the risk of uterine rupture and bleeding in the first and second trimesters of pregnancy.

Transvaginal ultrasound allows early diagnosis of the disease before these tragic outcomes and allows conservative treatment rather than mutilating surgeries such as hysterectomy and then preserving fertility. It also allows differential diagnosis with ongoing abortion, molar pregnancy, and ectopic cervical pregnancy.

The diagnosis can be made by ultrasonography (**Figure 4**) and magnetic resonance imaging (**Figure 5**).

Transvaginal ultrasound findings for cesarean scar pregnancy include empty uterine cavity, decidual reaction, trophoblast located at the site of previous cesarean scar, and absence of healthy myometrium between the bladder and gestational sac.

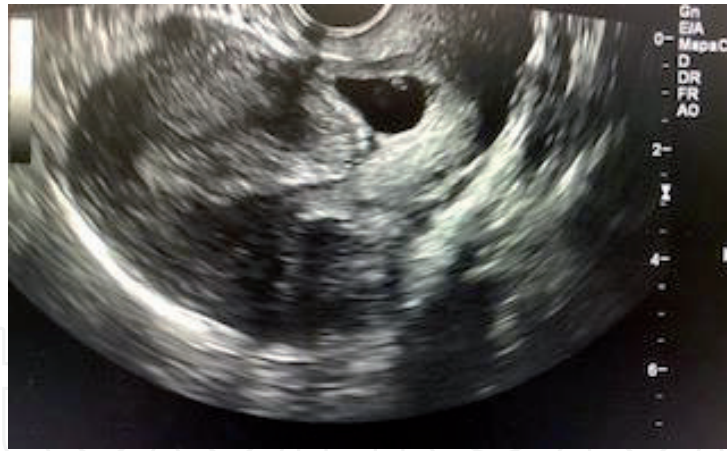


Figure 4. Cesarean scar pregnancy in the isthmic region with the presence of gestational sac with embryo. (author image file).

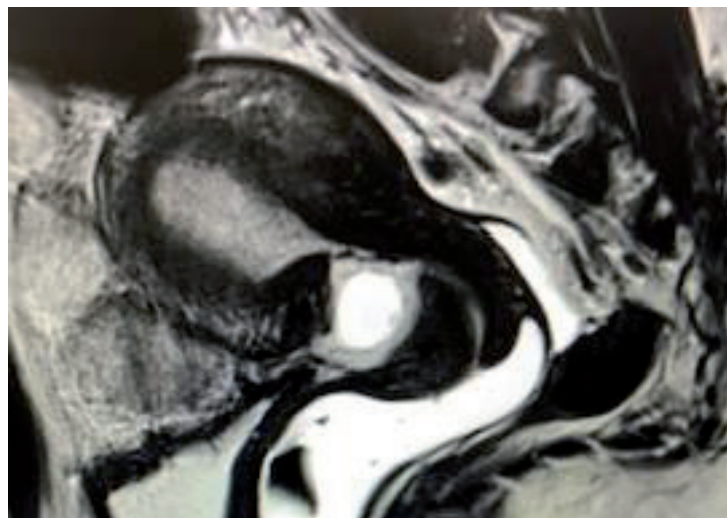


Figure 5. MRI of the uterus demonstrating an empty uterus, an empty cervical canal, the gestational sac being located in the anterior part of the isthmic portion of the uterus with a diminished myometrial layer, and a discontinuity in the anterior wall of the uterus.

There are two types of ectopic pregnancy in cesarean scar section: endogenous and exogenous. In the endogenous type, gestational sac implantation occurs in the cesarean section scar, with the development of pregnancy toward the uterine cavity. The exogenous type occurs with deeper implantation of the gestational sac in the cesarean scar, and as the pregnancy develops in the direction of the bladder, it increases the risk of rupture and hemorrhage in the first trimester of pregnancy.

The relationship between the gestational sac of a cesarean scar pregnancy and the endometrial line is defined as crossover sign (COS). In this sonographic sign, a straight line was drawn connecting the internal cervical os and the uterine fundus through the endometrium (endometrial line). The gestational sac was identified and its diameter, perpendicular to the endometrial line, was traced. Patients were categorized according to the relationship between the endometrial line and the diameter of the gestational sac into two groups: (1) COS-1, in which the gestational sac was implanted within the cesarean scar, and at least two-thirds of the diameter of the gestational sac was above the endometrial line, toward the anterior uterine wall; and (2) COS-2, in which the gestational sac was implanted within the cesarean scar, and less than two-thirds of the gestational sac was above the endometrial line [21] (Figure 6).

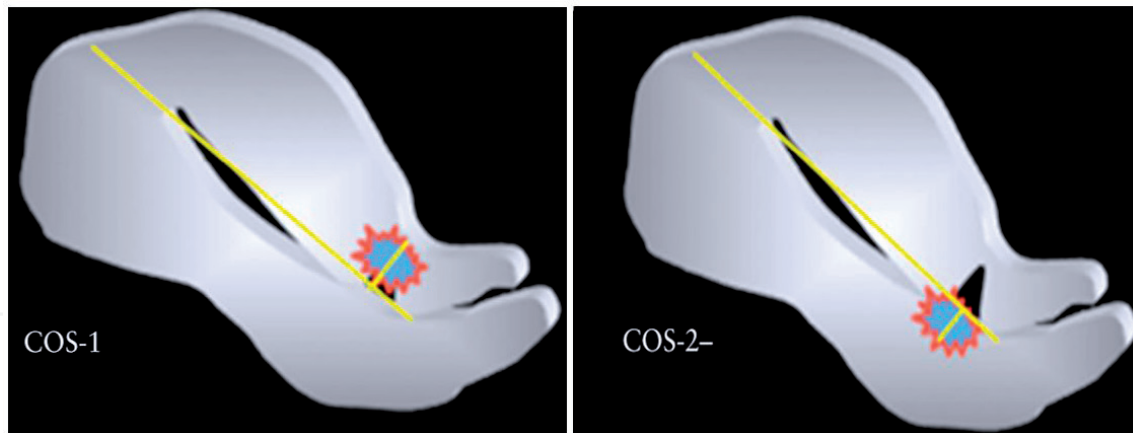


Figure 6. Crossover sign representing COS 1, in which the gestational sac was implanted within the Cesarean scar, and at least two-thirds of the diameter of the gestational sac was above the endometrial line, towards the anterior uterine wall; and COS-2, in which the gestational sac was implanted within the Cesarean scar, and less than two-thirds of the gestational sac was above the endometrial line [21].

This crossover sign may help to determine whether a cesarean scar pregnancy will progress to rupture in the first trimester (COS-1), or in a COS-2 case, the pregnancy could continue running the risk of placenta accreta and cesarean hysterectomy [21].

Approaches are divided into surgical and nonsurgical treatment. Surgical treatment may include uterine curettage or hysterectomy and uterine artery embolization. Nonsurgical treatment may be expectant or medical treatment with systemic or local methotrexate.

There is still no consensus on the best mode of treatment in case of ectopic pregnancy in cesarean scar section.

Surgical intervention is performed in the presence of important bleeding and, under these circumstances, if possible, a uterine artery embolization attempted before curettage or hysterectomy.

Dilatation and curettage with subsequent intrauterine Foley catheter insertion may be an option due to the simplicity. However, the risk of this treatment is the hemorrhage and the necessity of secondary hysterectomy. This treatment should only be used in selected cases.

Excision by hysteroscopy is another option. During the procedure, the pelvic ultrasound could help to avoid complications.

Excision by laparotomy or laparoscopy could be attempted. These procedures usually are performed if local MTX treatment failed or after uterine rupture.

Hysterectomy is usually performed when other treatments failed and to control the bleeding (**Figure 7**). This procedure is not the first line for the majority of gynecologists.

When the patient presents a cesarean scar pregnancy COS-2 or endogenous type and it is a viable pregnancy, the patient should be advised about the risks of continuing with the pregnancy. The late diagnosis of cesarean scar pregnancy evolves to a placenta accreta. The risks of continuing the pregnancy are hemorrhage (13% in first and second trimesters, and 39% in third trimester), uterine rupture (9.9% in first and second trimesters, and 10.2% in third trimester), placenta accreta 75%, and hysterectomy (15.2% in first and second trimesters, and 60.6% in the third trimester) [22]. The physician should discuss these risks and advise the patient. A deep reflection of the situation is required before taking the decision to keep or not the pregnancy, once the couple usually already has one child. When the decision is to continue with the pregnancy, some criteria

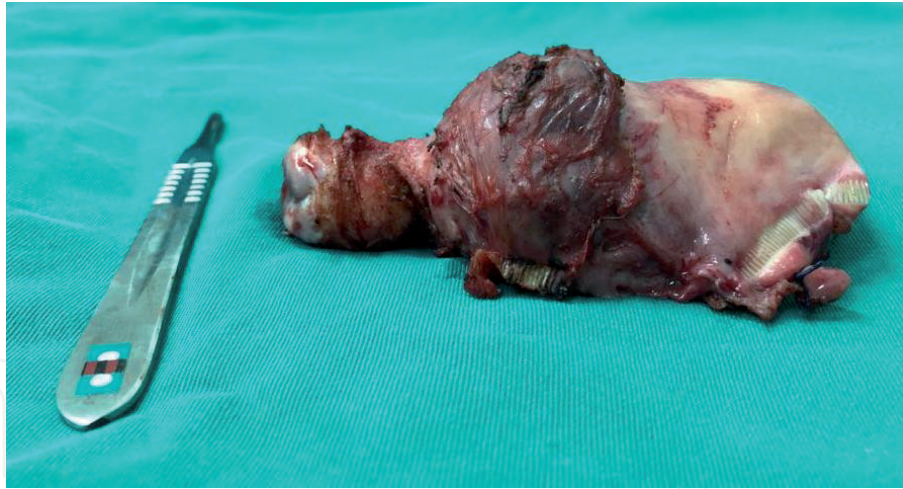

Figure 7.
Case of cesarean scar pregnancy evolved to hemorrhage and the patient was submitted to hysterectomy.

should be evaluated. In cases that have crossover sign (COS-1) or exogenous type and the magnetic resonance shows myometrium less than 5 mm, the pregnancy should be interrupted. In the other situation COS-2 or endogenous type and myometrium thickness > 5 mm, if the patient opts to continue with the pregnancy, they should be advised about the risk of placenta accreta and cesarean hysterectomy and should be assisted in a hospital with interventional radiology and neonatal intensive care.

Systemic methotrexate treatment is not effective in cases where the embryo has heartbeat. This treatment should be avoided in this condition because it delays a more effective treatment.

In cesarean scar pregnancy when the embryo/fetus has heartbeat, local methotrexate (1 mg/kg) treatment guided by transvaginal ultrasound should be the first option [23] (**Figures 8 and 9**). The current scientific evidences demonstrate that local treatment with MTX brings best results. This type of treatment is broadly used because it is not only effective but also simple and low cost.

In cases where the embryo/fetus has no heartbeat, it is important to check the titers of beta-hCG in an interval of 24/48 hours. If the levels were low and declining, the best approach is the expectant management. However, if the titers were high and increasing, the patient should be submitted to the systemic treatment with MTX. If the levels of beta-hCG are low (less than 5.000 mUI/ml), a single dose of MTX 50 mg/m² (same treatment of tubal pregnancy) is recommended. On the other hand, if the levels are higher (>5.000 mUI/ml), a protocol of multiple doses of MTX (1 mg/kg) on days 1, 3, 5, and 7 and folinic acid (0.1 mg/kg) on days 2, 4, 6, and 8 is recommended.

The MTX treatment is an outpatient follow-up with weekly examinations of β -hCG until resolution. During outpatient follow-up, ultrasound is not routinely performed and should only be repeated when β -hCG reaches a negative value 3 months in a row. Other than that the ultrasound should be repeated during the treatment in any case of complication suspected. In general, after 3–6 months, the image of the ectopic pregnancy disappears, and at this point, it is recommended to perform hysterosalpingography and hysteroscopy for a better evaluation of the uterine cavity, as well as appropriate reproductive planning for these patients [1].

In cases where the resolution takes a long period, other treatments could be offered, such as gestational sac aspiration under ultrasound or hysteroscopy to remove the gestational tissue with vascular coagulation of the implantation site.

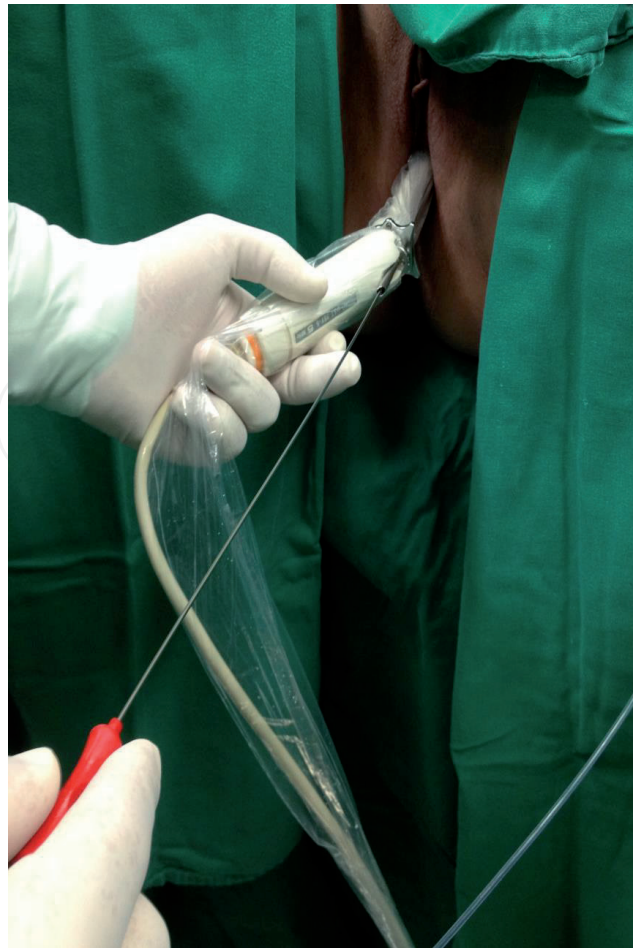

Figure 8.
The patient in the lithotomy position. A 22-gauge, 15 cm Wallace needle was inserted via vaginal route under transvaginal ultrasound guidance.

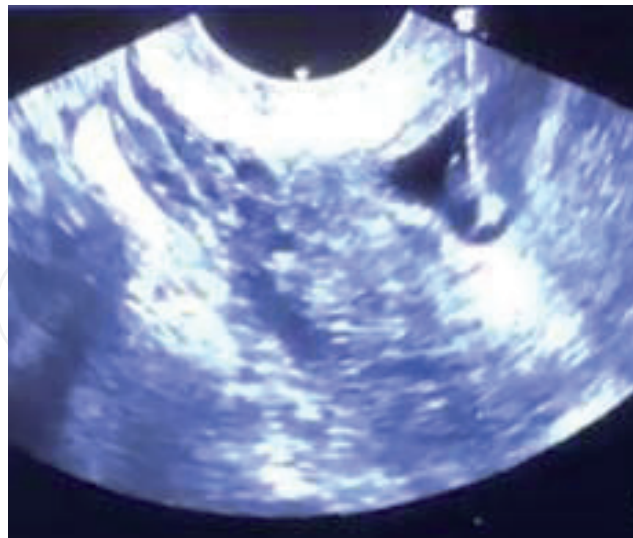

Figure 9.
Wallace needle was inserted via vaginal route into the gestational sac. MTX (1 mg/kg) was injected into the gestational sac.

In cases where local methotrexate treatment fails, uterine artery embolization should be considered [24], or laparoscopic or laparotomic cesarean scar pregnancy wedge resection with subsequent surgical correction of the cesarean section scar.

Birch et al. [25] in a systematic review about treatments for cesarean scar pregnancy showed that uterine artery embolization (UAE) combined with D&C had good results, because it presented a low risk of heavy bleeding and hysterectomy.

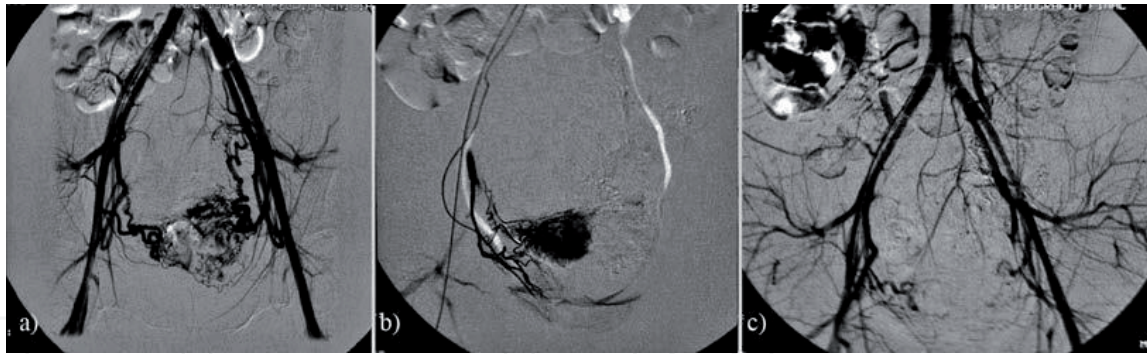


Figure 10. Bilateral uterine angiography before and after uterine artery embolization (a) uterine arteries were enlarged by means of hypervascular perfusion before methotrexate before uterine artery embolization, (b) unilateral occlusion was successfully performed, (c) bilateral arterial occlusion was confirmed after the uterine artery embolization and no extravasation was observed [26].

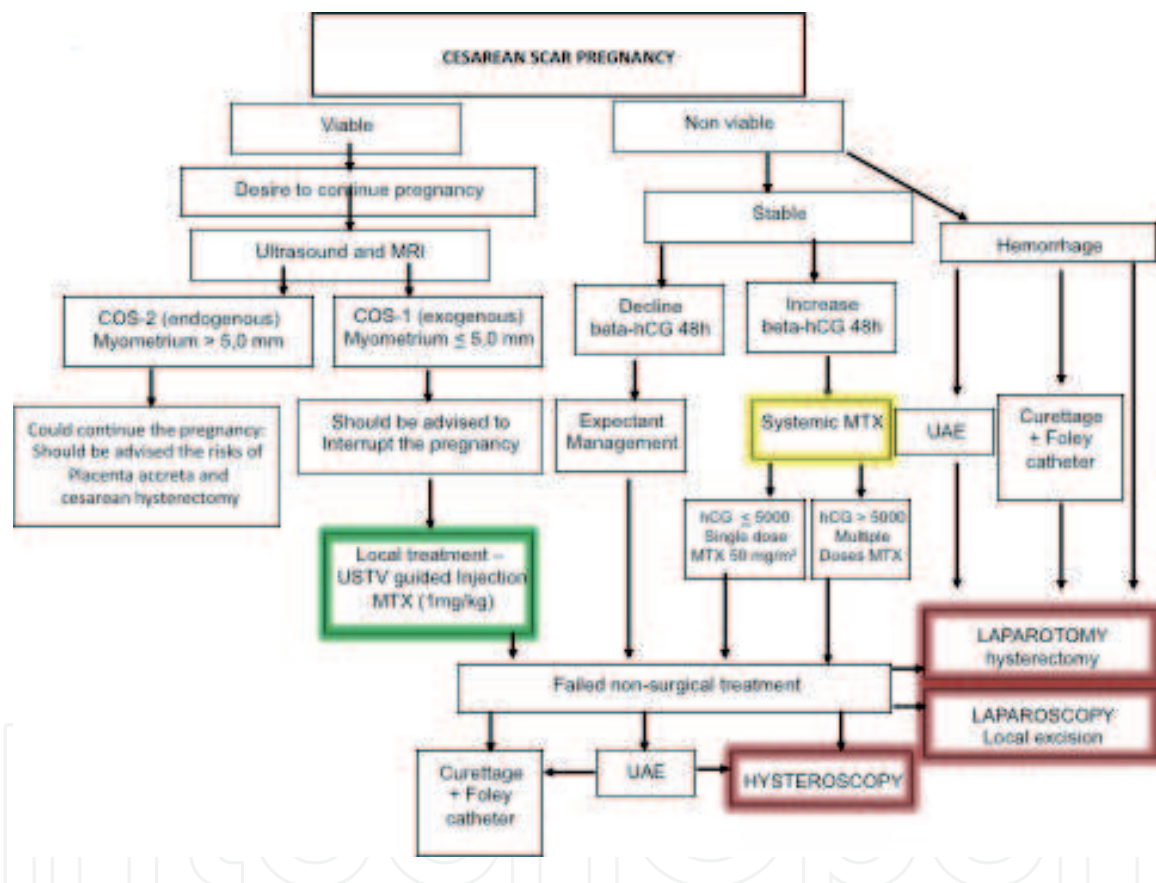


Figure 11. The management protocol of cesarean scar pregnancy.

The UAE procedure can be performed under spinal anesthesia and conscious sedation with standard antibiotic prophylaxis. After asepsis of groin area, the right or left common femoral artery is cannulated via the Seldinger technique, introducer 5F, and the procedure continues such as in the uterine fibroid embolization, with catheterization of the left uterine artery and subsequently the right uterine artery. Methotrexate is injected transarterially prior to the embolization with occluding microparticles, always larger than 500 μ to avoid paradoxical embolization to the ovary [26] (Figure 10). Despite arterial occlusion, the risk of severe bleeding is non-negligible because of gradual restoration of the normal circulation within approximately 3 weeks. The dilation and curettage with suction or vacuum aspiration 6–8 hours after intra-arterial chemoembolization reduce the incidence of bleeding [25].

There is a lack of consensus on the guideline for the treatment of cesarean scar pregnancy and several options of treatment are proposed in the literature (isolated or combined) [27]. Therefore, the author prepared a protocol to manage cesarean scar pregnancy based on his experience and the scientific evidences collected until now (Figure 11).

8. Nonsurgical treatment in non-tubal pregnancies

Management in cases of interstitial, cervical, and cesarean scar pregnancy should always be individualized. Nonsurgical treatment has emerged as an important alternative for these situations, avoiding surgeries that compromise the reproductive future. When the embryo has heartbeat, USTV-guided local treatment with MTX injection into the gestational sac at a dose of 1 mg/kg is the first-line treatment. When beta-hCG titers are greater than 5000 mIU/ml, the local treatment is complemented with the systemic multiple-dose protocol starting the day after puncture. Systemic treatment with MTX is performed in cases where the embryo has no heartbeat. The medical treatment will depend on the initial beta-hCG titer. For titers below 5000 mIU/ml, a single dose of MTX 50 mg/m² IM is recommended. On the other hand, if beta-hCG titers are greater than 5000 mIU/ml, a multiple dose MTX protocol is recommended. The MTX dose is 1 mg/kg IM on days 1, 3, 5, and 7, alternating with folinic acid at the dose of 0.1 mg/kg IM on days 2, 4, 6, and 8 (Figure 12).

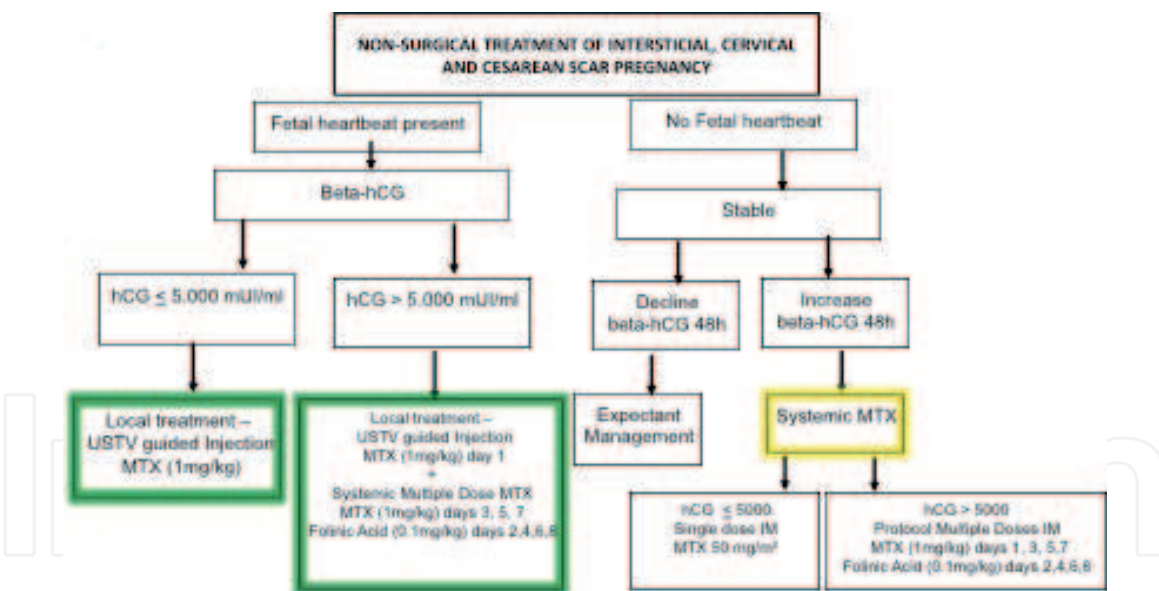


Figure 12. Nonsurgical protocol of non-tubal pregnancy.

9. Final considerations

Non-tubal pregnancy is a challenge for obstetricians due to the maternal morbidity and mortality. The incidence is increasing and the physicians should be aware of this situation. The early diagnosis by ultrasound is essential for a minimal invasive treatment avoiding fertility loss. There are several options for the treatment and no consensus in medical literature. In this introductory chapter, surgical and nonsurgical approaches as well as guidelines have been presented for the treatment of non-tubal pregnancy based on current scientific evidence.

IntechOpen

IntechOpen

Author details

Julio Elito Jr
Federal University of Sao Paulo, Brazil

*Address all correspondence to: elitojrr@hotmail.com

IntechOpen

© 2020 The Author(s). Licensee IntechOpen. This chapter is distributed under the terms of the Creative Commons Attribution License (<http://creativecommons.org/licenses/by/3.0>), which permits unrestricted use, distribution, and reproduction in any medium, provided the original work is properly cited. 

References

- [1] Cecchino GN, Araujo Júnior E, Elito Júnior J. Methotrexate for ectopic pregnancy: When and how. *Archives of Gynecology and Obstetrics*. 2014;**290**(3):417-423
- [2] Shen L, Fu J, Huang W, Zhu H, Wang Q, Yang S, et al. Interventions for non-tubal ectopic pregnancy. *Cochrane Database of Systematic Reviews*. 2014;**7**:CD011174
- [3] Chetty M, Elson J. Treating non-tubal ectopic pregnancy. *Best Practice and Research. Clinical Obstetrics and Gynaecology*. 2009;**23**:529-538
- [4] Comstock C, Huston K, Lee W. The ultrasonographic appearance of ovarian ectopic pregnancies. *Obstetrics and Gynecology*. 2005;**105**(1):42-46
- [5] Phupong V, Terasakul P, Kankaew K. Broad ligament twin pregnancy. A case report. *The Journal of Reproductive Medicine*. 2001;**46**(2):144-146
- [6] Holzhacker S, Elito J Jr, Santana RM, Hisaba W. Advanced intraligamentary abdominal pregnancy—Case Report. *Revista da Associação Médica Brasileira* (1992). 2008;**54**(5):387-389
- [7] Bouyer J, Coste J, Ferrnandez H, et al. Sites of ectopic pregnancy: A 10 year population-based study of 1800 cases. *Human Reproduction*. 2002;**17**:3224-3230
- [8] Centre for Maternal and Child Enquiries (CMACE). 2006-2008 saving mothers' lives. Reviewing maternal deaths to make motherhood safer. *British Journal of Obstetrics and Gynaecology*. 2011;**118**(Suppl 1):1-203
- [9] Martin JJ, Sessums JK, Martin RW. Abdominal pregnancy: Current concepts of management. *Obstetrics and Gynecology*. 1988;**71**:549
- [10] Stevens CA. Malformations and deformations in abdominal pregnancy. *The American Journal of Medicine*. 1993;**47**:1189
- [11] Eddy CA, Pauerstein CJ. Anatomy and physiology of the fallopian tube. *Clinical Obstetrics and Gynecology*. 1980;**23**:1177
- [12] Lau S, Tulandi T. Conservative medical and surgical management of interstitial ectopic pregnancy. *Fertility and Sterility*. 1999;**72**:207-215
- [13] Rock JA, Damarico MA. Ectopic pregnancy. In: Rock JA, Thompson JD, editors. *TeLinde's Operative Gynecology*. 8th ed. Philadelphia, PA, USA: Lippincott-Raven; 1997. pp. 505-520
- [14] Tulandi T, Al-Jaroudi D. Interstitial pregnancy: Results generated from the Society of Reproductive Surgeons Registry. *Obstetrics and Gynecology*. 2004;**103**(1):47-50
- [15] Elito J Jr. Clinical treatment of unruptured ectopic pregnancy. Chapter 11. In: Kamrava M, editor. *Ectopic Pregnancy: Modern Diagnosis and Management*. 1st ed. Croatia: IntechOpen; 2011. pp. 177-208
- [16] Zalel Y, Caspi B, Insler V. Expectant management of interstitial pregnancy. *Ultrasound in Obstetrics and Gynecology*. 1994;**4**(3):238-240. PubMed PMID: 12797190
- [17] Tanaka T, Hayashi H, Kutsuzawa T, Fujimoto S, Ichinoe K. Treatment of interstitial ectopic pregnancy with methotrexate: Report of a successful case. *Fertility and Sterility*. 1982;**37**:851-855
- [18] Júnior JE, Musiello RB, Araujo Júnior E, Souza E, Fava JL, Guerzet EA, et al. Conservative management of cervical pregnancy with embryonic

heart activity by ultrasound-guided local injection: An eight case series. *The Journal of Maternal-Fetal and Neonatal Medicine*. 2014;**27**(13):1378-1381

[19] Larsen JV, Solomon MH. Pregnancy in a uterine scar sacculus—An unusual cause of postabortal haemorrhage. A case report. *The South African Medical Journal*. 1978;**53**(4):142-143

[20] Ash A, Smith A, Maxwell D. Caesarean scar pregnancy. *BJOG: An International Journal of Obstetrics and Gynaecology*. 2007;**114**(3):253-263

[21] Cali G, Forlani F, Timor-Tritsch IE, Palacios-Jaraquemada J, Minneci G, D'Antonio F. Natural history of cesarean scar pregnancy on prenatal ultrasound: The crossover sign. *Ultrasound in Obstetrics and Gynecology*. 2017;**50**(1):100-104

[22] Cali G, Timor-Tritsch IE, Palacios-Jaraquemada J, Monteagudo A, Buca D, Forlani F, et al. Outcome of cesarean scar pregnancy managed expectantly: Systematic review and meta-analysis. *Ultrasound in Obstetrics and Gynecology*. 2018;**51**(2):169-175

[23] Leite F, Fraietta R, Elito J Jr. Local management with methotrexate of cesarean scar ectopic pregnancy with live embryo guided by transvaginal ultrasound: A case report. *Revista da Associacao Medica Brasileira (1992)*. 2016;**62**(2):184-185

[24] Fornazari VA, Szejnfeld D, Elito J Jr, Goldman SM. Interventional radiology and endovascular surgery in the treatment of ectopic pregnancies. *Einstein (Sao Paulo)*. 2015;**13**(1):167-169

[25] Birch Petersen K, Hoffmann E, Rifbjerg Larsen C, Svarre Nielsen H. Cesarean scar pregnancy: A systematic review of treatment studies. *Fertility and Sterility*. 2016;**105**(4):958-967

[26] Elito J Jr, Araujo Júnior E, Martins Santana EF, Szejnfeld D, Helfer TM, Nardoza LM, et al. Uterine artery embolization with methotrexate infusion as treatment for cesarean scar pregnancy. Case report. *Medical Ultrasonography*. 2013;**15**(3):240-243

[27] Timor-Tritsch IE, Monteagudo A, Cali G, D'Antonio F, Agten AK. Cesarean scar pregnancy: Patient counseling and management. *Obstetrics and Gynecology Clinics of North America*. 2019;**46**(4):813-828