

# We are IntechOpen, the world's leading publisher of Open Access books Built by scientists, for scientists

4,800

Open access books available

122,000

International authors and editors

135M

Downloads

Our authors are among the

154

Countries delivered to

TOP 1%

most cited scientists

12.2%

Contributors from top 500 universities



WEB OF SCIENCE™

Selection of our books indexed in the Book Citation Index  
in Web of Science™ Core Collection (BKCI)

Interested in publishing with us?  
Contact [book.department@intechopen.com](mailto:book.department@intechopen.com)

Numbers displayed above are based on latest data collected.

For more information visit [www.intechopen.com](http://www.intechopen.com)



# Orthodontic Management of Cleft Lip and Palate Patients

Geetanjali Sharma

## Abstract

Patients with a cleft palate and or lip often require complex long-term orthodontic treatment, often in combination with a number of other specialists including maxillofacial surgery in order to produce a good facial appearance, with an esthetic, functional and stable occlusion. This chapter will specifically introduce the role of the orthodontic consultant in the management of the cleft lip and palate patient at multiple stages of their dental development and growth. The orthodontic burden of care for these patients is high and the duration of treatment will depend on the diagnosis and pattern of jaw growth and need for orthognathic surgery.

**Keywords:** orthodontist, role, cleft lip, cleft palate, management

## 1. Introduction

The orthodontic burden of care for patients with cleft lip and/or palate is significant as patients will often present with numerous variations and complications in their skeletal, dental and medical/behavioral presentation compared to the non-cleft patient.

### 1.1 Skeletal presentation

There are well established differences in growth patterns and dimensions among cleft patients. The growth and form of the maxillary arch may be affected in the vertical, antero-posterior and transverse dimensions leading to a dental malocclusion as a result of the severity of the initial cleft deformity and the growth response to the primary surgery [1].

*Antero-posterior sagittal problems:* the cleft lip and palate patient will often present with a Skeletal III base owing to maxillary hypoplasia as a consequence of scar tissue which can restrict the growth of the maxilla in the forwards and downwards direction.

*Transverse problems:* a narrow maxilla is a common finding in affected patients owing to a lack of boney development. Scar tissue from previous palate repair can also constrict the growth of the maxilla in the transverse plane.

*Vertical problems:* vertical deficiency is a common finding and can be coupled with an occlusal cant in the palatal plane, excessive freeway space and altered mandibular posture.

## **1.2 Dental presentation**

About 94% of cleft patients have at least one dental anomaly [2] and can present with one or more of the following features:

- congenitally missing teeth especially the upper laterals (50%);
- presence of natal/neonatal teeth;
- presence of supernumerary teeth (20%);
- ectopic eruption or impaction of teeth;
- delayed dental eruption;
- anomalies in tooth morphology, e.g. fused teeth;
- anomalies in tooth size, e.g. microdontia;
- enamel hypoplasia;
- poor oral hygiene leading to caries and periodontal disease;
- posterior and anterior cross bites;
- deep overbite/openbite;
- centerline discrepancies; and
- dentoalveolar disproportion, e.g. crowding/spacing.

## **1.3 Medical/behavioral presentation**

Cleft lip and palate patients may present with numerous behavioral/medical conditions that can influence orthodontic management. Unfavorable behavioral characteristics can lead to poor oral hygiene and co-operation with orthodontic treatment. Medically, patients may also exhibit neuromuscular anomalies, mental retardation, frequent upper respiratory infections and enlarged adenoids/tonsils. Cleft lip and palate patients may also present with associating syndromes. Associating syndromes with autosomal dominant inheritance include Van der Woude syndrome, Apert syndrome, Treacher Collins syndrome, Cleidocranial syndrome, Ectodermal dysplasia, Pierre Robin sequence and Stickler's syndrome. Roberts syndrome, Christian syndrome and Meckel syndrome are also examples of syndromes with autosomal recessive inheritance patterns.

As a consequence of the above, cleft patients are seen multiple times by an orthodontist from a young age to monitor their dental development and jaw growth. The majority of patients will require orthodontic intervention at various stages extending from presurgical nasoalveolar molding as a baby to orthodontic preparation before alveolar bone grafting in the mixed dentition to alignment of the upper arch once the permanent dentition is established. Patients may undergo a second course of orthodontic treatment on cessation of jaw growth to either camouflage an underlying skeletal discrepancy or in preparation for orthognathic surgery.

## 2. Integrated care pathway

Management of the cleft lip and or palate patient is a multi-disciplinary approach involving a number of health care professionals illustrated in **Figure 1**.

All members of the multi-disciplinary team are deemed to be equally important and it is prudent that they all work in tandem with each other to ultimately improve a patient's appearance, speech and function.

The orthodontist is involved in the management pathway at a number of different stages:

### 2.1 Ante/post-natal stage

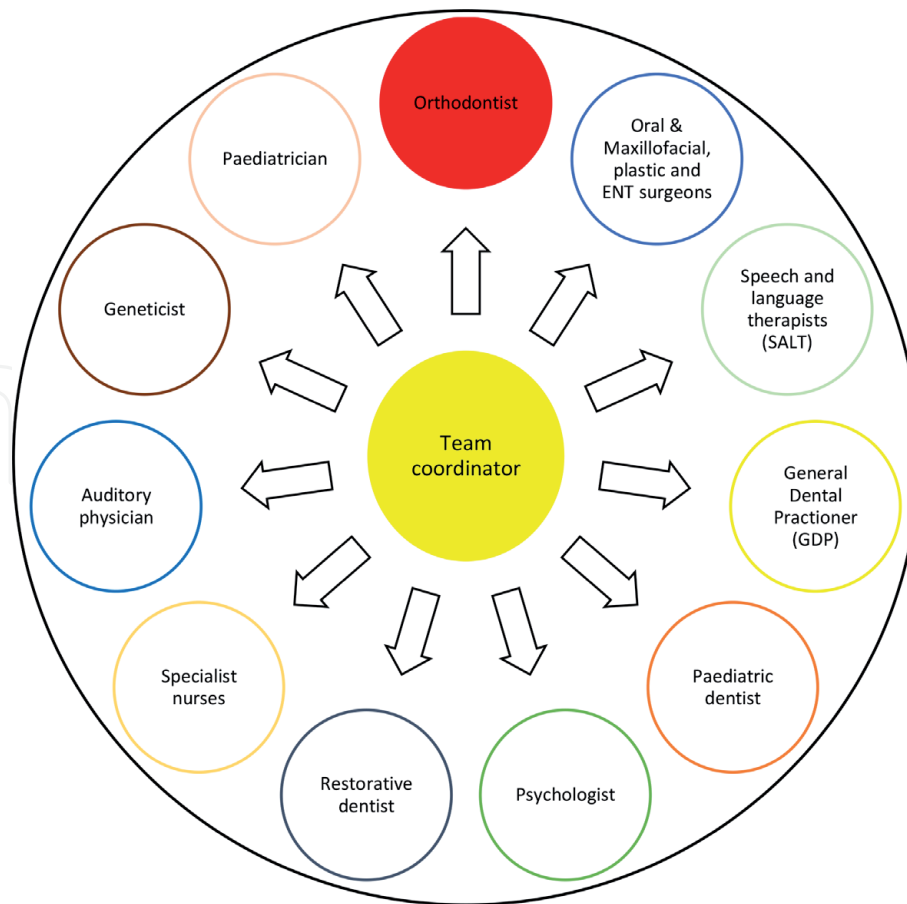
Occasionally, an orthodontist is involved prior to the birth of a baby if a cleft lip and or palate is diagnosed on a 20 week scan. Ultrasonography is a noninvasive diagnostic tool which is widely used. The unexpected finding is a considerable psychological blow to parents and counseling is often necessary. In a district general hospital an orthodontist may be called to counsel the parents on the process and subsequently pass on the details to a hub cleft lip and palate Centre.

Postnatally the orthodontist may be required to continue to provide support and counseling to the parents. Additionally, the orthodontist may be involved in the identification of syndrome related conditions and congenital disorders. Cleft patients may also be born with mobile natal teeth which require assessment and possible extraction.

### 2.2 0–6 months

Between 3 and 6 months lip repair is usually carried out by the cleft surgeon. Prior to lip repair an orthodontist may be involved in a phase of oral orthopedics to align the displaced cleft segments termed presurgical orthopedic treatment. Presurgical orthopedic treatment has been used since 1950. The earlier techniques focused on elastic retraction of the premaxilla using adhesive tape binding. In 1950, McNeil introduced the use of a series of plates to actively approximate the alveolar segments into the desired position which was developed by Burston who popularized the technique [3]. Thereafter, Georgiade and Latham introduced a pin retained active appliance to retract the premaxilla and simultaneously expand the posterior segments over several days [4]. Another example of an active appliance includes the DiBiase plate which uses an active coffin spring. Passive appliances aim to allow the segments to grow without the tongue being in the way. The use of passive orthopedic plates to align the cleft segments was described by Hotz in 1987 in response to controversy associated with active retraction of the premaxilla [5].

Fabrication of molding plates involves taking a heavy bodied silicone impression within the first week of birth. The impression is taken by inserting the impression tray whilst the infant is held upside down. This technique minimizes blockage of the airway by the tongue, impression material and oral fluids [6]. A dental stone model is then fabricated after which, the laboratory technician then obturates the cleft space and blocks out the undercuts with wax. Laboratory technicians may use a variety of methods to construct the molding plates. One technique involves approximating the segments on the model before an active plate is fabricated over this. In the case of a passive appliance the impression is taken and plastered out but the model is not cut prior to fabricating the passive plate over this. The molding plates usually have a minimum thickness of 2 mm, and should be relieved in the region of the frenum, suitably adjusted distally and smooth around the edges. An emergency airway hole of approximately 6 mm in diameter is made on the palatal



**Figure 1.**  
*Illustrative diagram of members involved in the multi-disciplinary management of cleft lip and palate patients.*

surface of the molding plate and positioned 8 mm from the posterior border to assure a patent airway in the instance of plate dislodgement. Retention buttons/ arms are then added and positioned at the junction of the cleft segments and vertically at the junction of where the upper and lower lip rests. Appliances are secured extra orally to the cheeks and bilaterally by surgical tapes. Approximately 100 grams of force can be applied to an active plate through a combination of screws and or elastics that are extended from the retention arms/buttons and stretched approximately two times their resting diameter for an appropriate activation force. Active appliances should be reviewed weekly to modify the acrylic plate and gradually approximate the alveolar segments and reduce the size of the cleft. This is often achieved by removing acrylic resin in areas where alveolar segments are to move and application of soft liner in areas where alveolar bone is to be reduced. Following a few visits, parents are often instructed to place tapes to approximate cleft lip segments to the base of the nose extending from the non-cleft side to the cleft side [7]. It is important to note that lip strapping is seldom done in the UK and only considered for wide bilateral clefts. Objectives include elongation of the columella, expansion of the cleft nasal mucosa and improvement of nasal tip symmetry.

Occasionally, a nasal stent component is incorporated into the plate once the width of the alveolar gap is reduced to around 5 mm. The stent is made up of 0.36 inch round stainless steel wire and adopts the shape of a 'Swan neck'. The stent is attached to the labial flange of the molding plate. It extends forward and then curves backwards entering 3–4 mm past the nostril aperture where the stent is curved back on itself to create a small loop for retention. Hard acrylic is applied to the wire armature followed by soft acrylic to create a bi-lobed structure. In the case

of bilateral cleft lip and palate cases there will be two retention arms and two stents. Following the addition of nasal stents nonsurgical lengthening of the columella can be commenced by introducing a horizontal band of soft denture material which joins the left and right lower lobes of the stents and spans the base of the columella. Tape is then attached to the prolabium under the horizontal lip tape and stretches downward to engage the retention arms with elastics. The vertical pull works in the opposite direction to the upward force applied to the nasal tip by the stent and helps to lengthen the columella [7].

The benefits of presurgical nasoalveolar molding (PNAM) have been debated but Scott's cartilaginous theory and Moss functional matrix theory suggests that by creating a normal functioning environment for normal growth it in turn:

- allows better feeding;
- allows the segments to grow without tension;
- postures the tongue away from the palatal shelves;
- allows the lip and nose repair to heal without pressure;
- facilitates better speech;
- reduces likelihood of choking; and
- yields psychological benefit for the parents.

Reported disadvantages/complications include:

- interference with growth;
- delaying surgery;
- risk of infection;
- occlusion of the airway;
- risk of ulceration/candida infection under a plate; and
- development of skin sores from the tape.

The evidence for PNAM with plates is not conclusive due to limited long term results with some studies indicating that nasoalveolar molding is efficient at reducing cleft width and improving nasal shape and symmetry in uni- and bilateral clefts [8]. A randomized control trial (RCT) which looked at the effects of passive plates on feeding, archform, maternal satisfaction and cost effectiveness found no difference with any of the above [9]. A study by Maserai also found no difference in unilateral cleft lip palate cases [10]. Shaw et al., conducted a RCT and found no effect on feeding and the trial was stopped midway [11]. Most surgeons however, would agree that their chance of achieving a finer surgical scar, good nasal tip projection, and more symmetrical and precisely defined nasolabial complex would be better in an infant who presents with a smaller cleft deformity. Therefore, PNAM can be an adjunct to facilitate surgical repair in infants with cleft lip and palate.

### **2.3 Early mixed dentition**

It is not uncommon for patients to develop a crossbite as the incisors start to erupt. If it is associated with displacement of the lower jaw, tooth wear /fremitus of the opposing dentition than an orthodontist can fabricate a simple upper removable appliance to procline the upper incisors and push them out of an anterior crossbite. Alternatively, a sectional fixed appliance can be used. Care must be taken to ensure that incisors positioned close to the cleft site are not moved out of the alveolar bone as there is typically very thin bone covering these teeth on the cleft side.

If a dental cross bite is not related to a mandibular shift, it is advisable not to perform any palatal expansion at this early stage due to:

- risks of widening a pre-existing oro-nasal communication;
- high risk of relapse due to palatal scarring; and
- long retention period that that will be required which can burn patients compliance and impede oral hygiene.

Patients should be seen on a regular basis, usually on a 6 monthly basis to monitor dental development, continue to motivate the family, reinforce oral hygiene and dietary advice and generate a good relationship and rapport with the patient and family. Orthodontic dental records including radiographs, photos and study models should be taken regularly after the eruption of the upper permanent incisors to detect teeth that may be positioned in the cleft area and to ascertain whether there is congenital absence of the lateral incisor.

### **2.4 Late mixed dentition**

At this stage a patient may require an autogenous alveolar bone graft which offers a number of benefits:

1. additional bone support for unerupted teeth and teeth adjacent to the cleft which will improve their periodontal support;
2. closure of oronasal fistulae;
3. support and elevation of the alar base on the cleft side which will help to achieve nasal and lip symmetry;
4. construction of a continuous arch form and alveolar ridge which in turn will allow the orthodontist to move teeth bodily and upright roots on the cleft side. Additionally, a more continuous archform will enable a prosthodontist/ surgeon to provide a more esthetic and hygienic prosthesis when teeth are missing; and
5. stabilization and or repositioning of the premaxilla in patients with a bilateral cleft.

The timing of a secondary alveolar bone graft largely depends on dental development than chronologic age. This usually takes place prior to the eruption of the upper permanent canine tooth when its root is approximately two-thirds formed.

This generally occurs between 9 and 10 years of age. On rare occasions a graft may be placed at an earlier age to improve the prognosis of a lateral incisor.

Most cleft patients will present with a narrow V-shaped upper archform hence, prior to receiving an alveolar bone graft expansion of the segments that make up the upper archform may be required by the orthodontist to improve access for surgery to allow maximum boney infill. Prior to starting active expansion an upper anterior standard occlusal radiograph, long cone periapical radiograph or CBCT of the cleft site should be considered to assess the volume of bone. There is no universal protocol for maxillary expansion prior to secondary alveolar bone grafting and a number of methods can be used to achieve expansion which include:

1. removable appliances—these can be used to correct an anterior cross bite and simultaneously expand and correct a posterior cross bite but are less popular for cleft patients as removable appliances can impede existing speech problems;
2. rapid maxillary expansion appliances—a number of designs can be used pending the type and amount of expansion that is required. The Hyrax appliance is useful when parallel expansion is required. Fan expansion screws can be used when larger expansion is required anteriorly; and
3. a fixed quad-helix/tri-helix appliance—these appliances provide controlled force application.

The expansion once commenced, should be monitored closely. The cleft surgeon and orthodontist must work in tandem to determine the anatomical limits of presurgical maxillary expansion. This is prudent to avoid overexpansion and development of an oronasal fistula that is beyond the limits of surgical closure. An upper anterior standard occlusal radiograph should be taken and reviewed by the orthodontist and cleft surgeon to assess whether enough expansion has taken place (**Figure 2**). Thereafter, the archform should be maintained with a simple upper removable appliance or trans-palatal arch. It is important to note that any primary teeth in line of the cleft should usually be removed a minimum of 3 months in advance of any planned alveolar bone graft to allow repair of the soft tissues. Supernumerary teeth can be extracted closer to the time of alveolar bone graft.

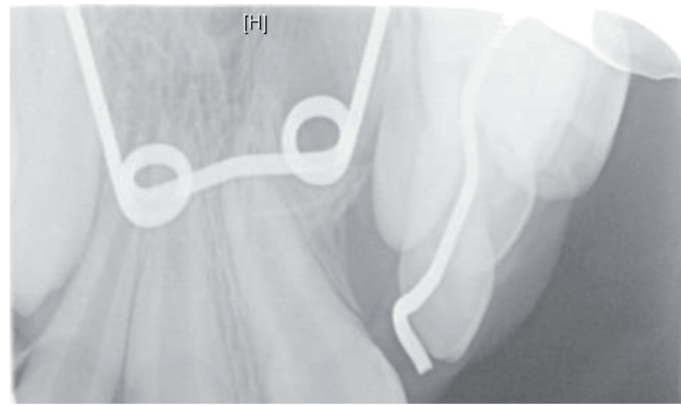
Three to six months post ABG, a postoperative CBCT or upper anterior standard occlusal radiograph should be obtained to confirm the outcome of the surgery which is generally considered satisfactory when sufficient volume of remodeled bone tissue is present. The orthodontist should monitor the developing dentition and eruption of the canine for a minimum of 3–6 months before moving teeth into the new bone.

## 2.5 Early permanent dentition

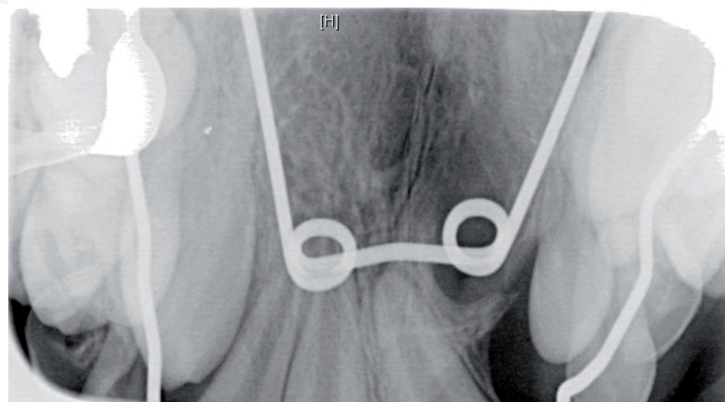
Orthodontic treatment at this stage may be conducted to:

- relieve crowding;
- facilitate the eruption of the canine tooth with or without surgical exposure and bonding of the tooth if it has failed to erupt through the alveolar bone graft after a minimum of 6 months;
- attempt correction of a developing Skeletal III relationship;





(a)



(b)

**Figure 2.**  
*(a) Pre- and (b) post-expansion upper anterior standard occlusal radiographs demonstrating successful expansion prior to a planned alveolar bone graft.*

- align the dentition;
- dental centre-line correction; and
- space closure.

Comprehensive correction of the malocclusion via orthodontic camouflage will be dictated by the extent of the underlying skeletal discrepancy and the likely effect of any future lower jaw growth. In cleft lip and palate patients the mandible is often unaffected and will grow normally, however, growth of the maxilla is often restricted in the forwards and downwards direction compared to the non-cleft patient [12]. Scar tissue from previous hard palate repair is thought to disturb growth of the maxilla leading to a short/hypoplastic maxilla and a Class III malocclusion [13]. Fibrosis can strip the periosteum and also affects antero-posterior, vertical and transverse growth. One option is to consider orthopedic correction during the early mixed dentition at ~7–9 years of age. This treatment option is generally limited to patients with a maximum negative overjet of 4–5 mm [14]. Orthopedic correction of a short maxilla in the cleft lip and palate patient would involve the use of protraction facemask therapy with forces in the range of 300–500 grams per side over 10–12 hours/day. Stability of this treatment is questionable due to counter pressure of a tight lip on the maxilla and scarring in pterygomaxillary region after extensive tissue mobilization for palatal closure. Reported success of this treatment varies with one study reporting an average of only 1.3 mm of maxillary protraction in Class III patients with unilateral cleft lip and palate [15]. Success rates reduce as

the patient ages. Long term results of early protraction appear to be only temporary which often have to be readdressed during late adolescence with retreatment [16]. To that end, if the patient is growing unfavorably and developing a significant class III incisor relationship and skeletal pattern then fixed appliance treatment should also be delayed until the patient has completed their jaw growth to coincide with any planned orthognathic surgery. However, fixed appliance orthodontic treatment can be carried out and limited to the upper arch to relieve crowding, align the dentition, dental center-line correction and or facilitate the eruption of canine teeth whilst lower jaw growth is monitored, and in attempting to achieve the above objectives extraction of a maxillary premolar or lateral incisor on the non-cleft side may be indicated.

## **2.6 Late permanent dentition**

Once the patient reaches adulthood the cleft patient should be reassessed with full diagnostic records. At this stage the outcome of previous orthodontic, hard or soft tissue surgery and speech therapy should be examined. If a cleft patient in the permanent dentition presents with no skeletal deformity then management of the dental malocclusion is not dissimilar from that of a non-cleft patient. For example patients with isolated clefts of the lip and alveolus or clefts of the soft palate may be amenable to fixed orthodontic treatment alone. The dental malocclusion may be limited to mild anterior or posterior crossbites, rotated teeth and missing lateral incisors in the cleft site. Mild crossbites can be managed through archwire expansion/quadrhelix appliance. Where a patient presents with missing lateral incisors a decision needs to be made with a prosthodontist to either close the spacing or redistribute space for a future prosthetic replacement. This decision is usually based on patient wishes, esthetics, position of the molar teeth and dental centerline and financial considerations. If a decision is made to open space, during active orthodontic treatment the space can be maintained with the use of a pontic tooth that contains a bracket and is ligated to the archwire. Once facial growth is complete, a single tooth implant can be placed. If space closure is planned the permanent canine will need recounering on the incisal, labial, mesial, distal and lingual surfaces either during or after active orthodontic treatment. A lateral incisor bracket should be bonded on the canine tooth more gingivally, to bring the gingival margin down and level to the adjacent incisor. Additionally, the first premolar which will adopt the canine position will also need recounering.

Patients presenting with mild skeletal discrepancies, minimal concerns about facial esthetics and no strong family history of mandibular excess can also be treated via orthodontic dental compensation. However, patients should be warned that any correction may be compromised if the patient continues to exhibit mandibular growth.

Most patients will present with a moderate to significant Class III incisor and skeletal relationship due to maxillary hypoplasia however, the need for orthognathic surgery will depend on patient wishes/concerns as well as function and esthetics. Patients who are happy to consider orthognathic treatment should be planned for carefully with an Oral and maxillofacial surgeon or plastic reconstructive surgeon. Timing is crucial. A restorative specialist may be involved to examine the need for implants, crown or bridgework as part of the overall plan as with the cleft patient who is treated via orthodontic camouflage.

Presurgical fixed appliance treatment is carried out by the consultant orthodontist to decompensate the labial segments, level and align the arches and coordinate the dental arches for a stable occlusal outcome. Where multiple segment maxillary

osteotomies are planned bracket positions should be altered for teeth adjacent to the osteotomy site. A careful evaluation of the cleft site should be made prior to presurgical orthodontics. Snap impressions should be taken periodically to assess whether the presurgical aims have been achieved prior to definitive surgical planning with the maxillofacial/cleft surgeons. The severity of the skeletal pattern will dictate whether a patient will only require a maxillary Le Fort I advancement or bimaxillary surgery. It is important that patients undergo special investigations to determine the effects of any maxillary advancement on the patient's speech prior to planned surgery. Where maxillary advancement is expected to exceed 6 mm, bimaxillary surgery may need to be considered to minimize the risk of developing complications related to speech, maintenance of a vascular supply and development of oronasal fistulas [17]. Alternatively, an orthodontist may be required to carry out internal or external distraction osteogenesis to reduce the impact on speech if big surgical movements are deemed necessary in patients with marked maxillary hypoplasia. Since distraction osteogenesis and midface advancement usually takes place at a rate of 1 mm/day, changes in velopharyngeal competence can be monitored during the advancement. Distraction can be carried out with internal distraction devices or via the use of a rigid adjustable external distractor which was described in 1997 by Polley and Figueroa [18]. Compliance with internal distraction devices are better but are limited in their use. External devices allow the clinician to change the vector of skeletal correction during active distraction. The general principles of distraction involve a period of latency of 5–6 days after a Le Fort I osteotomy is performed after which the appliance is activated at the rate of 1 mm/day. The patient should be monitored closely until the desired outcome is achieved. Inter-arch elastics can be incorporated to help direct the correction. Once the desired correction has been achieved with the distraction device a consolidation period of approximately 8 weeks is required to allow bone healing prior to carrying out post distraction orthodontics.

Postoperatively, the orthodontist should see the patient weekly to support the surgical treatment via the use of inter-maxillary elastics and settling archwires. Relapse of the surgical correction is more common in the cleft lip and palate patient and is important to monitor post operatively. Surgical techniques such as over correction, complete mobilization of the maxilla followed by rigid fixation, use of bone grafts and or a tension free advancement can help minimize relapse of the corrected position.

On completion of orthodontic treatment all patients should have a retention regime prescribed and should be reviewed for a prolonged period of time since patients may continue to require revision surgery for their soft tissues, pharyngoplasty and complex restorative treatment including bridge, crown or implant treatment. Scarring from previous cleft palate surgery can affect the stability of the corrected malocclusion therefore, if the patients' oral hygiene permits a fixed retainer may be deemed most appropriate coupled with removable Hawley style retainers to help maintain any transverse expansion and general alignment of the dentition.

In patients that present with associating craniofacial syndromes the general principles of combined orthodontic and orthognathic surgery still apply. These patients can also be intercepted at an early stage for the provision of a functional appliance/distraction osteogenesis.

### **3. Conclusion**

This chapter has focused on the orthodontic aspect of cleft lip palate (CLP) treatment. However, it should be noted that management is multi-disciplinary involving a number of specialists including the oral and maxillofacial surgeons,

cleft surgeons, ENT surgery, restorative and pediatric dentists, plastic surgeons, psychologists and speech therapists, etc. It is important for the orthodontist to communicate well with all these specialists in the management of CLP patients to allow for timely management. Additionally, it is prudent that the parents and patient are motivated for complex and elongated orthodontic management and maintenance of a high standard of dental health throughout treatment.

### **Conflict of interest**

The author declares no conflict of interest.

### **Author details**

Geetanjali Sharma  
Frimley Health NHS Foundation Trust, Wexham Park Hospital, Slough,  
United Kingdom

\*Address all correspondence to: [geetanjali.sharma1@nhs.net](mailto:geetanjali.sharma1@nhs.net)

### **IntechOpen**

© 2019 The Author(s). Licensee IntechOpen. This chapter is distributed under the terms of the Creative Commons Attribution License (<http://creativecommons.org/licenses/by/3.0>), which permits unrestricted use, distribution, and reproduction in any medium, provided the original work is properly cited. 

## References

- [1] Gregory SA, Bryan DT, David MF. Preoperative cleft lip measurements and maxillary growth in patients with unilateral cleft lip and palate. *The Cleft Palate-Craniofacial Journal*. 2016;**53**(6):198-207
- [2] Nicholls W. Dental anomalies in children with cleft lip and palate in Western Australia. *European Journal of Dentistry*. 2016;**10**(2):254
- [3] Burston WR. The early orthodontic treatment of cleft palate conditions. *Dental Practice*. 1958;**9**:41
- [4] Georgiade NG, Latham RA. Maxillary arch alignment in the bilateral cleft lip and palate infant, using pinned coaxial screw appliance. *Plastic and Reconstructive Surgery*. 1975;**56**:52-60
- [5] Hotz M, Perko M, Gnoinski W. Early orthopaedic stabilization of the premaxilla in complete bilateral cleft lip and palate in combination with the Celesnik lip repair. *Scandinavian Journal of Plastic and Reconstructive Surgery and Hand Surgery*. 1987;**21**:45-51
- [6] Loeffelbein DJ, Rau A, Wolff KD. Impression technique for monitoring and virtual treatment planning in nasoalveolar molding. *The British Journal of Oral and Maxillofacial Surgery*. 2013;**51**(8):902-907
- [7] Grayson BH, Maull D. Nasoalveolar molding for infants born with clefts of the lip, alveolus, and palate. *Seminars in Plastic Surgery*. 2005;**19**(4):294-301
- [8] Rau A, Ritschl LM, Mucke T, Wolff KD, Loeffelbein DJ. Nasoalveolar molding in cleft care- experience in 40 patients from a single centre in Germany. *PLoS One*
- [9] Catharina AMB, Anne MK, Martin AV, Birte PA. The effect of infant orthopedics on the occlusion of the deciduous dentition in children with complete unilateral cleft lip and palate (Dutchcleft). *The Cleft Palate-Craniofacial Journal*. 2004;**41**(6):633-641
- [10] Masarei AG, Wade A, Mars M, Sommerlad BC, Sell D. A randomized control trial investigating the effect of presurgical orthopedics on feeding in infants with cleft lip and/or palate. *Cleft Palate-Craniofacial Journal*. 2007;**44**(2):182-193
- [11] Shaw WC, Bannister RP, Roberts CT. Assisted feeding is more reliable for infants with clefts—A randomized trial. *Cleft Palate-Craniofacial Journal*. 1999;**36**(3):262-268
- [12] Vargervik K. Growth characteristics of the premaxilla and orthodontic treatment principles in bilateral cleft lip and palate. *Cleft Palate-Craniofacial Journal*. 1983;**20**:289-302
- [13] Arosarena OA. Cleft lip and palate. *Otolaryngologic Clinics of North America*. 2007;**40**:27-60
- [14] Williams MD, Sarver DM, Sadowsky PL, Bradley E. Combined rapid maxillary expansion and protraction facemask in the treatment of class III malocclusions in growing children: A prospective long-term study. *Seminars in Orthodontics*. 1997;**3**:265-275
- [15] So LL. Effects of reverse headgear treatment on sagittal correction in girls born with unilateral complete cleft lip and cleft palate-skeletal and dental changes. *American Journal of Orthodontics and Dentofacial Orthopedics*. 1996;**109**:140-147
- [16] Tindlund RS. Orthopedic protraction of the midface in the deciduous dentition. Results covering 3 years out of treatment. *Journal*

of Cranio-Maxillo-Facial Surgery.  
1989;17(Suppl 1):17-19

[17] Epker BN, Stella JP, Fish LC.  
Dentofacial deformities associated  
with cleft lip and palate. In: *Dentofacial  
Deformities: Integrated Orthodontic  
and Surgical Correction, III*. 2nd ed. St  
Louis: Mosby; 1998. pp. 1571-1708

[18] Polley JW, Figueroa AA.  
Management of severe maxillary  
deficiency in childhood and adolescence  
through distraction osteogenesis with  
an external, adjustable, rigid distraction  
device. *The Journal of Craniofacial  
Surgery*. 1997;8:181-185

IntechOpen