

Killen Harold Briones Claudett¹⁻³, Mónica H Briones Claudett^{2,3}, Estupiñan Vargas Domenica^{1,2}, Stalin Rodriguez Garcia^{1,2}, Cesar Andrade Cabrera³, Jaime Benites Solis⁴, Michelle Grunauer Andrade^{5,6}

¹Universidad de Guayaquil, Facultad de Ciencias Médicas, Guayaquil, Ecuador

²Centro Fisiológico-Respiratorio Briones-Claudett, Guayaquil, Ecuador

³Intensive Care Unit, Ecuadorian Institute of Social Security, Babahoyo, Ecuador, Juan Anoleto, Babahoyo, Ecuador

⁴OMNIHospital, Abel Castillo Romero y Av. Juan Tanca Marengo, Guayaquil, Ecuador

⁵Universidad San Francisco de Quito, Quito, Ecuador

⁶School of Medicine, Quito, Ecuador

Volume-assured pressure support mode plus pirfenidone as resuscitation therapy in patients with exacerbation of idiopathic pulmonary fibrosis

Abstract

Introduction: Treatment among advanced stage idiopathic pulmonary fibrosis is quite challenging, especially considering that no major evidence has been released about it. This case report demonstrates and discusses the benefit of non-invasive mechanical ventilation in volume-assured pressure support (AVAPS) mode plus pirfenidone based on the relief of a patient's symptoms in combination with high-resolution computed tomography (HRCT) evidence.

Material and methods: An 83-year-old female patient with multiple hospital admissions within a six-month period initially presented with cardiac symptoms which were later attributed to a possible exacerbation of her primary diagnosis, idiopathic pulmonary fibrosis.

Conclusion: The addition of non-invasive mechanical ventilation in AVAPS mode plus pirfenidone can improve the survival rates even in patients with current exacerbations of acute respiratory failure due to idiopathic pulmonary fibrosis.

Key words: pirfenidone, idiopathic pulmonary fibrosis, non-invasive ventilator

Adv Respir Med. 2019; 87: 147–152

Introduction

Idiopathic pulmonary fibrosis (IPF) is the most frequent and devastating form of idiopathic interstitial pneumonias. The average survival time from diagnosis is 3 years. It commonly affects people older than 60. IPF is a chronic fibrotic interstitial lung disease (ILD) characterized by progressive loss of lung function with symptoms including dyspnea and cough [1]. The American Thoracic Society, European Respiratory Society, Japanese Respiratory Society, and Latin American Thoracic Association guidelines indicate that a diagnosis of IPF should be based on: a) Exclusion of other known causes of interstitial lung disease (e.g., domestic and occupational environmental exposures, connective tissue disease,

and drug toxicity); b) Presence of a usual interstitial pneumonia (UIP) pattern on high-resolution CT (HRCT) in patients who have not undergone surgical lung biopsy; and c) Specific combinations of HRCT and surgical lung biopsy pathological patterns in patients who have undergone surgical lung biopsy [2]. The American Thoracic Society defines exacerbation as: a) Previous or concurrent diagnosis of IPF; b) Acute worsening, or development of dyspnea typically < 1-month duration; c) Computed tomography with new bilateral ground-glass opacity and/or consolidation superimposed on a background pattern consistent with a usual interstitial pneumonia pattern; d) Deterioration not fully explained by cardiac failure or fluid overload [3]. Patients with IPF frequently suffer from acute exacerbations, which could

Address for correspondence: Killen Harold Briones Claudett, Universidad de Guayaquil, Facultad de Ciencias Médicas, Guayaquil, Ecuador; e-mail: killen.brionesc@ug.edu.ec

DOI: 10.5603/ARM.2020.0077

Received: 19.05.2019

Copyright © 2019 PTChP

ISSN 2451–4934

be due to single or multiple factors [4]. Pirfenidone was recently found to be effective for a patient with an acute exacerbation of IPF (AE-IPF) [5].

Based on high in-hospital mortality rates, current treatment guidelines state that many patients with respiratory failure due to AE-IPF should not receive mechanical ventilation, mainly because of the aforementioned high mortality rates. There are no studies suggesting that mechanical ventilation (including non-invasive ventilation) might be successful [6–8]. Furthermore, the use of non-invasive mechanical ventilation in these patients has been questioned due to the possibility of futility [9].

We present this case to show that the combination of noninvasive mechanical ventilation in AVAPS mode plus pirfenidone might provide a different perspective towards the clinical approach of ventilatory management for these patients.

Material and methods

An 83-year-old female patient who was transferred from another hospital presented to the emergency department with a 4-week history of productive cough, low production of white expectoration, and marked dyspnea (class III MRC (Medical Research Council) dyspnea scale). The patient was diagnosed with AE-IPF based on the American Thoracic Society guidelines: a) Worsening dyspnea; b) New findings on HRCT, and c) Significantly decreased PaO₂. According to the criteria, these findings should occur within 1 month of one another without any other causative factor (e.g. infection); c) During admis-

sion, the patient was conscious and dyspnea was clearly observed. There was no evidence of cardiac symptoms or possible cardiac involvement and no manifestation of hemodynamic compromise.

IPF had been diagnosed in a tertiary referral hospital approximately 1-year prior to the admission to our hospital. The diagnosis of IPF included a transbronchial biopsy that exhibited characteristic pathological patterns.

Physical examination showed rhythmic heart sounds, hypoventilated lung fields with the presence of bilateral basal crepitations, and a Glasgow score of 15/15. Laboratory tests indicated normal blood count (Leukocytes — 7.87 mm³), normal inflammatory markers (Monocytes — 14.7%, Lymphocytes — 15.1%, Neutrophils — 64.6%, Eosinophils — 3.99%), Hematocrit — 32.6%, Hemoglobin — 10.8 g/dL, Red Blood Cells — 373 mm³, Platelets — 429 mm³, ALT — 35 U/L, AST — 41 U/L, LDH — 246 U/L) and serum creatinine was 0.7 mg/dL.

The HRCT revealed diffuse bilateral pleuropulmonary infiltrations accompanied by areas of fibrosis in the lung bases (Figure 1).

The patient remained under hospital supervision for four days with clinical suspicion of an AE-IPF exacerbation and was discharged after observed improvement.

One week later, the patient returned to the emergency department complaining of cough without expectoration, as well as use of accessory muscles of breathing (especially sternocleidomastoids).

White blood cell count, prior to admission, was as follows: Leukocytes — 9.93 mm³; Neutrophils — 66.8%. CRP value was: 2.0 mg/L.

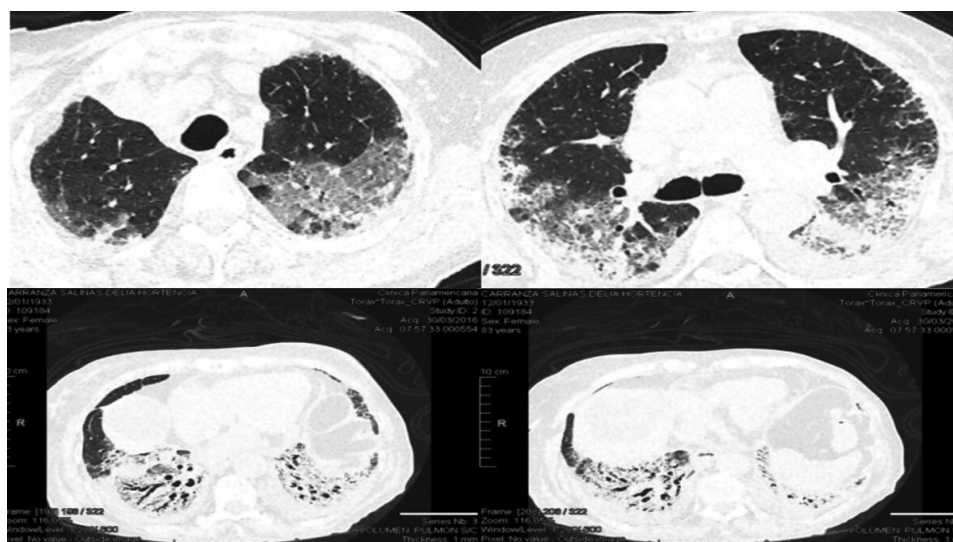


Figure 1. High-resolution computed tomography of the chest on initial presentation. Peripheral ground-glass, traction bronchiectasis. Reticulated opacities were distributed throughout the basal lungs; honeycombing was absent

Blood and sputum cultures, along with molecular investigations for atypical respiratory pathogens remained negative.

After assessment in the emergency department, the patient was admitted to the intensive care unit (ICU). The patient was started on treatment consisting of sodium chloride for hydration, ampicillin-sulbactam, salbutamol, fluticasone, salmeterol, enoxaparin, furosemide, and hydrocortisone 400 mg/day.

The initial arterial blood gas analysis showed: pH — 7.47, PaCO₂ — 33.6 (mm Hg), PaO₂ — 45.2 (mm Hg), HCO₃ — 24 (mmol/L), excess base — 1.9, and SO₂ — 85%.

The Echocardiogram reports showed evidence of preserved global and segmental contractility with an ejection fraction (EF) of 72.8% and an estimated systolic pulmonary artery pressure (PSAP) of 32 mm Hg.

Ventilatory parameters

The ventilatory parameters were initially programmed in the BiPAP S/T-AVAPS (volume-assured pressure support) (AVAPS) Tidal volume programmed AVAPS (ml) 400 mL, levels of IPAP programmed maximum — 14 (cmH₂O).

Levels of IPAP patient — 14 (cmH₂O), levels of EPAP — 8 (cmH₂O), RAMP — 3 (msec), inspiratory time — 1.2 (sec), tidal volume patient — 398 (mL), Vmin — 18 (L/min), leak — 10 (cmH₂O), FiO₂ — 70 (%).

During the fifth day in the ICU, treatment with pirfenidone was administered at 200 mg orally three times daily (600 mg/day). This treatment was based on the IPF diagnosis and was initiated after obtaining informed consent from the patient and her surrogates.

The patient was then transferred at which point she and her relatives decided to establish a “do not resuscitate order”. Through advanced care planning, cardiopulmonary resuscitation

(CPR) and/or invasive mechanical ventilation would not be attempted. However, clinical management was sustained. During the hospitalization, she continued with NIV for 9 days (approximately 20 hours a day) with a high percentage of inspired (FiO₂) 70%, and with the use of a rebreather mask during the rest periods of NIV in AVAPS mode.

The patient presented slight erythema on the nasal bridge due to skin irritation from the facial mask. On day 10, we decided to increase the dose of pirfenidone to 1200 mg/day. On day 12, the patient began to decrease daily use of NIV in AVAPS mode to 18 hours/day, requiring less percentage inspired FiO₂ (65%). On day 16, the dose of pirfenidone was increased to 2400 mg/day and the patient presented with ruddiness of the face along with a sensation of heat as a result of the use of pirfenidone. On day 19, NIV was decreased to 10 hours a day with FiO₂ 50%. On day 24, the use of NIV in AVAPS mode was decreased to 3 hours, twice daily. On day 26 of hospitalization, the patient began to wear a facial oxygen mask at 5 L/min. After 27 days of hospitalization, the patient was finally discharged with an oxygen mask, receiving pirfenidone at the dose of 1200 mg/d.

Follow-up

The patient had consultations throughout the year after her initial presentation in the hospital, and the evaluation showed a marked decrease in patchy opacities. Figure 3 shows a marked decrease in ground-glass opacities at 18 months after treatment with pirfenidone. Forced and slow spirometry maneuvers are shown in Figure 4.

Minute ventilation (VE), peak oxygen consumption (VO₂), and carbon dioxide released (VCO₂) measured breath by breath (Software PistonXP version 1.61 PRE-201 Ergospirometer) (Piston Ltd.'s respiratory diagnostics), and 12-lead ECG (BTL CardioPoint-Ergo E600). Data was continuously recorded. After 3 min of resting

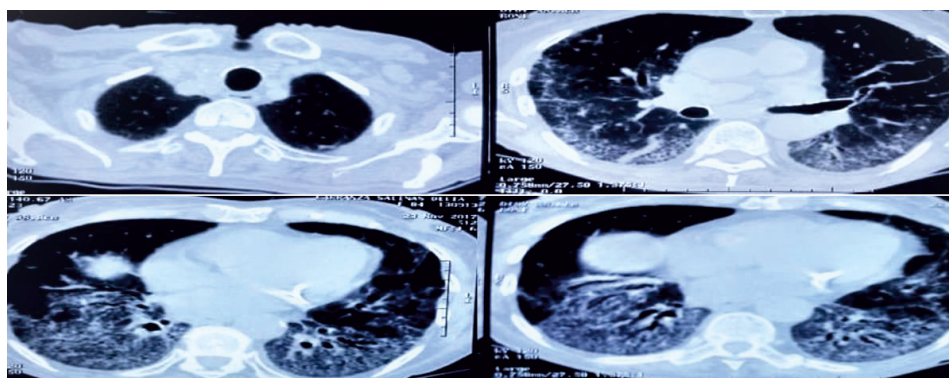


Figure 2. CT notes a notable decrease in opacities in upper lung segments in the axial section

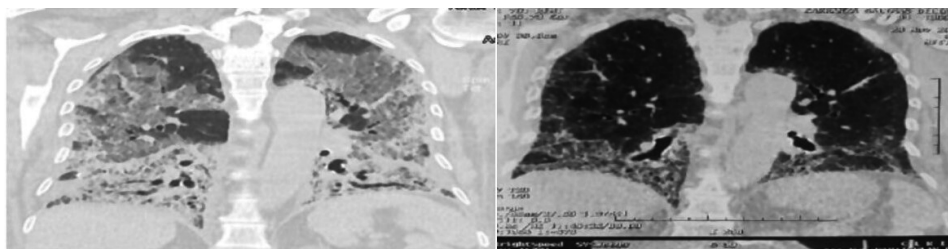


Figure 3. CT note the decrease in opacities in upper lung lobes in the coronal section 18 months after treatment with pirfenidone

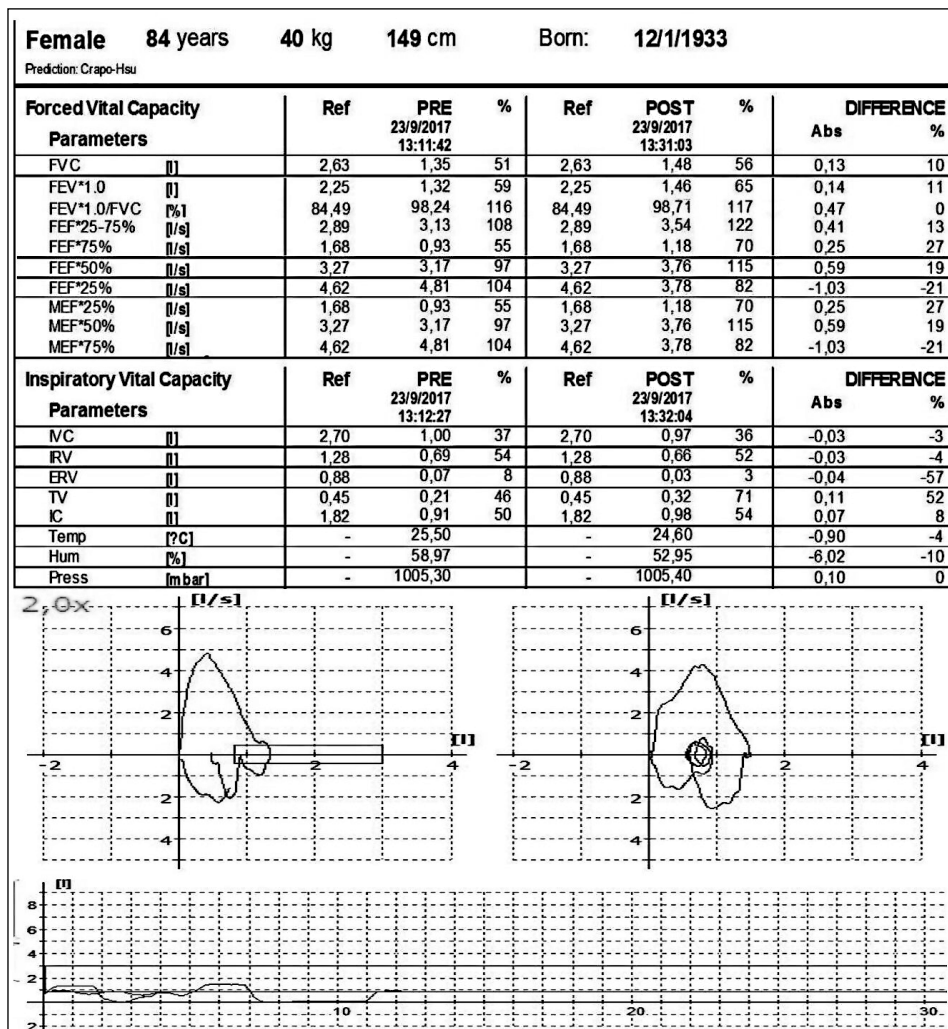


Figure 4. Forced spirometry and slow spirometry maneuvers in which the flow-volume curve shows an ascending branch of rapid rise in expiratory loop with a restrictive pattern and a reduction in inspiratory capacity

and 2 min of warm up, the exercise load was increased every 3 min by 25 watts; as determined for patients with interstitial disease and chronic pulmonary disease. She pedaled at about 50 to 60 revolutions per min. The following data was obtained: VO_2 9.18 ml/kg/min (51% predictor), VCO_2 9.41 ml/kg/min, respiratory exchange ratio (RER) 1.15, Load 50 watts, breaths rate (BR) 47 breath/min, VE 28 (38%), coefficient minute ventilation/ VO_2 production (VE/VO_2) 46.7; coefficient minute

ventilation/ VCO_2 production (VE/VCO_2) 82,5, coefficient VO_2 production/heart rate (VO_2/HR) 8,4 mL/b, coefficient VO_2 production/work rate (WR) 4,70 mL/min/watts, HR maximum 157 heart/min; maximum (Figure 5).

Discussion

IPF is defined as a specific form of chronic, progressive, fibrosing interstitial pneumonia of

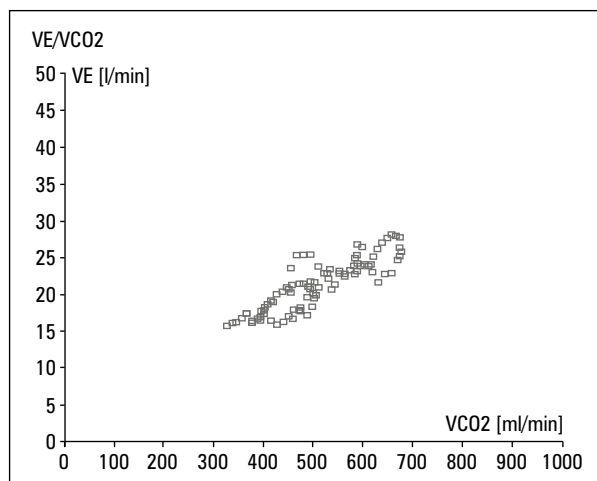


Figure 5. VE/VC₀₂ value during incremental cardiopulmonary exercise testing VE/VC₀₂ (coefficient minute ventilation/VC₀₂ production)

unknown cause. IPF shows the usual interstitial pneumonia (UIP) pattern, pathologically and/or radiologically. Recently, an official ATS, ERS, JRS, and LATA consensus statement (the current IPF guideline) advocated that the presence of characteristic UIP findings (“UIP pattern”) on thin-section CT images is sufficient for diagnosing IPF/UIP without pathologic evaluation by surgical lung biopsy in appropriate clinical settings [1]. Pirfenidone inhibits transforming growth factor- β (TGF- β) and has antifibrotic, anti-inflammatory, and antioxidant effects. Pirfenidone is the first antifibrotic agent that has been approved by the FDA for the treatment of IPF and has recently been found to be effective for a patient with AE-IPF [10].

AE-IPF is defined as any respiratory event characterized by new bilateral ground-glass opacification/consolidation not fully explained by cardiac failure or fluid overload, which parallels the Berlin Criteria for acute respiratory distress syndrome. However, there is difficulty in distinguishing idiopathic from respiratory events triggered by known causes (apart from cases with evident infectious pneumonia); both idiopathic and triggered events (e.g. infection, post-procedural/postoperative, drug toxicity, aspiration) resulting in worsening respiratory symptoms and widespread alveolar damage can be diagnosed as AE-IPF. The difference between AE triggered by infection and pneumonia in terms of therapeutic strategy and prognosis remains unknown.

No treatments have been shown to be effective in the management of acute exacerbations. Patients usually require hospital admission,

supplemental oxygen, and broad-spectrum antibiotics. International treatment guidelines include a weak recommendation for the use of high-dose corticosteroids in the management of patients with AE-IPF, based on very low-quality evidence.

In the case of our patient, she received noninvasive mechanical ventilation (NIV) plus pirfenidone, the latter therapy beginning on the fifth day of hospitalization. These resulted in clinical improvement with a gradual decrease in oxygen requirement (inspired FiO₂) and time of use of NIV. Hence, current IPF guidelines state that while the majority of patients with respiratory failure due to IPF should not receive mechanical ventilation, it may be a reasonable intervention in a minority of patients (weak recommendation, low-quality evidence) and that NIV may be appropriate in some patients [11].

Management of AE-IPF in the ICU may be justified, particularly in patients in whom the possibility of lung transplantation exists and in those who have not yet undergone clinical evaluation for the cause of their respiratory decline [12].

Patients with IPF often present common comorbidities such as pulmonary hypertension [13], obstructive sleep apnea, lung cancer, chronic obstructive pulmonary disease (COPD) / emphysema, ischemic heart disease, and GERD [14], which demand holistic approach in the disease management.

Conclusion

In our case, we facilitated the recovery of a patient with AE-IPF who had marked hypoxemia and ventilatory work, normal blood chemistry and adequate renal function. The patient remained on NIV in AVAPS mode to avoid intubation. Pirfenidone was added at high doses that were achieved progressively and which were well tolerated.

The patient experienced progressive clinical improvement with declining oxygen requirements and NIV time until her hospital discharge at which time she no longer required NIV. Follow-up after one year demonstrated that the patient maintained a reduced lung function with minimal oxygen requirements at home, and her chest CT showed a notable improvement in opacities in upper lung segments in the axial section.

Conflict of interest:

No conflict of interest.

References:

- Ghebre YT, Raghu G. Idiopathic pulmonary fibrosis: novel concepts of proton pump inhibitors as antifibrotic drugs. *Am J Respir Crit Care Med*. 2016; 193(12): 1345–1352, doi: [10.1164/rccm.201512-2316PP](https://doi.org/10.1164/rccm.201512-2316PP), indexed in Pubmed: [27110898](https://pubmed.ncbi.nlm.nih.gov/27110898/).
- Raghu G, Rochweg B, Zhang Y, et al. American Thoracic Society; European Respiratory society; Japanese Respiratory Society; Latin American Thoracic Association. An Official ATS/ERS/JRS/ALAT Clinical Practice Guideline: Treatment of idiopathic pulmonary fibrosis. An update of the 2011 clinical practice guideline. *Am J Respir Crit Care Med*. 2015; 192(2): 13–19.
- Collard HR, Ryerson CJ, Corte TJ, et al. Acute exacerbation of idiopathic pulmonary fibrosis. An international working group report. *Am J Respir Crit Care Med*. 2016; 194(3): 265–275, doi: [10.1164/rccm.201604-0801CI](https://doi.org/10.1164/rccm.201604-0801CI), indexed in Pubmed: [27299520](https://pubmed.ncbi.nlm.nih.gov/27299520/).
- Song JW, Hong SB, Lim CM, et al. Acute exacerbation of idiopathic pulmonary fibrosis: incidence, risk factors and outcome. *Eur Respir J*. 2011; 37(2): 356–363, doi: [10.1183/09031936.00159709](https://doi.org/10.1183/09031936.00159709), indexed in Pubmed: [20595144](https://pubmed.ncbi.nlm.nih.gov/20595144/).
- Tzouveleki A, Ntoliou P, Karamitsakos T, et al. Safety and efficacy of pirfenidone in severe idiopathic pulmonary fibrosis: A real-world observational study. *Pulm Pharmacol Ther*. 2017; 46: 48–53, doi: [10.1016/j.pupt.2017.08.011](https://doi.org/10.1016/j.pupt.2017.08.011), indexed in Pubmed: [28843616](https://pubmed.ncbi.nlm.nih.gov/28843616/).
- Gaudry S, Vincent F, Rabbat A, et al. Invasive mechanical ventilation in patients with fibrosing interstitial pneumonia. *J Thorac Cardiovasc Surg*. 2014; 147(1): 47–53, doi: [10.1016/j.jtcvs.2013.06.039](https://doi.org/10.1016/j.jtcvs.2013.06.039), indexed in Pubmed: [23968871](https://pubmed.ncbi.nlm.nih.gov/23968871/).
- Rush B, Wiskar K, Berger L, et al. The use of mechanical ventilation in patients with idiopathic pulmonary fibrosis in the United States: A nationwide retrospective cohort analysis. *Respir Med*. 2016; 111: 72–76, doi: [10.1016/j.rmed.2015.12.005](https://doi.org/10.1016/j.rmed.2015.12.005), indexed in Pubmed: [26733227](https://pubmed.ncbi.nlm.nih.gov/26733227/).
- Vianello A, Arcaro G, Battistella L, et al. Noninvasive ventilation in the event of acute respiratory failure in patients with idiopathic pulmonary fibrosis. *J Crit Care*. 2014; 29(4): 562–567, doi: [10.1016/j.jcrc.2014.03.019](https://doi.org/10.1016/j.jcrc.2014.03.019), indexed in Pubmed: [24768565](https://pubmed.ncbi.nlm.nih.gov/24768565/).
- Briones Claudett KH. Noninvasive ventilation in the event of acute respiratory failure in patients with idiopathic pulmonary fibrosis: waiting for? *J Crit Care*. 2014; 29(6): 1128, doi: [10.1016/j.jcrc.2014.07.016](https://doi.org/10.1016/j.jcrc.2014.07.016), indexed in Pubmed: [25201432](https://pubmed.ncbi.nlm.nih.gov/25201432/).
- Ohkubo H, Kunii E, Moriyama S, et al. Efficacy of combined corticosteroid and pirfenidone for acute exacerbation of idiopathic pulmonary fibrosis after surgery for lung cancer: a case report. *Respir Investig*. 2015; 53(1): 45–47, doi: [10.1016/j.resinv.2014.09.003](https://doi.org/10.1016/j.resinv.2014.09.003), indexed in Pubmed: [25542603](https://pubmed.ncbi.nlm.nih.gov/25542603/).
- Mallick S. Outcome of patients with idiopathic pulmonary fibrosis (IPF) ventilated in intensive care unit. *Respir Med*. 2008; 102(10): 1355–1359, doi: [10.1016/j.rmed.2008.06.003](https://doi.org/10.1016/j.rmed.2008.06.003), indexed in Pubmed: [18635345](https://pubmed.ncbi.nlm.nih.gov/18635345/).
- Yokoyama T, Kondoh Y, Taniguchi H, et al. Noninvasive ventilation in acute exacerbation of idiopathic pulmonary fibrosis. *Internal Medicine*. 2010; 49(15): 1509–1514, doi: [10.2169/internalmedicine.49.3222](https://doi.org/10.2169/internalmedicine.49.3222).
- Castria D, Refini RM, Bargagli E, et al. Pulmonary hypertension in idiopathic pulmonary fibrosis: prevalence and clinical progress. *Int J Immunopathol Pharmacol*. 2012; 25(3): 681–689, doi: [10.1177/039463201202500314](https://doi.org/10.1177/039463201202500314), indexed in Pubmed: [23058018](https://pubmed.ncbi.nlm.nih.gov/23058018/).
- Raghu G, Amatto VC, Behr J, et al. Comorbidities in idiopathic pulmonary fibrosis patients: a systematic literature review. *Eur Respir J*. 2015; 46(4): 1113–1130, doi: [10.1183/13993003.02316-2014](https://doi.org/10.1183/13993003.02316-2014), indexed in Pubmed: [26424523](https://pubmed.ncbi.nlm.nih.gov/26424523/).