

This is a provisional PDF only. Copyedited and fully formatted version will be made available soon.



ISSN: 0015-5659

e-ISSN: 1644-3284

The effect of N- acetylcysteine on the sensory retina of male albino rats exposed prenatally to cypermethrin

Authors: N. M. Issa, M. A Al-Gholam

DOI: 10.5603/FM.a2020.0043

Article type: ORIGINAL ARTICLES

Submitted: 2020-02-12

Accepted: 2020-03-18

Published online: 2020-04-10

This article has been peer reviewed and published immediately upon acceptance. It is an open access article, which means that it can be downloaded, printed, and distributed freely, provided the work is properly cited.

Articles in "Folia Morphologica" are listed in PubMed.

The effect of N- acetylcysteine on the sensory retina of male albino rats exposed prenatally to cypermethrin

Running title: Effect of N-acetylcysteine on the retina exposed to cypermethrin prenatally

N.M. Issa, M.A. Al-Gholam

Human Anatomy and Embryology, Faculty of Medicine, Menoufia University, Egypt, Menoufia, Shibin Alkoum

Address for correspondence: Marwa Abdel-Samad Al-Gholam (lecturer of Human Anatomy and Embryology Department, Faculty of Medicine, Menoufia University, Egypt, Menoufia, Shibin Alkoum, (002-01025079077) e-mail: marwaelgholam@yahoo.com

Abstract

Cypermethrin (CYP), a pyrethroid that is globally used in the field and house to fight the pests. CYP can induce cellular toxicity and cross the placental barrier. N-acetylcysteine (NAC) can fight the prenatal exposure to the inflammation. This work aimed to study, for the first time, the effects of NAC on the sensory retina of male albino rats exposed prenatally to cypermethrin. Twenty four sexually mature female albino rats and twelve male albino rats were allowed for mating and divided equally into the following groups: Group I (Control Group): kept without treatment. Group II (NAC group): received 1g/kg/day NAC diluted in distilled water orally by gastric tube from the seventh day of gestation till delivery. Group III (CYP group): received 12 mg/kg/day of cypermethrin orally by gastric tube from the seventh day of gestation till delivery. Group IV (CYP and NAC group): received 12 mg/kg/day of cypermethrin and 1g/kg/day of NAC. The ten male offsprings of each group were divided into subgroups (a) and (b) that were sacrificed at the age of 7th and 14th days postnatal respectively. At the end of the experiment, the eye samples were subjected to histological, immunohistochemical and morphometric studies. Concerning the different previous studies, the sensory retina of CYP subgroups showed vacuolation of the inner and outer plexiform layers, dilated congested blood vessels, hyalinization and disorganization of the photoreceptor layer. Also, the expression of collagen IV and caspase 3 (a marker of apoptosis) was up-regulated in the CYP subgroups. NAC significantly protected the sensory retina from the damaging effects of CYP. NAC could be considered as a good protective agent against the damaging effect of CYP on the sensory retina.

Key words: cypermethrin N-acetylcysteine rat sensory retina

INTRODUCTION

Pyrethrins are organic compounds, naturally derived from *Chrysanthemum cinerariifolium* flowers [18]. They have a potent insecticidal activity as their synthetic analogs which are called pyrethroids [19]. Cypermethrin (CYP), a pyrethroid that is globally used in the field and house to fight pests [13]. It is capable to disturb the cellular structure and function of pests [1]. CYP induced cellular toxicity may be due to ROS (reactive oxygen species) that cause destruction of the cellular proteins, lipids and DNA [8]. CYP can cross the placental barrier causing toxic effects on the development of albino rats causing several congenital malformations and fetal death [10]. Cysteine is the basic amino acid for the synthesis of glutathione which combats the oxidative stress and the resultant free radicals by its antioxidant activity [11]. This activity is classified as enzymatic one through the promotion of glutathione peroxidase and reductase enzymes [14]. Besides this, N-acetylcysteine (NAC) has anti-inflammatory properties through inhibition of the cyclooxygenase enzyme together with its products as prostaglandins [6]. And so, NAC can fight the prenatal exposure to the inflammation preventing the occurrence of behavioral and memory alterations on the offsprings [16]. This allows us to study the role of NAC on the retina of prenatally exposed rats to cypermethrin.

MATERIALS AND METHODS

Materials

Cypermethrin: A trade name to an oily solution containing 250 g/L of the active ingredient cypermethrin, it was diluted with distilled water to concentration levels convenient to be used throughout the whole experiment, in which 1 ml of diluted working solution contained 12 mg of cypermethrin.

NAC: A pharmacological preparation (Acetylcistein 600 mg, Effervescent Instant Granules, SEDICO Pharmaceutical Co, 6 October City-Egypt) was diluted with tap water and given to the rats orally.

Animals

Twenty four sexually mature female albino rats and twelve male albino rats, weighing between 200-250 gm were allowed for laboratory rat chow diet and water ad-libitum. Every two female rats were housed overnight with a sexually mature male albino rat for mating; every morning, vaginal smears were taken and microscopically examined for the presence of sperms. The detection of sperms in the smears was considered as the 1st day of gestation. All experimental

procedures were performed with the approval of the Research Ethics Committee, Faculty of Medicine, Menoufia University, Egypt.

Experimental design

The pregnant mothers were divided equally into the following groups:

Group I (Control Group): The pregnant rats were fed ad libitum and allowed free water supply from the seventh day of gestation. Ten male offsprings were divided into subgroup I (a) and I (b) that were sacrificed at the age of 7th and 14th days postnatal respectively.

Group II (NAC group): The pregnant rats received 1g/kg/day of NAC [3] diluted in distilled water orally by gastric tube from the seventh day of gestation till delivery. Ten male offsprings were divided into subgroup II (a) and II (b) that were sacrificed at the age of 7th and 14th days postnatal respectively.

Group III (CYP group): The pregnant rats received 12 mg/kg/day of cypermethrin [7] orally by gastric tube from the seventh day of gestation till delivery. Ten male offsprings were divided into subgroup III (a), and III (b) that were sacrificed at the age of 7th and 14th days postnatal respectively.

Group IV (CYP and NAC group): The pregnant rats received 12 mg/kg/day of cypermethrin and 1g/kg/day of NAC diluted in distilled water orally by gastric tube from the seventh day of gestation till delivery. Ten male offsprings were divided into subgroup IV (a) and IV (b) that were sacrificed at the age of 7th and 14th days postnatal respectively.

At the end of each detected period, the eye samples were removed from each animal. The eye samples were fixed in 10% formol saline and processed to prepare 5 µm-thick paraffin sections for use in the following histological techniques:

Histological study

Hematoxylin and Eosin stain and Toluidine blue stain.

Immunohistochemical study

For detection of the immunoreactivity of collagen IV and caspase 3, the sections were deparaffinized, rehydrated, and after antigen retrieval with 10m mol/l citrate acid solution (pH 6), the specimens were preincubated with goat serum for 5 min and were then incubated overnight at 4°C with anti-collagen IV (Abcam, 6586) and anti caspase 3 (Abcam, 2302) (Working dilution 1:500). The binding was detected using biotinylated secondary antibody (goat anti-mouse IgG; Sigma Aldrich) for 10 min. The specimens were then incubated with streptavidin-peroxidase complex for 5 min, followed

by incubation with 3, 3'-diaminobenzidinetetrahydrochloride (DAB; Sigma Aldrich) for 3 min. Slides were counterstained with hematoxylin and mounted.

Morphometric study

Data were obtained from five different sections from each rat of all subgroups and examined using image J analyzer software, version 1.47 v to determine:

The color intensity in toluidine blue-stained sections

Area % in collagen IV immune-stained sections

The number of positive cells in caspase 3 immune-stained sections.

Statistical analysis [15]

Data obtained from the morphometric study was subjected to statistical analysis using SPSS software version 20 (SPSS, Inc., Chicago, IL, USA). Data were presented as mean \pm standard deviation. Differences among the study groups were detected by using Mann Whitney U test. The results were considered statistically significant with p value < 0.05 .

RESULTS

Histological study

Hematoxylin and eosin (H and E) stain

H and E-stained retinal sections of the control and NAC groups revealed the same histological features of the sensory retina.

The sensory retina of postnatal rats aged 7 days from control mothers (control group) consisted of the photoreceptor layer, 2 nuclear (outer and inner) layers that were separated from each other by the outer plexiform layer. Moreover, the inner nuclear layer was followed internally by the inner plexiform layer then the ganglion cell layer. The nerve fiber layer was followed by the inner limiting membrane with the developing blood vessels.

However, the sensory retina of 7 days old postnatal rats from mothers treated with cypermethrin (CYP group) showed vacuolations of inner and outer plexiform layers. The nuclear layers showed pyknosis of their nuclei, also the blood vessels showed vasodilatations and congestion. On the treatment of the mothers with cypermethrin and N-acetylcysteine (CYP and NAC group), the sensory retina of their 7 days old postnatal offsprings showed preservation of normal development and differentiation, so the retina appeared more or less normal. The sensory retinal layers of postnatal rats aged 14 days from control mothers (control group) appeared more differentiated than that of the age of 7 days (figs. 1).

On the treatment of the mothers with cypermethrin (CYP group), the sensory retina of their 14 days postnatal offsprings showed hyalinization and disorganization of the photoreceptor layer. Also, the vacuolations of the plexiform layers and nuclear pyknosis of the nuclear layers appeared. On the treatment of the mothers with cypermethrin and N-acetylcysteine (CYP and NAC group), the sensory retina of their 14 days old postnatal offsprings showed preservation of normal development and differentiation, so the sensory retina appeared more or less normal (figs. 2).

Toluidine blue stain

The sensory retina of postnatal rats aged (7 and 14) days from control mothers (control group) showed dark blue staining of its neural cells indicating the presence of dense nissl's bodies in their cytoplasm. The CYP sensory retinae showed a significant decrease in the color intensity as compared to that of the control group, while the NAC treated sensory retinae showed a significant increase in the color intensity of the toluidine blue stain as compared to that of CYP group (figs 3 and 4).

Immunohistochemical study

The sensory retina of postnatal rats aged (7 and 14) days from CYP mothers (CYP group) showed significant increase in the percentage of positively reacting area for collagen IV as compared to that of control group, while the NAC treated sensory retinae showed significant decrease in the percentage of positively reacting area for collagen IV as compared to that of CYP group (figs. 5 and 6).

The sensory retina of postnatal rats aged (7 and 14) days from control mothers (control group) showed minimal expression of caspase 3. The CYP sensory retinae (CYP group) showed significant increase in the number of positively immunostaining cells for caspase 3 as compared to that of control group, while the NAC treated sensory retinae (CYP and NAC group) showed significant decrease in the number of positively immunostaining cells for caspase 3 as compared to that of CYP group (figs. 7 and 8).

DISCUSSION

The postnatal exposure to cypermethrin leads to neurodegenerative effects on human and rat [22], so the aim of this work was to study for the first time, the effect of prenatal exposure to cypermethrin on the development of the sensory retina and the possible role of N-acetylcysteine. The sensory retina of 7 days old postnatal rats from mothers treated with cypermethrin (CYP group) showed vacuolations of inner and outer plexiform layers. The nuclear layers showed pyknosis of their nuclei, also the blood vessels showed vasodilatations and congestion. Moreover, the sensory retina of

14 days postnatal rats from mothers treated with cypermethrin showed hyalinization and disorganization of the photoreceptor layer. These degenerative changes were explained by the toxic effect on the retinal blood vessels causing retinal hypoxia. Hypoxia-induced reactive changes in glial cells (responsible for retinal vasculature development), which, in turn, result in an imbalance of pro-angiogenic and anti-angiogenic factors leading to retinal degeneration during vascular development and migration of blood vessels in the neural retina [17]. Massengill et al. explained the retinal degeneration by the occurrence of the inflammation [12]. The inflammation was mediated by the accumulation of cyclic GMP causing the opening of calcium channels in the rod cells and subsequent rod cell death which was followed by the degeneration of other retinal layers [9]. Our results also showed a concomitant significant decrease in the intensity of the toluidine blue-stained retinae (CYP group) as compared to the control group. The reduced intensity was explained by the loss of nissl's bodies (basophilic ribosomal ribonucleic acid substances) as reported by Ajibade et al. [2] which added that neuronal degeneration followed by defective protein synthesis and loss of neuronal function. Our immunohistochemical results showed a significant increase in the expression of collagen IV in the sensory retina of the CYP group as compared to the control group denoting the neovascularization (proliferation and abnormal organization) of retinal blood vessels, as reported by Dorrell et al. [5]. The retinal neovascularization was owed to two factors (hypoperfusion and inflammation), but the inflammatory process might precede the ischemia [21]. The inflammatory cytokines (IL1 β , IL6, IL8 and TNF- α) were claimed to cause endothelial proliferation and pathologic angiogenesis [3]. Also, the sensory retina of the CYP group showed a significant increase in the number of caspase 3 immune-positive cells as compared to that of the control group, this explained that the retinal neuro-degeneration occurred through caspase-dependent apoptotic mechanism stimulated by the oxidative stress [23]. NAC allowed significant protection of the sensory retina of the CYP& NAC group by preventing the neural degeneration and pathological apoptosis with the preservation of its nissl's bodies. Moreover, NAC allowed normal development of retinal blood vessels preventing neovascularization. The protective role of NAC could be explained by acting as a glutathione precursor (cysteine is required for endogenous antioxidant glutathione production), down regulator of the expression of several inflammatory cytokines genes and microglia proliferation inhibitor [20].

CONCLUSIONS

The prenatal exposure of the rats to cypermethrin led to damage to their sensory retina and the use of NAC as a protective agent resulted in the preservation of the normal structure of the sensory retina.

The experiment was conducted at Human Anatomy and Embryology Department, Faculty of Medicine, Menoufia University.

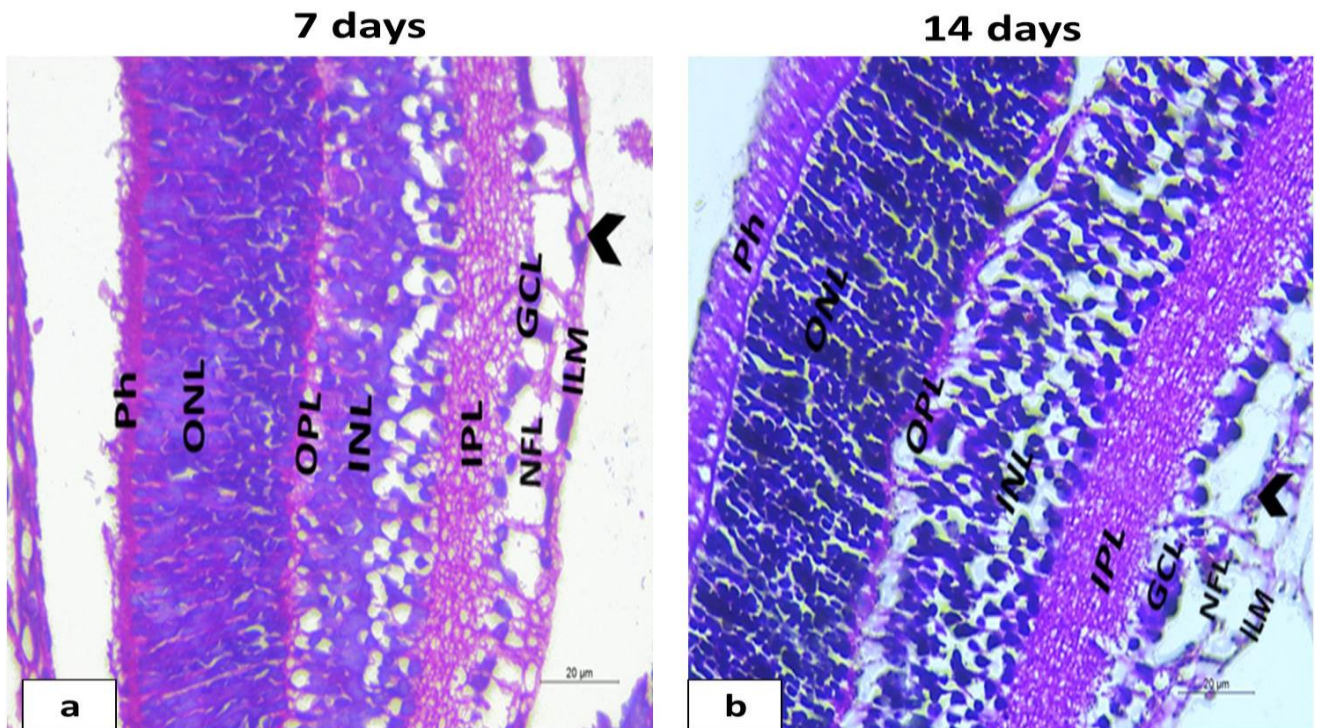


Figure (1): H and E stained sensory retinal sections (X 400) of 7 and 14 days postnatal offsprings of control group: the sensory retina of 7 (a) and 14 (b) days postnatal offsprings of (control) group showing photoreceptor layer (ph), outer nuclear layer (ONL), outer plexiform layer (OPL), inner nuclear (INL), inner plexiform layer (IPL), ganglionic cell layer (GCL), nerve fiber layer (NFL) and inner limiting membrane (ILM). Also, the normal blood vessels (arrowhead) are present on the inner limiting membrane.

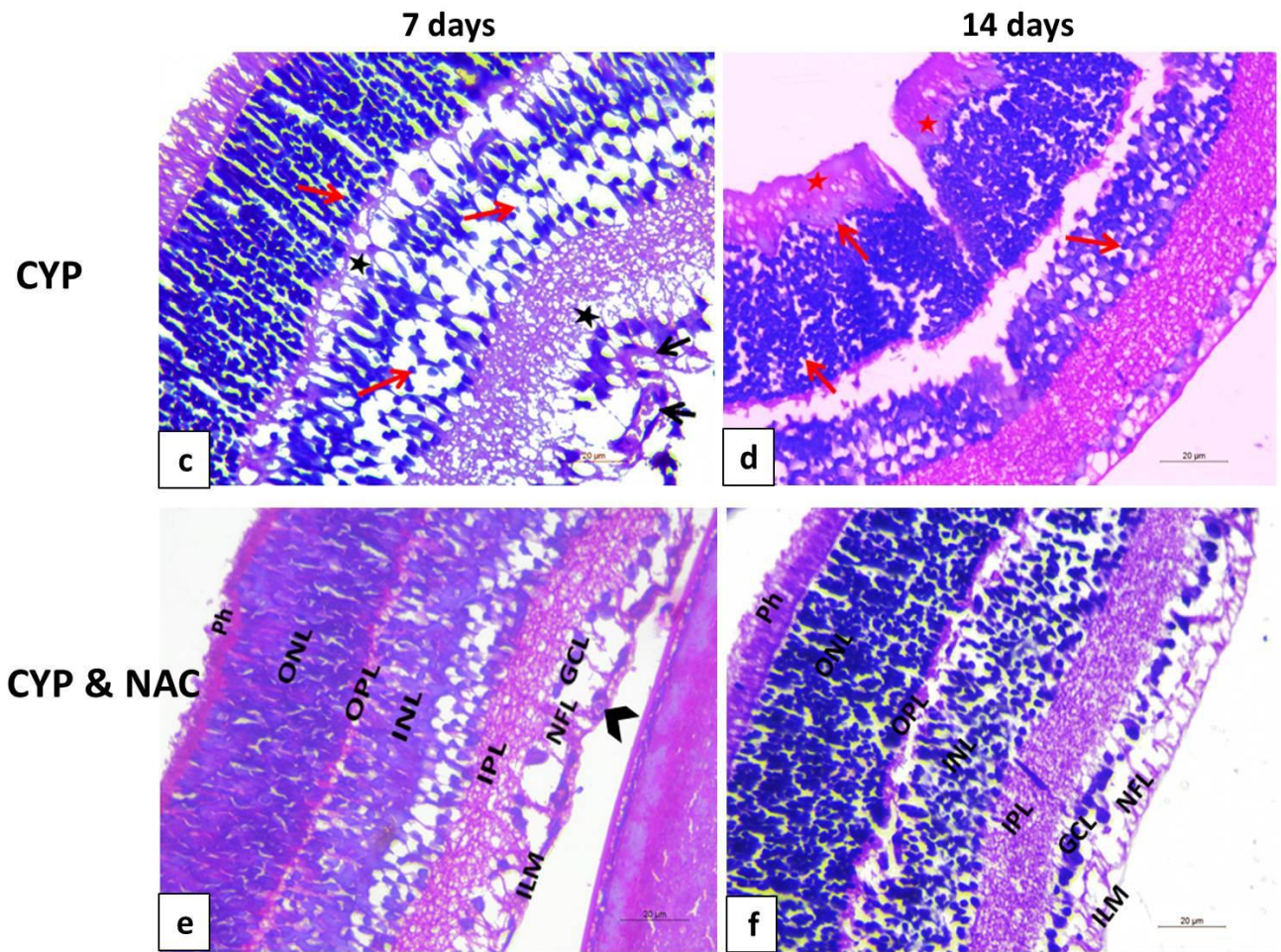


Figure (2): H and E stained sensory retinal sections (X 400) of 7 and 14 days postnatal offsprings of (CYP) and (CYP and NAC) groups. (c and d): sensory retina of 7 and 14 days postnatal offsprings of (CYP) group showing vacuolations (black star) of plexiform layers, pyknosis (red arrow) of nuclear layers, vasodilatation and congestion of the blood vessels (black arrow). Moreover, hyalinization and disorganization (red star) are present in the photoreceptor layer. **(e and f):** sensory retina of 7 and 14 days postnatal offsprings of (CYP and NAC) group showing preservation of normal development and differentiation.

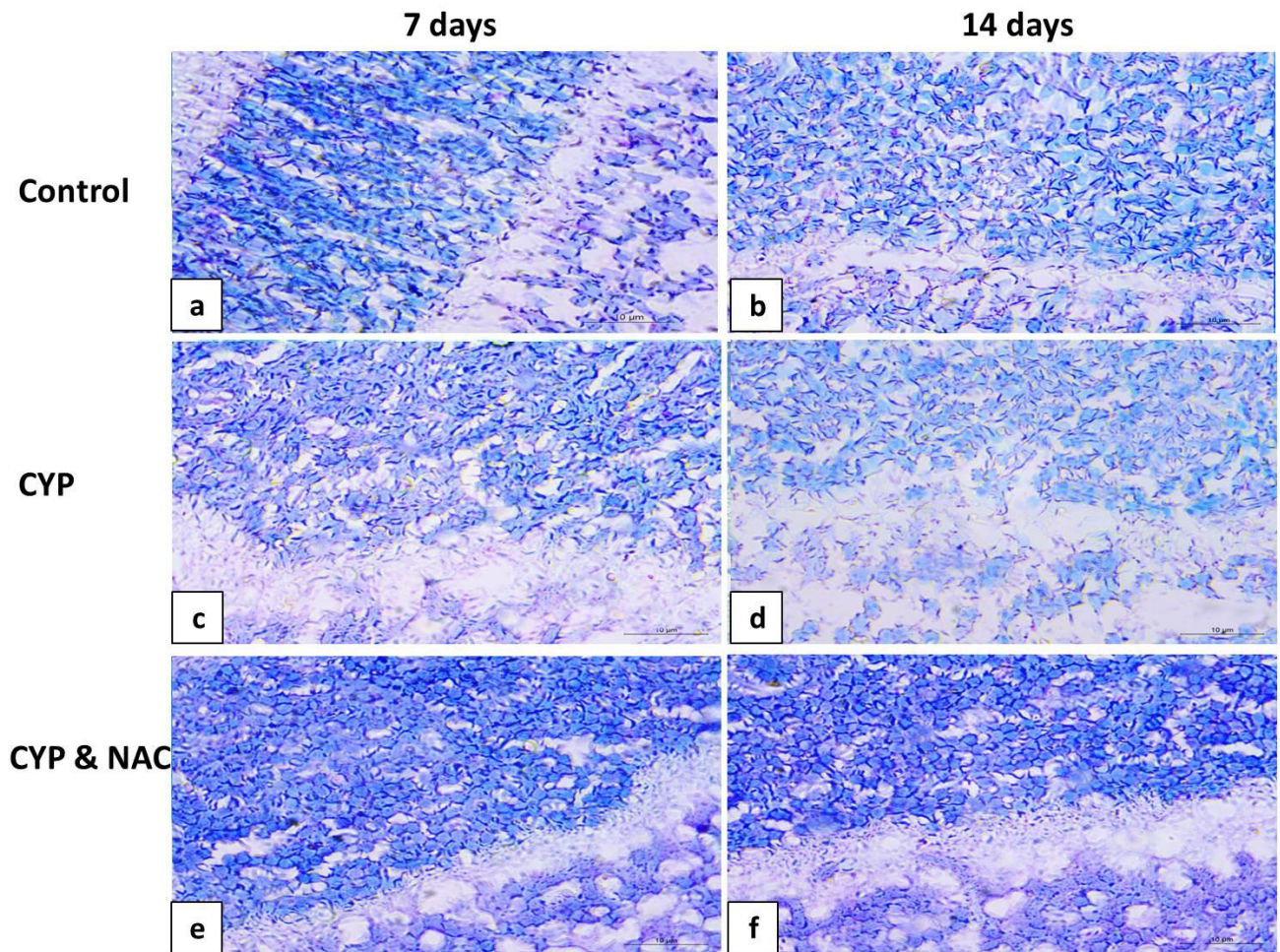


Figure (3): Representative toluidine blue-stained sensory retina (x1000) of all experimental groups: (a and b): dark blue staining of nissl's bodies in retinal neural cells of (control) group, (c and d): significant decrease ([#]P value) in color intensity of the sections of (CYP) group as compared to (control) group, (e and f): significant increase (^{*}P value) in color intensity of the sections of (CYP and NAC) group as compared to (CYP) group.

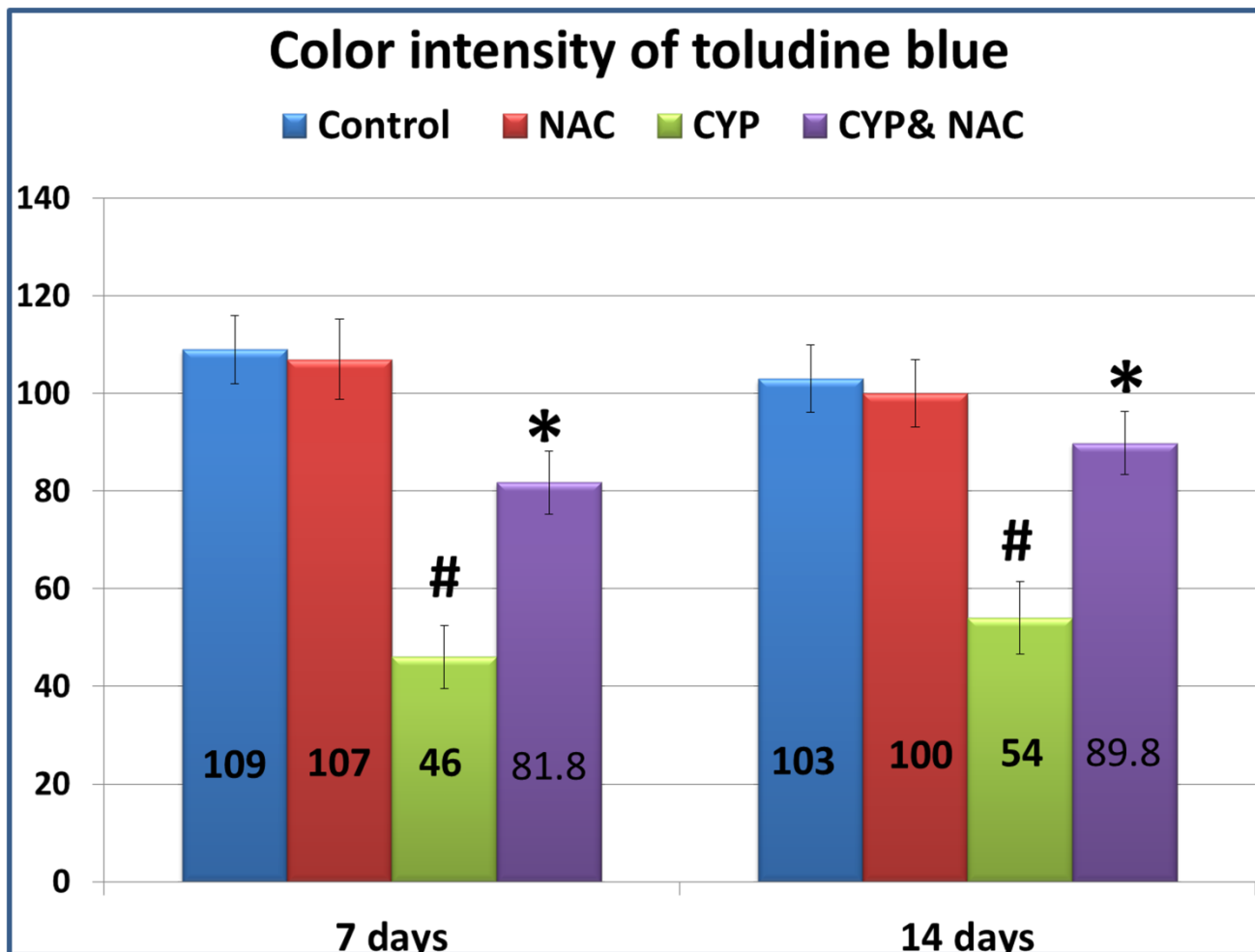


Figure (4): Regarding the color intensity of toluidine blue staining, the CYP group showing a significant decrease ($^{\#}P$ value < 0.05) as compared to the control group while the CYP and NAC group showing a significant increase (*P value < 0.05) as compared to CYP group.

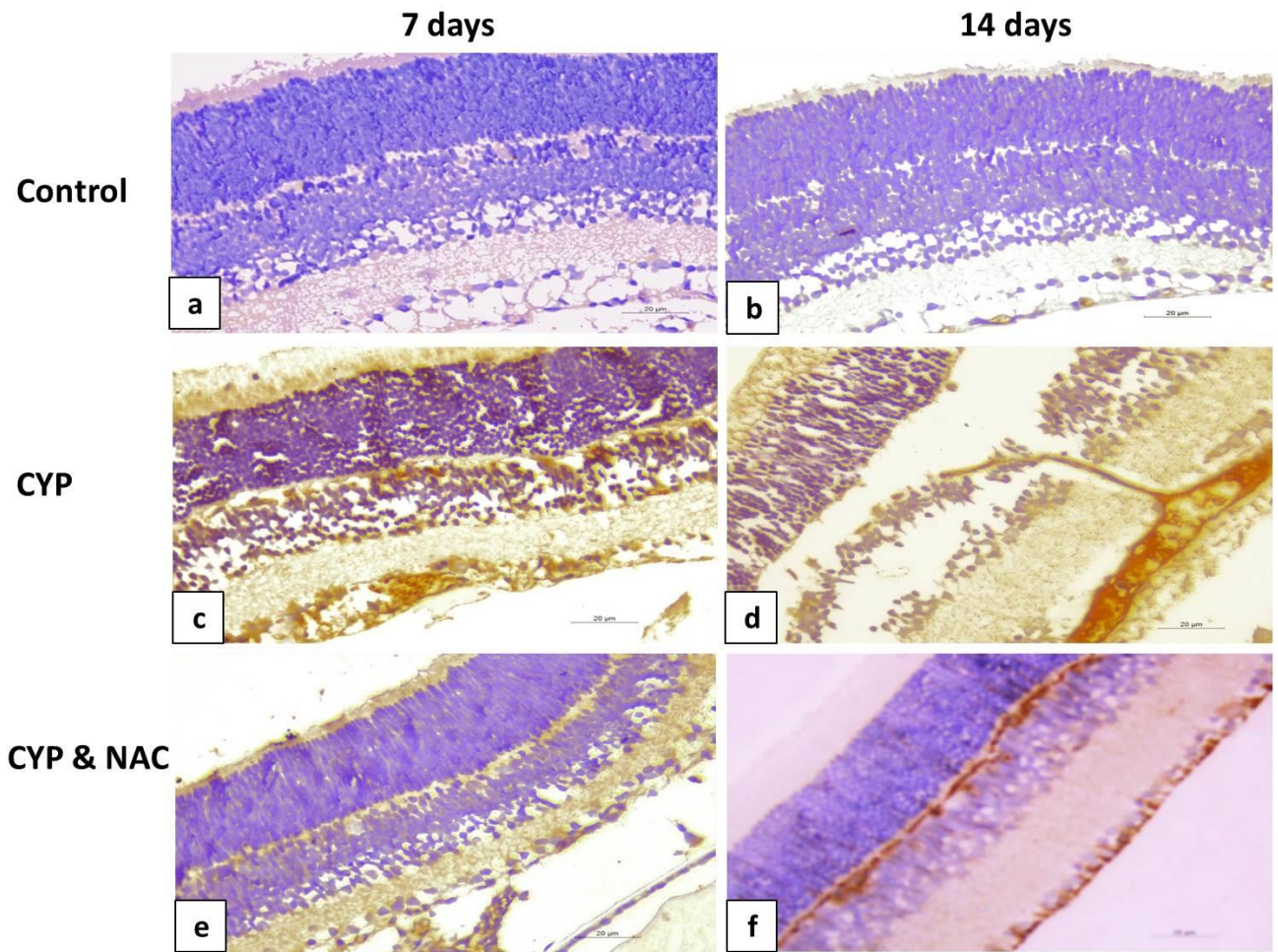


Figure (5): Representative collagen IV immunostained sensory retina (x400) of all experimental groups: (a and b): normal expression of collagen IV in retinal blood vessels of (control) group, (c and d): significant up-regulation (#P value) in percentage of collagen IV immunoreacting area in retinae of (CYP) group as compared to those of (control) group, (e and f): significant down-regulation (*P value) in percentage of collagen IV immunoreacting area in retinae of (CYP and NAC) group as compared to (CYP) group.

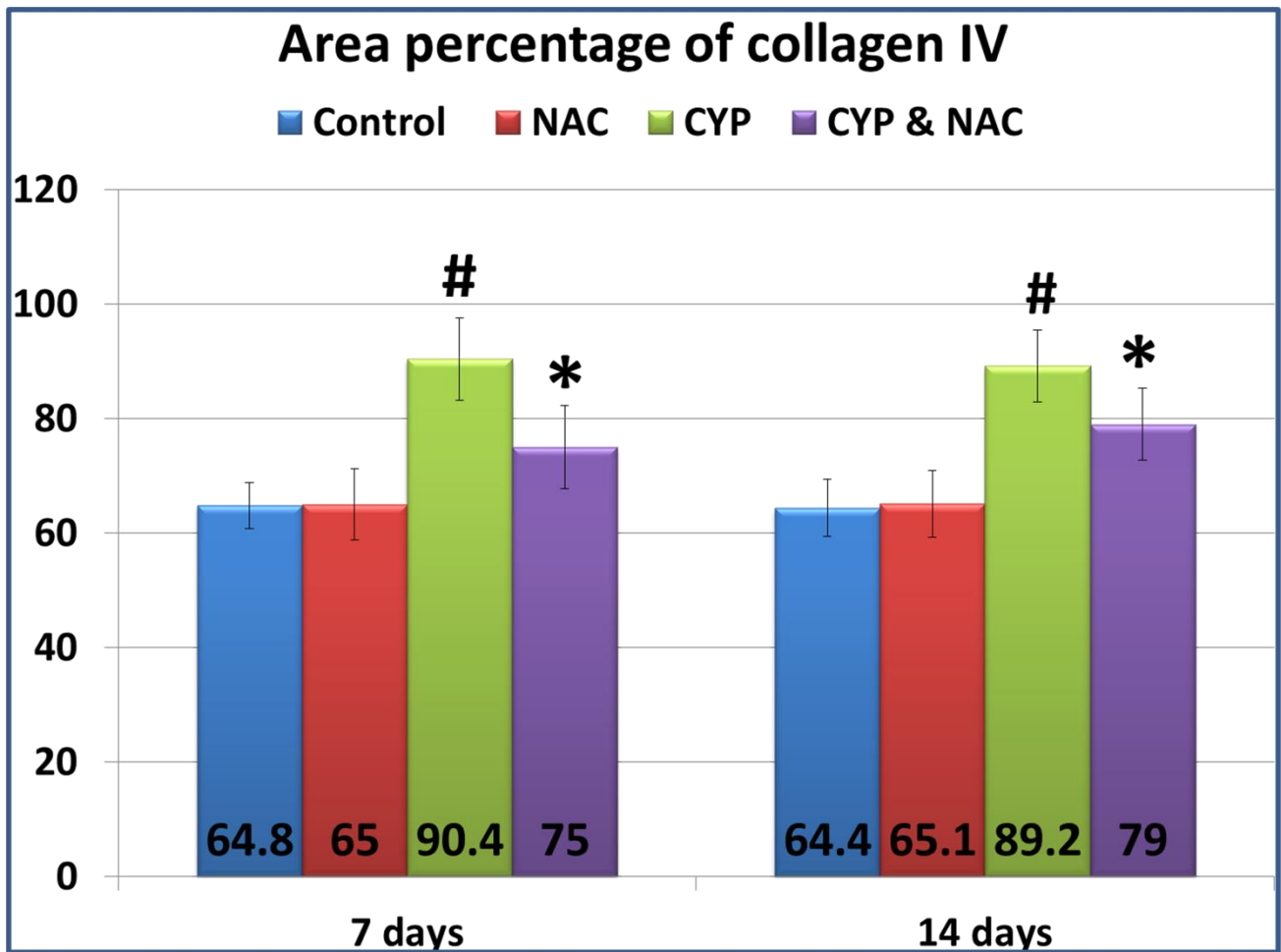


Figure (6): Regarding the expression of collagen IV immunostaining, the CYP group showing a significant increase ([#]P value < 0.05) as compared to the control group while the CYP and NAC group showing a significant decrease (^{*}P value < 0.05) as compared to (CYP) group.

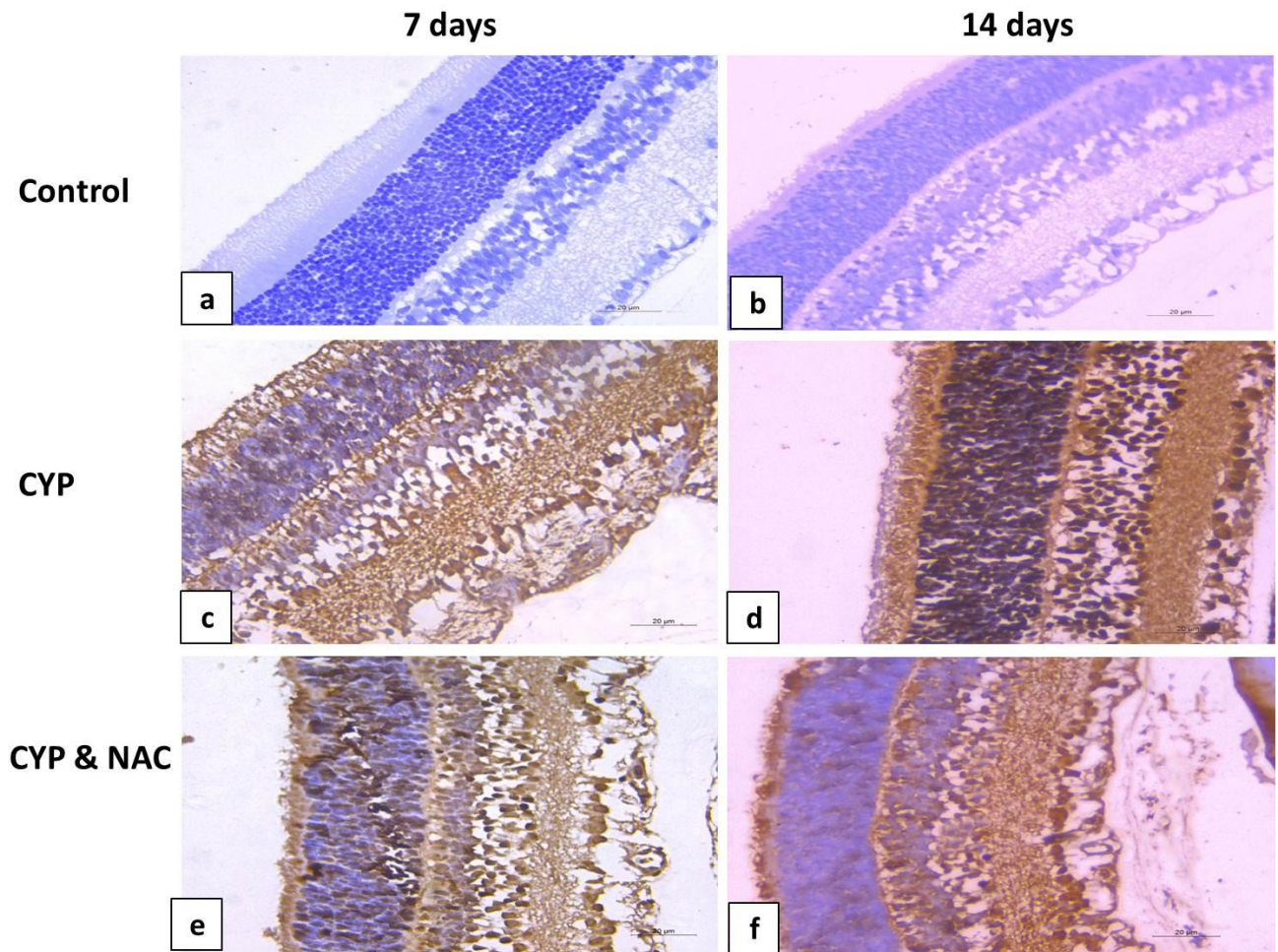


Figure (7): Representative caspase 3 immunostained sensory retina (x400) of all experimental groups: The retinae of (control) group showing negative (a) and minimal (b) expression of caspase 3, (c and d): significant increase (#P value) in number of caspase 3 immunopositive cells in retinae of (CYP) group as compared to those of (control) group, (e and f): significant decrease (*P value) in number of caspase 3 immunopositive cells in retinae of (CYP and NAC) group as compared to those of (CYP) group.

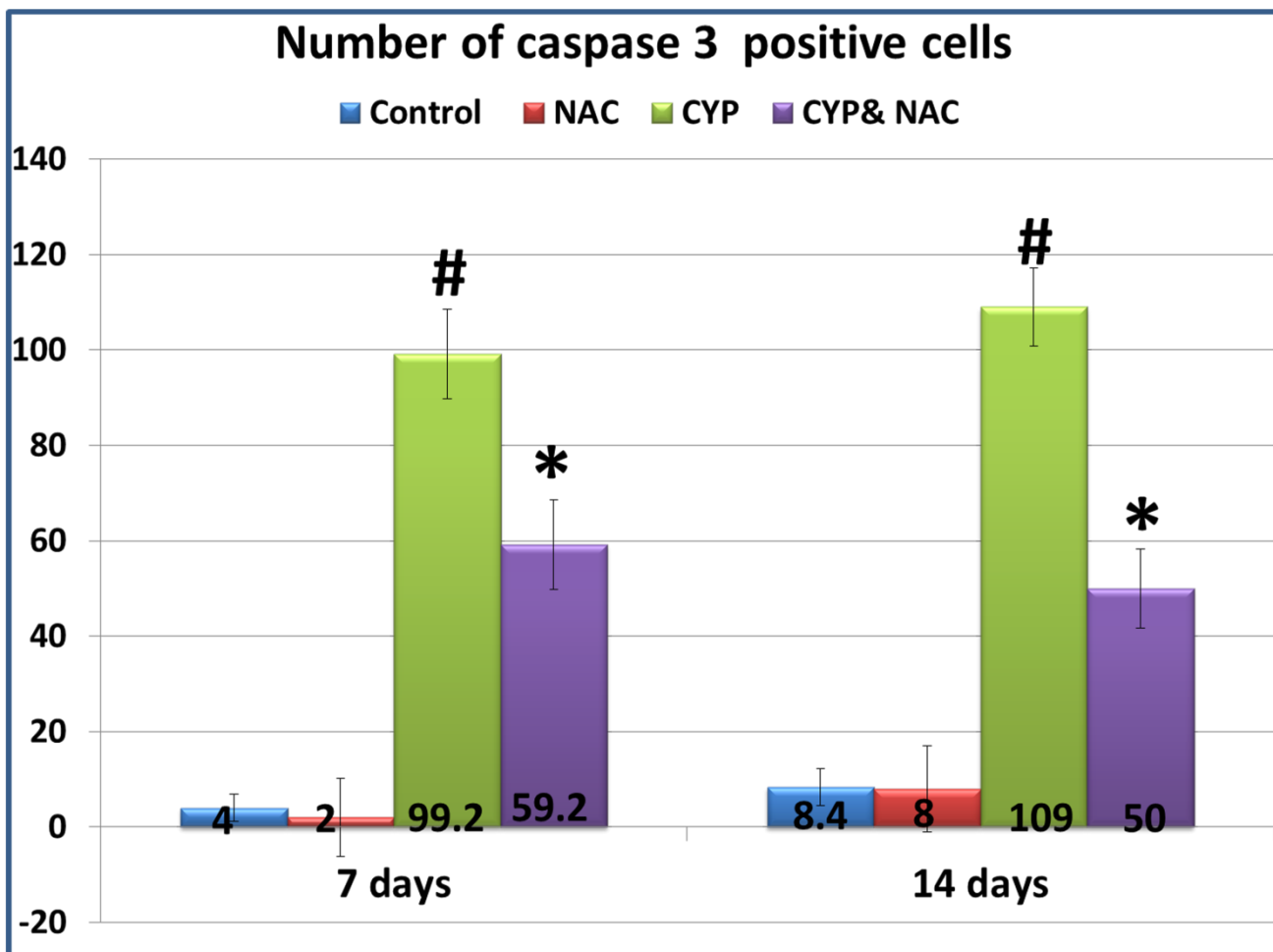


Figure (8): Regarding the expression of caspase 3 immunostaining, the CYP group showing a significant increase ([#]P value < 0.05) as compared to the control group however, the CYP and NAC group showing downregulation of caspase 3 expression (^{*}P value < 0.05) compared to CYP group.

References

- 1- Abdul-Hamid, M.; Moustafa, N.; Asran, A.A. and Mowafy, L. (2017): Cypermethrin-induced histopathological, ultrastructural and biochemical changes in liver of albino rats: The protective role of propolis and curcumin. Beni-Suef Univ. J. Basic Appl. Sci.; 6: 160–173.
- 2- Ajibade, A.J.; Adenowo, T.K.; Fegemilehin, M.E.; Caxton-Martins, E.A. and Omotoso, E.O. (2006): Some histological observations on the cerebellar cortex of adult Wistar rats following quinine administration. Sci. Focus; 11 (2): 97-100.
- 3- Berry, A.; Bellisario, V.; Panetta, P.; Ragi, C.; Magnifico, M.C.; Arese, M.; Cirulli, F. (2018): Administration of the Antioxidant N-Acetyl-Cysteine in Pregnant Mice Has Long-Term

- Positive Effects on Metabolic and Behavioral Endpoints of Male and Female Offspring Prenatally Exposed to a High-Fat Diet. *Front Behav Neurosci.*; 12:48.
- 4- Curnow, S.J. and Murray, P.I. (2006): Inflammatory mediators of uveitis: Cytokines and chemokines. *Curr Opin Ophthalmol.*; 17(6):532–7.
 - 5- Dorrell, M.I.; Aguilar, E. and Friedlander, M. (2002): Retinal vascular development is mediated by endothelial filopodia, a preexisting astrocytic template and specific R-cadherin adhesion. *Invest Ophthalmol Vis Sci.*; 43:3500–10.
 - 6- Farshid, A.A.; Tamaddonfard, E.; Yahyae, F. (2010): Effects of histidine and N-acetylcysteine on diclofenac-induced anti-inflammatory response in acute inflammation in rats. *Indian J Exp Biol.*; 48(11):1136–1142.
 - 7- Huang, C.; Li X. (2014): Maternal cypermethrin exposure during the perinatal period impairs testicular development in C57BL male offspring. *PLoS One*; 9(5):e96781.
 - 8- Huang, F.; Liu, Q.; Xie, S.; Xu, J.; Huang, B.; Wu, Y. and Xia, D. (2016): Cypermethrin induces macrophages death through cell cycle arrest and oxidative stressmediated JNK/ERK signaling regulated apoptosis. *Int. J. Mol. Sci.*; 17: 885.
 - 9- Luodan, A.; Zou, T.; He, J.; Chen, X.; Sun, D.; Fan, X. and Xu, H. (2019): Rescue of Retinal Degeneration in rd1 Mice by Intravitreally Injected Metformin. *Front. Mol. Neurosci.*; 12:102.
 - 10- Madu, E.P. (2015): Teratogenic and embryotoxic effects of orally administered cypermethrin in pregnant albino rats. *Journal of Toxicology and Environmental Health Sciences*; 7(7): 60-67.
 - 11- Massaad, C. A. and Klann, E. (2011): Reactive oxygen species in the regulation of synaptic plasticity and memory. *Antioxid. Redox Signal.*; 14 (10): 2013–54.
 - 12- Massengill, M. T.; Ahmed, C.; Lewin, A. S. and Ildefonso, C. J. (2018): Neuroinflammation in retinitis pigmentosa, diabetic retinopathy, and age-related macular degeneration: a minireview. *Adv. Exp. Med. Biol.*; 1074: 185–191.
 - 13- Molavi, M.; Razi, M.; Cheraghi, H.; Khorramjouy, M.; Ostadi, A. and Gholirad, S. (2016): Protective effect of vitamin E on cypermethrin-induced follicular atresia in rat ovary: Evidence for energy dependent mechanism. *Vet Res Forum*; 7 (2): 125 – 132.
 - 14- Monks, T.J.; Ghersi-Egea, J.F.; Philbert, M.; Cooper, A.J. and Lock, E.A. (1999): Symposium overview: the role of glutathione in neuroprotection and neurotoxicity. *Toxicol Sci.*; 51:161–177.
 - 15- Mould, R.F. (1999): *Introductory Medical Statistics*. Adam Hilger, Bristol, Philadelphia, USA, pp. 22-126.
 - 16- Phensy, A.; Duzdabanian, H.E.; Brewer, S.; Panjabi, A.; Driskill, C.; Berz, A.; Peng, G. and Kroener, S. (2017): Antioxidant Treatment with N-acetyl Cysteine Prevents the Development

of Cognitive and Social Behavioral Deficits that Result from Perinatal Ketamine Behav. *Neurosci.*; 11:106.

- 17-** Pinilla, I.; Fernández-Sánchez, L.; Segura, F. J.; Sánchez-Cano, A. I.; Tamarit, J. M.; Fuentes-Broto, L., et al. (2016): Long time remodeling during retinal degeneration evaluated by optical coherence tomography, immunocytochemistry and fundus autofluorescence. *Exp. Eye Res.*; 150: 122–134.
- 18-** Saka, W.A.; Akhigbe, R.E.; Azeez, O.M. and Babatunde, T.R. (2011): Effect of pyrethroid exposure on haematological and haemostatic profiles in rats. *Pak. J. Biol. Sci.*; 14: 1024–1027.
- 19-** Sankar, P.; Telang, A.G. and Manimaran, A. (2012): Protective effect of curcumin on cypermethrin-induced oxidative stress in Wistar rats. *Exp. Toxicol. Pathol.*; 64(5): 487–493.
- 20-** Santos, P.; Ana, P.; Elisabetsky, H.E. & Piato, A. (2019): Anxiolytic properties of compounds that counteract oxidative stress, neuroinflammation, and glutamatergic dysfunction: a review, *Braz. J. Psychiatry*; 41: 2.
- 21-** Sapieha, P.; Hamel, D. and Shao, Z. et al. (2010): Proliferative retinopathies: Angiogenesis that blinds. *Int J Biochem Cell Biol.*; 42(1):5–12.
- 22-** Wang, Y.; Zhang, Y.; Ji, L.; Hu, Y.; Zhang, J.; Wang, C.; Ding, G. and Chen, L. (2017): Prenatal and postnatal exposure to organophosphate pesticides and childhood neurodevelopment in Shandong, China. *Environ Int*; 108: 119-126.
- 23-** Wu, J.; Gorman, A.; Zhou, X.; Sandra, C. and Chen, E. (2002): Involvement of caspase-3 in photoreceptor cell apoptosis induced by in vivo blue light exposure. *Invest Ophthalmol Vis Sci.*; 43:3349–3354.