

ONLINE FIRST

This is a provisional PDF only. Copyedited and fully formatted version will be made available soon.



CARDIOLOGY
JOURNAL

ISSN: 1897-5593

e-ISSN: 1898-018X

Comparison of Figulla Flex® and Amplatzer™ devices for atrial septal defect closure: A meta-analysis

Authors: Alvaro Aparisi, Roman J. Arnold, Hipólito Gutiérrez, Ana Revilla, Ana Serrador, Benigno Ramos, Tania Rodriguez-Gabella, Alberto Campo, Carlos Baladron, Itziar Gómez, Manuel Carrasco-Moraleja, José A. San Roman, Ignacio J. Amat-Santos

DOI: 10.5603/CJ.a2020.0058

Article type: Original articles

Submitted: 2019-01-21

Accepted: 2019-07-04

Published online: 2020-04-17

This article has been peer reviewed and published immediately upon acceptance.
It is an open access article, which means that it can be downloaded, printed, and distributed freely,
provided the work is properly cited.

Articles in "Cardiology Journal" are listed in PubMed.

Comparison of Figulla Flex[®] and Amplatzer[™] devices for atrial septal defect closure: A meta-analysis

Short title: Figulla Flex and Amplatzer for ASD

Álvaro Aparisi¹, Roman J. Arnold^{1,2}, Hipólito Gutiérrez¹, Ana Revilla^{1,2}, Ana Serrador¹, Benigno Ramos¹, Tania Rodríguez-Gabella¹, Alberto Campo¹, Carlos Baladrón², Itziar Gómez², Manuel Carrasco-Moraleja², José A. San Roman^{1,2}, Ignacio J. Amat-Santos^{1,2}

¹Cardiology Department, Hospital Clínico Universitario, Valladolid, Spain

²CIBER CV, Cardiology Department, Hospital Clínico Universitario, Valladolid, Spain

Address for correspondence: Ignacio J. Amat-Santos, MD, PhD, Instituto de Ciencias del Corazón (ICICOR), Hospital Clínico Universitario de Valladolid, Ramón y Cajal 3. 47005. Valladolid, Spain, tel: 0034 983 42 00 26, fax: 0034 983 25 53 05, e-mail: ijamat@gmail.com

Abstract

Background: Atrial septal defect (ASD) is one of the most common congenital heart diseases. Percutaneous closure is the preferred treatment, but certain complications remain a concern. The most common devices are AMPLATZER[™] (ASO) (St. Jude Medical, St. Paul, MN, USA) and Figulla Flex[®] septal occluders (FSO) (Occlutech GmbH, Jena, Germany). The present study aimed to assess main differences in outcomes.

Methods: A systematic search in Pubmed and Google scholarship was performed by two independent reviewers for any study comparing ASO and FSO. Searched terms were “Figulla”, “Amplatzer”, and “atrial septal defect”. A random-effects model was used.

Results: A total of 11 studies including 1770 patients (897 ASO; 873 FSO) were gathered. Baseline clinical and echocardiographic characteristics were comparable although septal aneurysm was more often reported in patients treated with ASO (32% vs. 25%; $p = 0.061$). Success rate (94% vs. 95%; OR: 0.81; 95% CI: 0.38–1.71; $p = 0.58$) and peri-procedural complications were comparable. Procedures were shorter, requiring less fluoroscopy time with an FSO device (OR: 0.59; 95% CI: 0.20–0.97; $p = 0.003$). Although the global rate of

complications in long-term was similar, the ASO device was associated with a higher rate of supraventricular arrhythmias (14.7% vs. 7.8%, $p = 0.009$).

Conclusions: Percutaneous closure of ASD is a safe and effective, irrespective of the type of device. No differences exist regarding procedural success between the ASO and FSO devices but the last was associated to shorter procedure time, less radiation, and lower rate of supraventricular arrhythmias in follow-up. Late cardiac perforation did not occur and death in the follow-up was exceptional.

Key words: Figulla, Amplatzer, atrial septal defect

INTRODUCTION

Atrial septal defect (ASD) is one of the most common congenital cardiac diseases representing up to 8% of them. As a main type, the therapeutic management of *ostium secundum* ASD has quickly evolved from surgery to percutaneous closure despite the low mortality rate (< 1%) of surgical repair. This can be explained by the good results of percutaneous closure through a less invasive procedure. Since first percutaneous closure of an ASD was performed more than four decades ago [1–3], and different devices have been proved to be safe and effective. In the last decade, the most commonly used ASD closure devices include the Amplatzer Septal Occluder (ASO) (Abbott Vascular[®], California, USA) and the more recent Figulla Flex septal occluder (FSO) (Occlutech[®] GmbH, Jena, Germany). The last has been developed in order to minimize complications while maintaining efficacy. However, comparisons of this device with those representing a broader experience is limited to a short series and potential advantages of the newer devices remain unproven. This is of major interest given the current investigations focused on bioresorbable closure devices that will require comparison with quality standards.

The Amplatzer Septal Occluder (Fig. 1A) is composed of a nitinol metal wire mesh that holds two self-expanding discs, and can be steadily deployed and recaptured [4, 5]. Dacron patches with a pro-coagulant material have been placed within the mesh in order to promote thrombosis and endothelialization [3–5]. Concerns with this device include those related to the procedure as embolization or residual shunt, and the rare but worrisome risk of tissular erosion/perforation in the long term. The newer Figulla Flex device (Fig. 1B, C) aims to diminish the risk of these complications through a less heavy mesh theoretically providing greater flexibility with less aggression to the tissues, and its deliverability in mainly larger defects is simplified. Also, the lack of a micro-screw potentially allows a smooth delivery and decreases

the risk of clot formation [1, 4]. As was said, large prospective randomized studies have not been performed to explore these aspects. Hence, the aim herein was to compare the FSO and ASO devices in current cohorts through a meta-analysis in order to determine rates of success, as well as short- and long-term complications which each system.

MATERIALS AND METHODS

Literature search strategy

A systematic review of all published research in PubMed and Google-Scholar databases between February/2009 and February/2018 regarding percutaneous closure of ASDs was independently performed by two authors (AA and IJAS). The following terms were used: “Figulla”, “Amplatzer”, and “atrial septal defect” (Fig. 20). Only full English peer-reviewed articles were selected and editorials or expert opinions were ruled out. Discrepancies between reviewers were resolved by discussion, and a consensus was reached.

Eligibility criteria

Eligible studies were considered those directly comparing outcomes of patients receiving either ASO or FSO closure devices and reporting peri-procedural and long-term outcomes. Events were entered as zeros in the tables for those studies that reported no complications during the follow-up period.

Main outcomes

Primary outcomes were procedural success, peri-procedural, and long-term complications. The last included cardiac perforation, cardiac death (including those of unknown origin), neurological events, and thrombus formation at any time point. Long-term was considered to be at least 6 months of follow-up.

Statistical analysis

Qualitative variables are expressed as an absolute frequency and percentage. Continuous variables are expressed as mean \pm standard deviation unless otherwise specified. In order to compare demographic variables and risk factors between groups, the χ^2 or the Fisher test were used for categorical variables and the Student-t test for continuous variables in cases where it was required.

Potential publication bias was assessed by using a funnel plot. As a measure of the combined effect for the studies included, the odds ratio (OR) was estimated, valid for prospective and retrospective studies. The confidence interval was at 95%, as well as its statistical significance. The homogeneity between studies was contrasted by the Q_H statistic. In regard to the low sensitivity of this test, $p < 0.10$ values were considered as significant. To overcome this limitation in some way, the I^2 statistic was estimated as well, which measures the proportion of the total variation of the studies explained by the heterogeneity and its 95% confidence interval (CI). A random effects model was used for those cases in which the I^2 statistic was greater than 50% and the model of fixed effects for opposite cases. A random effects model was used for all outcomes to obtain a loose estimate due to the inclusion of prospective and retrospective studies.

All p values were two sided. All analyses were conducted using the statistical software Review Manager 5.3.

RESULTS

Patient distribution and baseline characteristics.

A total of 1827 patients from 11 different studies (**Suppl. Table 1**) [6–16] underwent percutaneous ASD closure, with ASO (n = 897, 49.1%) or FSO (n = 873, 47.8%). Additionally, 57 patients (3.1% from the global study population) were excluded from the final analyses because a different device was used.

Baseline characteristics of the study population are summarized in Table 1. Age and gender were similar between treatment groups with a higher proportion of women (60% vs. 40%, $p = 0.154$). There were no statically significant differences regarding cardiovascular risk factors, except for a higher incidence of hypertension (29% vs. 19%; $p = 0.004$) and smoking (20% vs. 10%; $p = 0.004$) in patients treated with ASO. The rate of neurovascular events was very similar across both groups. No other differences were found.

Screening protocol and peri-procedural characteristics

Prior to the percutaneous procedure, patients underwent screening with transthoracic/transesophageal echocardiography in all cases. Screening protocols ruled out associated neurovascular, hematological or other conditions. During the pre-procedural evaluation, the presence of atrial septal aneurysm (ASA) was more often detected in patients treated with ASO (32% vs. 25%; $p = 0.061$).

Overall, success rate was comparable (94% for ASO vs. 95% for FSO; OR: 0.81; 95% CI: 0.38–1.71; $p = 0.58$) irrespective of its use for PFO or ASD, but shorter procedure and fluoroscopy times were obtained with the FSO device (OR: 0.59; 95% CI: 0.20–0.97; $p = 0.003$) despite similar device size (Fig. 3; **Suppl. Figs. 1, 2**). General anesthesia was the preferred strategy for both devices.

Periprocedural complications

No differences were found regarding the rate of failed closure or device embolization (0.04% vs. 0.1%, $p = 0.337$) but the absolute rate of residual shunt after the procedure was higher in patients treated with ASO than with FSO (12.2% vs. 9%; $p = 0.075$). The incidence of main complications is summarized in Table 1.

One procedural-related death due to cardiac perforation during balloon sizing was reported though the patient died two months later as a result of other hospitalization-related complications. Also, one transient ischemic event occurred a few minutes after ASD closure. Finally, one case of coronary embolism, and two of device thrombosis were also reported.

A pooled analysis of all procedural related complications (including cardiac perforation, device embolization, device thrombosis, severe arrhythmias, vascular complication, neurological events, and coronary embolism) was performed demonstrating the lack of statistical difference between both devices.

Follow-up outcomes.

Follow-up data were reported in all the articles. The mean follow-up for the global study population was 10.7 ± 6.9 months. Main complications within this period are summarized in Table 1. Post-procedural differences in the rate of residual shunt did not persist in the follow-up (8.5% vs. 9.3%, OR: 1.04; 95% CI: 0.60–1.79; $p = 0.89$) as depicted in Figure 3. However, the rate of supraventricular arrhythmia + atrial fibrillation was significantly higher after ASO (14.7%) than after FSO (7.8%, $p = 0.009$) in the pooled analysis. This statistical difference did not persist when a separate analysis was performed for PFO and ASD patients but a trend persisted in PFO cases and absolute values of this complication remained higher in patients harboring ASO devices (Suppl. Table 2).

The most frequent severe complication in long-term was recurrent neurovascular event including three cases of transient ischemic attack and one case of stroke. None who presented adhered thrombi to the device but, on the contrary, in half of them a residual shunt was present

requiring surgical closure [10]. Four cases of device thrombosis were observed, one of them was noted at 12 months after the intervention, which required surgical removal [10]; the other 3 cases presenting this complication, despite continued dual antiplatelet therapy and was successfully managed with intravenous heparin and oral anticoagulation [11]. One case of infective endocarditis due to *Staphylococcus lugdunensis* was reported 3 months after device placement, had positive blood cultures but no vegetation on the device as assessed by transesophageal echocardiography, and infection resolved after antibiotic treatment [7]. None of the studies reported any death or other major complication such as aortic erosion or device fracture in follow-up.

Regarding the antithrombotic strategy 6 studies reported the use of intravenous heparin during the procedure and, afterwards, 4 studies recommended transitory dual antiplatelet therapy (acetylsalicylic acid [ASA] + clopidogrel) whereas single antiplatelet therapy with ASA was preferred in 4 more studies. Prophylaxis of endocarditis was recommended for up to 6 months.

DISCUSSION

Percutaneous closure of *ostium secundum* ASD has become the standard care over the last decades [17–20]. Currently, alternative devices can be used in this scenario with ASO and FSO being the preferred ones. Notwithstanding this, large comparative studies of these technologies remain lacking. This meta-analysis demonstrated that, in similar populations, both devices present comparable success rates ($\geq 97\%$ for both) and also a similar rate of main procedural-related complications including imaging findings such as residual shunt (~9% at 1-year follow up) or device thrombosis. However, procedures were shorter with FSO suggesting a simpler delivery process, requiring less radiation which is a sensitive aspect in this young target population, and they also presented with half the rate of supraventricular arrhythmias in follow-up which might be explained by the properties of the FSO device with a less heavy mesh, likely diminishing the interaction with atrial tissue.

Baseline risk and post-procedural main complications

There was a higher prevalence of septal aneurysm among patients that underwent closure with ASO devices (32% vs. 25%, $p = 0.061$) which might partially explain the greater residual shunt detected with ASO in the peri-procedural transesophageal echocardiography. Pre-procedural screening and diagnosis of septal anomalies with transesophageal echocardiography has demonstrated an excellent specificity to diagnose and measure interatrial shunts [21–23] but

also might be useful in determining which device is optimal for each patient. According to the present findings, those patients with baseline risk of residual shunt (i.e. larger defects, septal aneurysm) and those predisposed to supraventricular arrhythmias (i.e. larger atria or history of paroxysmal atrial fibrillation) might benefit more from a smoother device.

Percutaneous closure of the septal defects presented similar success rates to those reported in former studies (96–98%) [24]. The procedure is considered successful even in the presence of a mild residual shunt if the device is stable though it is well known that mild to moderate residual shunts might preclude from full endothelialization [5]. Indeed, current evaluation of residual shunting degree is based on the classification by Boutin et al. [24] (mild 1–2 mm, moderate 2–4 mm, and large 4–8 mm) which might present certain limitations when evaluating the impact on long-term outcomes. Although percutaneous closure presents a lower rate of complications as compared to surgical closure (7% vs. 24%), the presence of residual shunt and its associated risks (right heart overload, paradoxical emboli, supraventricular arrhythmia, etc.) might require surgical closure more often than thought. On the other hand, the absence of cases presenting cardiac erosion in this research is a reassuring finding but since that might appear even years after the procedure [24, 25] and is a life-threatening complication, any measure aimed to diminish that risk, as is the use of more flexible devices, ought to be considered [26].

Finally, the development of supraventricular arrhythmia is a classical concern in patients suffering from left-to-right blood shunting but, paradoxically, sometimes they can be triggered by the percutaneous closure device itself, likely due to local inflammation and scarring. In this regard, the potential variable impact of devices manufactured with different raw materials might explain the lower rate of this complication with the FSO [27, 28]. It is noted, this difference in the rate of supraventricular arrhythmias were not statistically significant when analyzed separately for PFO and congenital ASD but the persistence of a statistical trend also supports that this hypothesis which merits further investigation.

Uncommon complications: endocarditis, devices thrombosis and neurovascular events

Device implantation is performed under strict asepsia and with prior antibiotic prophylaxis [29] to lower the risk of device related infective endocarditis. However, this complication is occasionally reported in the literature [30]. Consensus has not been reached regarding adequate antibiotic prophylactic treatment but some authors suggest up to 6 months until endothelialization is completed (according to findings from animal models) [26], but also,

the raw materials and structure of the devices might play a role. Similarly, device thrombosis is rare but could be additionally associated to the use of one material or another and its structure. However, more data are needed to verify this hypothesis since no differences were found in this research. Finally, neurovascular events have been related to the presence of residual shunts [27, 28] which was not uncommon in this analysis and should raise attention to the most adequate imaging tool to be used in follow-up and also stresses the importance of adequate sizing during the procedure; the use of ASO or FSO neither played a role on this complication and both were equally safe in this regard.

There are a number of limitations related to this work. First, the paucity of multicentric randomized studies and the typology of the compiled studies may somehow limit the external validity of the reported findings. Secondly, outcomes were reported only for up to 1 year but longer follow-up would be required to assess safety issues of concern. Finally, some of the gathered studies presented a lack of clear definition of major and minor complications and their underreporting could not be ruled out. Also, some of the studies had small sample sizes which may have had an impact on the results due to low operator experience with percutaneous closure of interatrial septal defects.

CONCLUSIONS

In this meta-analysis that included 11 non-randomized studies and > 1800 patients undergoing ASD closure with both, the ASO or the FSO closure devices, safety and effectiveness were similar as well as global success rate. However, procedures were shorter with the FSO device and the rate of supraventricular arrhythmias in follow-up was lower. Importantly, no cases of late cardiac erosion were detected. Newer bioresorbable devices will need to demonstrate competitive results to those herein reported.

Conflict of interest: None declared

REFERENCES

1. Ilkay E, Kaçmaz F, Ozeke O, et al. The efficiency and safety of percutaneous closure of secundum atrial septal defects with the Occlutech Figulla device: initial clinical experience. *Turk Kardiyol Dern Ars.* 2010; 38(3): 189–193, indexed in Pubmed: [20675996](#).

2. Thomson JDR, Qureshi SA. Device closure of secundum atrial septal defect's and the risk of cardiac erosion. *Echo Res Pract.* 2015; 2(4): R73–R78, doi: [10.1530/ERP-15-0023](https://doi.org/10.1530/ERP-15-0023), indexed in Pubmed: [26796060](https://pubmed.ncbi.nlm.nih.gov/26796060/).
3. Gupta A, Kapoor G, Dalvi B. Transcatheter closure of atrial septal defects. *Expert Rev Cardiovasc Ther.* 2004; 2(5): 713–719, doi: [10.1586/14779072.2.5.713](https://doi.org/10.1586/14779072.2.5.713), indexed in Pubmed: [15350172](https://pubmed.ncbi.nlm.nih.gov/15350172/).
4. Bissessor N. Current perspectives in percutaneous atrial septal defect closure devices. *Med Devices (Auckl).* 2015; 8: 297–303, doi: [10.2147/MDER.S49368](https://doi.org/10.2147/MDER.S49368), indexed in Pubmed: [26203289](https://pubmed.ncbi.nlm.nih.gov/26203289/).
5. Garg P, Walton AS. The new world of cardiac interventions: a brief review of the recent advances in non-coronary percutaneous interventions. *Heart Lung Circ.* 2008; 17(3): 186–199, doi: [10.1016/j.hlc.2007.10.019](https://doi.org/10.1016/j.hlc.2007.10.019), indexed in Pubmed: [18262841](https://pubmed.ncbi.nlm.nih.gov/18262841/).
6. Pac A, Polat TB, Cetin I, et al. Figulla ASD occluder versus Amplatzer Septal Occluder: a comparative study on validation of a novel device for percutaneous closure of atrial septal defects. *J Interv Cardiol.* 2009; 22(6): 489–495, doi: [10.1111/j.1540-8183.2009.00497.x](https://doi.org/10.1111/j.1540-8183.2009.00497.x), indexed in Pubmed: [19735475](https://pubmed.ncbi.nlm.nih.gov/19735475/).
7. Saguner AM, Wahl A, Praz F, et al. Figulla PFO occluder versus Amplatzer PFO occluder for percutaneous closure of patent foramen ovale. *Catheter Cardiovasc Interv.* 2011; 77(5): 709–714, doi: [10.1002/ccd.22737](https://doi.org/10.1002/ccd.22737), indexed in Pubmed: [20931665](https://pubmed.ncbi.nlm.nih.gov/20931665/).
8. Oto A, Aytemir K, Ozkutlu S, et al. Transthoracic echocardiography guidance during percutaneous closure of patent foramen ovale. *Echocardiography.* 2011; 28(10): 1074–1080, doi: [10.1111/j.1540-8175.2011.01524.x](https://doi.org/10.1111/j.1540-8175.2011.01524.x), indexed in Pubmed: [21967656](https://pubmed.ncbi.nlm.nih.gov/21967656/).
9. Canpolat U, Aytemir K, Yorgun H, et al. PP-066: Figulla PFO occluder versus Amplatzer PFO occluder for percutaneous closure of patent foramen ovale. *Int J Cardiol.* 2012; 155: S120, doi: [10.1016/s0167-5273\(12\)70292-9](https://doi.org/10.1016/s0167-5273(12)70292-9).
10. Aytemir K, Oto A, Özkutlu S, et al. Percutaneous ASD and PFO Closure. *Congenit Heart Dis.* 2013; 8: 418–427.
11. Vitarelli A, Mangieri E, Capotosto L, et al. Echocardiographic findings in simple and complex patent foramen ovale before and after transcatheter closure. *Eur Heart J Cardiovasc Imaging.* 2014; 15(12): 1377–1385, doi: [10.1093/ehjci/jeu143](https://doi.org/10.1093/ehjci/jeu143), indexed in Pubmed: [25139906](https://pubmed.ncbi.nlm.nih.gov/25139906/).
12. Roymanee S, Promphan W, Tonklang N, et al. Comparison of the Occlutech® Figulla® septal occluder and Amplatzer® septal occluder for atrial septal defect device closure. *Pediatr Cardiol.* 2015; 36(5): 935–941, doi: [10.1007/s00246-015-1103-y](https://doi.org/10.1007/s00246-015-1103-y), indexed in Pubmed: [25633819](https://pubmed.ncbi.nlm.nih.gov/25633819/).
13. Godart F, Houeijeh A, Recher M, et al. Transcatheter closure of atrial septal defect with the Figulla(®) ASD Occluder: a comparative study with the Amplatzer(®) Septal Occluder. *Arch Cardiovasc Dis.* 2015; 108(1): 57–63, doi: [10.1016/j.acvd.2014.09.005](https://doi.org/10.1016/j.acvd.2014.09.005), indexed in Pubmed: [25453168](https://pubmed.ncbi.nlm.nih.gov/25453168/).
14. Scalise F, Auguadro C, Sorropago G, et al. Long-Term contrast echocardiography and clinical follow-up after percutaneous closure of patent foramen ovale using two different atrial septal occluder devices. *J Interv Cardiol.* 2016; 29(4): 406–413, doi: [10.1111/joic.12314](https://doi.org/10.1111/joic.12314), indexed in Pubmed: [27338839](https://pubmed.ncbi.nlm.nih.gov/27338839/).
15. Nir-David Y, Mainzer G, Tal R, et al. Comparing the Performance of Amplatzer® and Occlutech® Figulla® Septal Occluders: The Pediatric Point of View. A Retrospective Study. *Isr Med Assoc J.* 2017; 19(9): 557–561, indexed in Pubmed: [28971639](https://pubmed.ncbi.nlm.nih.gov/28971639/).
16. Trabattoni D, Gaspardone A, Sgueglia GA, et al. AMPLATZER versus Figulla occluder for transcatheter patent foramen ovale closure. *EuroIntervention.* 2017; 12(17): 2092–2099, doi: [10.4244/EIJ-D-15-00499](https://doi.org/10.4244/EIJ-D-15-00499), indexed in Pubmed: [27993750](https://pubmed.ncbi.nlm.nih.gov/27993750/).

17. Baumgartner H, Bonhoeffer P, De Groot NMS, et al. Task Force on the Management of Grown-up Congenital Heart Disease of the European Society of Cardiology (ESC), Association for European Paediatric Cardiology (AEPC), ESC Committee for Practice Guidelines (CPG). ESC Guidelines for the management of grown-up congenital heart disease (new version 2010). *Eur Heart J*. 2010; 31(23): 2915–2957, doi: [10.1093/eurheartj/ehq249](https://doi.org/10.1093/eurheartj/ehq249), indexed in Pubmed: [20801927](https://pubmed.ncbi.nlm.nih.gov/20801927/).
18. Vasquez AF, Lasala JM. Atrial septal defect closure. *Cardiol Clin*. 2013; 31(3): 385–400, doi: [10.1016/j.ccl.2013.05.003](https://doi.org/10.1016/j.ccl.2013.05.003), indexed in Pubmed: [23931101](https://pubmed.ncbi.nlm.nih.gov/23931101/).
19. Rao PS, Harris AD. Recent advances in managing septal defects: atrial septal defects. *F1000Res*. 2017; 6: 2042, doi: [10.12688/f1000research.11844.1](https://doi.org/10.12688/f1000research.11844.1), indexed in Pubmed: [29250321](https://pubmed.ncbi.nlm.nih.gov/29250321/).
20. Harper RW, Mottram PM, McGaw DJ. Closure of secundum atrial septal defects with the Amplatzer septal occluder device: techniques and problems. *Catheter Cardiovasc Interv*. 2002; 57(4): 508–524, doi: [10.1002/ccd.10353](https://doi.org/10.1002/ccd.10353), indexed in Pubmed: [12455087](https://pubmed.ncbi.nlm.nih.gov/12455087/).
21. Bechis MZ, Rubenson DS, Price MJ. Imaging assessment of the interatrial septum for transcatheter atrial septal defect and patent foramen ovale closure. *Interv Cardiol Clin*. 2017; 6(4): 505–524, doi: [10.1016/j.iccl.2017.05.004](https://doi.org/10.1016/j.iccl.2017.05.004), indexed in Pubmed: [28886842](https://pubmed.ncbi.nlm.nih.gov/28886842/).
22. Mojadidi MK, Winoker JS, Roberts SC, et al. Accuracy of conventional transthoracic echocardiography for the diagnosis of intracardiac right-to-left shunt: a meta-analysis of prospective studies. *Echocardiography*. 2014; 31(9): 1036–1048, doi: [10.1111/echo.12583](https://doi.org/10.1111/echo.12583), indexed in Pubmed: [24689727](https://pubmed.ncbi.nlm.nih.gov/24689727/).
23. Mojadidi MK, Bogush N, Caceres JD, et al. Diagnostic accuracy of transesophageal echocardiogram for the detection of patent foramen ovale: a meta-analysis. *Echocardiography*. 2014; 31(6): 752–758, doi: [10.1111/echo.12462](https://doi.org/10.1111/echo.12462), indexed in Pubmed: [24372693](https://pubmed.ncbi.nlm.nih.gov/24372693/).
24. Moore J, Hegde S, El-Said H, et al. ACC IMPACT Steering Committee. Transcatheter device closure of atrial septal defects: a safety review. *JACC Cardiovasc Interv*. 2013; 6(5): 433–442, doi: [10.1016/j.jcin.2013.02.005](https://doi.org/10.1016/j.jcin.2013.02.005), indexed in Pubmed: [23702008](https://pubmed.ncbi.nlm.nih.gov/23702008/).
25. Crawford GB, Brindis RG, Krucoff MW, et al. Percutaneous atrial septal occluder devices and cardiac erosion: a review of the literature. *Catheter Cardiovasc Interv*. 2012; 80(2): 157–167, doi: [10.1002/ccd.24347](https://doi.org/10.1002/ccd.24347), indexed in Pubmed: [22552868](https://pubmed.ncbi.nlm.nih.gov/22552868/).
26. Wiktor DM, Carroll JD. ASD closure in structural heart disease. *Curr Cardiol Rep*. 2018; 20(6): 37, doi: [10.1007/s11886-018-0983-x](https://doi.org/10.1007/s11886-018-0983-x), indexed in Pubmed: [29666940](https://pubmed.ncbi.nlm.nih.gov/29666940/).
27. Contractor T, Mandapati R. Arrhythmias in patients with atrial defects. *Card Electrophysiol Clin*. 2017; 9(2): 235–244, doi: [10.1016/j.ccep.2017.02.006](https://doi.org/10.1016/j.ccep.2017.02.006), indexed in Pubmed: [28457238](https://pubmed.ncbi.nlm.nih.gov/28457238/).
28. Rengifo-Moreno P, Palacios IF, Junpaparp P, et al. Patent foramen ovale transcatheter closure vs. medical therapy on recurrent vascular events: a systematic review and meta-analysis of randomized controlled trials. *Eur Heart J*. 2013; 34(43): 3342–3352, doi: [10.1093/eurheartj/ehq285](https://doi.org/10.1093/eurheartj/ehq285), indexed in Pubmed: [23847132](https://pubmed.ncbi.nlm.nih.gov/23847132/).
29. Jalal Z, Hascoet S, Baruteau AE, et al. Long-term complications after transcatheter atrial septal defect closure: a review of the medical literature. *Can J Cardiol*. 2016; 32(11): 1315.e11–1315.e18, doi: [10.1016/j.cjca.2016.02.068](https://doi.org/10.1016/j.cjca.2016.02.068), indexed in Pubmed: [27179546](https://pubmed.ncbi.nlm.nih.gov/27179546/).
30. Amedro P, Soulatges C, Fraisse A. Infective endocarditis after device closure of atrial septal defects: Case report and review of the literature. *Catheter Cardiovasc Interv*. 2017; 89(2): 324–334, doi: [10.1002/ccd.26784](https://doi.org/10.1002/ccd.26784), indexed in Pubmed: [27641431](https://pubmed.ncbi.nlm.nih.gov/27641431/).

Table 1. Reported baseline characteristics, procedural and follow-up outcomes.

Variables	Global study population N = 1827	Amplatzer N = 897/1770 (50.7%)	Figulla N = 873/1770 (49.3%)	P
Baseline characteristics				
Females	663/1099 (60%)	350 (62%)	313 (58%)	0.154
Age [years]	45.48 ± 10.39	44.08 ± 11.48	47.02 ± 9.08	< 0.001
Hypertension	149/634 (24%)	85/297 (29%)	64/337 (19%)	0.004
Diabetes	15/634 (24%)	9/297 (3%)	6/337 (2%)	0.301
Dyslipemia	144/493 (29%)	66/225 (29%)	78/268 (29%)	0.956
Smoking	72/493 (15%)	44/225 (20%)	28/268 (10%)	0.004
TIA	411/744 (55%)	193/347 (56%)	218/397 (55%)	0.846
Stroke	218/634 (34%)	102/297 (34%)	116/337 (34%)	0.983
Recurrent ischemic or embolic events	222/634 (35%)	105/297 (35%)	117/337 (35%)	0.867
Thrombophilia	84/594 (14%)	39/277 (14%)	45/317 (14%)	0.995
Atrial septal aneurysm	186/657 (28%)	96/301 (32%)	90/356 (25%)	0.061
NYHA III-IV	10/149 (7%)	5/72 (7%)	5/77 (6%)	0.999
Procedural outcomes				
Procedural success	788/809 (97.4%)	435/446 (98%)	353/363 (97%)	0.8
Procedural time [min]	40.59 ± 25.25	41.82 ± 22.54	39.24 ± 27.94	0.166
Fluoroscopic time [min]	11.60 ± 20.05	12.22 ± 19.42	10.91 ± 20.73	< 0.001
Device size [mm]	21.18 ± 4.23	21.19 ± 3.87	21.16 ± 4.65	0.37
Device embolization	9/1683 (0.53%)	3/848 (0.4%)	6/826 (1%)	0.337
Vascular complication	9/908 (1%)	4/441 (0.9%)	5/458 (1.1%)	0.999
Residual shunt	131/1287 (10.2%)	46/373 (12.2%)	54/386 (9%)	0.075
Stroke/TIA	1/1770 (0.05%)	0	1/873 (0.1%)	0.999
Device thrombosis	0	0	0	0.999
Coronary embolism	1/101 (1%)	1/52 (2%)	0	0.999
Death	1/445 (0.2%)	1/445 (0.2%)	0/463	0.999
Follow up outcomes				

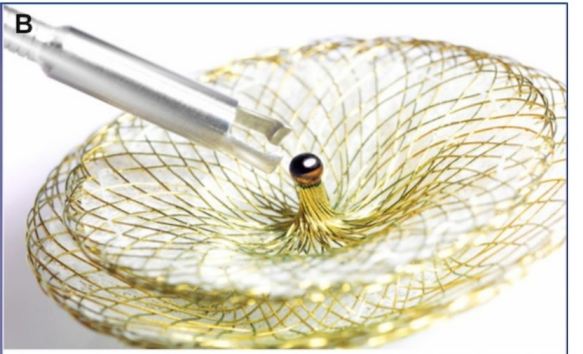

Death	0	0	0	–
Aortic erosion	0	0	0	–
Device fracture	0	0	0	–
Stroke/TIA	5/788 (0.6%)	2/251 (0.8%)	3/296 (1%)	0.999
Endocarditis	1/788 (0.1%)	0	1/296	0.999
Residual shunt (at 6–12 months)	70/788 (8.79%)	17/222 (7.7%)	17/160 (10.6%)	0.31
SVA and AF	60/547 (11%)	37/251 (14.7%)	23/296 (7.8%)	0.009
SVA	50/406 (12.3%)	30/179 (16.8%)	20/227 (8.8%)	0.006
AF	10/547 (1.8%)	7/251 (2.8%)	3/296 (1%)	0.198

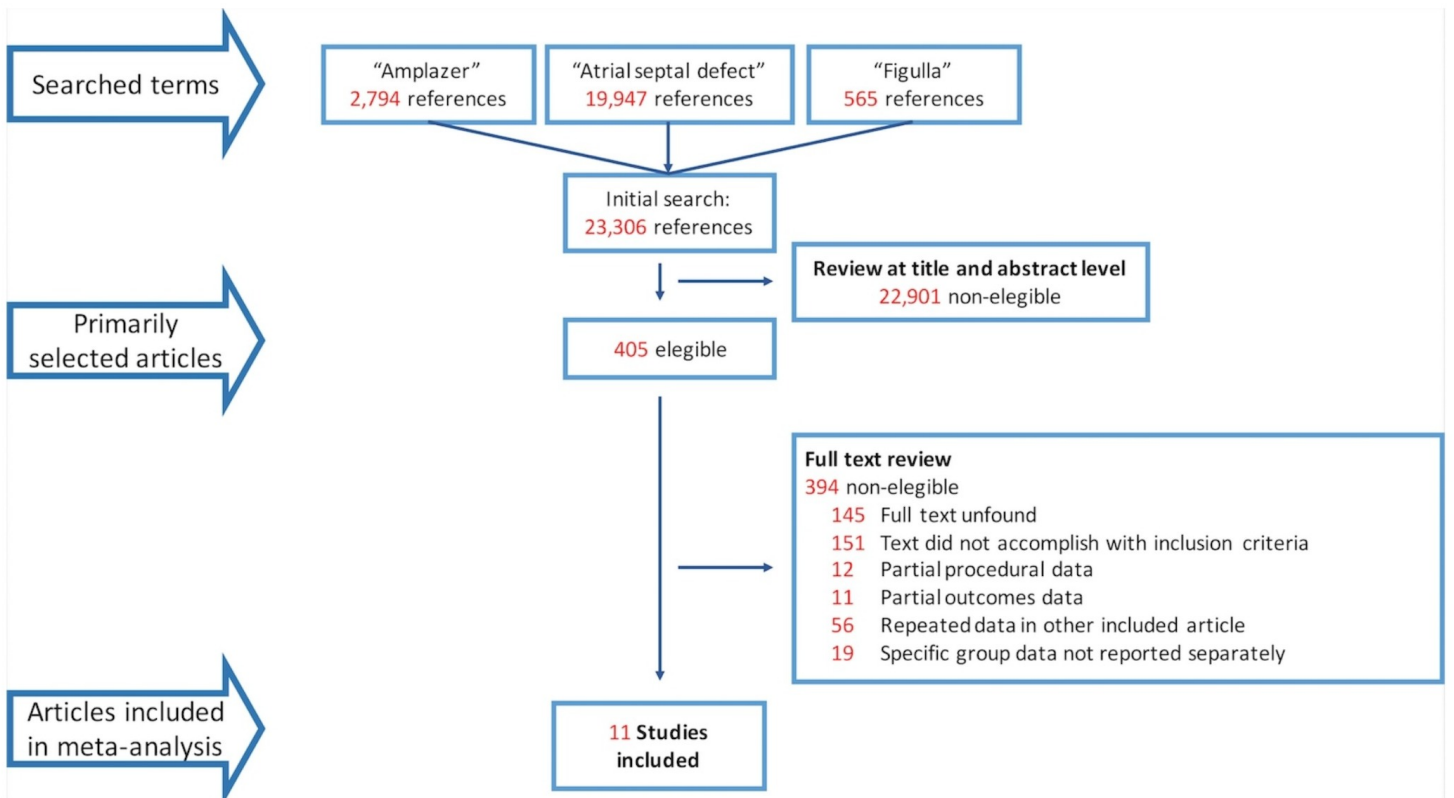
AF — atrial fibrillation; NYHA — New York Heart Association; SVA — supraventricular arrhythmia; TIA — transient ischemic attack

Figure 1. Amplatzer septal occluder (**A**) and Figulla Flex II (**B**, **C**) showing main differential features of Figulla Flex including the lack of screw attachment (replaced by a ball, **B**) and the smooth left atrial disc (**C**).

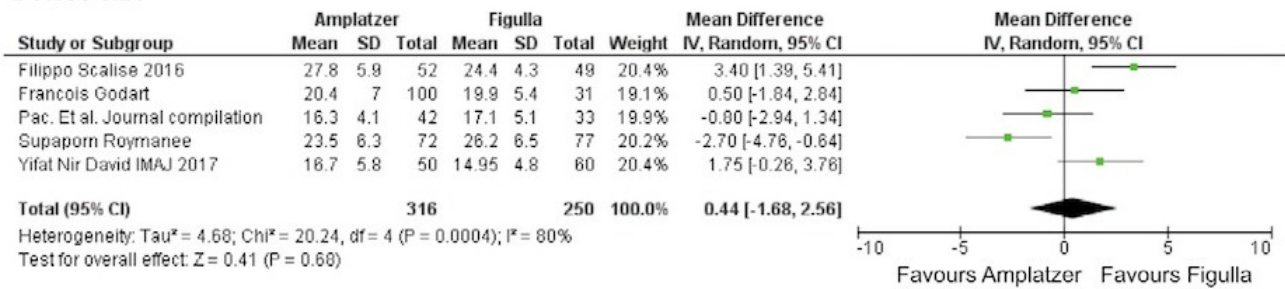
Figure 2. Flow chart showing search results and selection of the studies included in the meta-analysis.

Figure 3. Forest plot reflecting procedural and follow-up outcomes of the patients included in the meta-analysis. *Vertical line represents “no difference” point between the Amplatzer and Figulla groups; Horizontal lines 95% confidence interval (CI). Squares represent odds ratio for each study (the size of each square denotes the proportion of information given by each study). Diamonds represent pooled odds ratios from all studies.

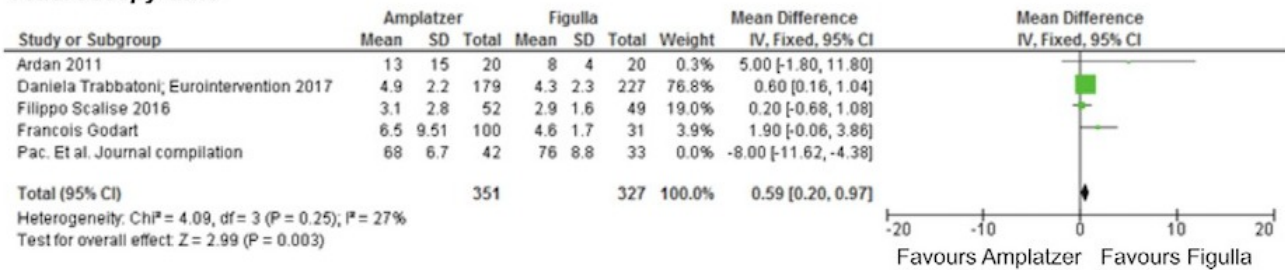




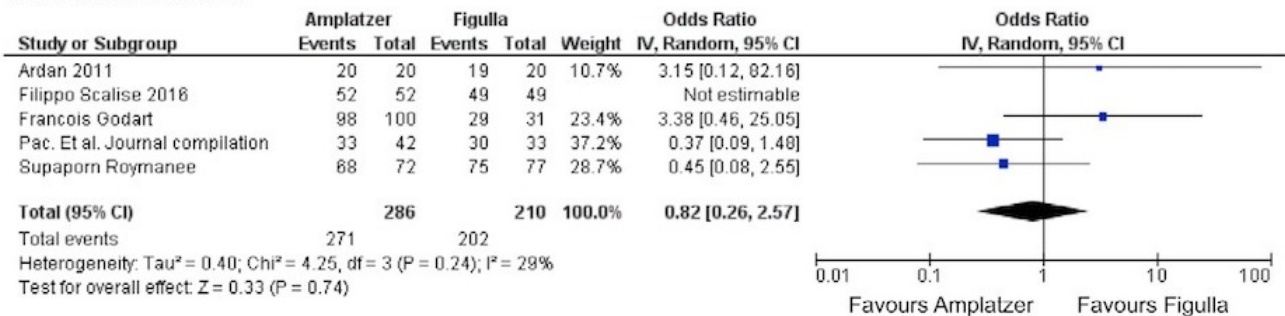
Device size



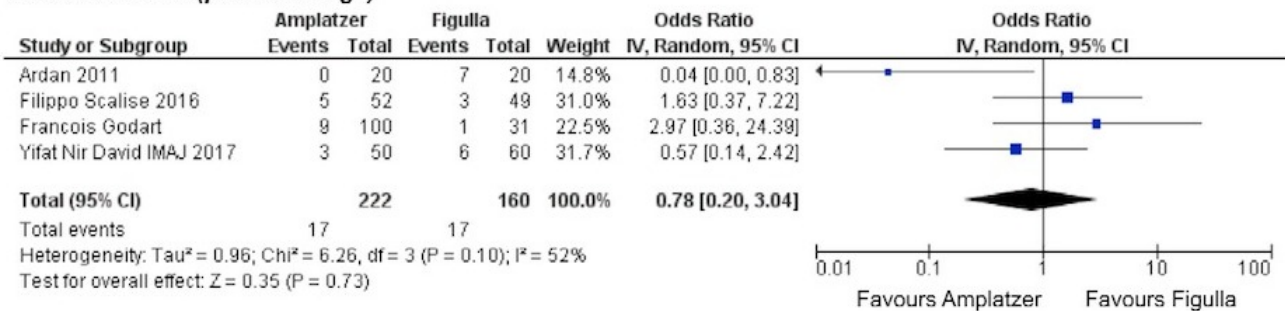
Fluoroscopy time



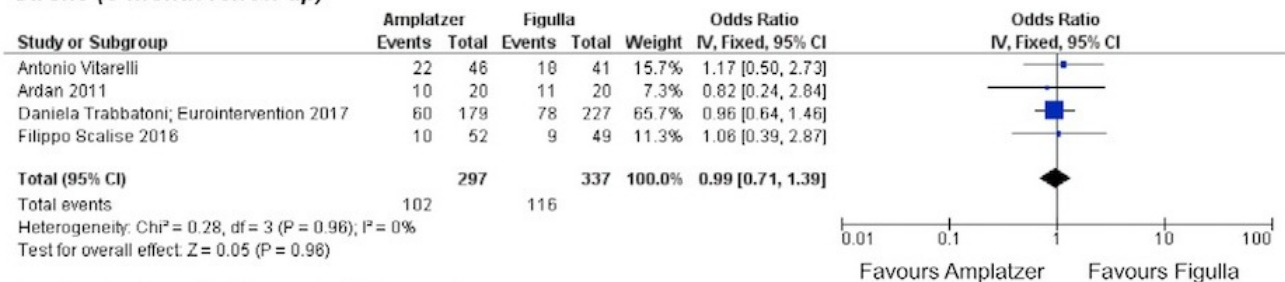
Procedural success



Residual shunt (pre-discharge)



Stroke (6-month follow up)



Residual shunt (6-12 month follow up)

