

2018

Transaortic gunshot wound through perivisceral segment successfully managed by placement of thoracic stent graft

Jared T. Feyko

Peter Zmijewski

Cara Lyle

Allison Wilson

Luke Marone

Follow this and additional works at: https://researchrepository.wvu.edu/faculty_publications



Part of the [Surgery Commons](#)

Transaortic gunshot wound through perivisceral segment successfully managed by placement of thoracic stent graft

Jared T. Feyko, DO, Peter Zmijewski, MD, Cara Lyle, MD, Allison Wilson, MD, and Luke Marone, MD,
Morgantown, WV

ABSTRACT

We describe a 36-year-old woman who presented to our facility after sustaining a gunshot wound to the epigastric region. The gunshot resulted in injury to the left lobe of the liver and the twelfth thoracic vertebral body as well as in a through-and-through injury to the abdominal aorta at the level of the celiac axis. The vascular injury was managed successfully by placement of a thoracic stent graft with coverage of the celiac axis. This case demonstrates the feasibility of managing this uncommon injury with endovascular techniques. (*J Vasc Surg Cases and Innovative Techniques* 2018;4:24-6.)

Thoracic stent grafts have been approved by the Food and Drug Administration for treatment of descending thoracic aortic aneurysms since 2005.¹ Thoracic stent graft use in modern clinical practice has since expanded to treat additional pathologic processes, including aortic transections and dissections. The use of these grafts has dramatically changed the approach to and morbidity of traumatic aortic transection. This technology has decreased the operative burden for multiply injured patients, such as those with traumatic brain injuries or pulmonary contusions. It is rare for thoracic stent grafts to be used for treatment of penetrating aortic trauma or iatrogenic injuries to the aorta. This use has been described for gunshot injury to the thoracic aorta as well as for iatrogenic injury.^{2,3} The thoracoabdominal gunshot wound remains a substantial challenge that carries with it a markedly high morbidity and mortality. Novel approaches that provide rapid control of bleeding and repair of the injury in this anatomically critical region are desired. This case describes a transaortic gunshot injury at the level of the celiac axis successfully managed by placement of a thoracic stent graft. Written consent was obtained from the patient for publication of this case.

CASE REPORT

We describe a 36-year-old woman who presented with a single epigastric gunshot wound of unknown caliber. The injury

occurred approximately 3 hours before arrival to the trauma center. She was initially hypotensive in the field but responded to crystalloid infusion by the emergency medical services. On arrival to the trauma center, the patient was hemodynamically stable, with a heart rate of 90 beats/min and blood pressure of 125/80 mm Hg. She had normal breath sounds and oxygen saturations. Her Glasgow Coma Scale score was 15, and she reported decreased sensation in and movement of her left lower extremity. Her secondary survey revealed a single gunshot wound to the epigastrium and no exit wound. Pulses were palpable and equal in all extremities. No other abnormalities were noted on examination. A chest radiograph showed a metallic density in the epigastric region. The Focused Assessment with Sonography for Trauma examination was performed; results were positive for fluid in the right upper quadrant but negative for fluid in the pericardial sac or other abdominal views. She remained normotensive and was not tachycardic, nor did she require crystalloid or blood products. Given her hemodynamic stability and the combination of length of time from injury, location of wound and fragments, and neurologic deficits of the leg, the decision was made to obtain a computed tomography (CT) scan to better delineate the injury. A CT angiogram of the chest, abdomen, and pelvis was obtained. This showed a grade III liver laceration, a comminuted fracture of the left lateral T12 vertebral body, and a bullet residing in the soft tissue posterior to the spine. Most important, a through-and-through injury to the abdominal aorta was present at the level of the celiac axis with retroperitoneal hematoma (*Fig 1*).

The patient was taken to the hybrid operating room with both trauma and vascular surgeons with the plan to repair the aorta by an endovascular approach. At the start of the case, we obtained percutaneous access and placed a 16F sheath in the left common femoral artery and a 5F sheath in the right common femoral artery. We used radiographic guidance to locate the femoral head and performed sheath angiography to confirm the site of our access before upsizing our sheath and deploying ProGlide (Abbott Vascular, Santa Clara, Calif) devices. We did not heparinize the patient because of her coexisting liver injury. A pigtail catheter was inserted through the right sheath, and anteroposterior and lateral aortograms were obtained.

From the Division of Vascular Surgery, West Virginia University.

Author conflict of interest: none.

Correspondence: Jared T. Feyko, DO, Division of Vascular Surgery, West Virginia University, 1 Medical Center Dr, PO Box 8500, Morgantown, WV 26506 (e-mail: jfeyko@hsc.wvu.edu).

The editors and reviewers of this article have no relevant financial relationships to disclose per the Journal policy that requires reviewers to decline review of any manuscript for which they may have a conflict of interest.

2468-4287

© 2018 The Author(s). Published by Elsevier Inc. on behalf of Society for Vascular Surgery. This is an open access article under the CC BY-NC-ND license (<http://creativecommons.org/licenses/by-nc-nd/4.0/>).

<https://doi.org/10.1016/j.jvscit.2017.11.009>

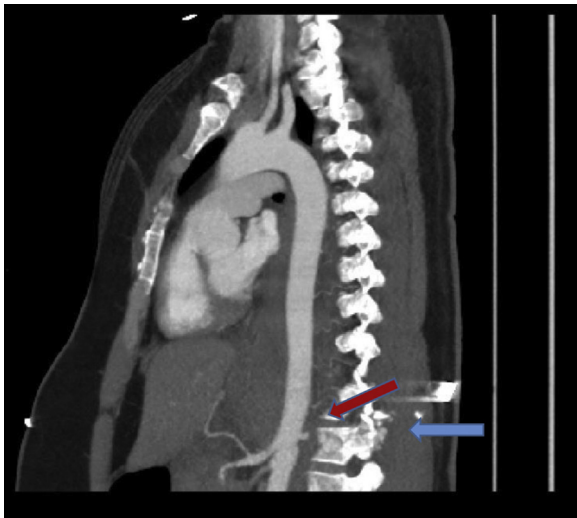


Fig 1. Computed tomography (CT) scan before intervention. The *blue arrow* marks the thoracic body fracture; the *red arrow* marks aortic extravasation.

This demonstrated an aortic pseudoaneurysm caudal to the celiac axis and cranial to the superior mesenteric artery with 1 cm between the two vessels (Fig 2). The aorta was sized on the basis of CT, and the anticipated proximal seal zone in the distal descending thoracic aorta measured 18 mm in diameter. The anticipated distal seal between the celiac and superior mesenteric artery measured 17 mm in diameter. A proximal component Zenith Alpha Thoracic Endovascular Graft (Cook Medical, Bloomington, Ind) 20 mm in diameter and 109 mm in length was selected and deployed with the distal extent covering the orifice of the celiac artery. Before deployment, the patency of the gastroduodenal artery was confirmed. The stent graft was postdilated using a Reliant balloon (Medtronic, Santa Rosa, Calif) to fully appose the graft to the vessel wall, and completion angiography demonstrated good seal with exclusion of the injured visceral segment of aorta. In addition, the superior mesenteric artery remained patent, and the celiac branches filled through collaterals. At this point, an exploratory laparotomy was conducted with the following findings: grade III liver injury in segment III, grade I injury to segment I, and grade I pancreatic injury of the pancreatic body. No resection was required, and drains were placed by the liver to drain any potential bile leak and by the pancreatic injury. Her case was complicated by left-sided access site thrombosis requiring thrombectomy and fasciotomies. Her postoperative course was complicated by a bile leak, which was managed by sphincterotomy and biliary stent placement. She has since recovered well and has returned to normal activities. There was no long-term morbidity associated with her access site complication. She was seen 6 months postoperatively and CT was performed, which demonstrated proper positioning of the stent graft and patency of the celiac artery (Fig 3).

DISCUSSION

Endovascular treatment of penetrating traumatic aortic injuries or iatrogenic aortic injuries is extremely rare.

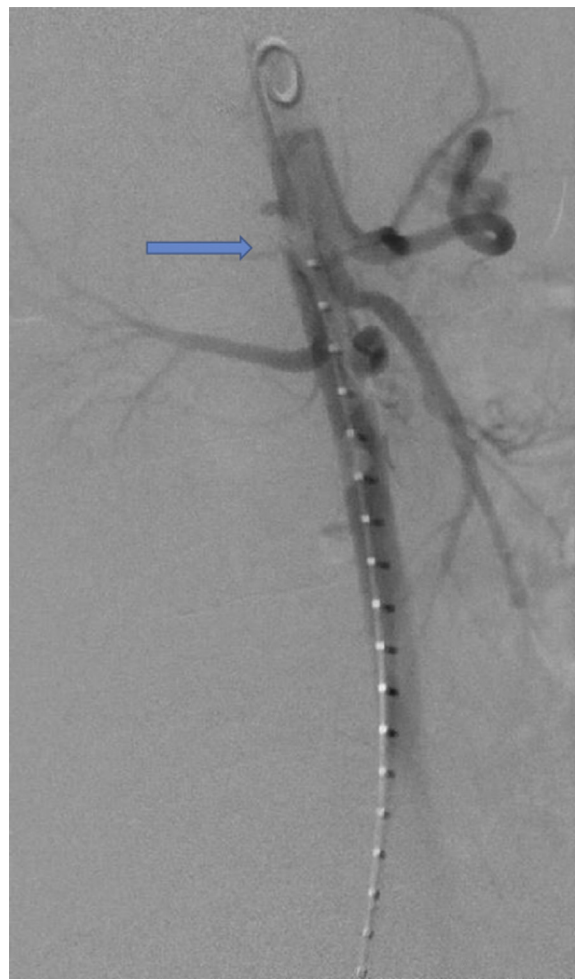


Fig 2. Aortogram before graft deployment. The *arrow* marks the area of aortic injury.

There is a case report of a gunshot injury to the thoracic aorta that was managed with thoracic stent graft placement.² There was also a recent report in an open access journal of a gunshot wound to the supraceliac aorta treated with stent graft placement; however, this case did not require coverage of any major aortic branch vessels.⁴ The overall stability of this patient on presentation was probably secondary to two key factors: first, her injury was likely caused by a small-caliber weapon; and second, the injury to the supraceliac aorta was tamponaded by the diaphragmatic crus and dense surrounding connective tissue. Therefore, after the initial penetrating injury, a pseudoaneurysm formed, which was controlled by the unique anatomy in this region and was critical to her stability on arrival.

Open repair of aortic injuries has a high rate of mortality and morbidity. Open procedures involving the perivisceral segment are more complex and have higher rates of morbidity and mortality. This case demonstrated that even in the challenging perivisceral segment, stent grafts can be used successfully to manage penetrating

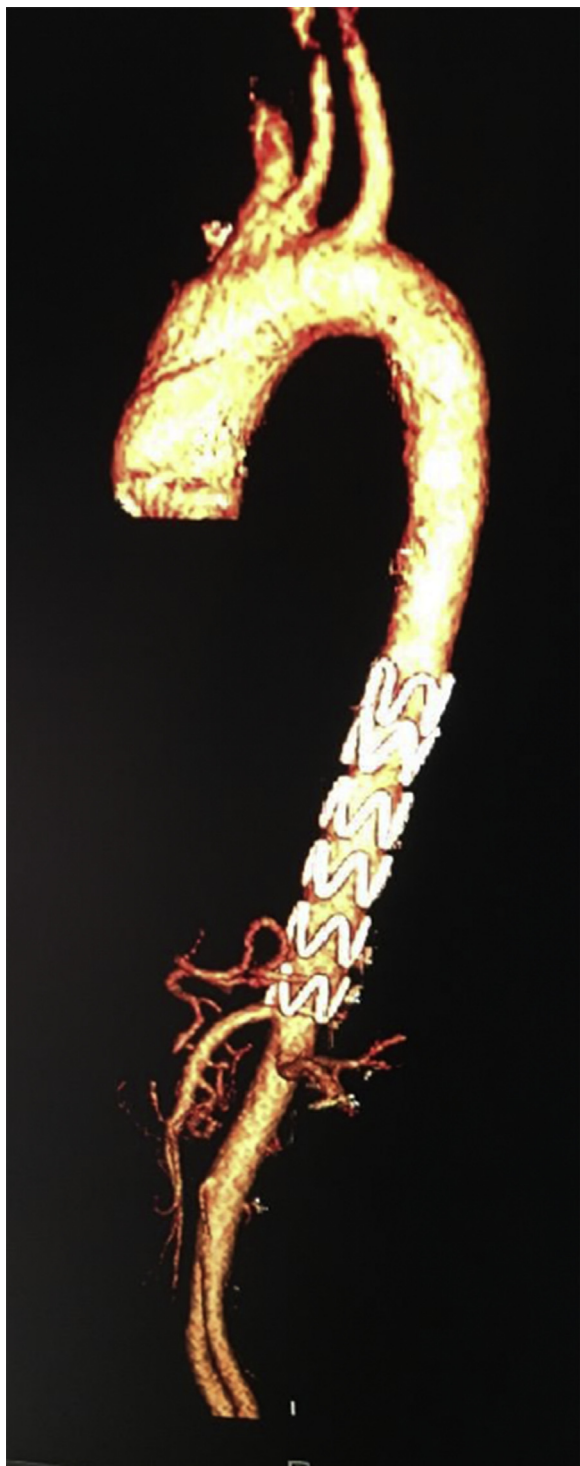

Fig 3. The 6-month follow-up computed tomography (CT) scan.

traumatic injuries. Confirming the presence of patent collateral vessels (most notably the gastroduodenal artery) to perfuse the celiac branches before celiac artery coverage is critical in this scenario. The literature from endovascular treatment of aortic dissections and

aneurysms requiring celiac artery coverage supports the feasibility and favorable long-term outcome of celiac coverage.⁵ This patient did unfortunately have a thrombotic complication of the vascular access site. The endovascular portion of the case proceeded quickly and took approximately 20 minutes. We elected to leave the sheaths in place during the laparotomy in case urgent vascular control was needed. Therefore, the total sheath dwell time was >1 hour. This factor certainly contributed to the patient's access site thrombosis. In addition, we were unable to systemically heparinize because of liver injury, and her iliac vessels were small caliber, causing the left-sided sheath to be occlusive (the external iliacs measured 7 mm in diameter bilaterally). The authors would advocate for a cutdown approach for exposure in the future and removal of the sheaths as soon as possible. In this case, her complication was recognized as soon as the ProGlide devices were deployed and she had absent pulses distally. Thrombectomy then proceeded immediately. As far as choice of stent graft, a Cook Alpha graft was selected because of its low profile and availability of smaller diameter devices.

CONCLUSIONS

This case demonstrates the successful use of a thoracic stent graft for an uncommon injury. Penetrating traumatic aortic injuries in the polytrauma patient present a considerable challenge to the trauma and vascular surgeon and are associated with substantial morbidity and mortality for the patient. The correct management strategy depends on multiple factors, including stability of the patient, time since injury, comorbidities of the patient, and overall traumatic burden. This report demonstrates the feasibility of using this technique for this particular injury and allows a further tool to be added to the vascular and trauma surgeon's armamentarium in managing these severe injuries.

REFERENCES

1. Cho JS, Haider SE, Makaroun MS. Endovascular therapy of thoracic aneurysms: Gore TAG trial results. *Semin Vasc Surg* 2006;19:18-24.
2. Baldwin ZK, Phillips LJ, Bullard MK, Schneider DB. Endovascular stent graft repair of a thoracic aortic gunshot injury. *Ann Vasc Surg* 2008;22:692-6.
3. Vagefi P, Patel M, LaMuraglia G. Endovascular stent for iatrogenic penetrating injury of the thoracic aorta. *Vasc Endovascular Surg* 2014;48:333-6.
4. Yepuri N, Costanza M, Helkin A, Cooney RN. Endovascular stent graft repair of an abdominal gunshot with liver and aortic injuries. *Trauma Surg Acute Care Open* 2017;2:1-2.
5. Rose MK, Pearce BJ, Matthews TC, Patterson MA, Passman MA, Jordan WD. Outcomes after celiac artery coverage during thoracic endovascular aortic aneurysm repair. *J Vasc Surg* 2015;62:36-42.

Submitted Aug 8, 2017; accepted Nov 30, 2017.