



Faculty Scholarship

2018

Mucinous Adenocarcinoma of the Scalp: Primary Cutaneous Neoplasm Versus Underlying Metastatic Disease

Ciara A. Brown

Michael C. Lynch

Cristiane M. Ueno

Follow this and additional works at: https://researchrepository.wvu.edu/faculty_publications



Part of the [Pathology Commons](#), [Plastic Surgery Commons](#), and the [Surgery Commons](#)

Mucinous Adenocarcinoma of the Scalp: Primary Cutaneous Neoplasm Versus Underlying Metastatic Disease

Ciara A. Brown, B.S.*
Michael C. Lynch, M.D.†
Cristiane M. Ueno, M.D.‡

Summary: Primary cutaneous mucinous carcinoma (PCMC) is a rare mucin-producing malignancy derived from epithelial glandular structures. The literature regarding this topic is mostly in the form of case reports and case series. PCMC tends to present in the elderly with predilection for the head and neck and on initial assessment it can be easily mistaken for a simple inclusion cyst. Although PCMC is often indolent in nature, in rare instances it can metastasize and should remain a differential diagnosis in a selected population. The significance in identifying PCMC is reliably differentiating it from metastatic mucinous adenocarcinoma. We present a review of literature and case of PCMC on the scalp of a 67-year-old female. (*Plast Reconstr Surg Glob Open* 2018;6:e1761; doi: 10.1097/GOX.0000000000001761; Published online 16 April 2018.)

P primary cutaneous mucinous carcinoma (PCMC) is a rare mucin-producing malignancy derived from epithelial glandular structures, first described in 1952 by Lennox et al.¹⁻⁴ The tumor most often presents in the sixth or seventh decade with a predilection for the head and neck.⁵⁻⁷ It tends to locally recur, but rarely metastasizes.^{1,2,5} Since its initial description, literature documents various case series and reports of PCMC. After identification of a cutaneous mucin-producing neoplasm, it is essential to differentiate the primary cutaneous form from an underlying metastatic malignancy because the prognosis and management differ drastically.¹⁻⁴

BACKGROUND

In 2005, Kazakov et al.⁵ published a series of mucinous lesions, 37 of which were PCMC with 24 metastatic adenocarcinomas. The average age of presentation in this series was 65.2 years. Of the 37 PCMC identified, 95% presented on the head and neck and 41% were on the scalp. Addi-

tionally, there are a few case series (Table 1) such as the meta-analysis by Kamalpour et al.⁶ containing data from 1952 to 2010, which document 159 PCMC with the majority in the head and neck area.

One of the greatest challenges in identifying PCMC is differentiating it from an underlying metastatic process.^{2-5,8-10} The presentation of the primary cutaneous form both histologically and grossly appears nearly identical to metastatic adenocarcinoma. The tumor cells may stain positive immunohistochemically (IHC) for specific markers of breast, lung, ovary, prostate, and gastrointestinal (GI) tumors that will carry a poor prognosis.¹⁻⁴ Research in differentiating these processes via IHC markers has been pursued. In a small series by Levy et al.,³ PCMC and breast metastatic mucinous carcinoma to the skin stained positive for CK7, whereas primary colorectal adenocarcinoma stained positive for CK20. Authors concluded that CK20 was an appropriate IHC marker to differentiate GI adenocarcinomas; however, the other markers were neither sensitive nor specific enough to differentiate breast from the primary cutaneous forms. Literature supports that the presence of an in situ component favors PCMC, whereas location on the chest wall or in the axilla tends to favor a breast primary.⁵

In a 16-year retrospective study at a single cancer center, 51 cases of metastatic adenocarcinoma from an internal primary were identified.⁸ In the majority of them, the cutaneous metastatic lesion presented within 3 years following initial diagnosis; however, in 6 cases, the cutaneous metastasis was the initial presentation of an underlying malignancy. These findings support the importance of a

*From the *Department of Surgery, Division of Plastic and Reconstructive Surgery, West Virginia University School of Medicine, Morgantown, W. Va.; †Department of Pathology, West Virginia University School of Medicine, Morgantown, W. Va.; and ‡Department of Surgery, Division of Plastic and Reconstructive Surgery, West Virginia University School of Medicine, Morgantown, W. Va. Received for publication November 28, 2017; accepted March 1, 2018.*

Copyright © 2018 The Authors. Published by Wolters Kluwer Health, Inc. on behalf of The American Society of Plastic Surgeons. This is an open-access article distributed under the terms of the Creative Commons Attribution-Non Commercial-No Derivatives License 4.0 (CCBY-NC-ND), where it is permissible to download and share the work provided it is properly cited. The work cannot be changed in any way or used commercially without permission from the journal.

DOI: 10.1097/GOX.0000000000001761

Disclosure: The authors have no financial interest to declare in relation to the content of this article. The Article Processing Charge was paid for by the authors.

Table 1. PCMC in the Literature

Author	Cases	Age Range (Average)	Head and Neck	Trunk/Other	Outcomes
Breiting et al. ²	15	43–83 (64)	14	1	1 patient required chemotherapy for recurrence, 1 regional lymph node metastasis
Mendoza and Helwig ⁴	14	8–76 (51.3)	9	5	6 recurrences, 1 regional lymph node metastasis
Kazakov et al. ⁵	37	31–89 (65)	35	2	7 reexcisions due to positive margins, 5 recurrences
Kamalpour et al. ⁶	159	63.5	137	22	15 treated with Mohs: 2 (13%) recurrences; 136 treated with excision: 46 (34%) recurrences
Al Betedдини et al. ⁷	1	61	1		Mohs surgery
Choi et al. ⁹	1	49	1		5 mm excision margin, no recurrence
Hanna et al. ¹⁰	1	74	1		Recurrence following surgical excision, subsequently treated with radiation

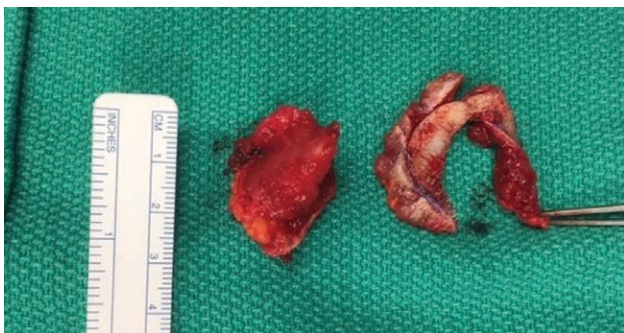


Fig. 1. Intraoperative excised scalp specimen revealing transition between the skin and lesion.

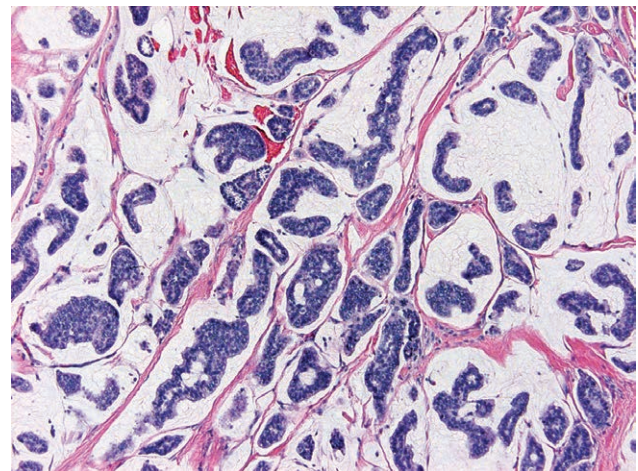


Fig. 2. Hematoxylin and eosin staining 100× magnification of excised specimen.

thorough workup for underlying malignancy upon recognition of a cutaneous mucinous neoplasm.

Treatment modalities of PCMC include surgical excision or Mohs procedure, with local recurrence rates up to 40%.⁶ A poor outcome, defined by recurrence or metastasis, was associated with younger age at presentation, lesion > 1.5cm, and lesions presenting on the trunk.⁶ Alternatively, a favorable outcome was associated with individuals who presented at an older age, with smaller lesions, and lesions on the head and neck.⁶ In rare instances, radiation alone, or in combination with chemotherapy, has been attempted in patients with distant metastasis of PCMC with little success.^{6,10}

CASE PRESENTATION

A 67-year-old Caucasian female with medical history of inflammatory bowel disease presented for evaluation of an enlarging, palpable scalp mass for the past year. She reports that in addition to growth, the lesion started to cause migraine headaches. On physical examination, a mobile mass measuring 5 × 3 cm was observed on the right temporal scalp region. The skin was thickened but no ulceration, bleeding, or sinus tracts were appreciated. Based on clinical evaluation, the patient was scheduled for lesion excision and closure of a suspected epidermal inclusion cyst.

The patient was brought to the operating room for surgical excision of lesion. However, instead of revealing the expected cyst wall, the opening incision revealed a pink, nonwalled mucinous substance. Due to the unexpected findings, the surgeon completed an excisional biopsy with primary closure (Fig. 1).

Hematoxylin and eosin histologic examination revealed an infiltrative tumor center in the dermis and

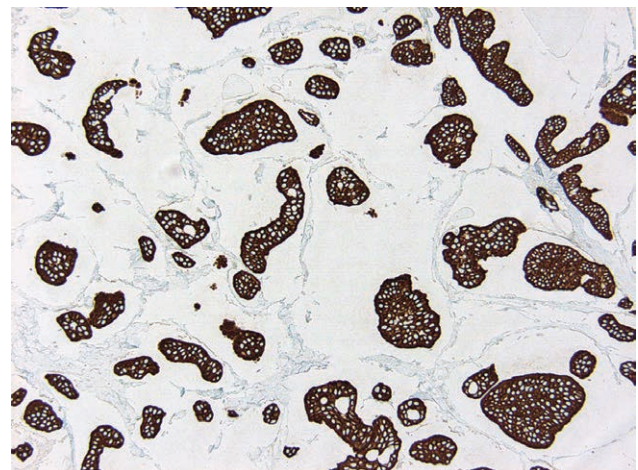


Fig. 3. Specimen showing CK 7-positive immunohistochemical staining.

extending into the subcutis and margins of resection. The tumor was composed of pools of mucin separated by thin fibrous septae with mildly atypical epithelial clusters and duct formation floating amongst the mucin (Fig. 2). IHC analysis showed the tumor cells to be strongly CK7-positive (Fig. 3) while CK 20-negative. Based on these findings, the histologic differential diagnosis included PCMC versus

metastatic mucinous carcinoma, especially of the breast due to CK7 positivity. Therefore, the patient was referred to oncology for a thorough oncologic workup.

Mammography showed no abnormalities, excluding breast as primary; however, positron emission tomography scan revealed hypermetabolic activity suspicious for rectal adenocarcinoma. Following discussion with her gastroenterologist and oncologist, the increased activity observed from the positron emission tomography scan was determined to be secondary to her history of inflammatory bowel disease. This diagnosis was biopsy proven, thereby ruling out a GI malignant primary. After discussion with the pathologist, comprehensive assessment of IHC CK20-negative staining further supported the excised lesion as a PCMC. Literature on resection margins for PCMC is scarce. The decision for margin reexcision was based on management of malignant skin cancers.^{9,10} Reexcision was performed with a 1.0-cm margin, leading to a 6 × 4 cm defect that was closed via complex wound closure. The final pathology reported negative margins. The patient is 6 months postoperative with no recurrences and follows in conjunction with oncology.

DISCUSSION

This case demonstrates the relatively rare phenomenon of PCMC presentation (estimated < 50 documented cases with scalp presentation). PCMC should be in the differential diagnosis of cutaneous lesions, specifically in patients of older age with lesions of the head and neck. Literature describes metastatic cutaneous adenocarcinoma with primary sites of malignancy in the lungs, breast, and viscera. Although IHC stains aid in the workup of primary cutaneous versus metastatic mucinous adenocarcinoma, they should not be relied on exclusively to determine the definitive diagnosis. Upon discovery of a cutaneous lesion with histology, suggesting mucinous adenocarcinoma, a thorough oncologic workup is warranted to rule out an underlying malignancy. For the future, given the rarity of

this tumor, it is important to maintain continuous documentation especially regarding margin resection to track outcomes such as recurrence and metastasis.

Ciara A. Brown, BS

Plastic Surgery

HSC-S, PO Box 9238

Morgantown, WV 26506

E-mail: cebrown2@mix.wvu.edu

REFERENCES

1. Lennox B, Pearse AG, Richards HG. Mucin-secreting tumours of the skin with special reference to the so-called mixed-salivary tumour of the skin and its relation to hidradenoma. *J Pathol Bacteriol.* 1952;64:865–880.
2. Breiting L, Christensen L, Dahlstrøm K, et al. Primary mucinous carcinoma of the skin: a population-based study. *Int J Dermatol.* 2008;47:242–245.
3. Levy G, Finkelstein A, McNiff JM. Immunohistochemical techniques to compare primary vs. metastatic mucinous carcinoma of the skin. *J Cutan Pathol.* 2010;37:411–415.
4. Mendoza S, Helwig EB. Mucinous (adenocystic) carcinoma of the skin. *Arch Dermatol.* 1971;103:68–78.
5. Kazakov DV, Suster S, LeBoit PE, et al. Mucinous carcinoma of the skin, primary, and secondary: a clinicopathologic study of 63 cases with emphasis on the morphologic spectrum of primary cutaneous forms: homologies with mucinous lesions in the breast. *Am J Surg Pathol.* 2005;29:764–782.
6. Kamalpour L, Brindise RT, Nodzenski M, et al. Primary cutaneous mucinous carcinoma: a systematic review and meta-analysis of outcomes after surgery. *JAMA Dermatol.* 2014;150:380–384.
7. Al Beteddi OS, Sheikh S, Shareefi F, et al. Primary mucinous adenocarcinoma of the scalp: a case report and literature review. *Int J Surg Case Rep.* 2015;10:241–244. doi: 10.1016/j.ijscr.2015.02.006.
8. Sariya D, Ruth K, Adams-McDonnell R, et al. Clinicopathologic correlation of cutaneous metastases: experience from a cancer center. *Arch Dermatol.* 2007;143:613–620.
9. Choi JH, Kim SC, Kim J, et al. Primary cutaneous mucinous carcinoma treated with narrow surgical margin. *Arch Craniofac Surg.* 2016;17:158–161.
10. Hanna SA, Hu J, Gupta A, et al. Surgical management of primary cutaneous mucinous carcinoma. *Clin Skin Cancer.* 2017;1:94–96. doi:10.1016/j.dsc.2017.04.002.