

2017

Negative-Pressure Wound Therapy for Ludwig's Angina: A Case Series

Nainika Nanda
West Virginia University

Habib Zalzal
West Virginia University

Gregory Borah
West Virginia University

Follow this and additional works at: https://researchrepository.wvu.edu/faculty_publications

Digital Commons Citation

Nanda, Nainika; Zalzal, Habib; and Borah, Gregory, "Negative-Pressure Wound Therapy for Ludwig's Angina: A Case Series" (2017). *Faculty Scholarship*. 1346.
https://researchrepository.wvu.edu/faculty_publications/1346

This Article is brought to you for free and open access by The Research Repository @ WVU. It has been accepted for inclusion in Faculty Scholarship by an authorized administrator of The Research Repository @ WVU. For more information, please contact ian.harmon@mail.wvu.edu.

Negative-Pressure Wound Therapy for Ludwig's Angina: A Case Series

Nainika Nanda, BA*
Habib G. Zalzal, MD†
Gregory L. Borah, MD, FACS‡

Summary: Negative-pressure wound therapy (NPWT) is a well-established therapeutic approach for various complex wound classes. There is currently limited information on the use of NPWT for the scope of head and neck wounds. However, NPWT has been used successfully in some cases, including malignancy, infection, and trauma. In West Virginia, the incidence of dental-related infections leading to Ludwig's Angina is high due to lack of access to dental care. Our case series describes the application of vacuum-based therapy in conjunction with antibiotic therapy for quick, effective closure of deep tissue infections before definitive complex wound repair via graft and flap reconstructions. Over a period of 3 months, 2 patients with submental infections extending to the lateral neck demonstrated clean, efficient wound closure with NPWT for less than 14 days while hospitalized at West Virginia University Medicine. Outpatient follow-up with these patients demonstrated excellent cosmetic outcomes with minimal contracture or hypertrophy of healing tissue. NPWT promotes wound healing through decreased edema, improved perfusion, and increased granulation of tissue based on our findings. Our series encourages the use of NPWT for initial closure of complex wounds secondary to deep neck infections. (*Plast Reconstr Surg Glob Open* 2017;5:e1561; doi: 10.1097/GOX.0000000000001561; Published online 7 November 2017.)

INTRODUCTION

Ludwig's angina is a deep neck space infection, which typically affects an immunocompromised patient resulting in airway compromise, which can lead to death. This disease etiology involves spread of odontogenic bacteria in the neck through the mylohyoid muscle into submental and para-laryngeal spaces. Untreated Ludwig's angina often leads to death due to rapid progression of the infection and resulting massive edema causing para-pharyngeal swelling, airway constriction, and asphyxiation. Prompt diagnosis is essential for survival and is usually made by oral maxillofacial (OMFS) and otolaryngology surgeons. Current therapy protocol entails parenteral antibiotics, airway control, extraction of infected teeth, and wide surgical incision and drainage, but limited in-

formation exists on the effectiveness of negative-pressure wound therapy (NPWT) for these devastating head and neck (H&N) infections.¹

NPWT is a well-established therapeutic approach for complex wound problems often used by plastic and general surgeons. NPWT results in vacuum-assisted removal of reactive tissue exudate, reducing edema, which in turn improves tissue perfusion to promote granulation and preparation for definitive closure. NPWT has been documented in various surgical cases involving malignancy, posttraumatic wounds, and infections, such as Fournier's gangrene.² However, it has not been reported in Ludwig's angina odontogenic infections. Our series using NPWT for Ludwig's Angina demonstrates its lifesaving benefits in cervical necrotizing fasciitis manifesting from dental infection and cervical spread.

PATIENT CASE 1

A 45-year-old man with uncontrolled diabetes mellitus type 2 presented with submental cellulitis. His lower molar fractured, but he did not seek care until 4 days later. He presented with progressive neck swelling, hoarseness, sore throat, and dysphagia. A computed tomography scan showed a deep submandibular and submental infection with interstitial free air. The diagnosis of Ludwig's angina

From the *West Virginia University School of Medicine, Morgantown, W.Va.; †Department of Otolaryngology-Head and Neck Surgery, West Virginia University School of Medicine, Morgantown, W.Va.; and ‡Division of Plastic, Reconstructive and Hand Surgery, West Virginia University School of Medicine, Morgantown, W.Va.
Received for publication May 15, 2017; accepted September 15, 2017.

Copyright © 2017 The Authors. Published by Wolters Kluwer Health, Inc. on behalf of The American Society of Plastic Surgeons. This is an open-access article distributed under the terms of the Creative Commons Attribution-Non Commercial-No Derivatives License 4.0 (CCBY-NC-ND), where it is permissible to download and share the work provided it is properly cited. The work cannot be changed in any way or used commercially without permission from the journal.

DOI: 10.1097/GOX.0000000000001561

Disclosure: The authors have no financial interest to declare in relation to the content of the article. The Article Processing Charge was paid for by the authors.

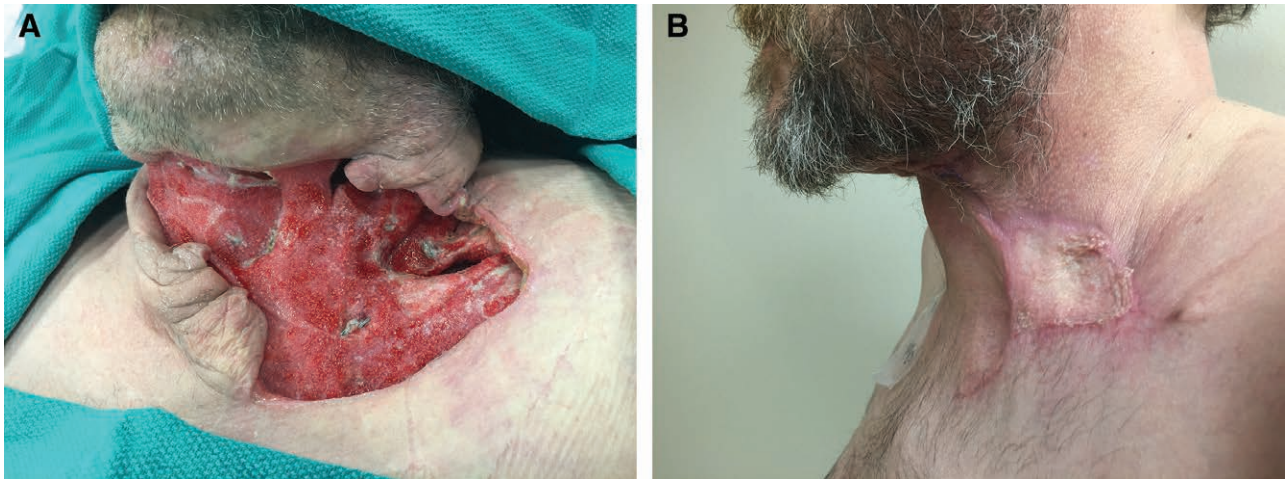


Fig. 1. Patient 1 with NPWT in place (A), and at clinic follow-up 1 week after discharge following reconstruction (B).

was made, and broad spectrum antibiotics were started. He underwent emergent incision and drainage. Intraoperative cultures grew *Enterococcus*, coagulase-negative *Staphylococcus*, and multiple anaerobic organisms. Over 6 weeks, the patient required multiple procedures with debridement of tissue necrosis. Because of worsening clinical state, our plastic surgical team was consulted for management of this neck infection. Tissues were noted to have copious serous purulence, so a vacuum-assisted closure VeraFlo Cleanse Dressing was placed in the operating room. The irrigating vacuum dressing was changed every 2 days, and he rapidly improved over the course of the next week. He was extubated without incident and able to take fluids and semisolid food by mouth for the first time in 7 weeks. His cervical wound was repaired with skin graft and fasciocutaneous flaps. Follow-up demonstrated well-healing wound at 3 months (Fig. 1).

PATIENT CASE 2

A 40-year-old man with morbid obesity presented with fevers, right-sided facial edema, and pain for 5 days. He had trismus, dysphagia to solids, and orofacial purulence. Computed tomography imaging reported inflammation of the face with suspected abscess and retropharyngeal space involvement. Intravenous clindamycin was started. He emergently underwent awake intubation, tooth extraction, and incision and drainage of the pharyngeal space, buccal space, and submandibular and sublingual spaces. Intraoperative cultures grew mixed oral flora. He underwent standard wound care over a period of 11 days by the OMFS service with little improvement, so the plastic surgery team was consulted on day 12. An irrigating vacuum-assisted closure system was immediately applied in the operating room to the open wounds underneath the mandible and supraclavicular wound area. The NPWT was changed ev-

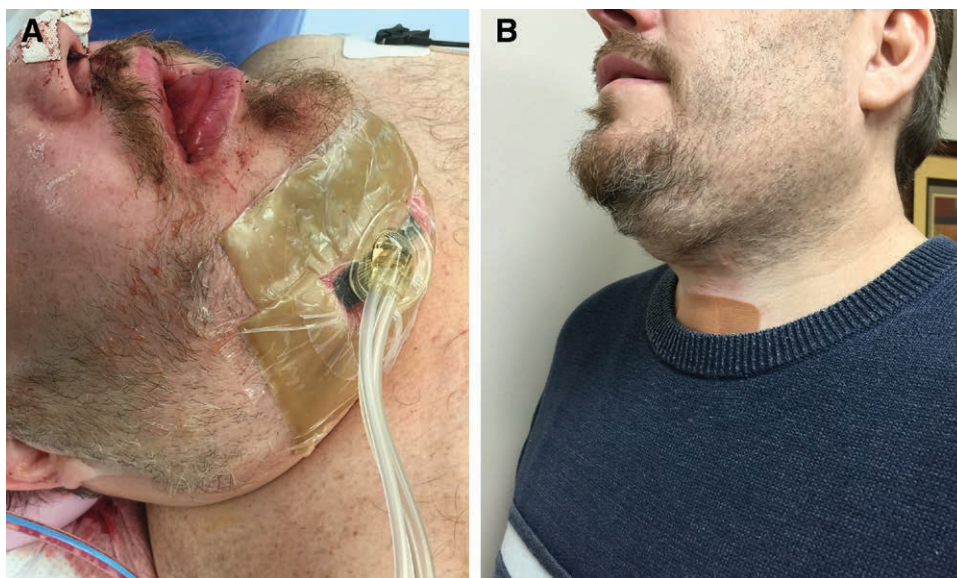


Fig. 2. Patient 2 following removal of NPWT without reconstruction (A), and at follow-up outpatient 2 weeks after reconstruction (B).

ery other day for 1 week with rapid improvement in his infection. He began oral feeding within a few days. Wound closure was achieved with a tissue flap. Follow-up demonstrated near-complete wound healing (Fig. 2).

DISCUSSION

The 2 areas of important advantages for NPWT in Ludwig's angina infections are (1) definitive infection control by rapid wound drainage and (2) wound preparation for closure. In our series, the effectiveness of infection control is the most important. The first case demonstrates that Ludwig's angina is difficult to manage even with intense use of powerful antibiotics and surgical release and debridement. When NPWT with irrigation and vacuum drainage was added, the patient made a rapid recovery. This lesson was applied to the second patient who received early initiation of NPWT and had prompt resolution of the infection and swelling. The effectiveness of NPWT for wound closure was helpful, but the lifesaving benefits of NPWT for edema control and reduction of the causative infection were paramount.

Odontogenic infections of Ludwig's angina are not discussed in the few reports of NPWT in H&N. One article discusses NPWT for local infection control for a cutaneous neck wound abscess.³ Another case of mandibular osteoradionecrosis reported use of NPWT before definitive reconstruction.⁴ Forehead defects with full-thickness tissue loss showed granulation formation with NPWT followed by surgical closure.⁵ Four retrospective reviews of 112 patients with 73 H&N wounds demonstrated improved wound healing without complication.⁶⁻¹⁰

CONCLUSIONS

Ludwig's angina is a difficult infection to manage even with intense use of powerful antibiotics and deep space surgical release and debridement. Despite being a well-documented treatment modality, NPWT use in Ludwig's angina has not been widely reported in the literature. The 2 important areas of interest for NPWT in Ludwig's angina patients are: (1) definitive infection control and (2) wound preparation for closure. In our series, the utility of NPWT for infectious control demonstrated rapid improvement in clinical condition and prompt resolution of infection. The

effectiveness of NPWT on preparation of the wound sites for definitive closure is helpful, but the probable lifesaving benefits of NPWT for control and treatment of the causative infection are paramount. Plastic surgeons are well informed about the usefulness of NPWT for tissue infections. However, other specialties, such as OMFS and otolaryngology, which are more likely to encounter Ludwig's patients may not be aware of this application for NPWT. The dramatic effectiveness of NPWT in the life-threatening disease in this article educates surgeons on potential wound vacuum applications for future Ludwig's angina patients.

Habib G. Zalzal, MD

Department of Otolaryngology-Head and Neck Surgery
West Virginia University School of Medicine
1 Medical Center Drive
Morgantown, WV 26506
E-mail: hgzalzal@hsc.wvu.edu

REFERENCES

1. Boscolo-Rizzo P, Da Mosto MC. Submandibular space infection: a potentially lethal infection. *Int J Infect Dis.* 2009;13:327-333.
2. Leong M, Murphy KD, Phillips LG. *Sabiston Textbook of Surgery.* Chapter 6: Wound healing. Elsevier, Philadelphia, PA 130-162.
3. Frankel JK, Rezaee RP, Harvey DJ, et al. Use of negative pressure wound therapy with instillation in the management of cervical necrotizing fasciitis. *Head Neck.* 2015;37:E157-E160.
4. Poglio G, Grivetto F, Nicolotti M, et al. Management of an exposed mandibular plate after fibula free flap with vacuum-assisted closure system. *J Craniofac Surg.* 2011;22:905-908.
5. Hsia JC, Moe KS. Vacuum-assisted closure therapy for reconstruction of soft-tissue forehead defects. *Arch Facial Plast Surg.* 2011;13:278-282.
6. Satteson ES, Crantford JC, Wood J, et al. Outcomes of vacuum-assisted therapy in the treatment of head and neck wounds. *J Craniofac Surg.* 2015;26:e599-e602.
7. Yang YH, Jeng SF, Hsieh CH, et al. Vacuum-assisted closure for complicated wounds in head and neck region after reconstruction. *J Plast Reconstr Aesthet Surg.* 2013;66:e209-e216.
8. Dhir K, Reino AJ, Lipana J. Vacuum-assisted closure therapy in the management of head and neck wounds. *Laryngoscope.* 2009;119:54-61.
9. Tian B, Khoo D, Tay AC, et al. Management of orocutaneous fistulas using a vacuum-assisted closure system. *Head Neck.* 2014;36:873-881.
10. Govea-Camacho LH, Astudillo-Carrera A, Hermosillo-Sandoval JM, et al. [Impact of vacuum-assisted closure management in deep neck abscesses]. *Cir Cir.* 2016;84:275-281.